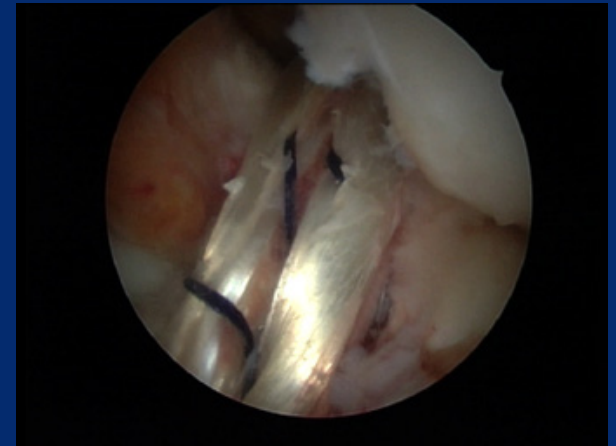


ACL reconstruction with Hamstring tendons

How I do



François Kelberine, Jean Philippe Vivona

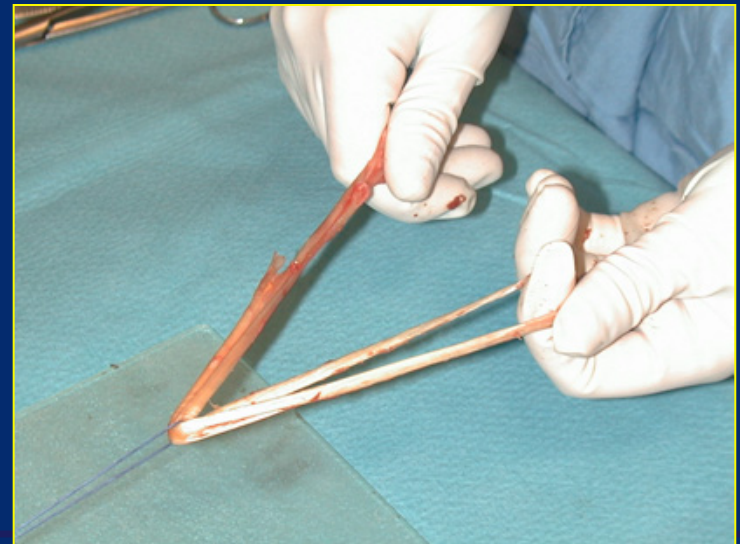
Aix en Provence, France



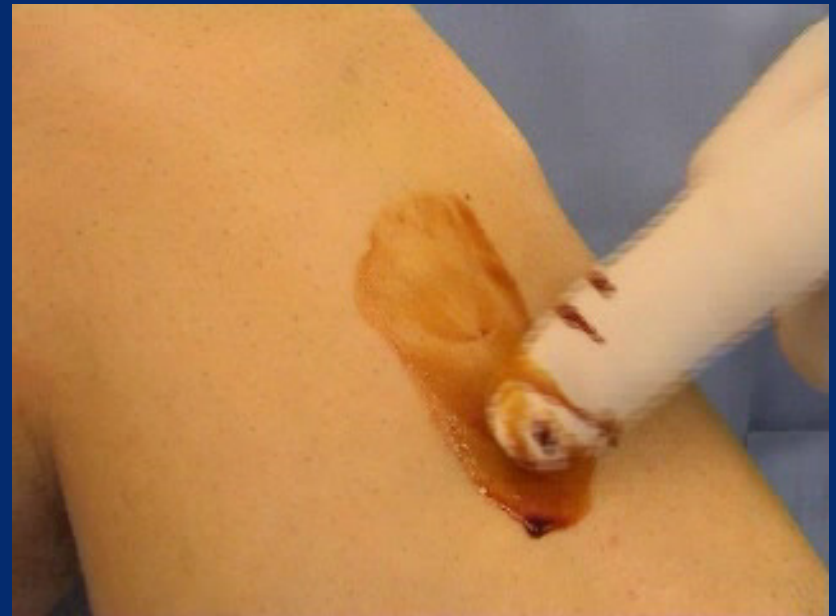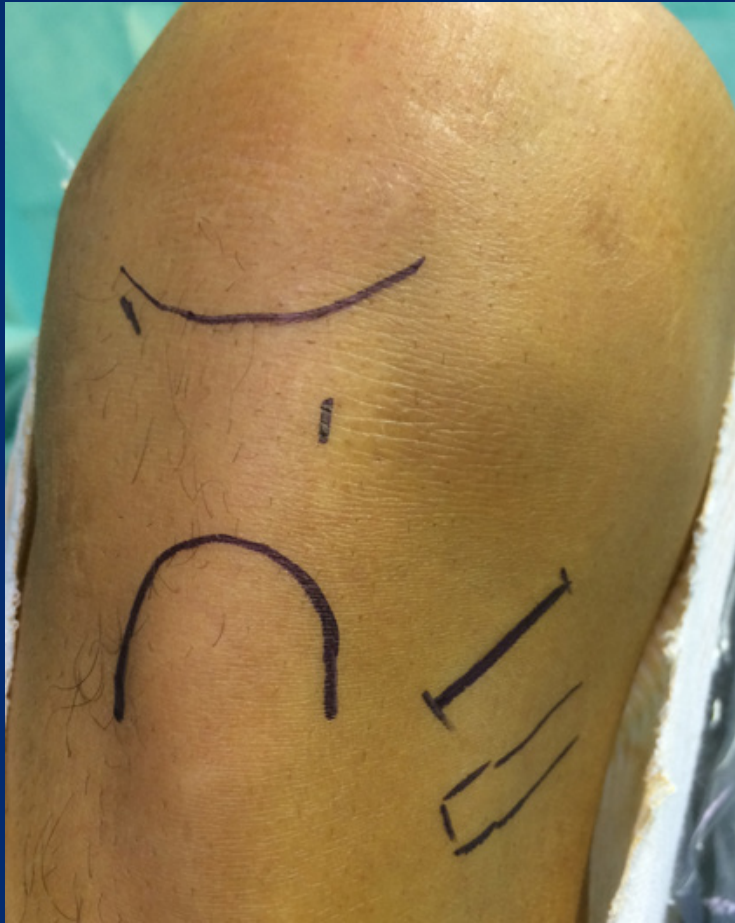✓ Graft harvesting and preparation

✓ Transtibial femoral tunnel

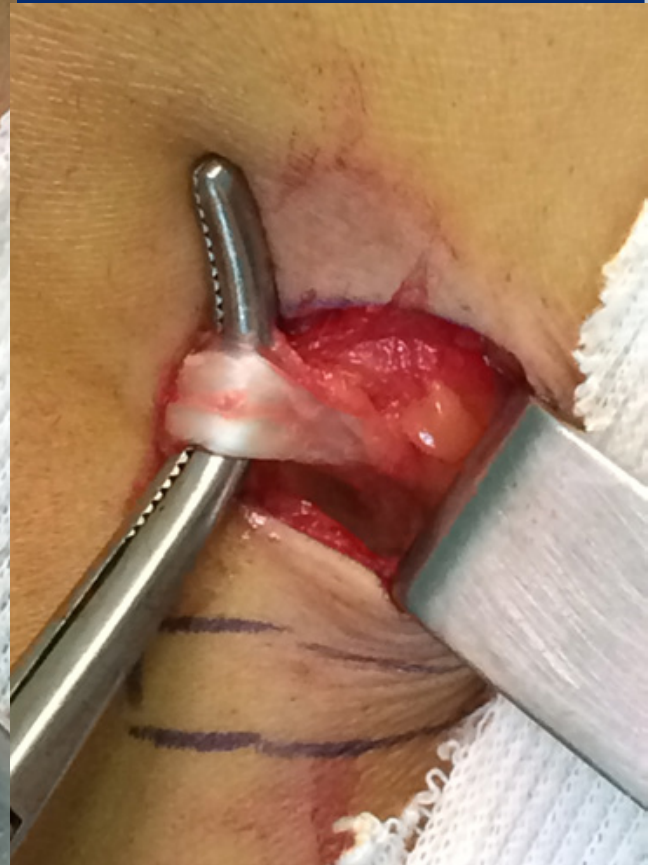
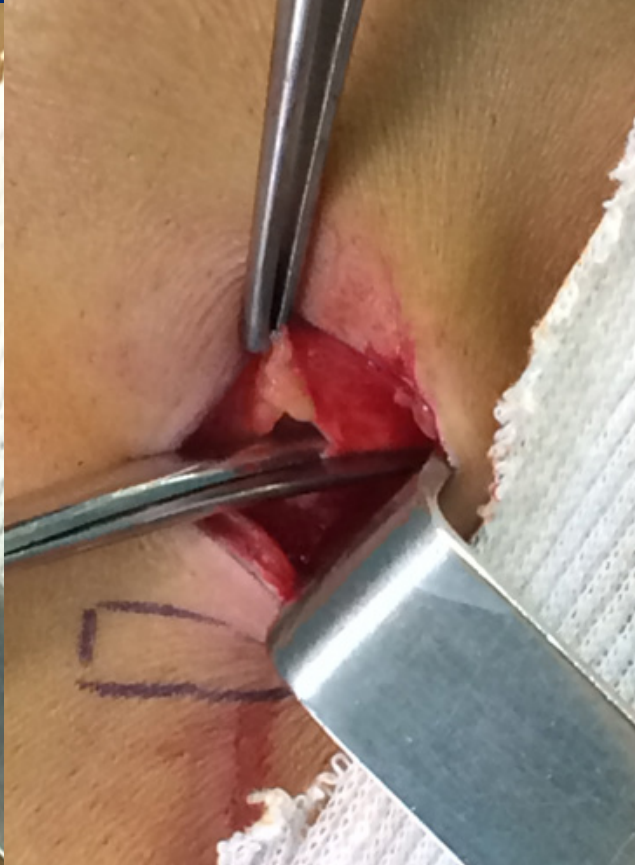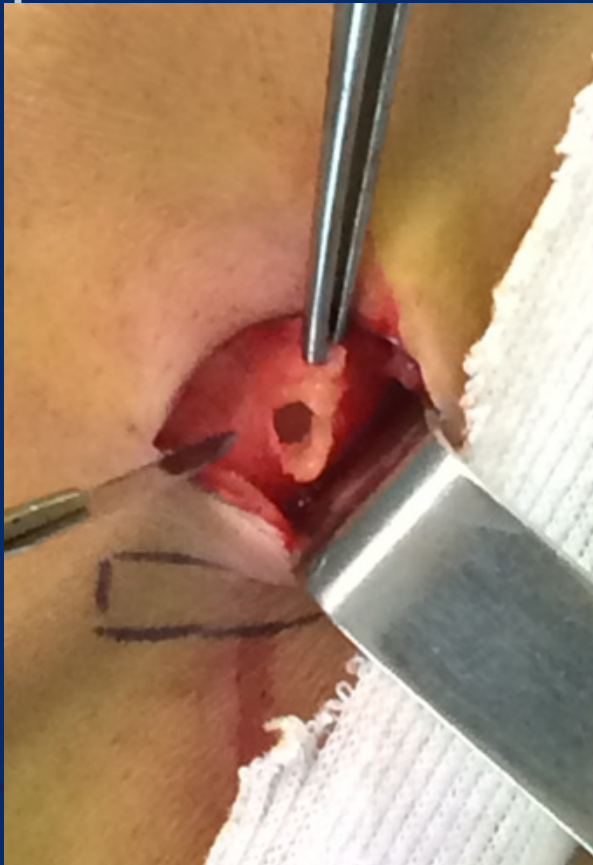✓ Fixation



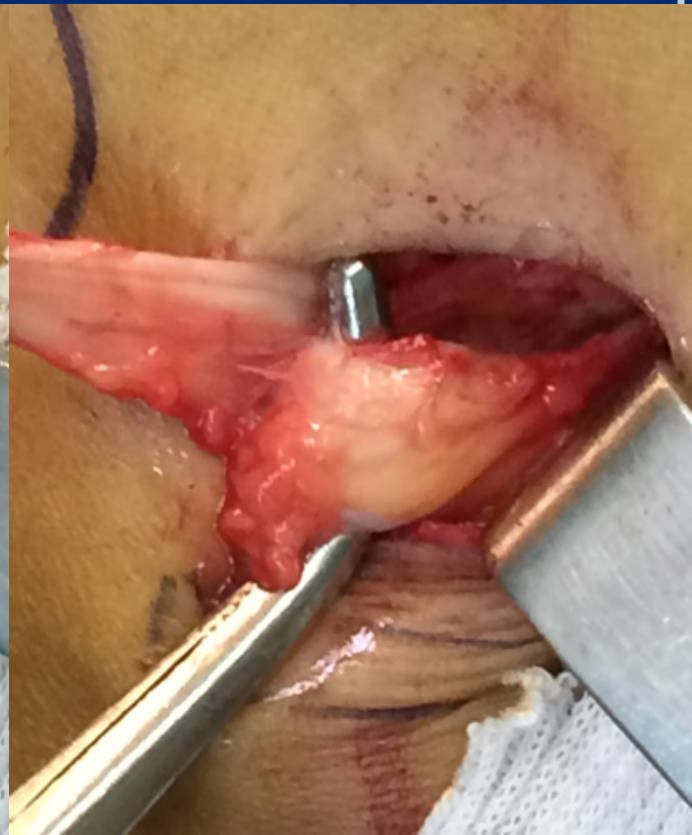
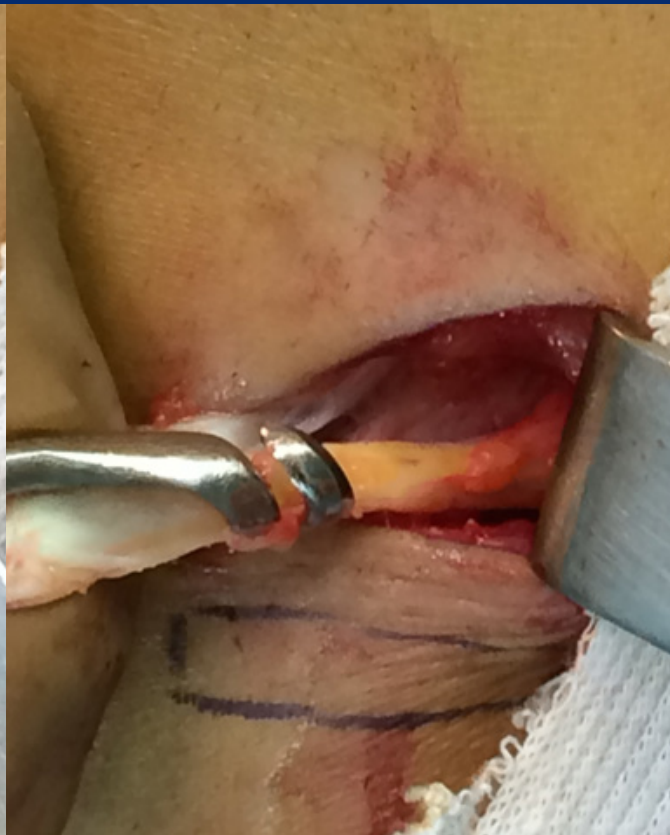
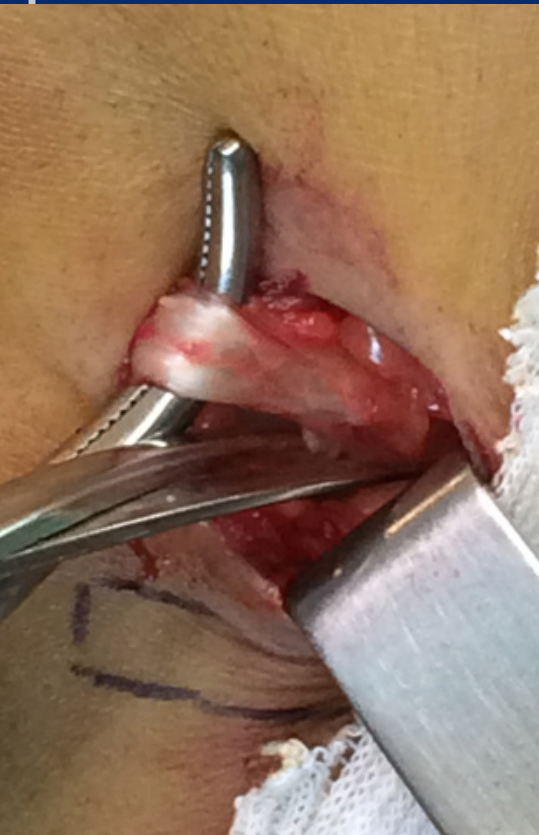Skin incision



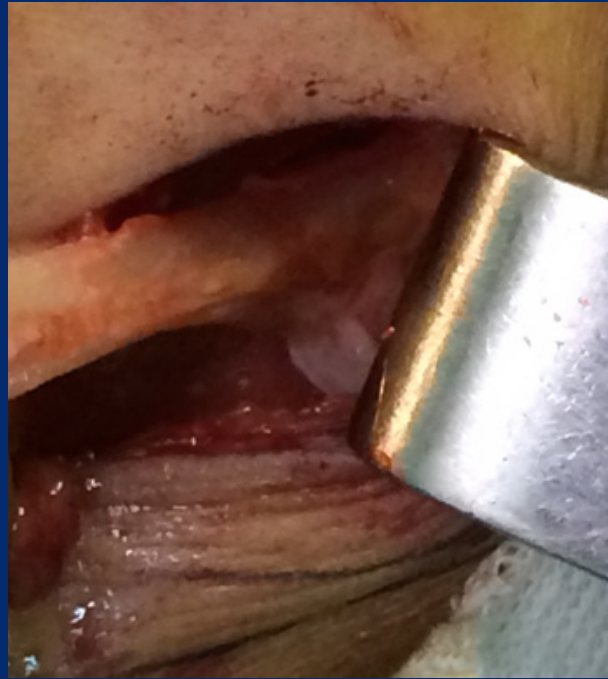- ✓ Hang sartorius & open (air) enlarge proximal
- ✓ Gracilis @ the deep part (pull sartorius)
- ✓ Grasper or hook



- ✓ Cut posterior vinculae, open stripper
- ✓ Hanging gracilis pulls out ST
- ✓ Cut post expansion +++



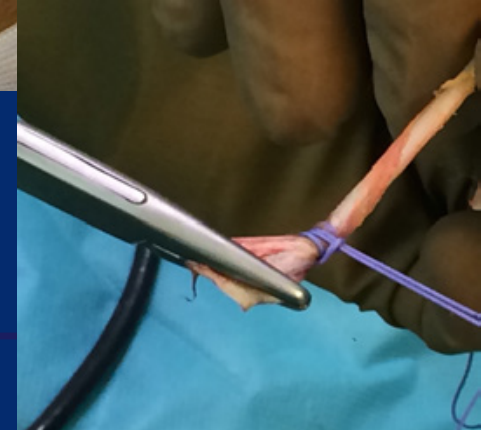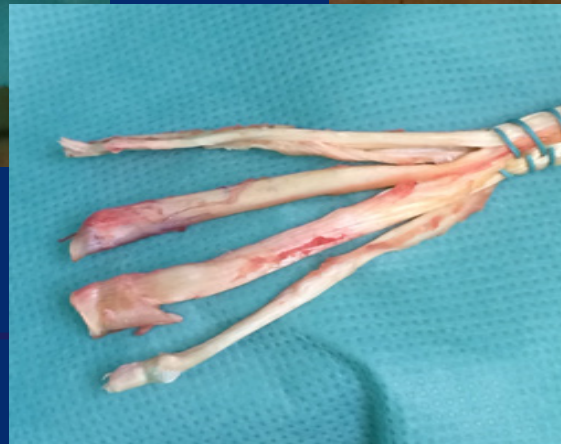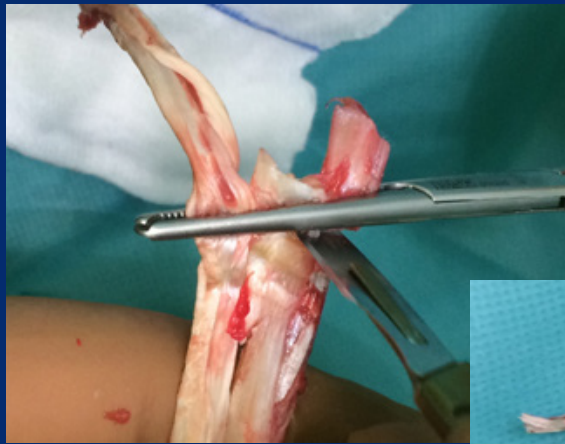
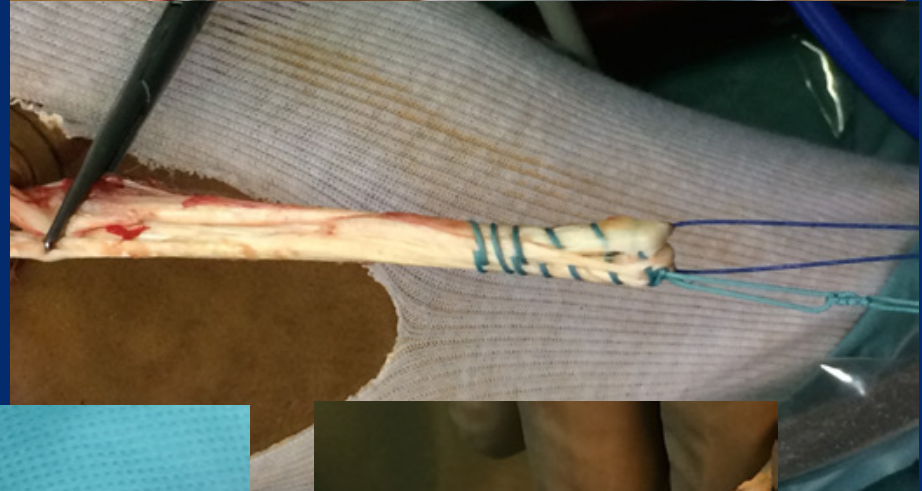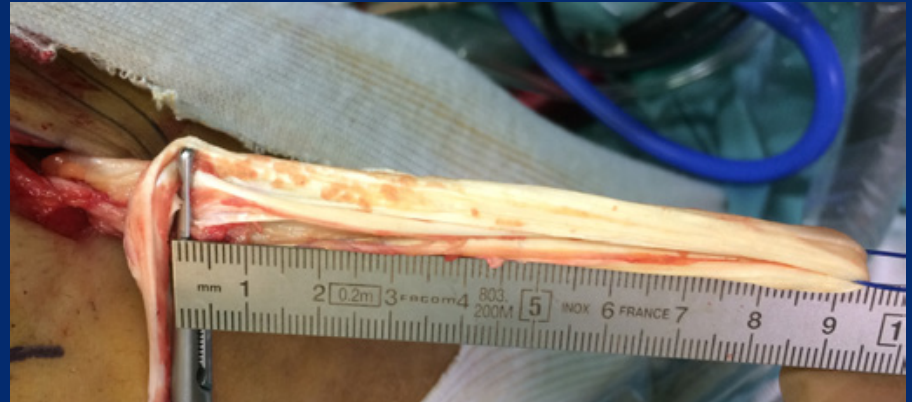Tricks for the stripper



- ✓ Replace the hook by the finger
- ✓ Check the direction
- ✓ Push as much as you pull
- ✓ Pay attention to early resistance (remaining expansion)


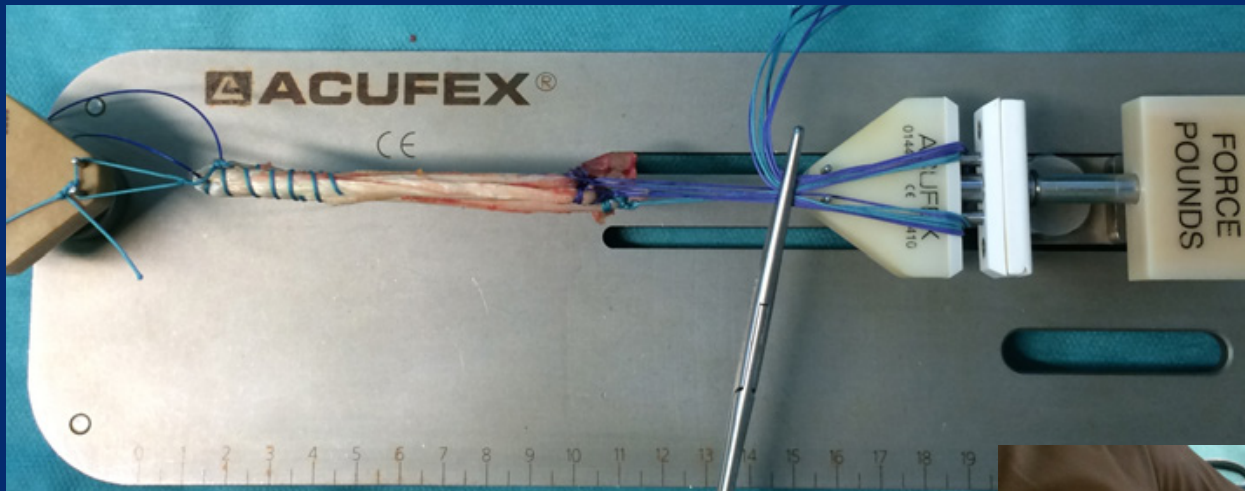
Preparing the graft

- ✓ Length
- ✓ Suture femoral extremity
- ✓ Octopus



Preparing the graft

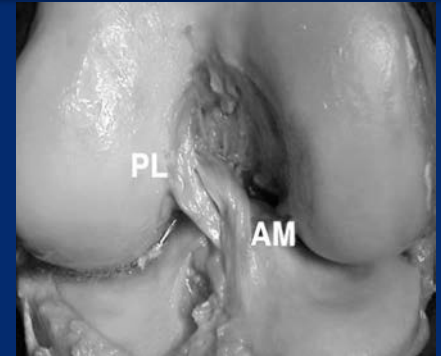
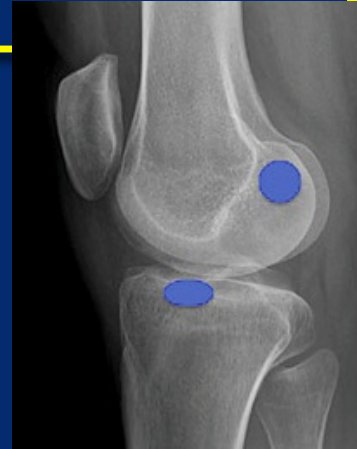✓ Tension ++++



Transtibial femoral tunnel Base is Anatomy

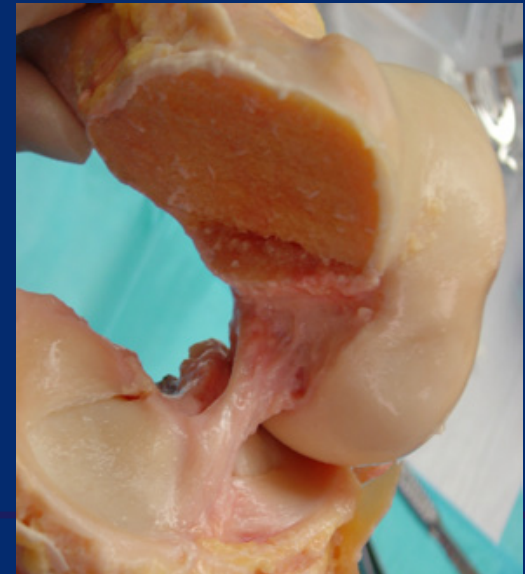
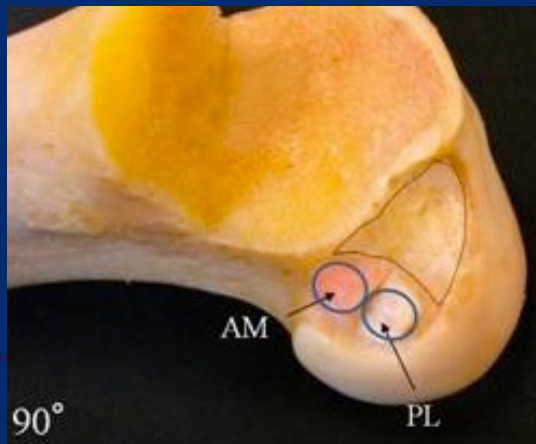


✓ To go from A to B



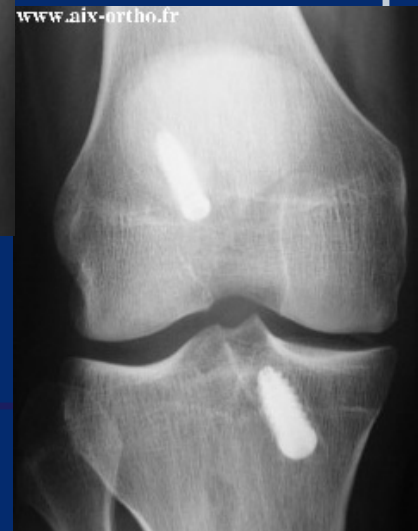
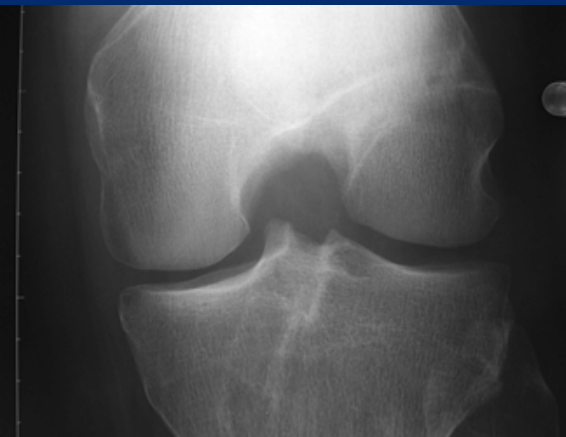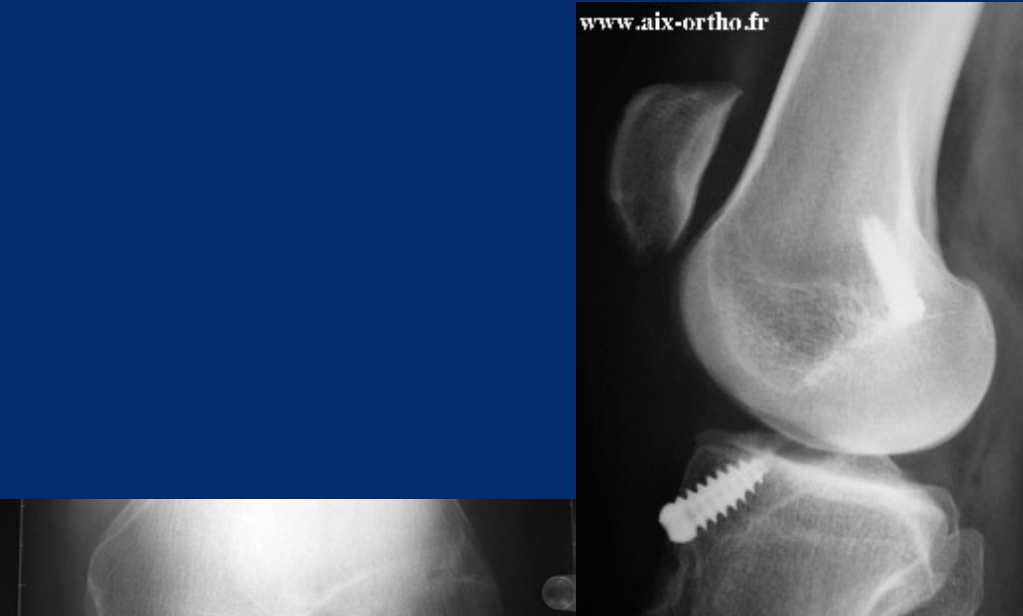
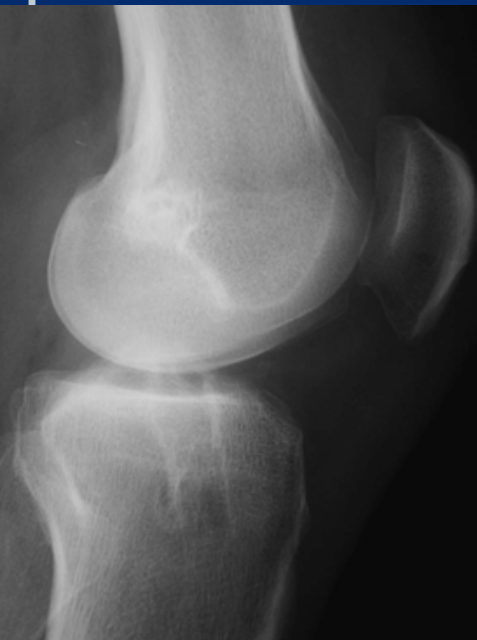
✓ ACL femoral insertion spot

Post and Medial



Femoral tunnel is less important

✓ Direction, diameter, length

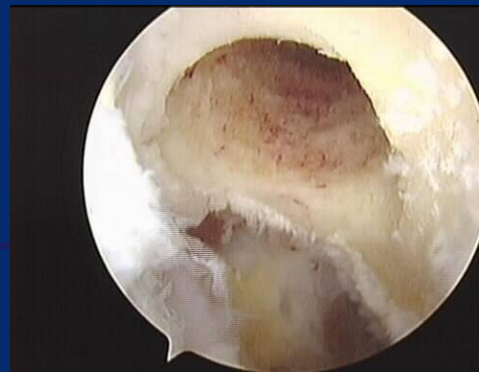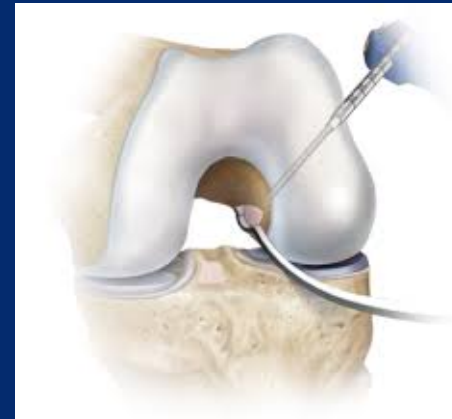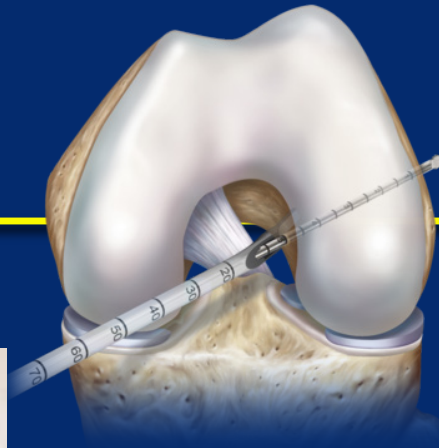


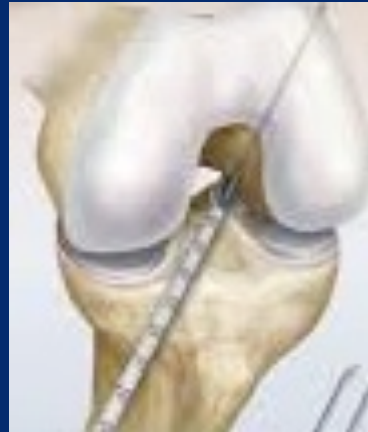✓ Anteromedial portal

✓ Transtibial

✓ Out in technique

✓ Reliable and reproducible



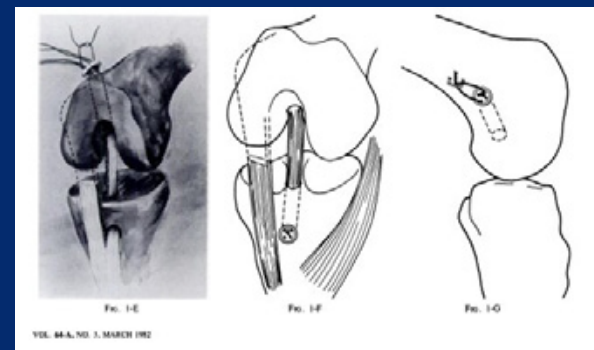
Literature

93 hits the last 5 years

✓ Advantages AM portal \geq Out/In $>$ Transtibial

✓ Significant !!

- ✓ 1,2 to 2,3 mm
- ✓ Clock position



✓ Comparison with malpositioned femoral spot

✓ Thanks to DB studies to show that we have to be oblique (for those who did notice it before...)

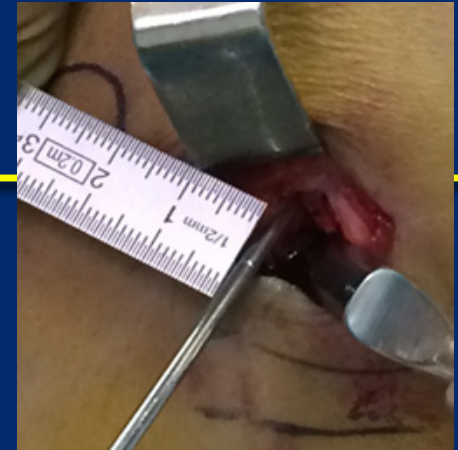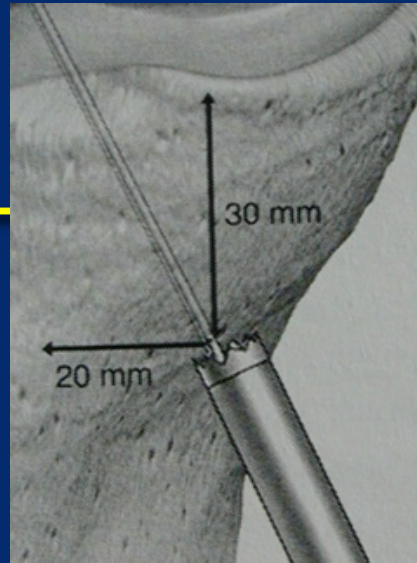
Weak points of the "rules"

- ✓ **Intra tester reliability**
 - ✓ Change with patient's morphotype
 - ✓ Dominant hand
- ✓ **Knee anatomy**
- ✓ **Is it valid & clinically relevant?**

Trans tibial

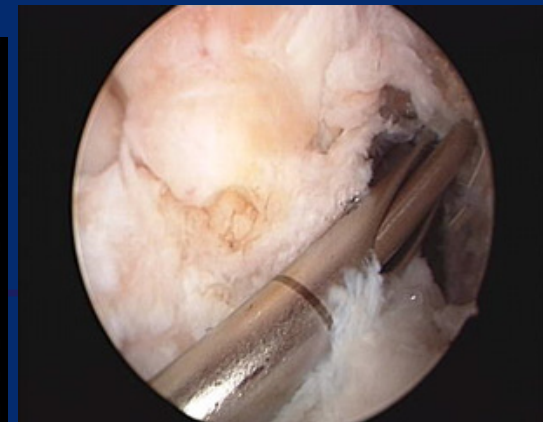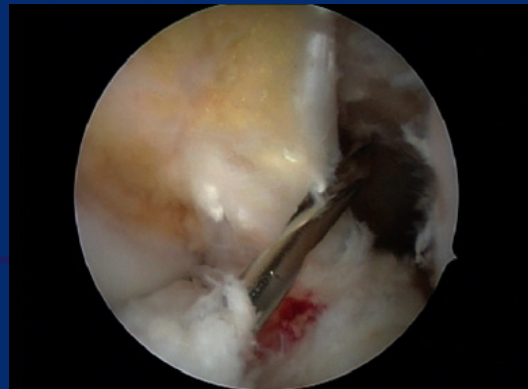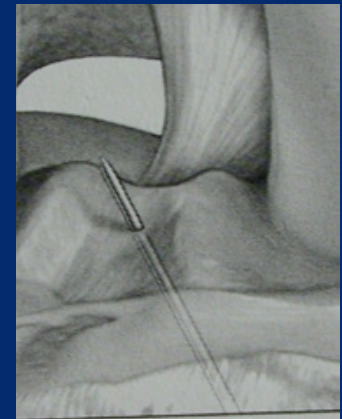✓ Technique

- ✓ Spot tibial cortex
- ✓ Offset guide



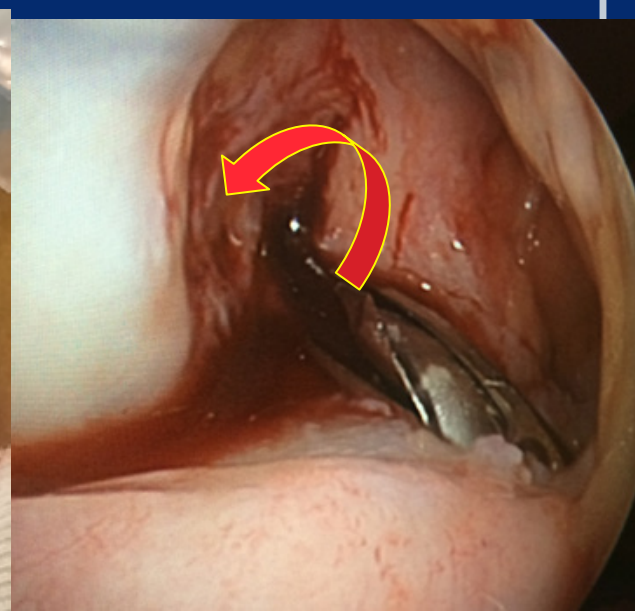
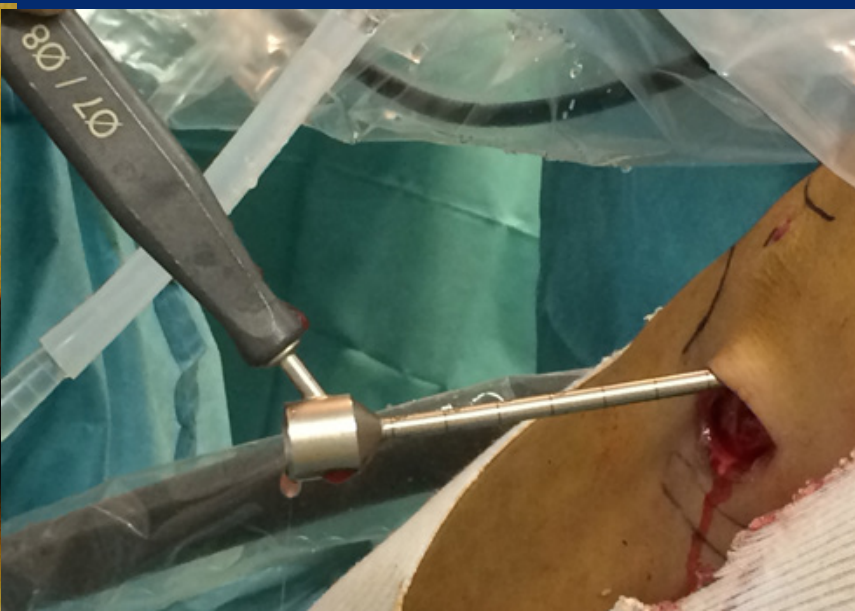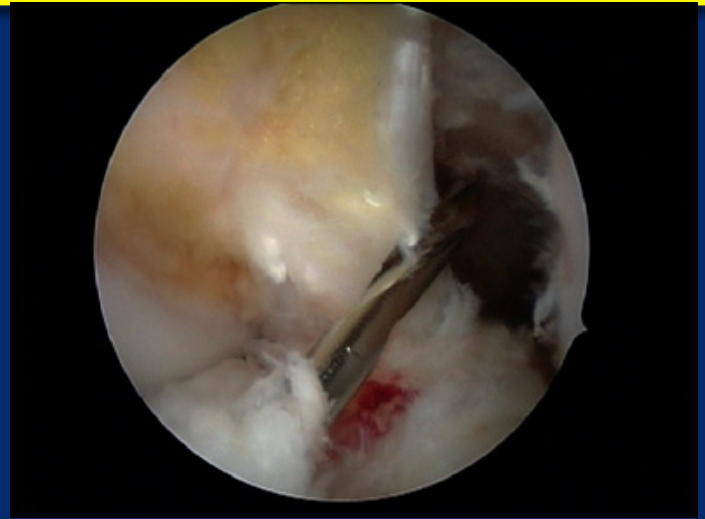
✓ Risks

- ✓ Damage tibial tunnel : the trick



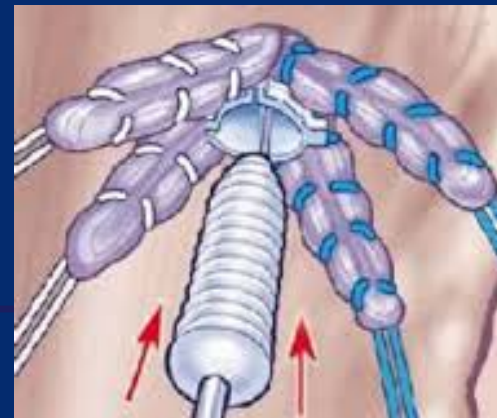
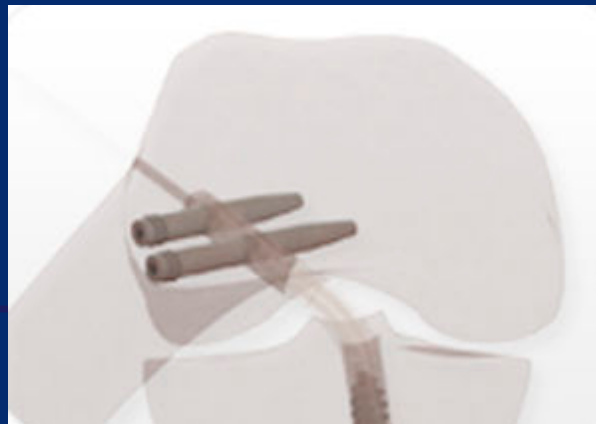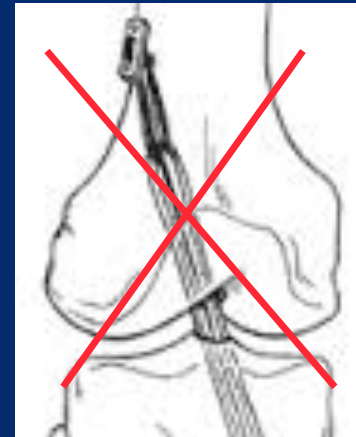
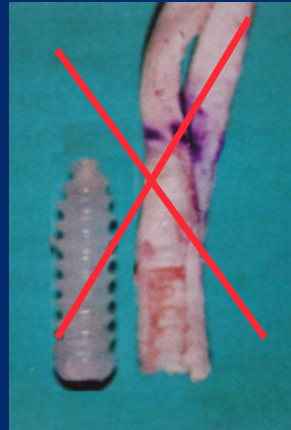
To reach the good spot

- ✓ 6mm @ tibia
- ✓ Pivoting femoral guide



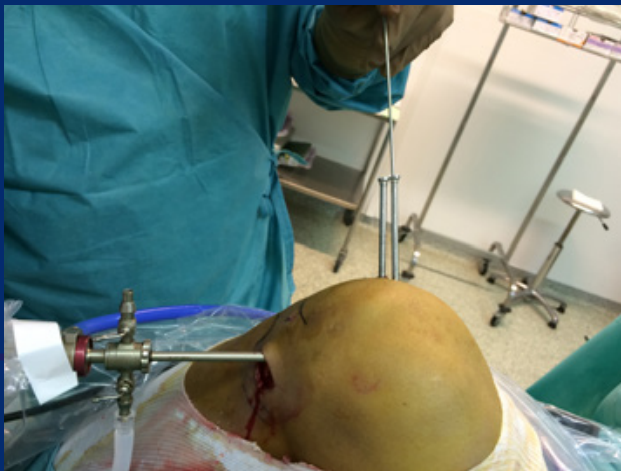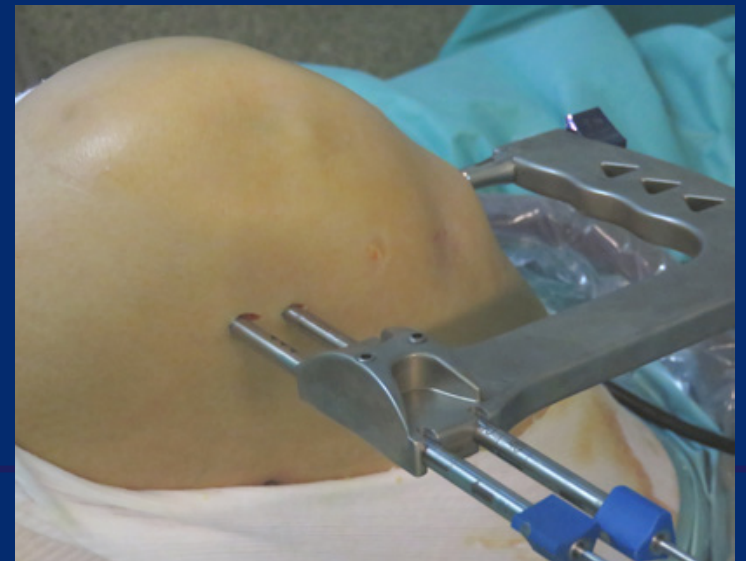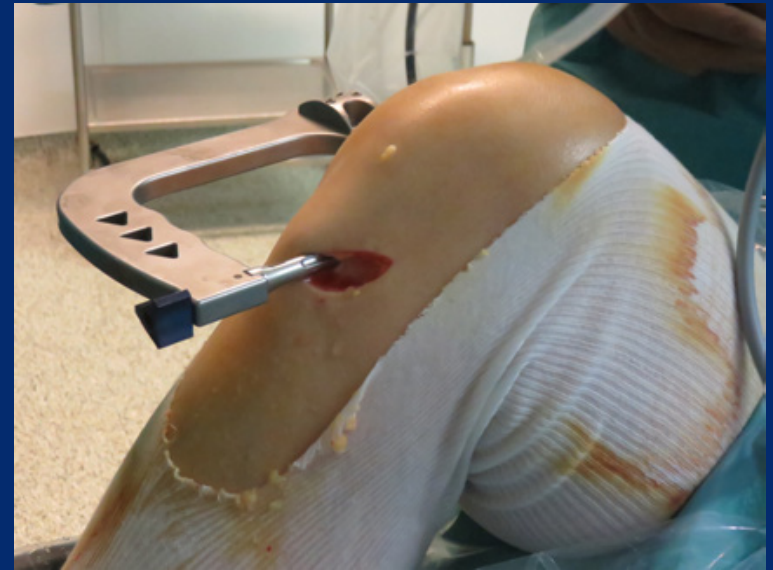Fixation for Hamstring

- ✓ Keep intact peripheral contact
- ✓ Stabilize close the cartilage

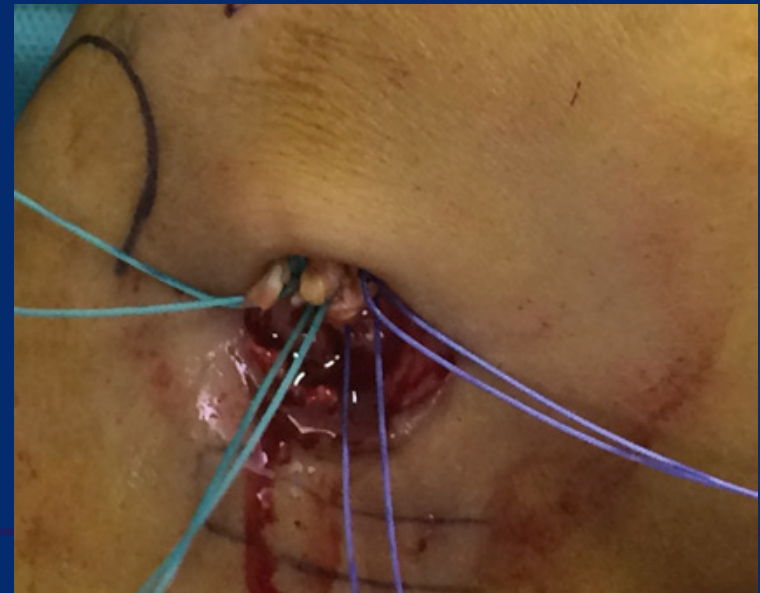
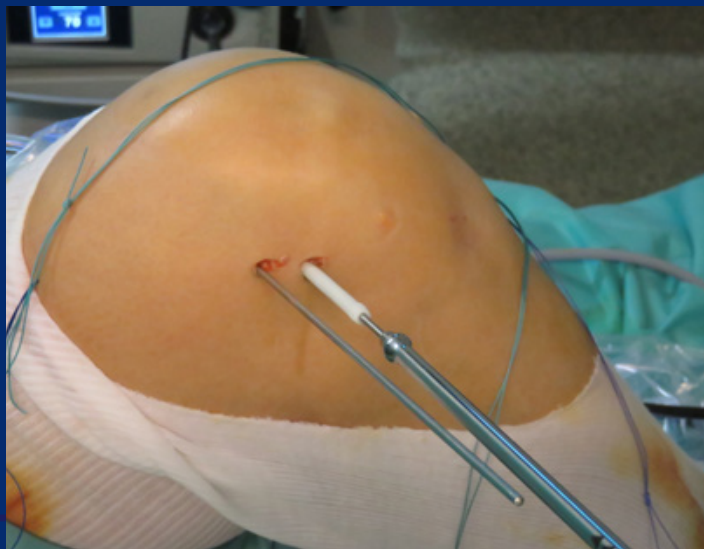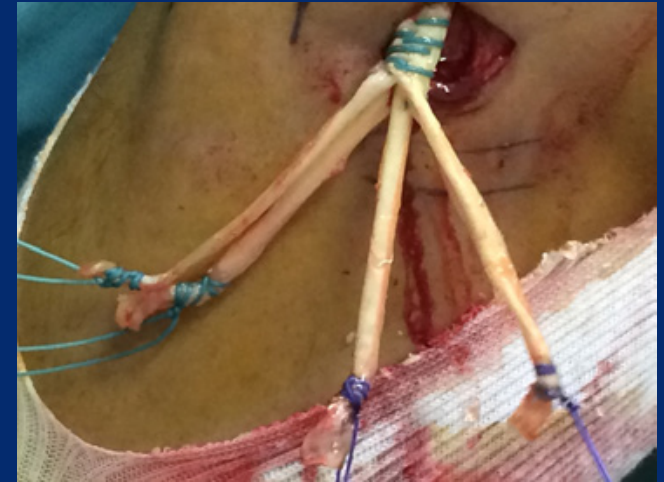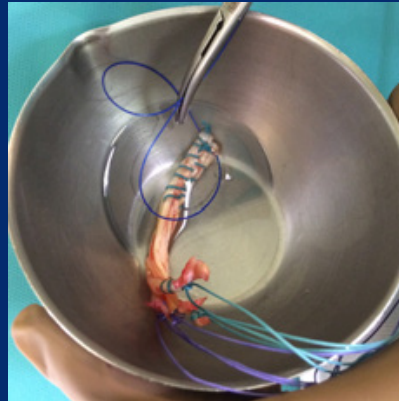
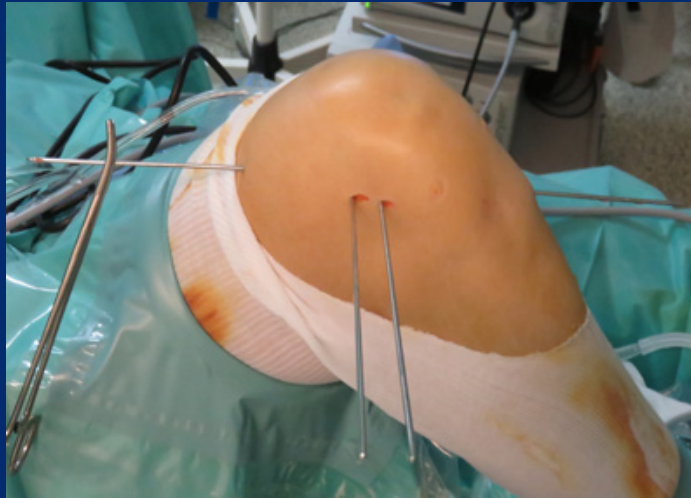


Femoral fixation

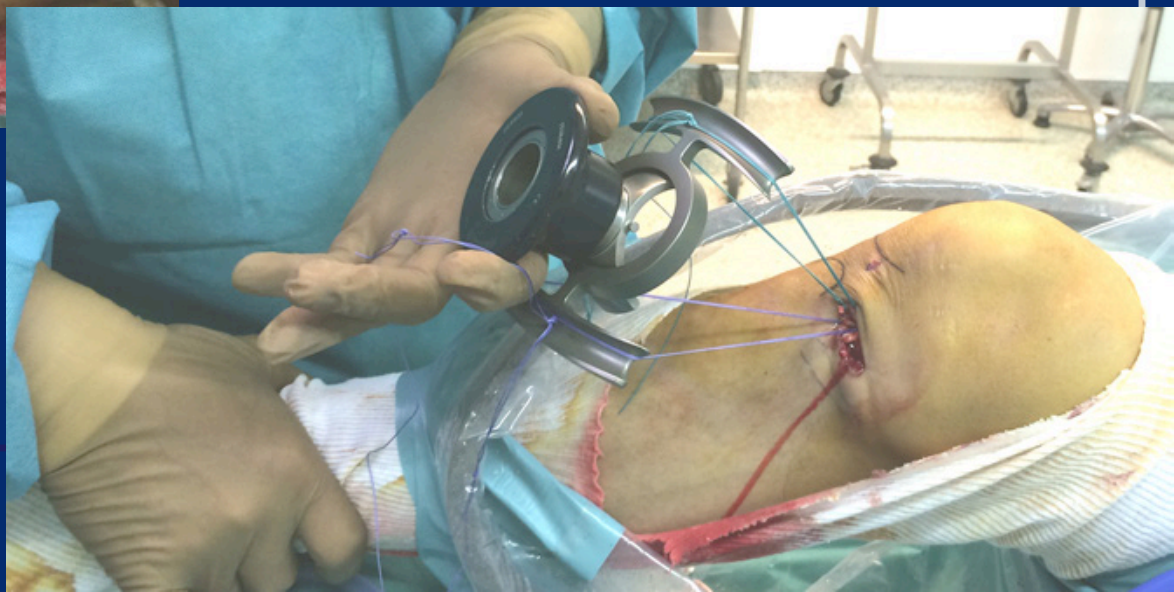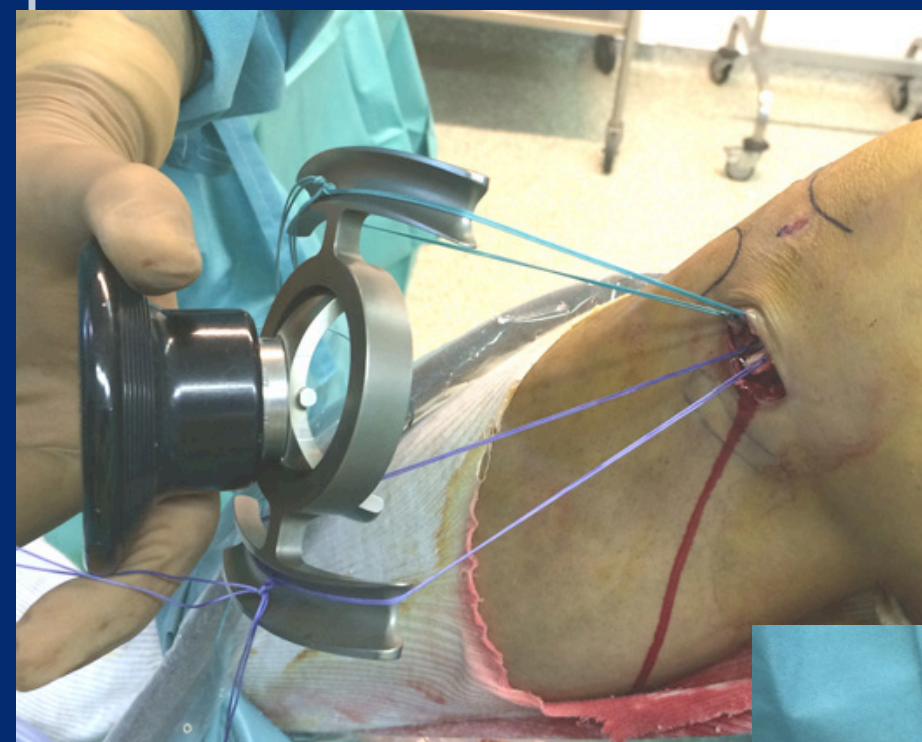- ✓ Transtibial guide
- ✓ Transcondylar pin guide
- ✓ Intra articular check



Transplant insertion & fixation



Cycling



Tibial fixation

