



# Antwerp Orthopaedic Center knee department



## FastFix Ultra and 360

For Meniscus Allograft Transplantation and Scaffold Implantation

Peter Verdonk MD, PhD

[pverdonk@yahoo.com](mailto:pverdonk@yahoo.com)

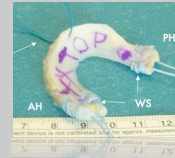
© Peter Verdonk

if you cannot save it, then think about replacing it...

## Meniscus Substitution Options in postmeniscectomy syndrome



20 years




meniscus allograft

5 years



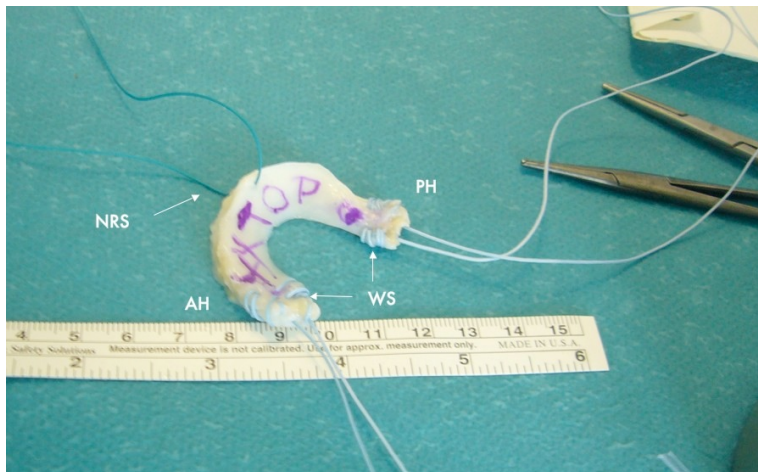
meniscus scaffold

2 year

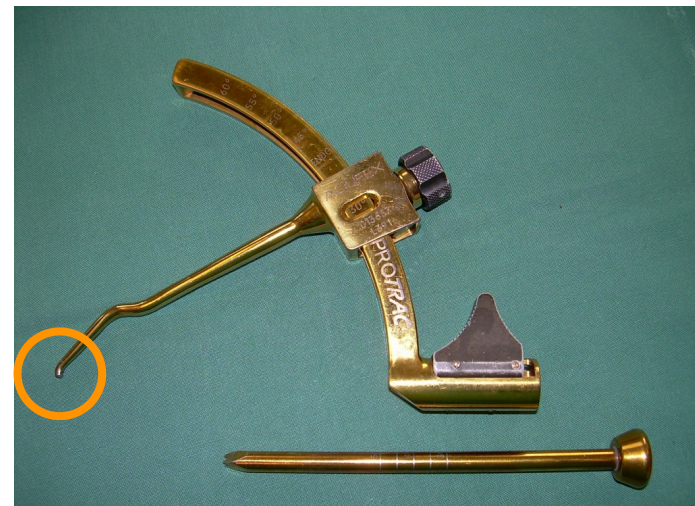


meniscus implant

## Meniscus Allograft Preparation

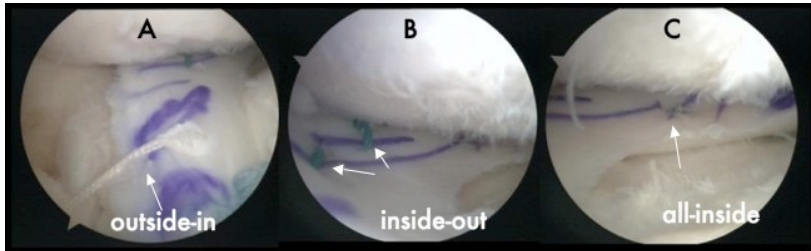


## Aiming Device: Low Profile Tip



## Suture Types

---



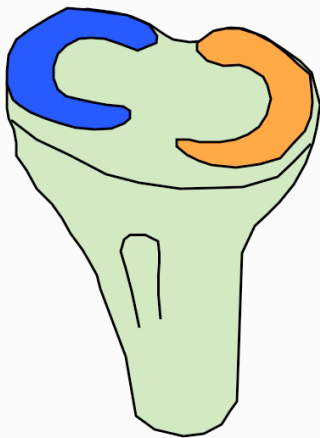
## Repair Techniques

---

### All Inside

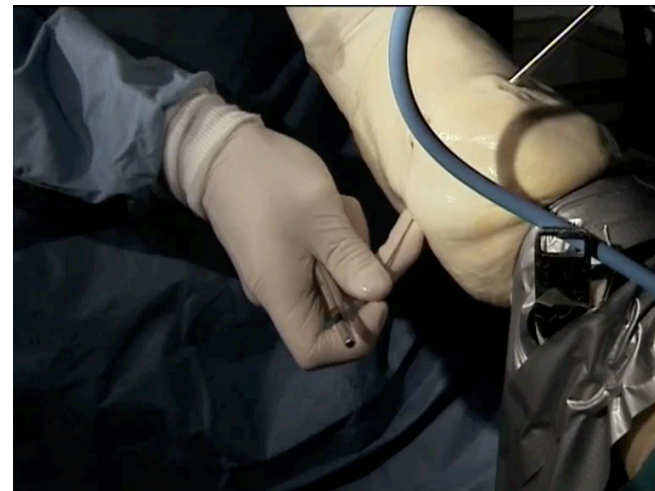

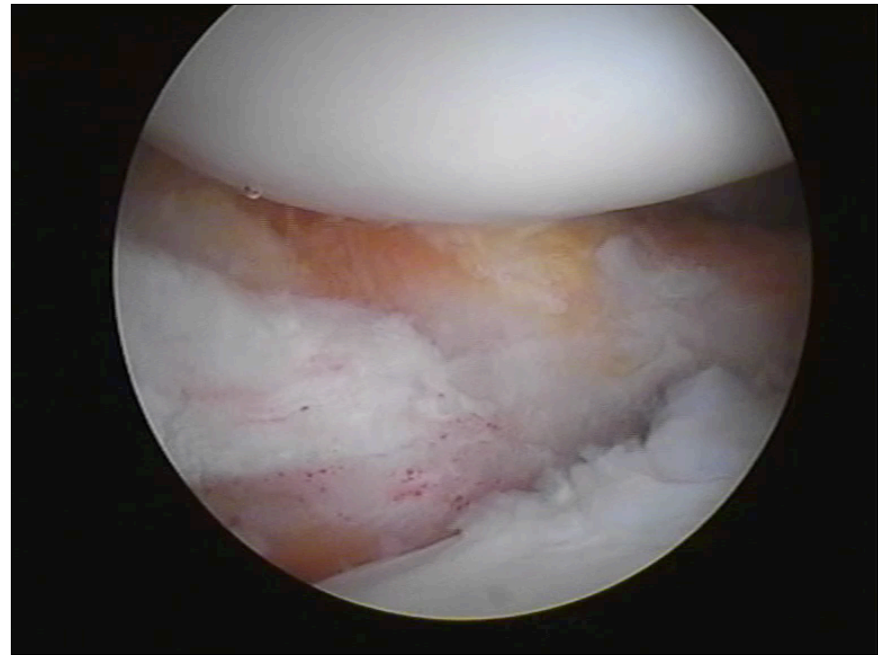
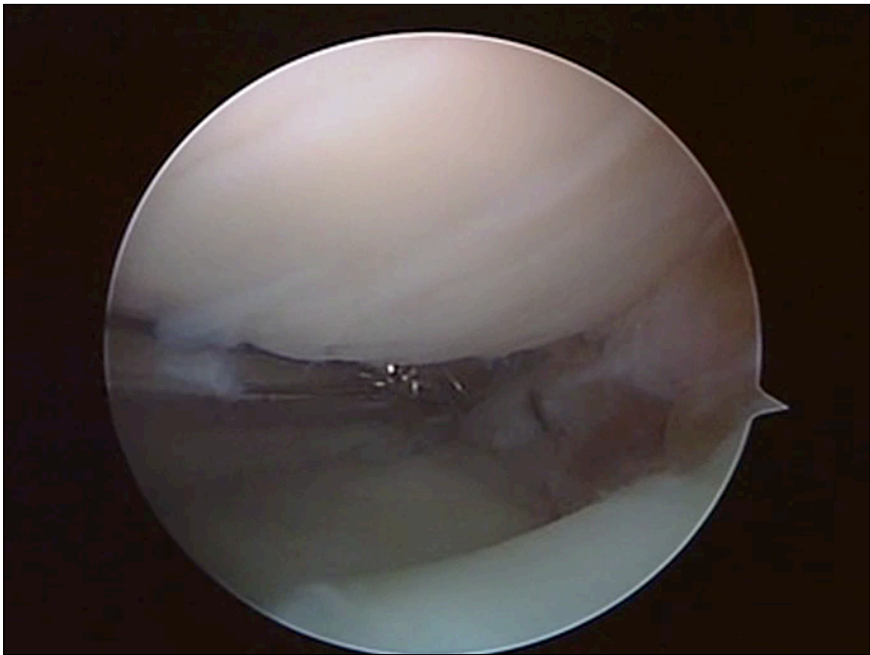
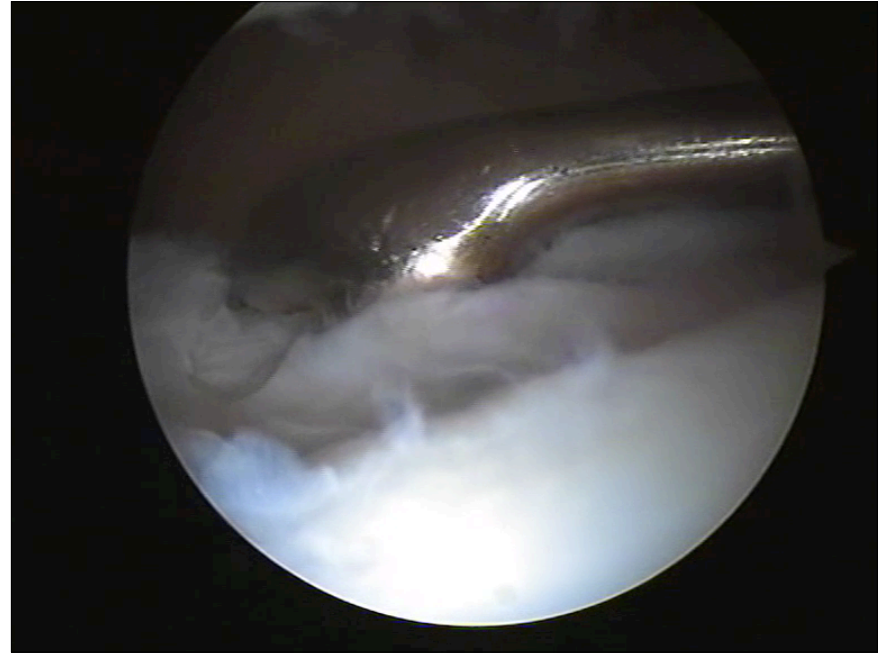
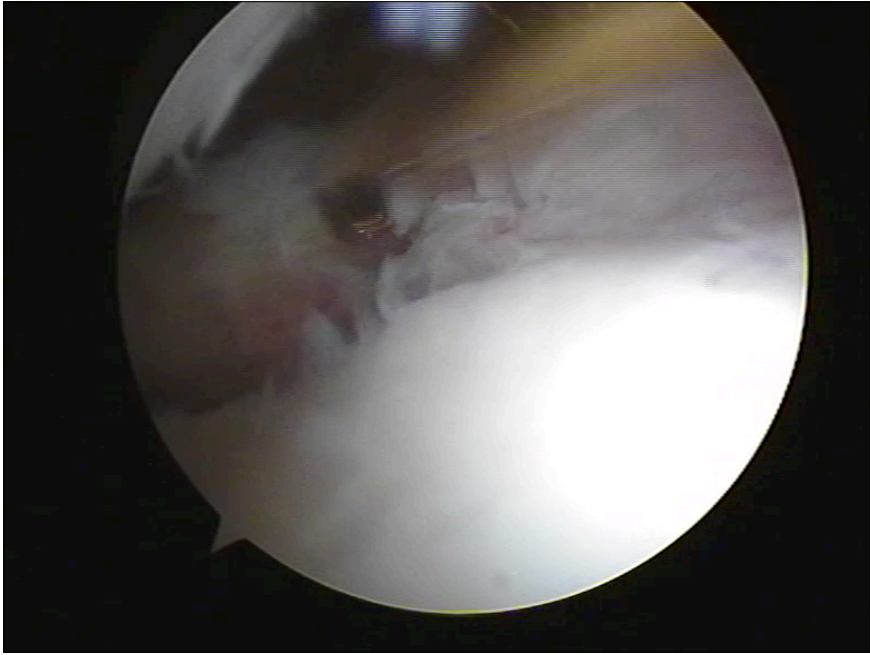
I only use the curved one...

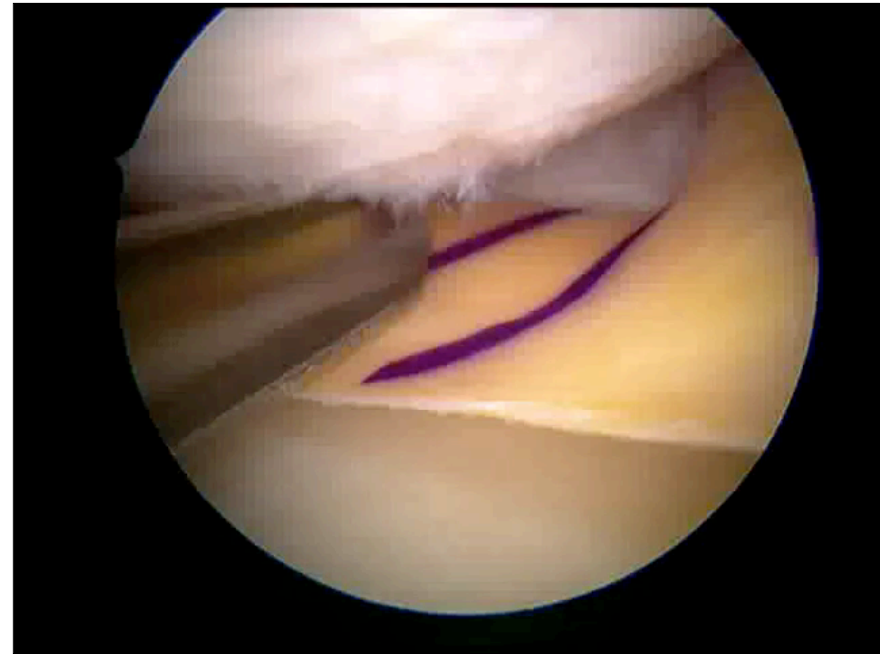
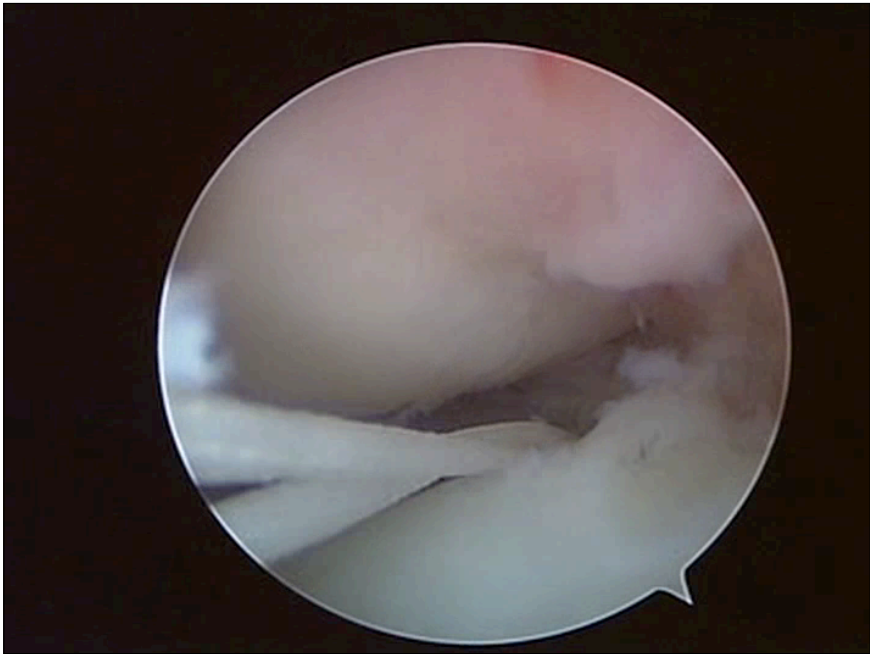
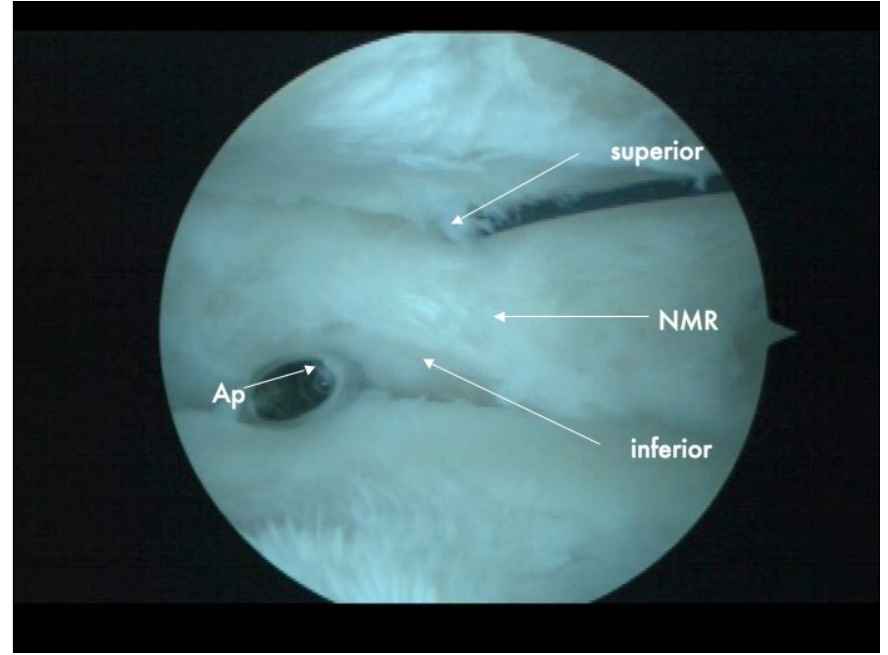
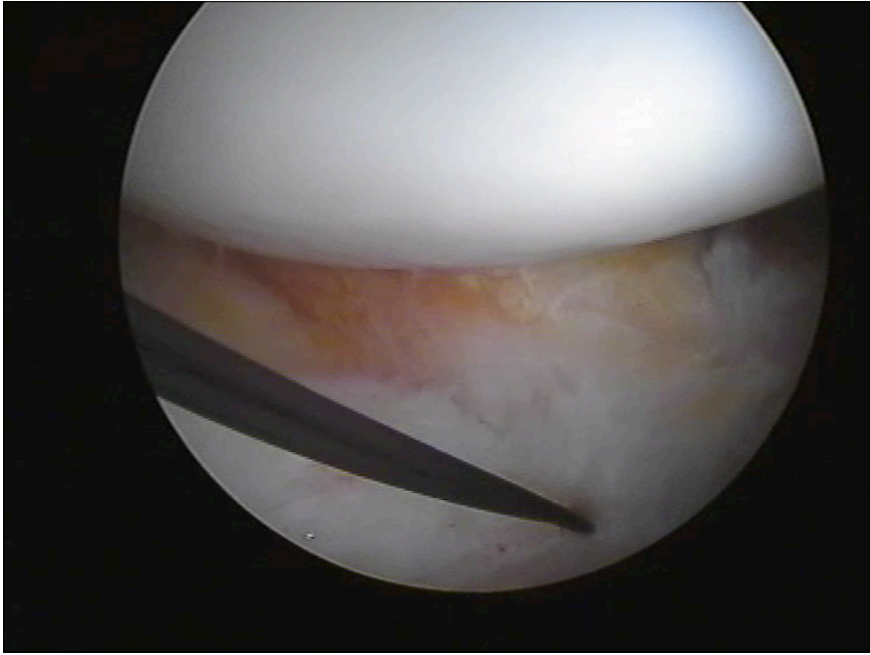


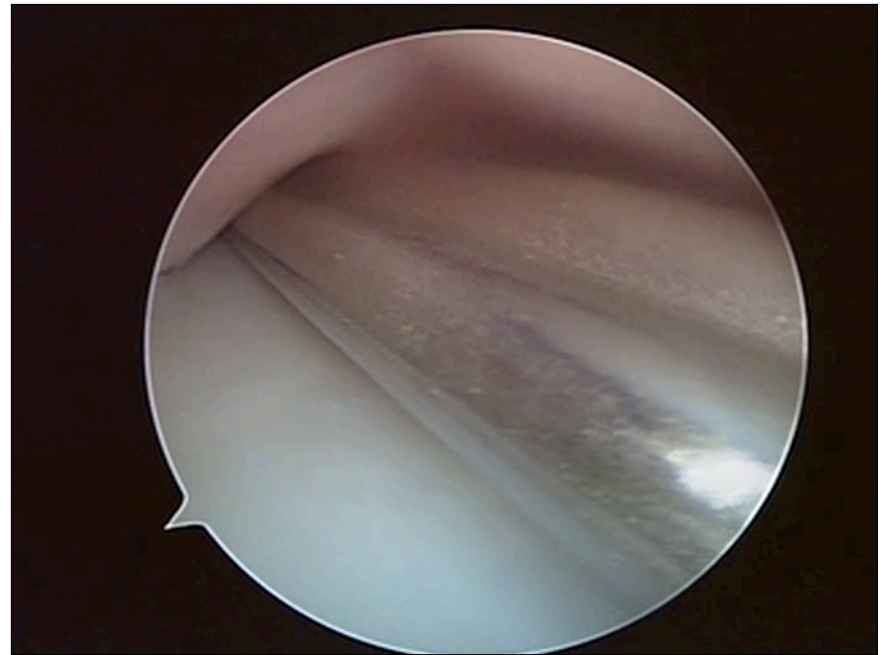
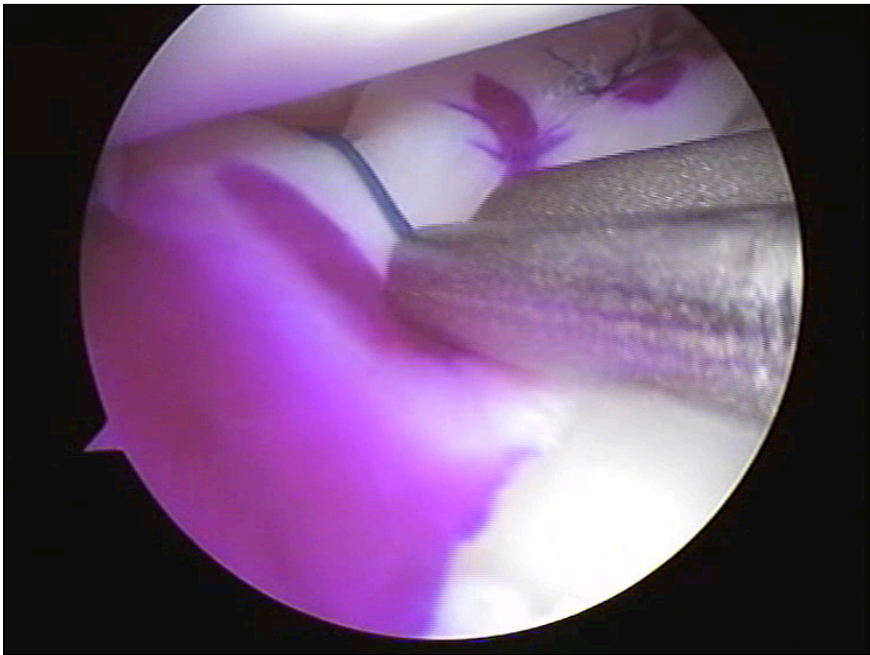
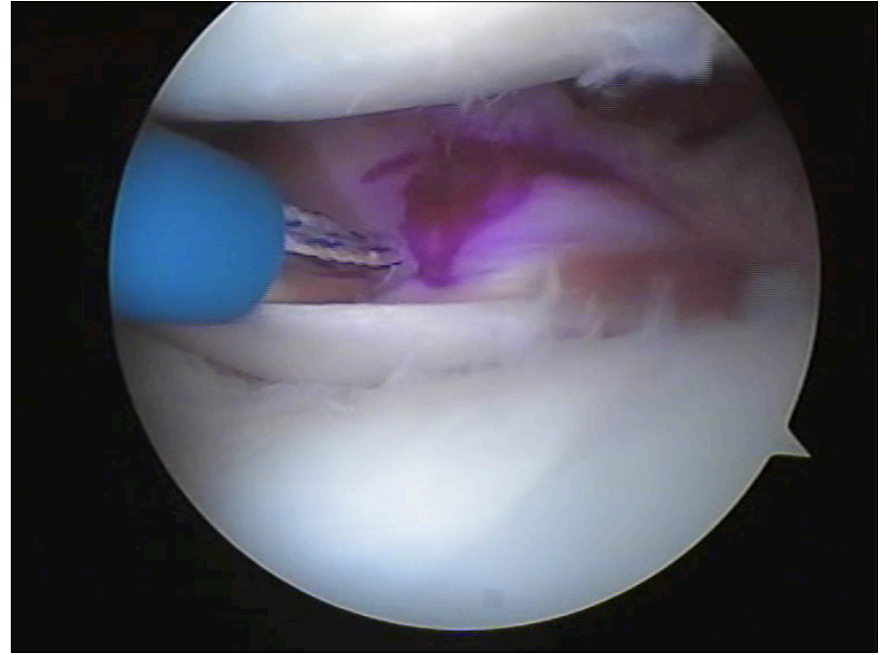
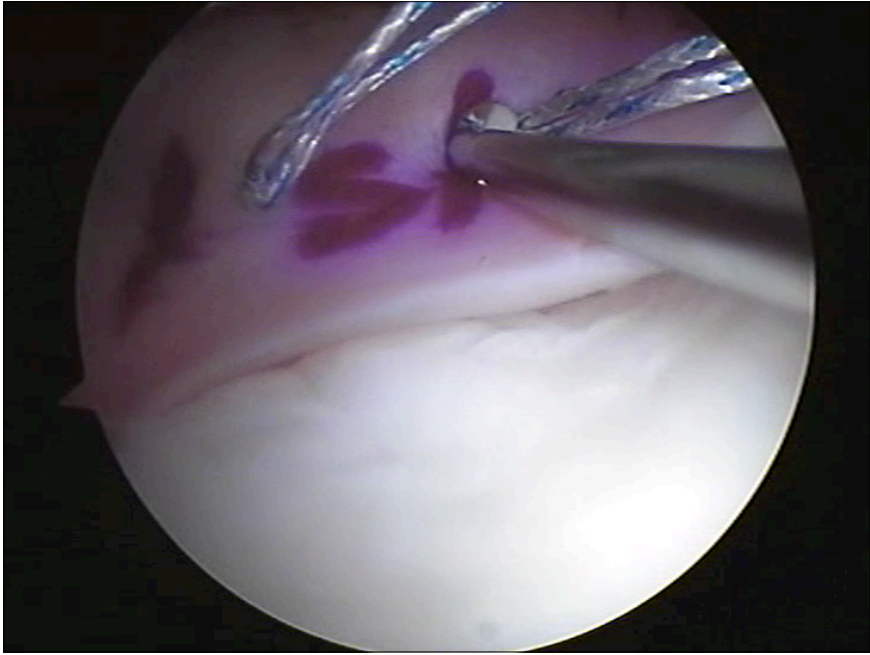
## Opening up of tight medial compartment

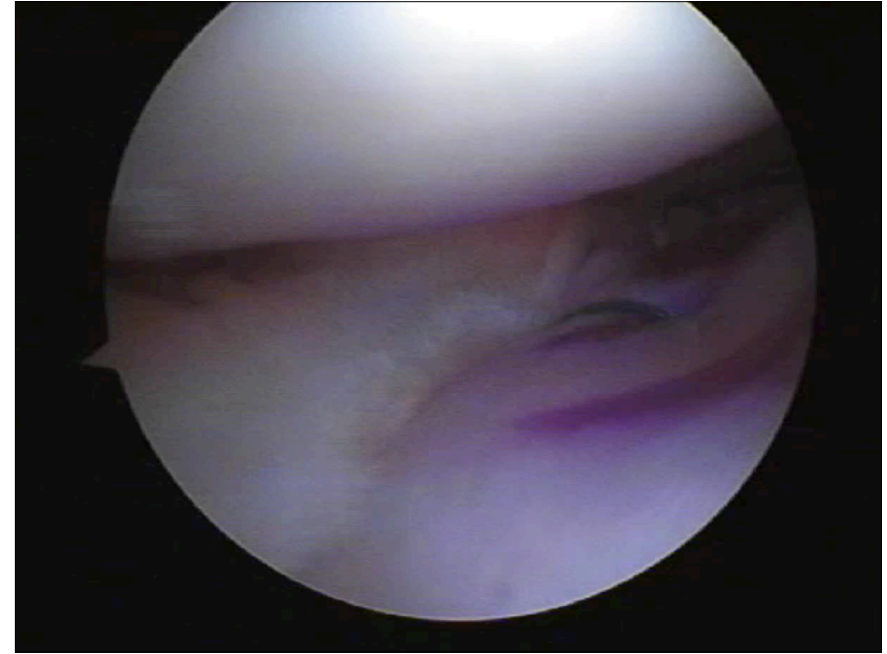
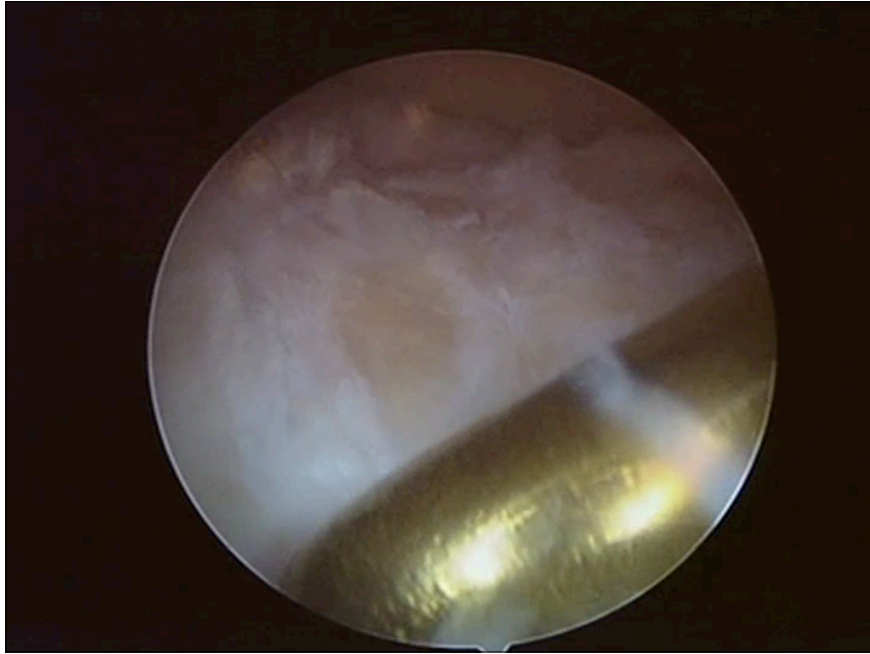
---











## Conclusion

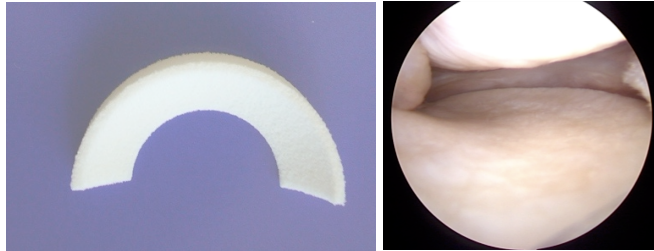
---

*Meniscus Allograft Transplantation should no longer be considered experimental*

## Conclusion

---

*MAT works best in young patients with limited cartilage wear!*

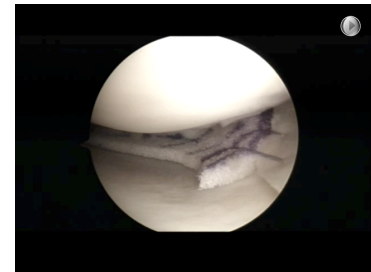
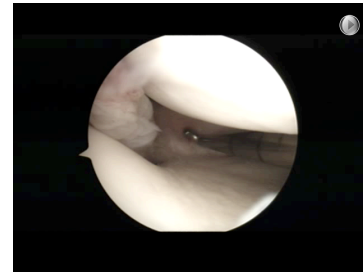


## Acellular Meniscus Scaffolds Implantation for partial defects

[www.verdonk.be](http://www.verdonk.be)

## Typical Indication

- Remaining pain after extensive partial meniscectomy (3-7cm)
- Meniscus rim and horns intact
- Cartilage in good shape (max ICRS grade 3)
- Stable and well-aligned knee

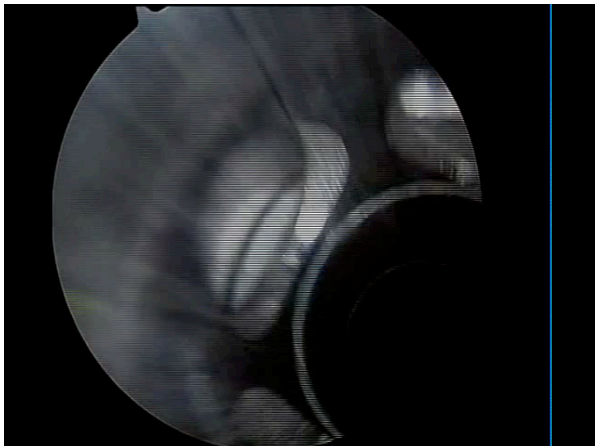


[pverdonk@yahoo.com](mailto:pverdonk@yahoo.com)

[www.knee.be](http://www.knee.be)

## Tips and Tricks

- Make sure the tendon popliteus rim is intact!



27

## Use horizontal sutures



TRIANGLE



SQUARE

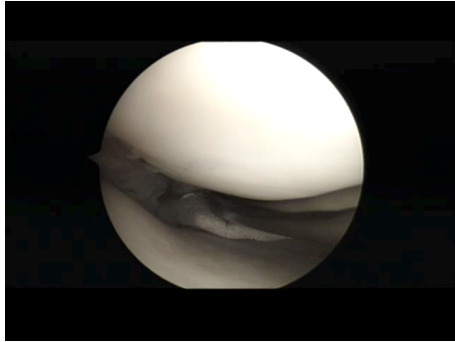


Since scaffold is the weaker link:  
Amount of tissue included in  
sutures is most important factor!

F Hardeman, K Corten, P Verdonk, R Verdonk, J Bellemans. ESSKA 2012


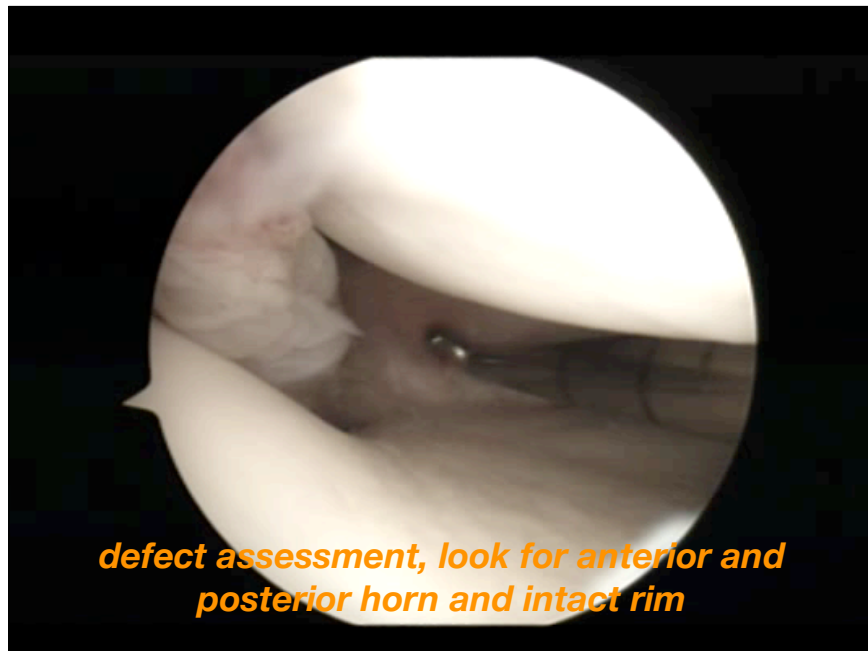
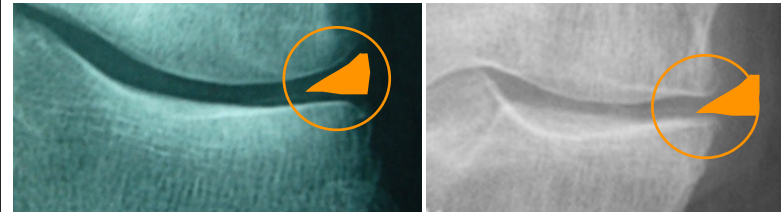
## Tips and Tricks

- Use Horizontal sutures!
- Do not overtighten the sutures

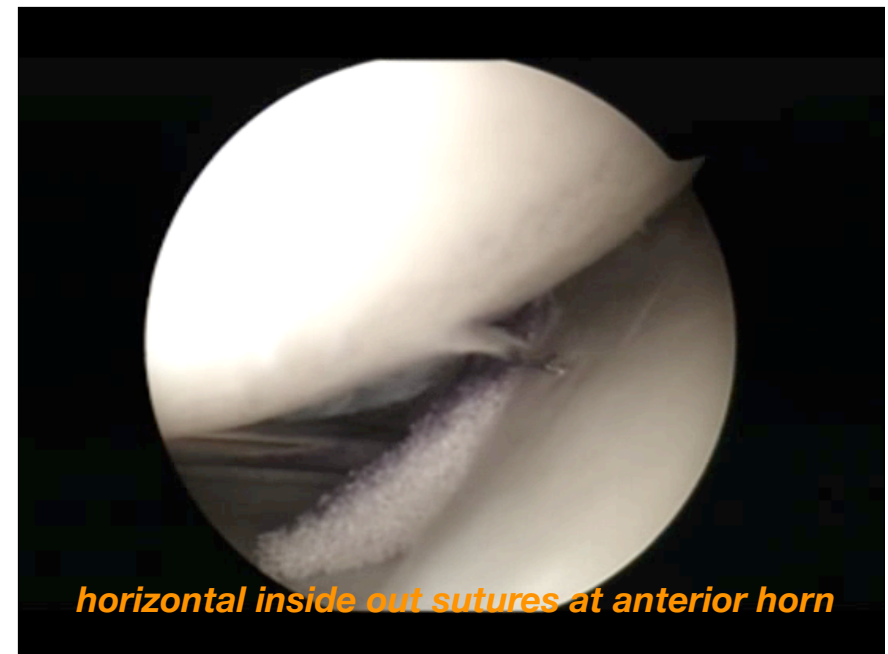
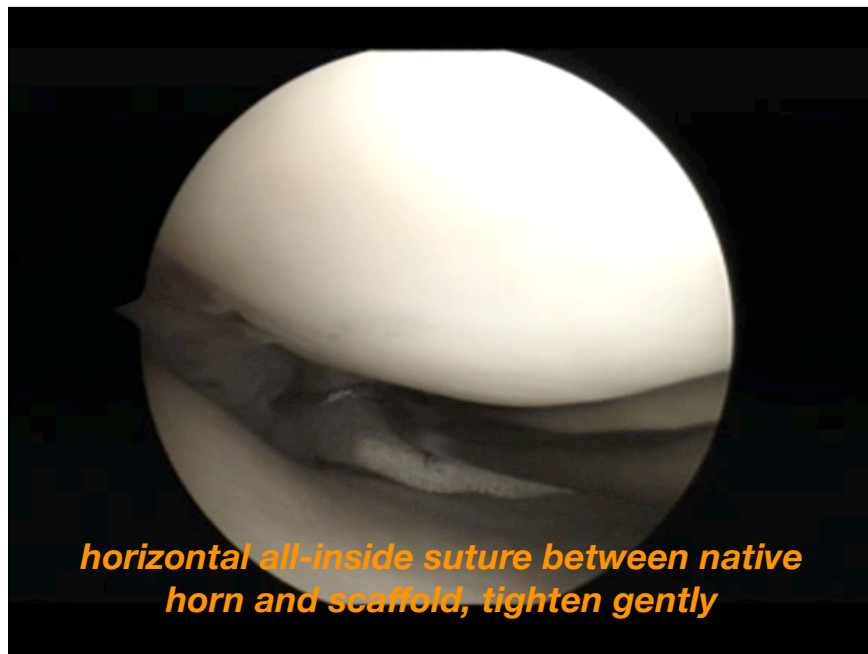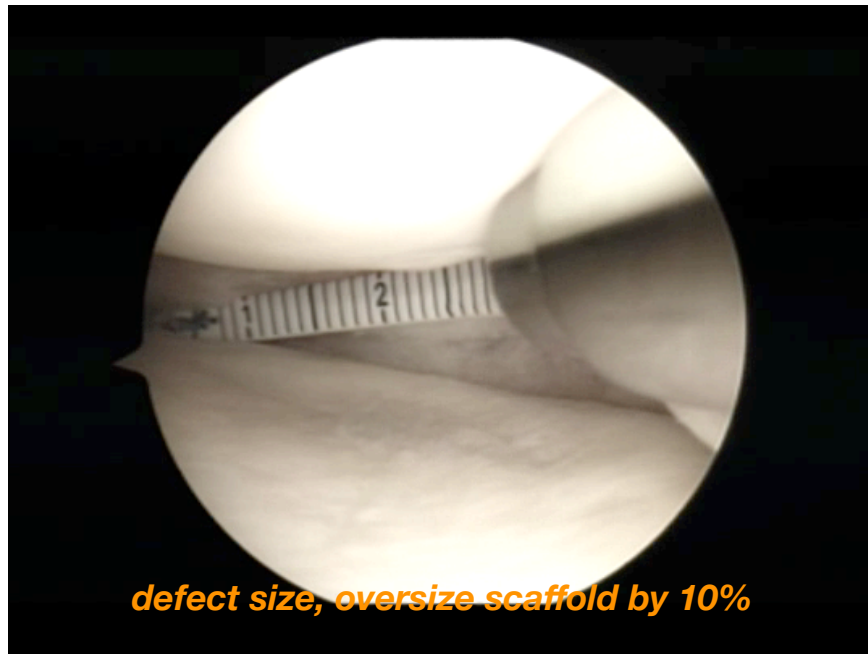


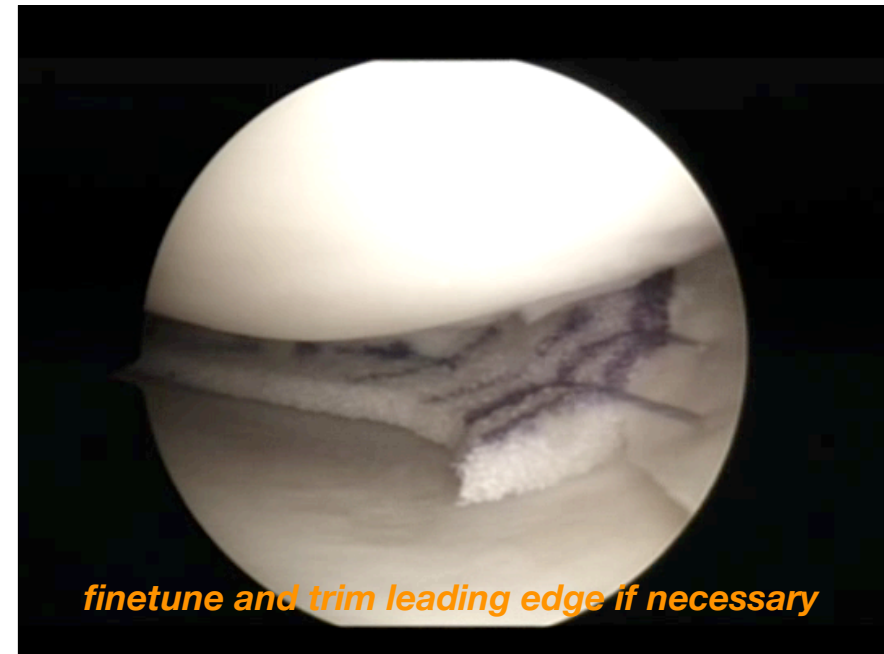
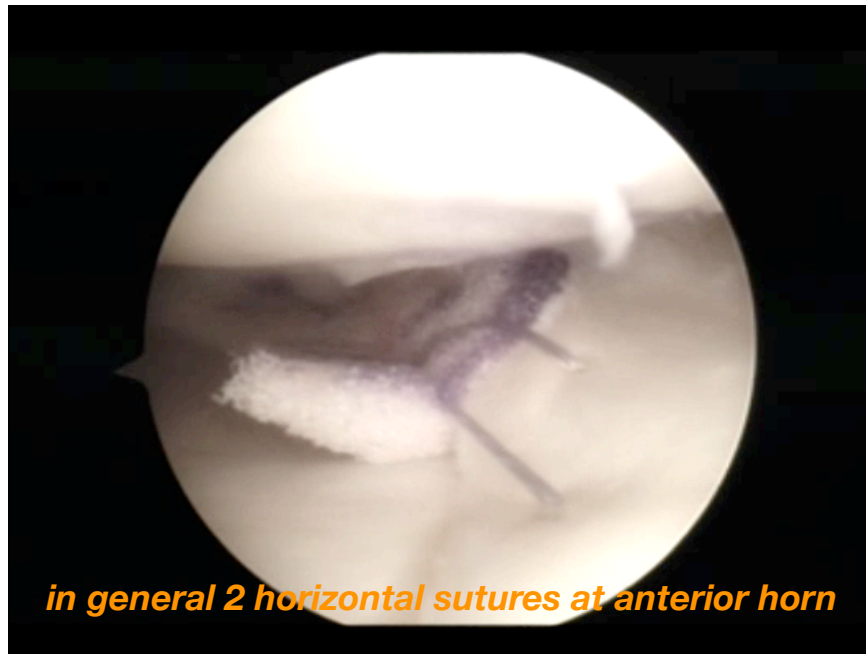
## Tips and Tricks

- Femoral condyle squaring is exclusion!





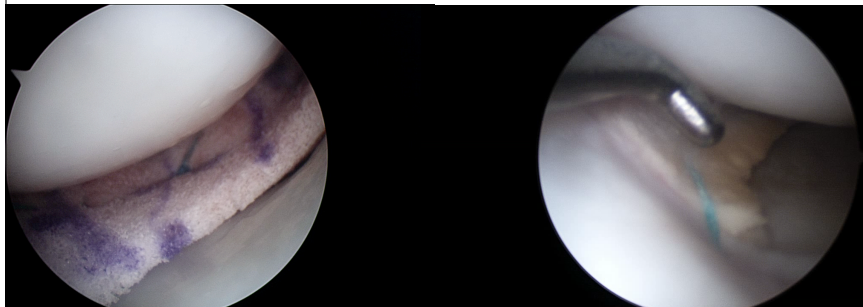




## Bone Marrow Cells

- easily accessible, cheap

*Clinical application*



BM application on polyurethane scaffold

Relook at 12 months

## Closing remarks

When you are confronted with a painful meniscectomy, consider meniscus replacement instead of a redo meniscectomy...

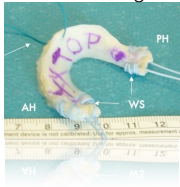
Take home message

---

**prevent cartilage degeneration...  
SAVE THE MENISCUS !!!**

- meniscus solutions are expanding

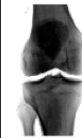
meniscus allograft



meniscus scaffold



meniscus implant



**Antwerp Orthopaedic Center**  
**knee department**



FastFix Ultra and 360 for expanded indications

---

For Meniscus Allograft Transplantation and Scaffold Implantation

Peter Verdonk MD, PhD

[pverdonk@yahoo.com](mailto:pverdonk@yahoo.com)

© Peter Verdonk