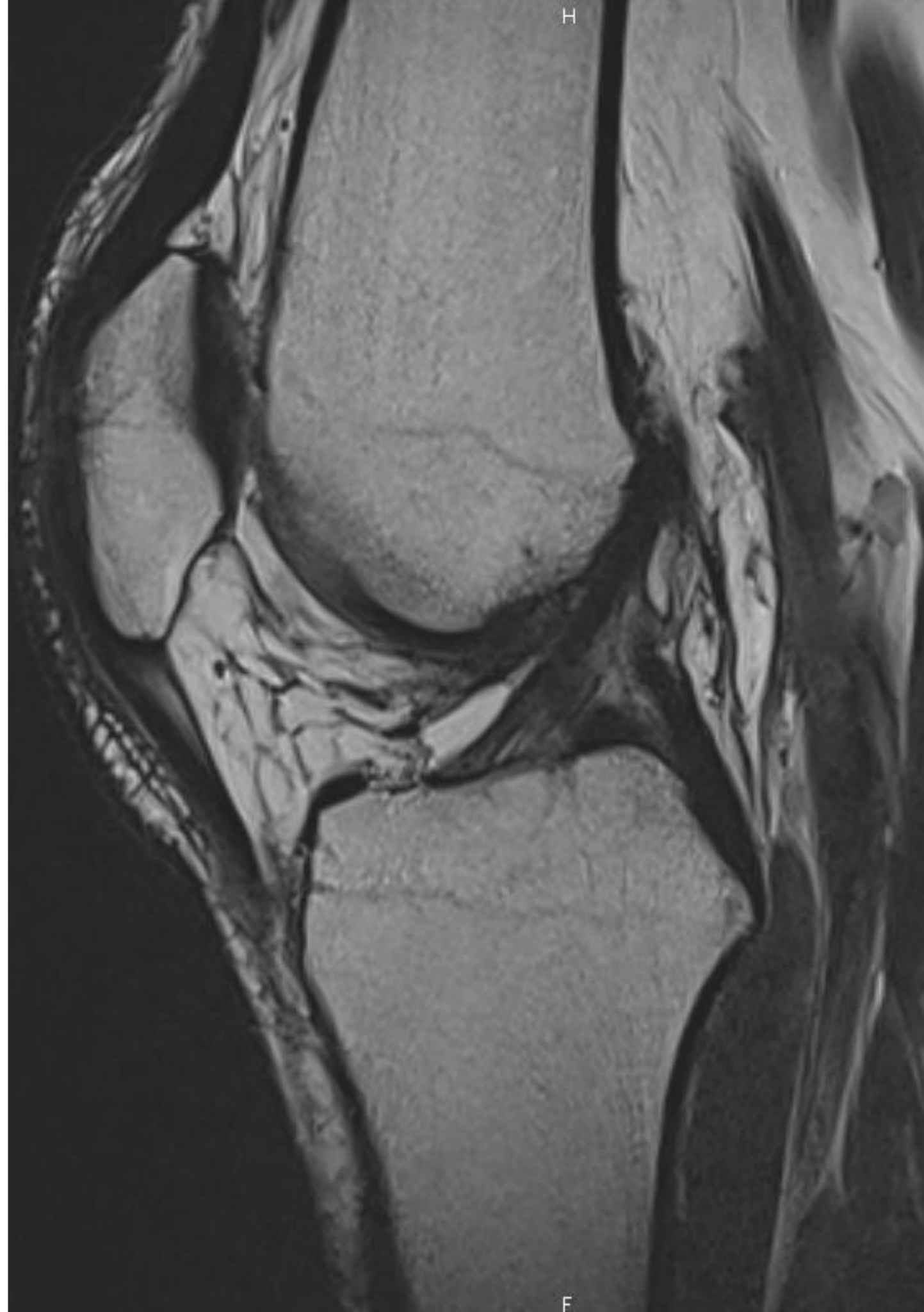


# IMAGERIE DU GENOU

Florent GARRIGUES  
Radiologie ostéo-articulaire  
CHRU BREST



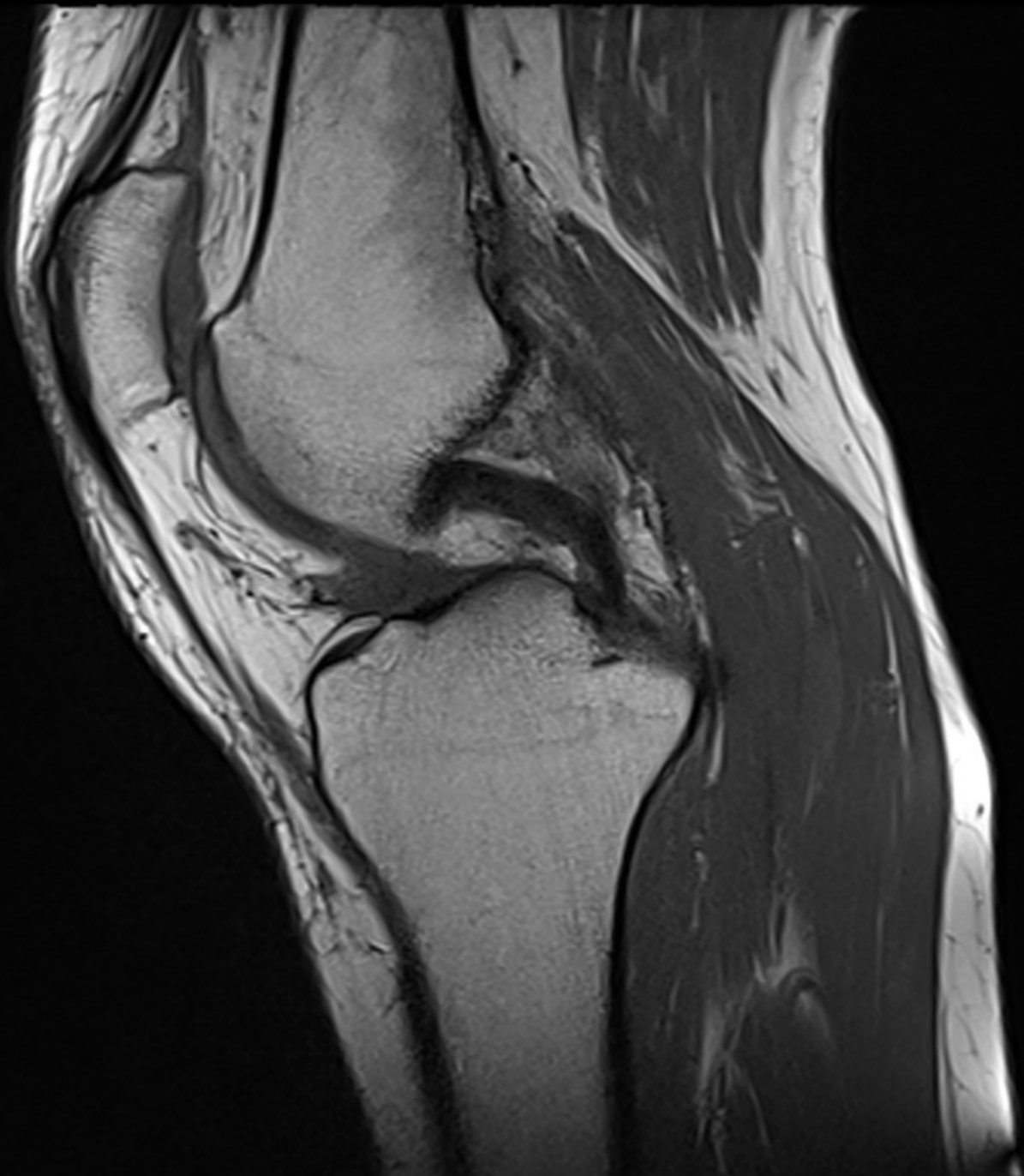# Bilan IRM du GENOU

---

1. Technique IRM
2. Lésions du pivot central
3. Ligaments collatéraux et points d'angle
4. Lésions méniscales
5. Lésions ostéochondrales
6. Autres techniques : ECHO, ARTHRO-TDM et ARTHRO-IRM

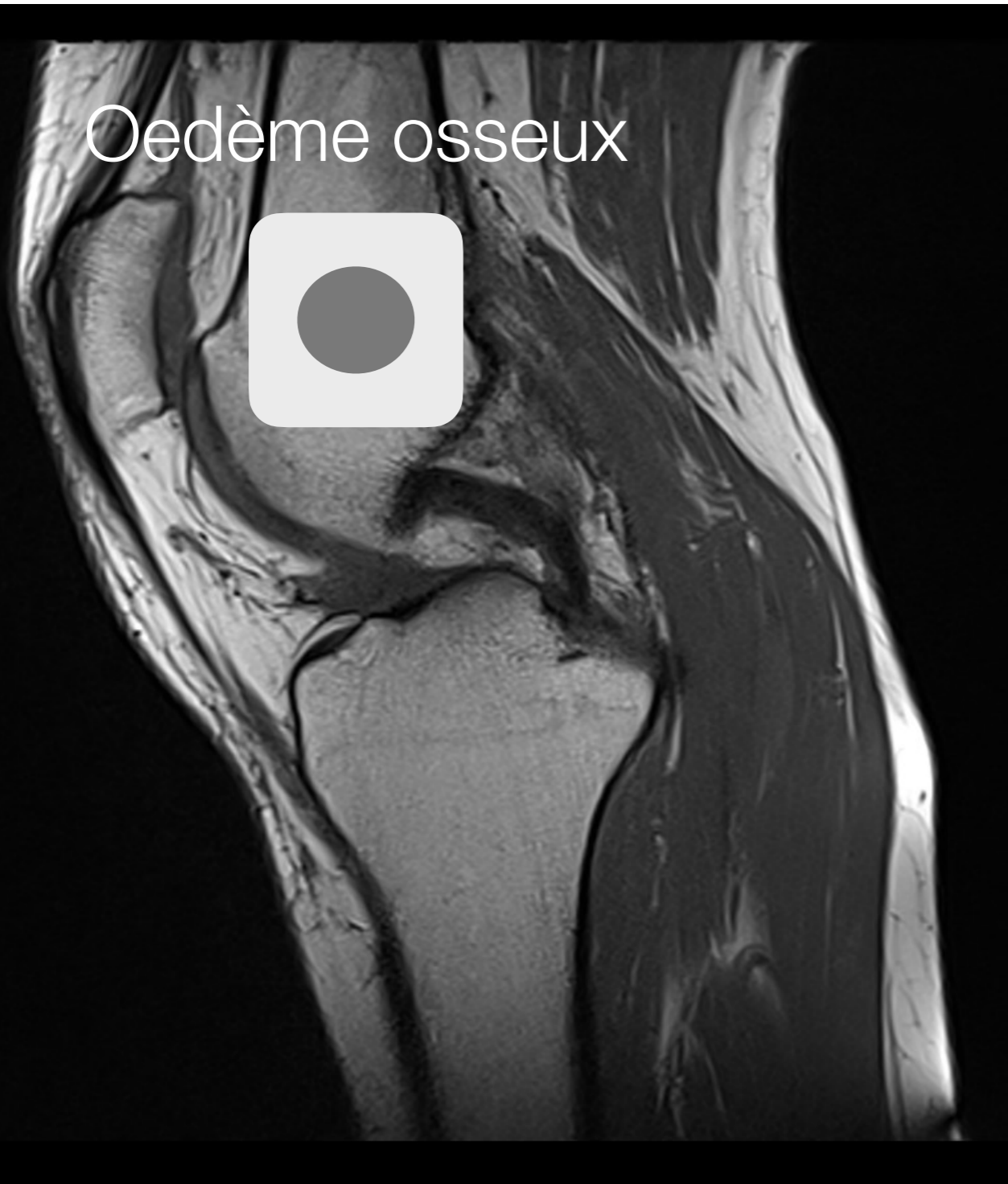# 1. IRM

# 1. Pondération T1 en 2D



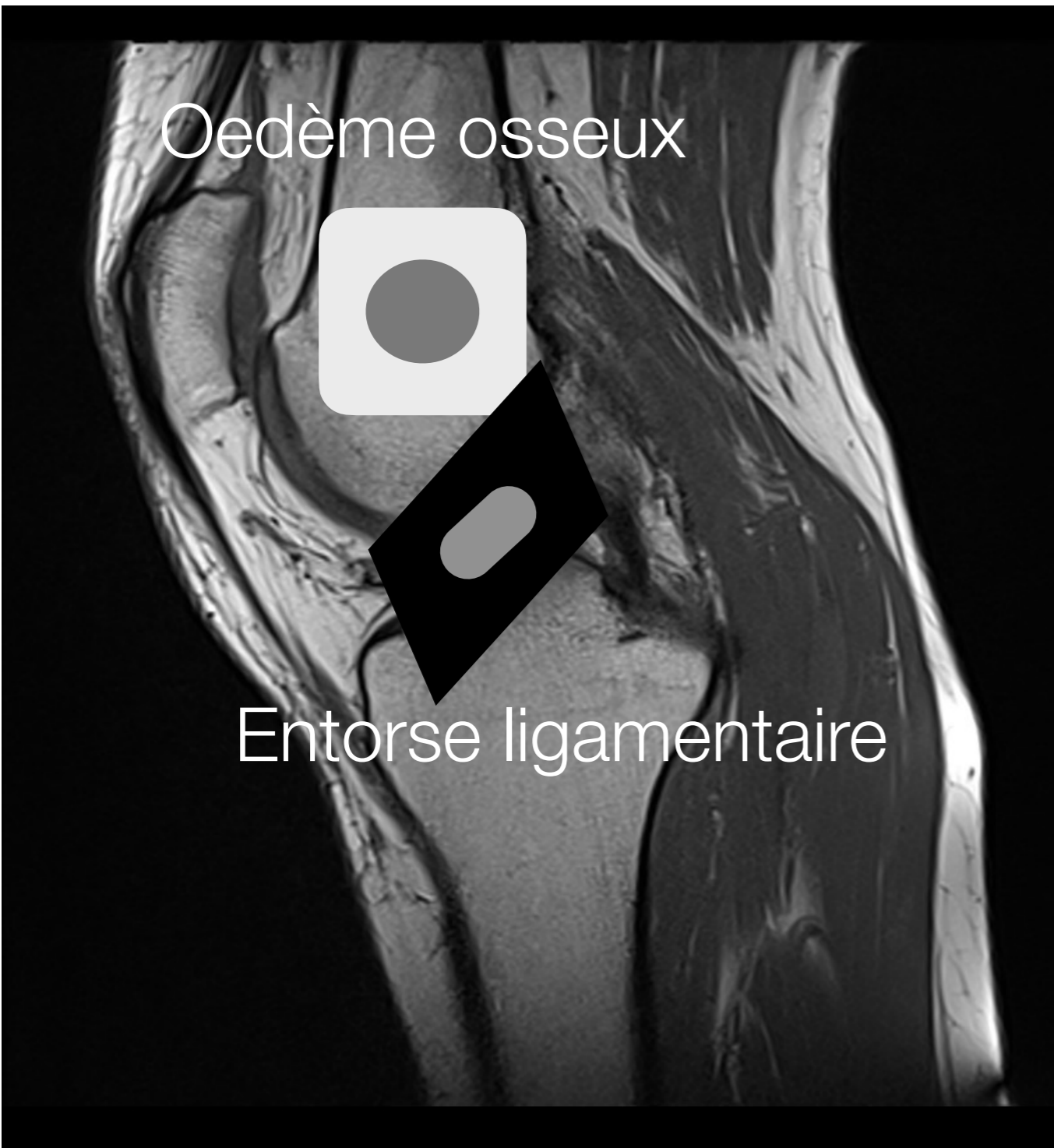T1	
ISO SIGNAL	Muscle
HYPER signal = BLANC	GRAISSE Hématome récent
HYPO = GRIS	LIQUIDE OEDEME Cartilage
ASIGNAL = NOIR	MENISQUE LIGAMENT TENDON CORTICALE CALCIF FASCIA

# 1. Pondération T1 en 2D



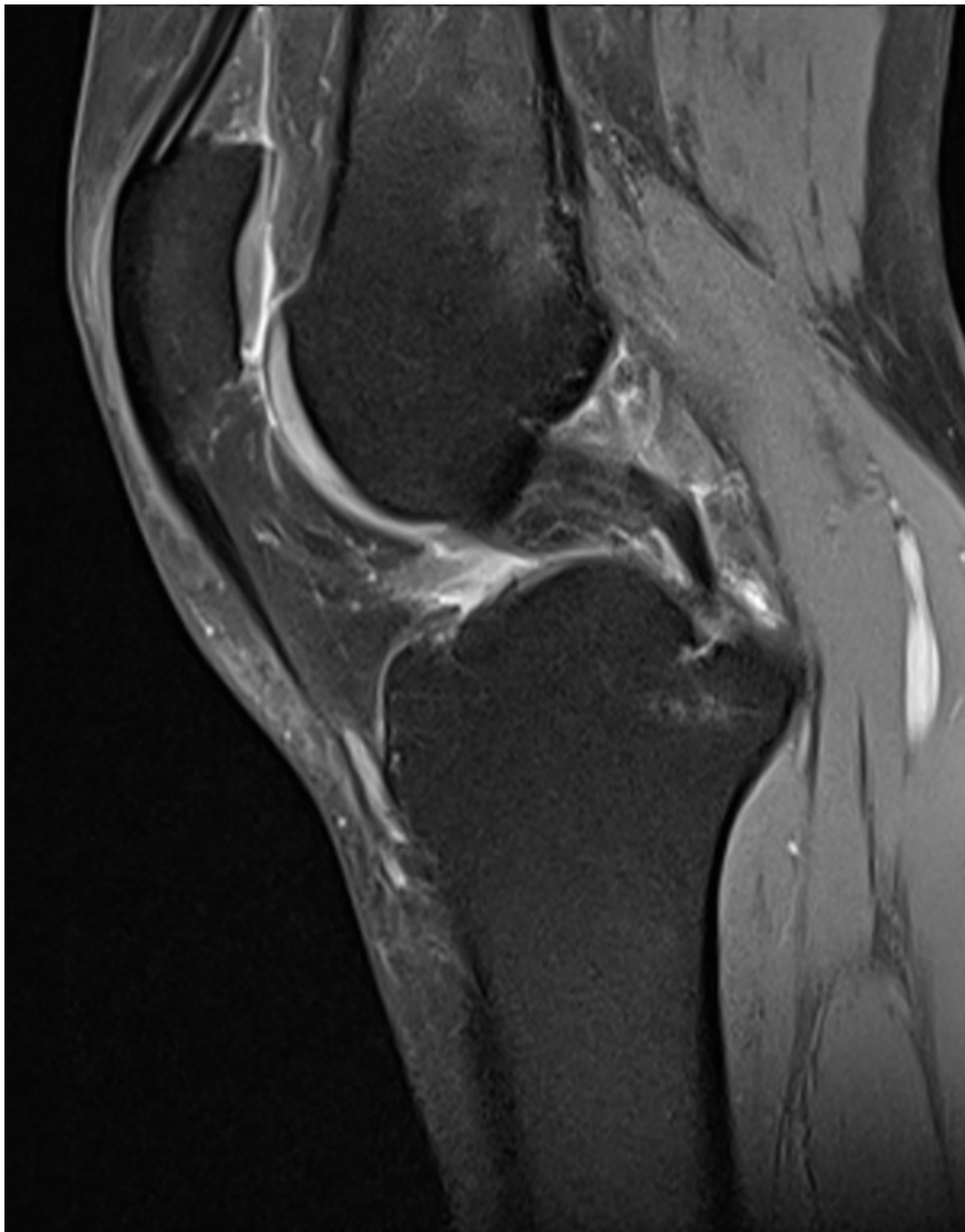
T1	
ISO SIGNAL	Muscle
HYPER signal = BLANC	GRAISSE Hématome récent
HYPO = GRIS	LIQUIDE OEDEME Cartilage
ASIGNAL = NOIR	MENISQUE LIGAMENT TENDON CORTICALE CALCIF FASCIA

# 1. Pondération T1 en 2D



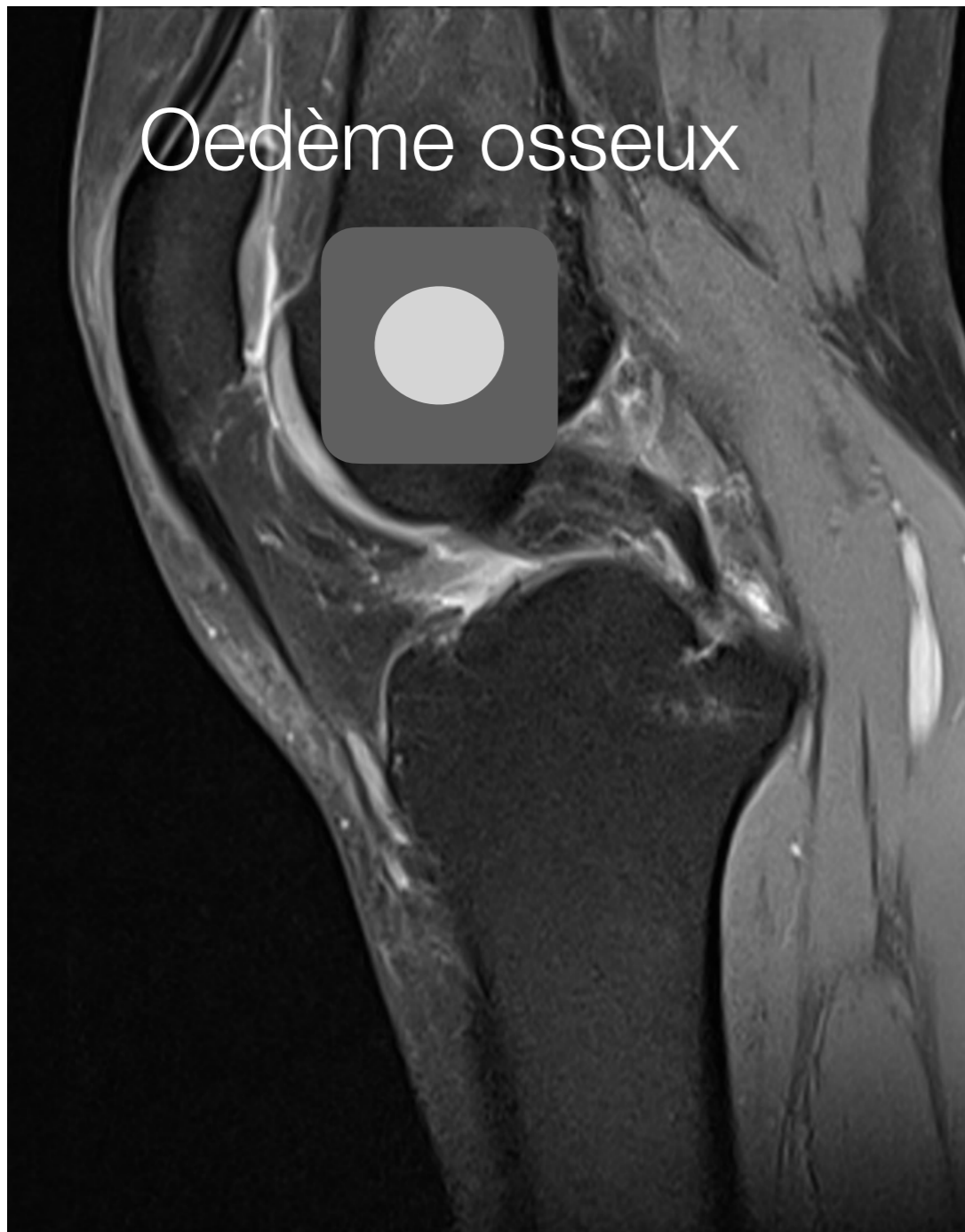T1	
ISO SIGNAL	Muscle
HYPER signal = BLANC	GRAISSE Hématome récent
HYPO = GRIS	LIQUIDE OEDEME Cartilage
ASIGNAL = NOIR	MENISQUE LIGAMENT TENDON CORTICALE CALCIF FASCIA

# 1. Pondération DP FS



DP FS	
ISO SIGNAL	Muscle
HYPER signal = BLANC	LIQUIDE OEDEME CARTILAGE
HYPO = GRIS	GRAISSE OS SPONGIEUX
ASIGNAL = NOIR	MENISQUE LIGAMENT TENDON CORTICALE CALCIF FASCIA

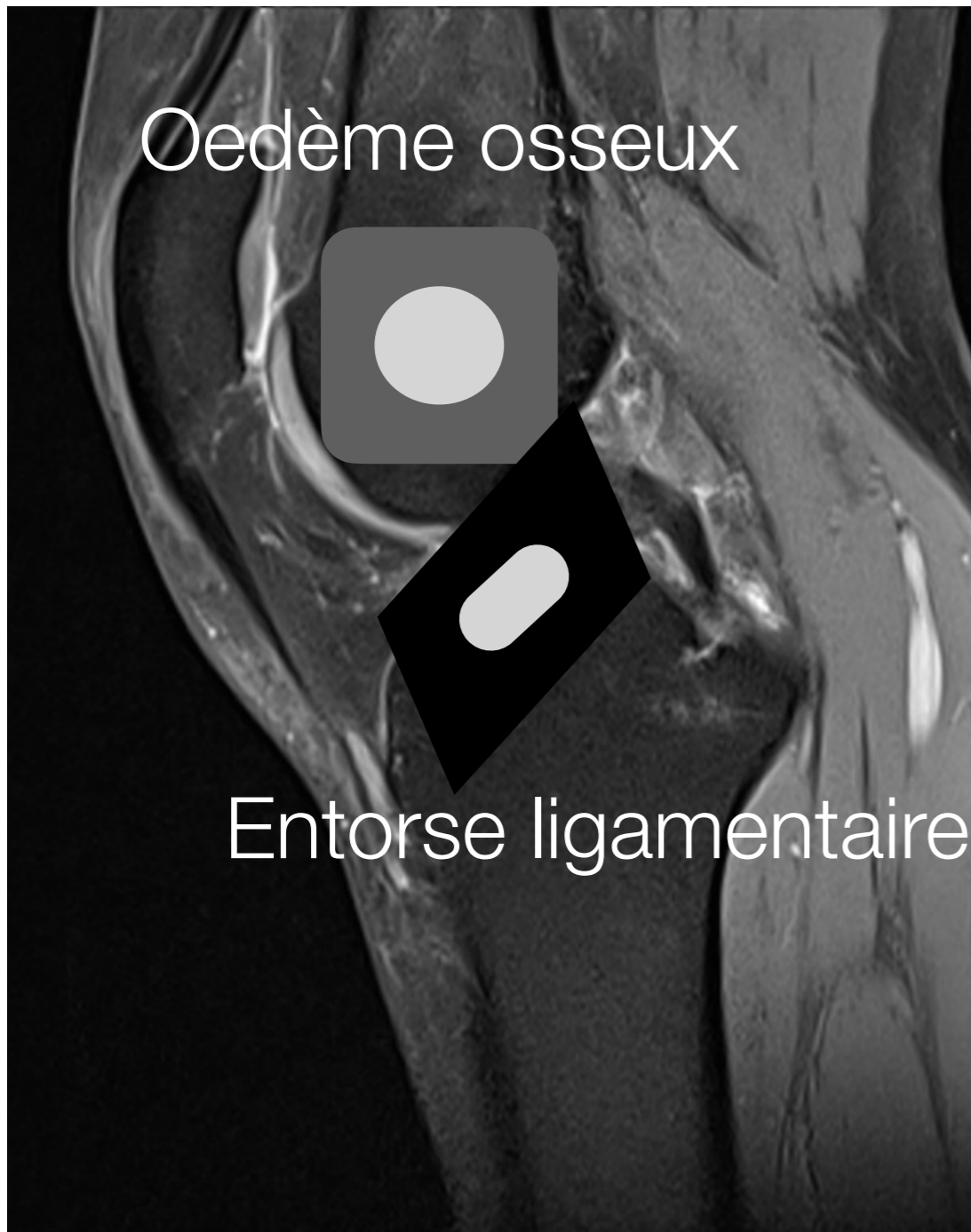
# 1. Pondération DP FS



DP FS	
ISO SIGNAL	Muscle
HYPERSIGNAL = BLANC	LIQUIDE OEDEME CARTILAGE
HYPO = GRIS	GRAISSE OS SPONGIEUX
ASIGNAL = NOIR	MENISQUE LIGAMENT TENDON CORTICALE CALCIF FASCIA

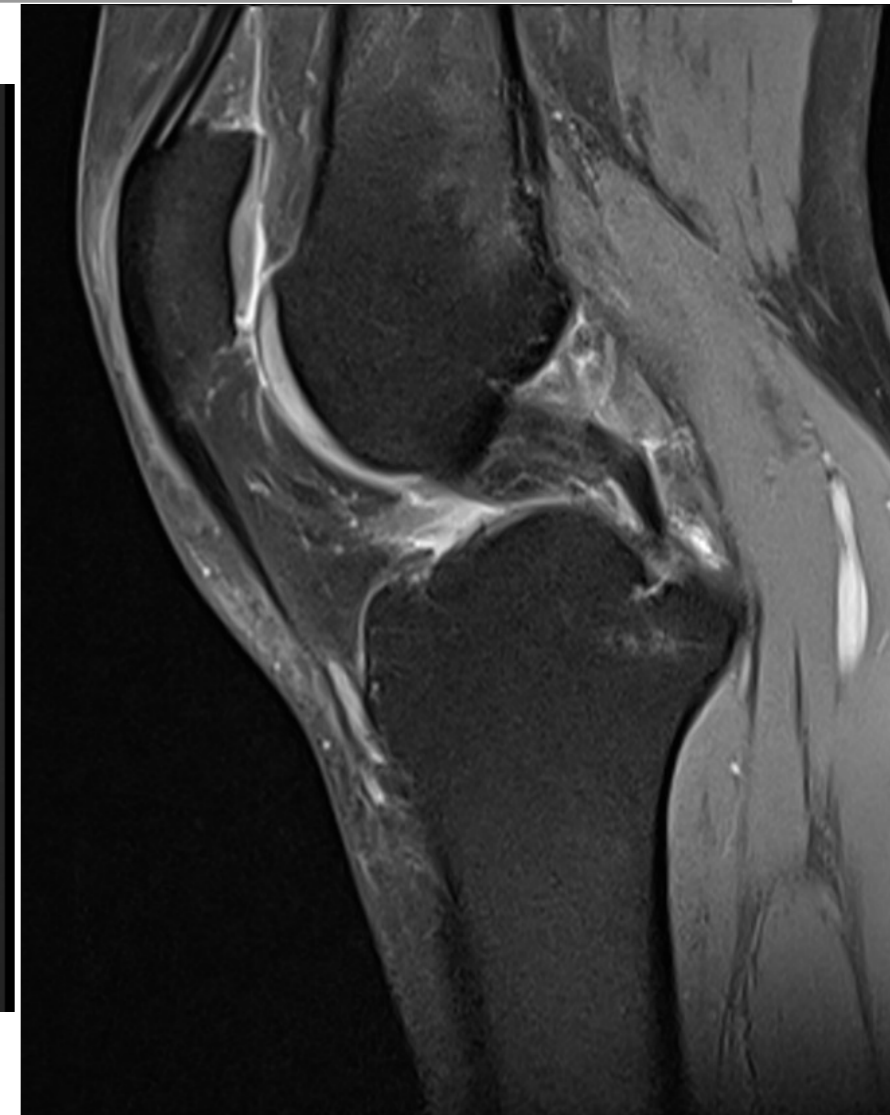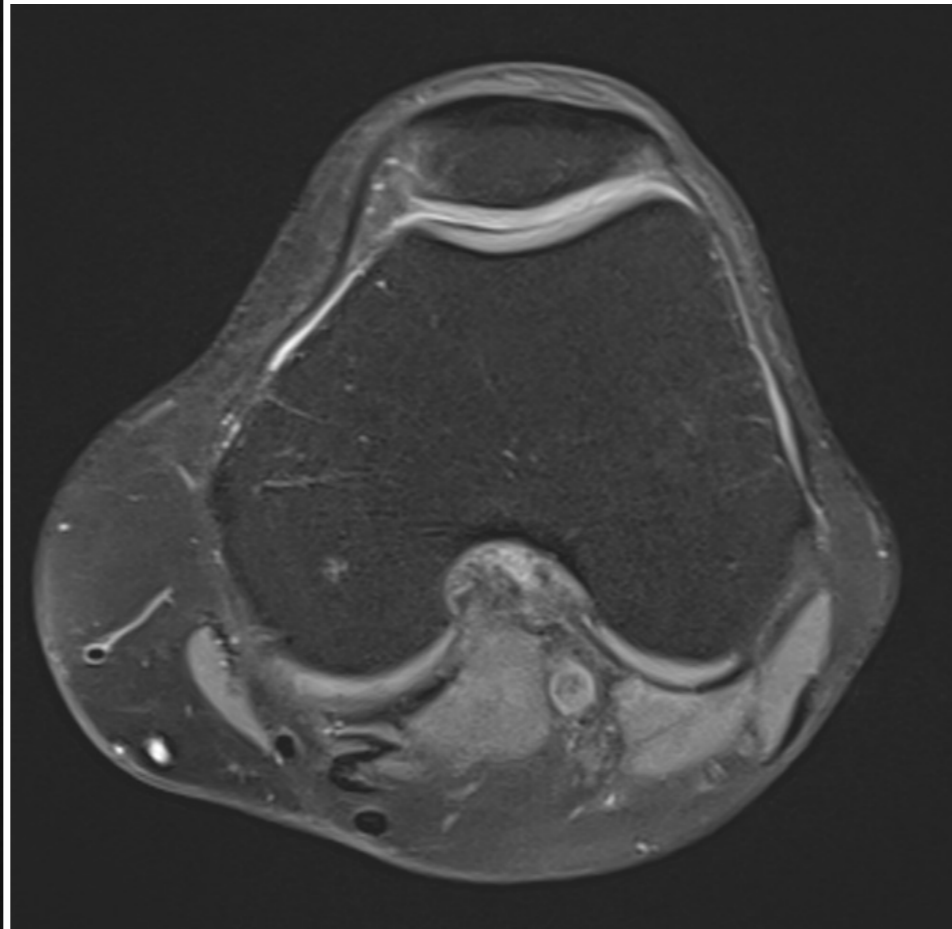
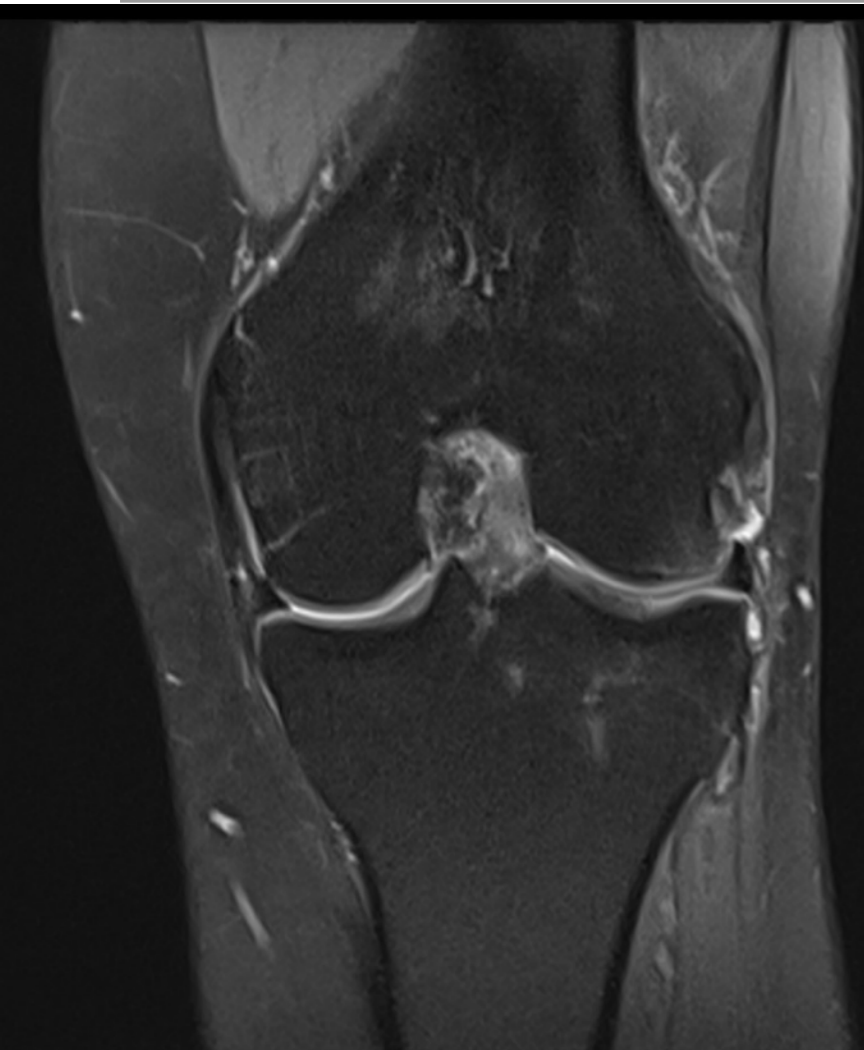


# 1. Pondération DP FS



DP FS	
ISO SIGNAL	Muscle
HYPER signal = BLANC	LIQUIDE OEDEME CARTILAGE
HYPO = GRIS	GRAISSE OS SPONGIEUX
ASIGNAL = NOIR	MENISQUE LIGAMENT TENDON CORTICALE CALCIF FASCIA

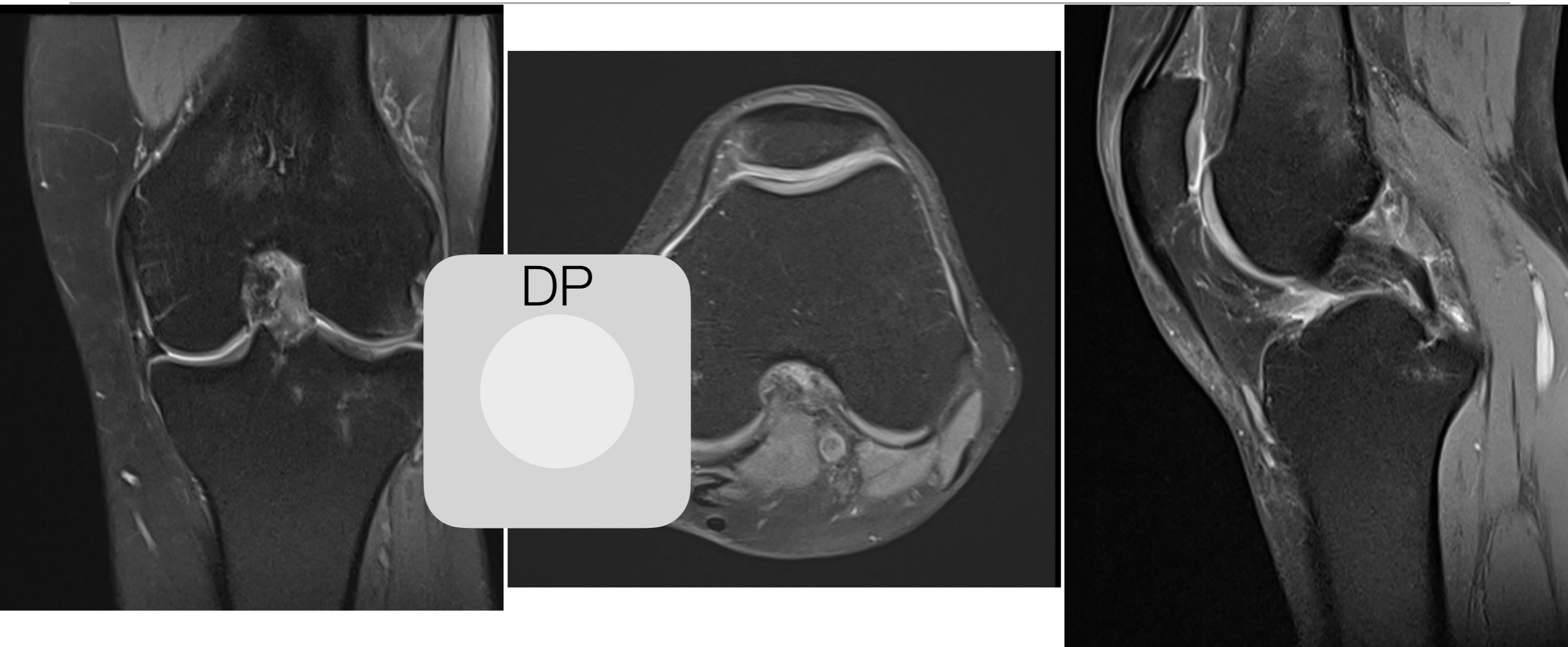
# 1. Pondération DP FS en 2D



**DP** = DENSITE DE PROTON = T2 moins intense

**FS** = FAT SATURATION = chute du signal de la graisse = graisse en hyposignal

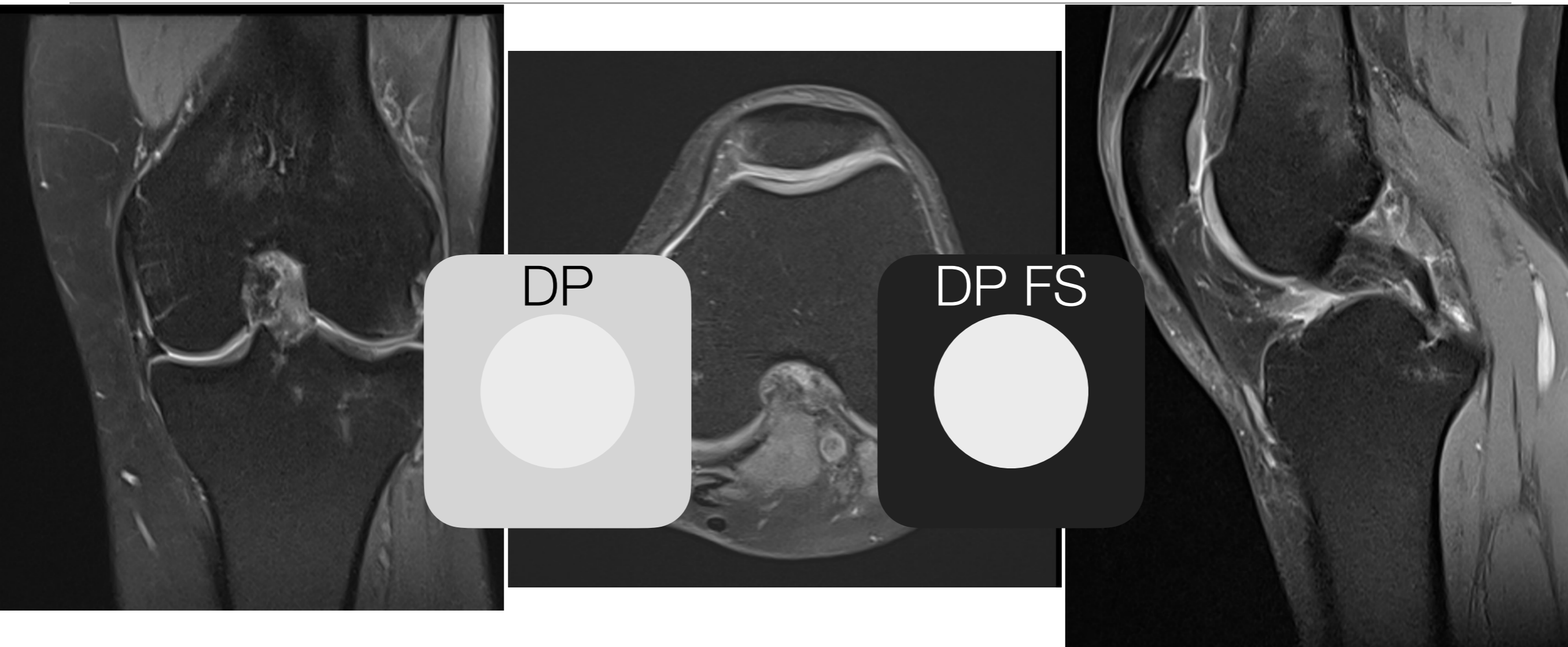
# 1. Pondération DP FS en 2D



**DP** = DENSITE DE PROTON = T2 moins intense

**FS** = FAT SATURATION = chute du signal de la graisse = graisse en hyposignal

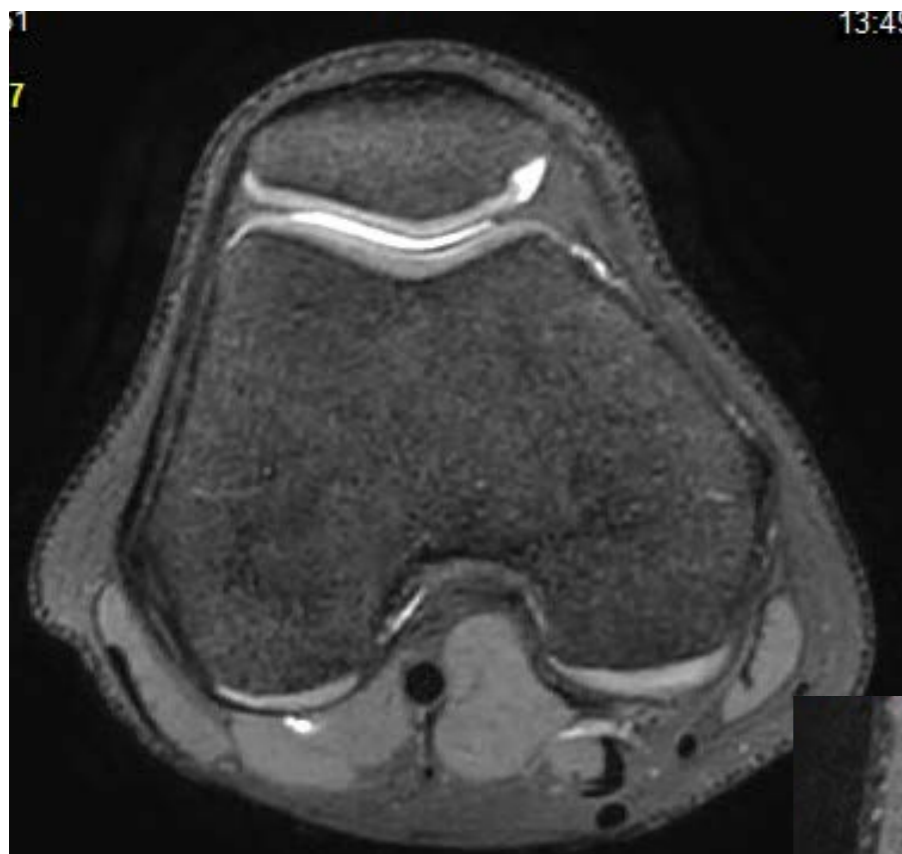# 1. Pondération DP FS en 2D



**DP** = DENSITE DE PROTON = T2 moins intense

**FS** = FAT SATURATION = chute du signal de la graisse = graisse en hyposignal

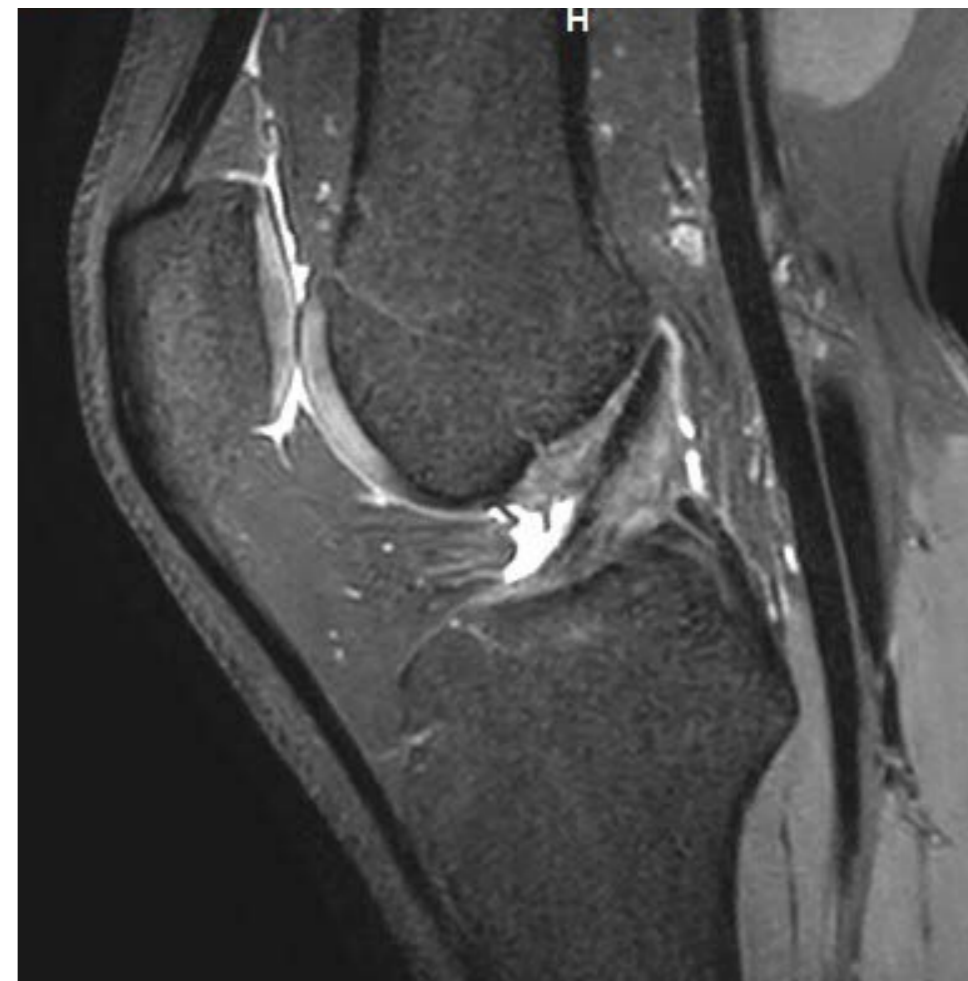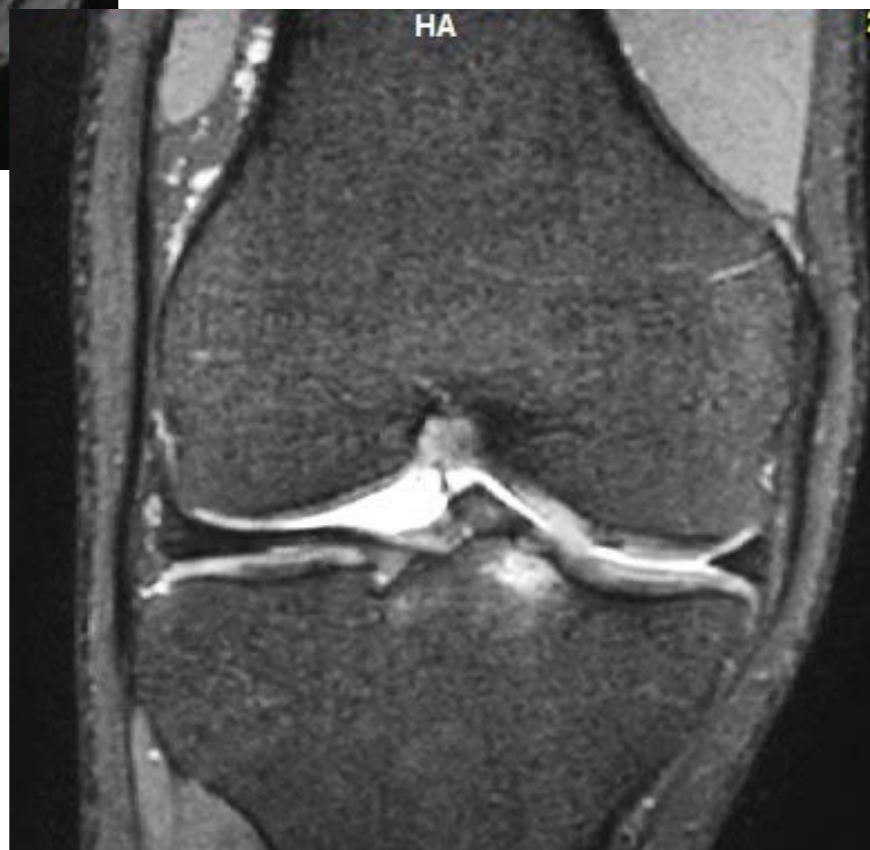# 1. Séquence 3D



**3D DP FS**

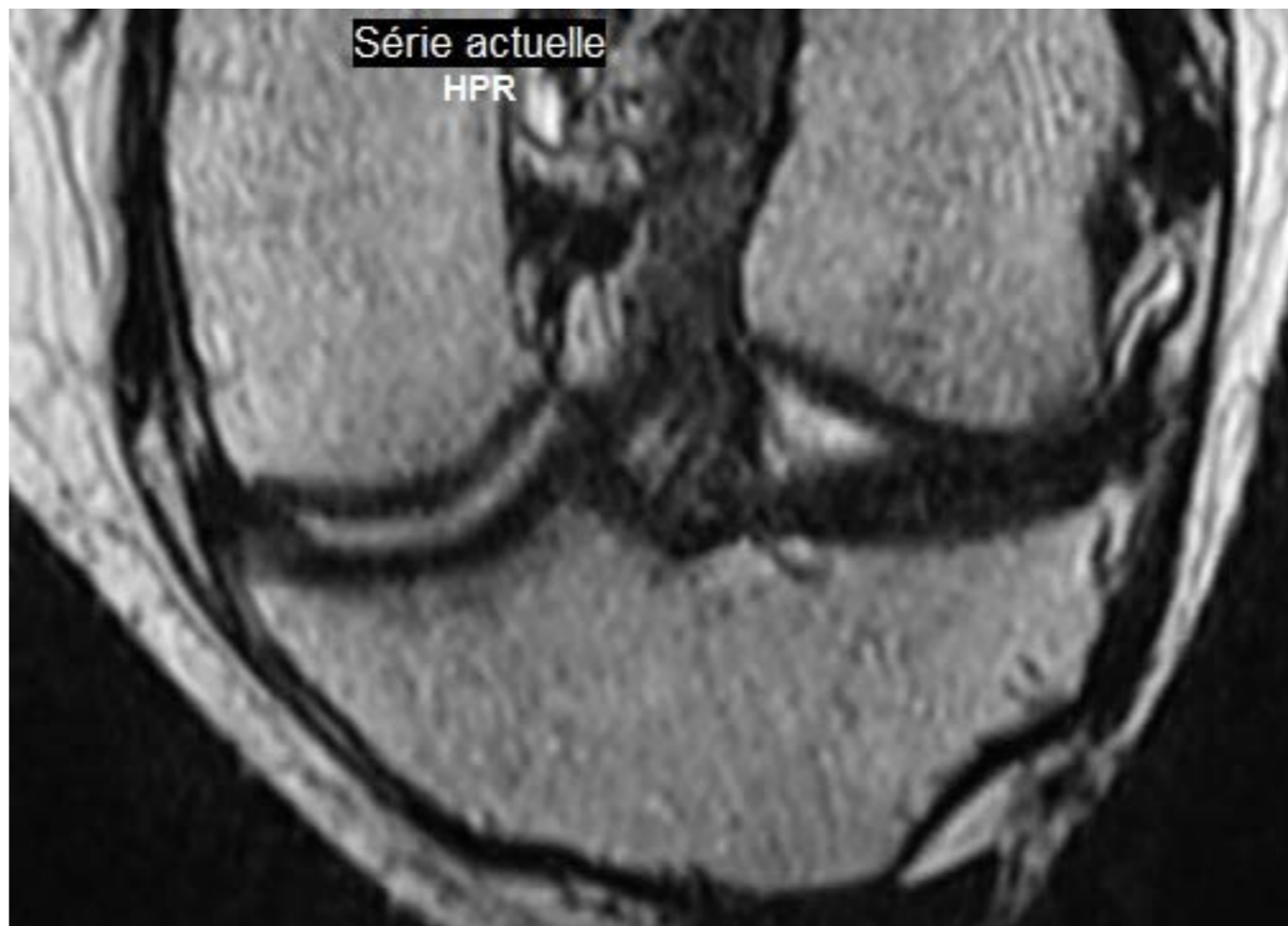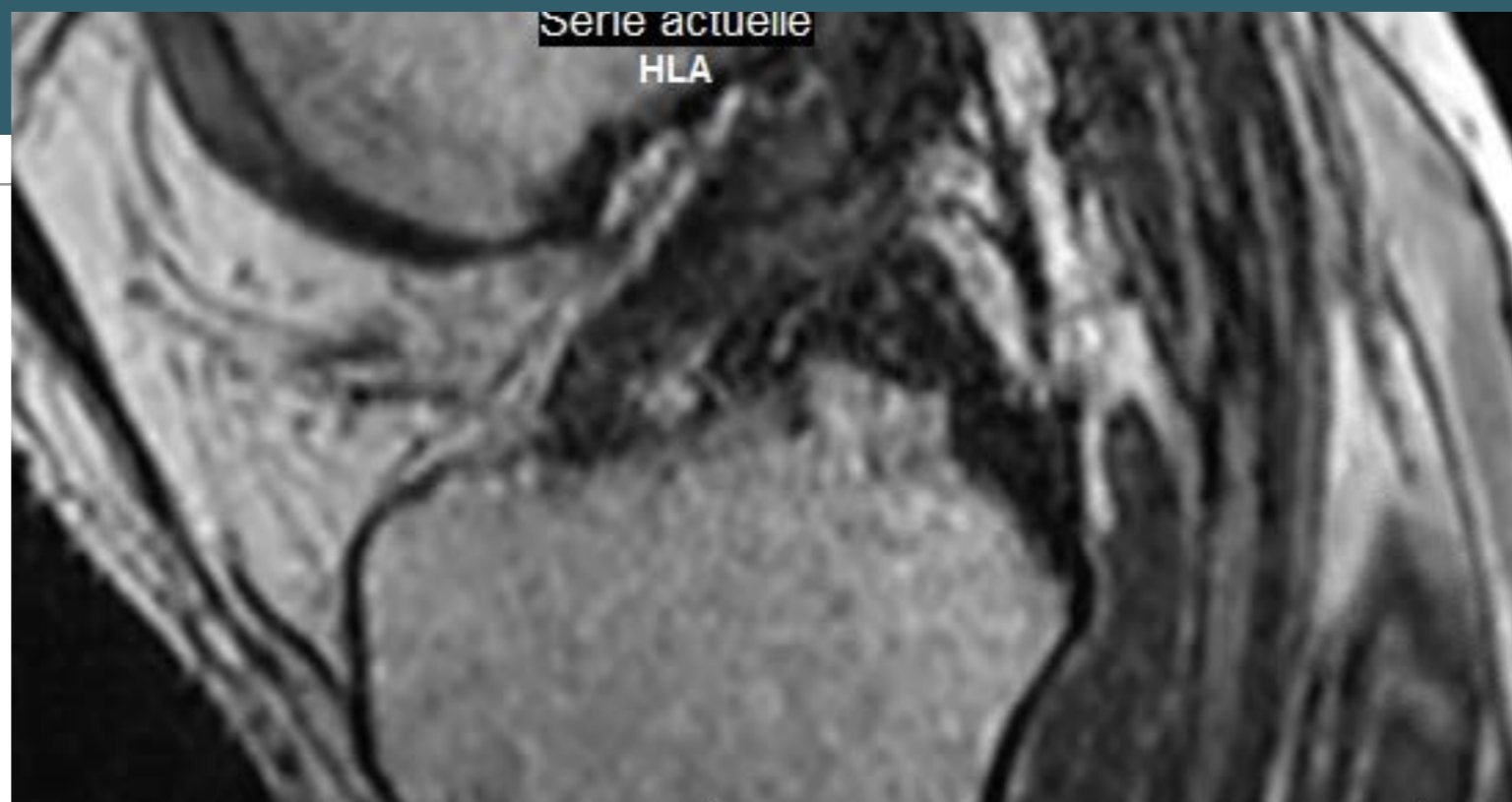
3D T1

3D DP



# 1. Séquence 3D

## 3D DP/T2 sans FS




# 1. DIXON séquence 4 en 1

---

**FLEX / IDEAL**

# 1. DIXON séquence 4 en 1

**FLEX / IDEAL**




T1 - DP - T2 - T1 GADO



# 1. DIXON séquence 4 en 1

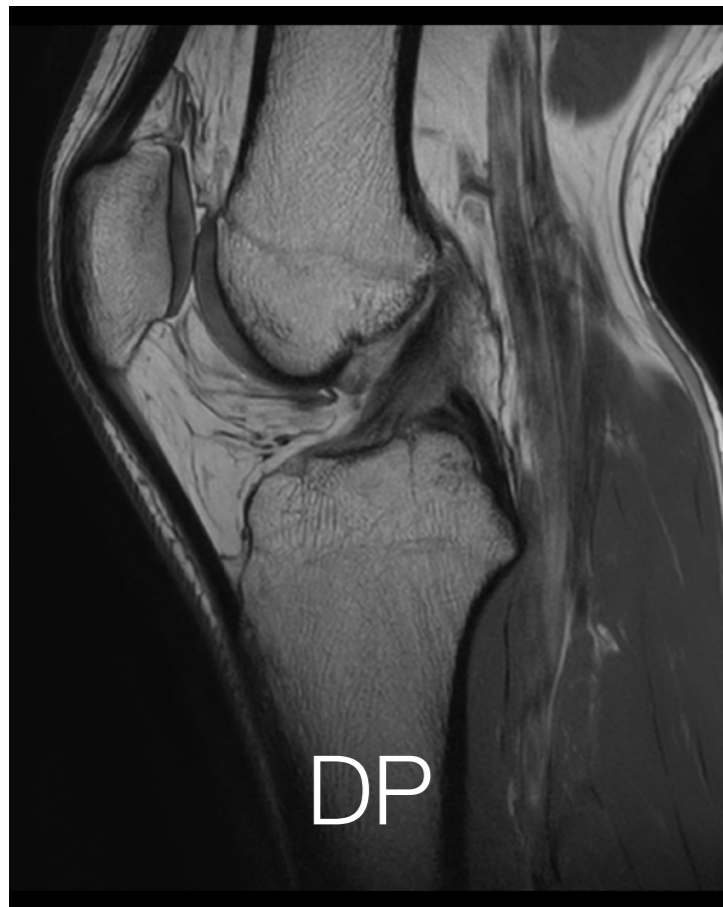**FLEX / IDEAL**



T1 - DP - T2 - T1 GADO

**IN PHASE**

Vraie pondération



# 1. DIXON séquence 4 en 1

**FLEX / IDEAL**



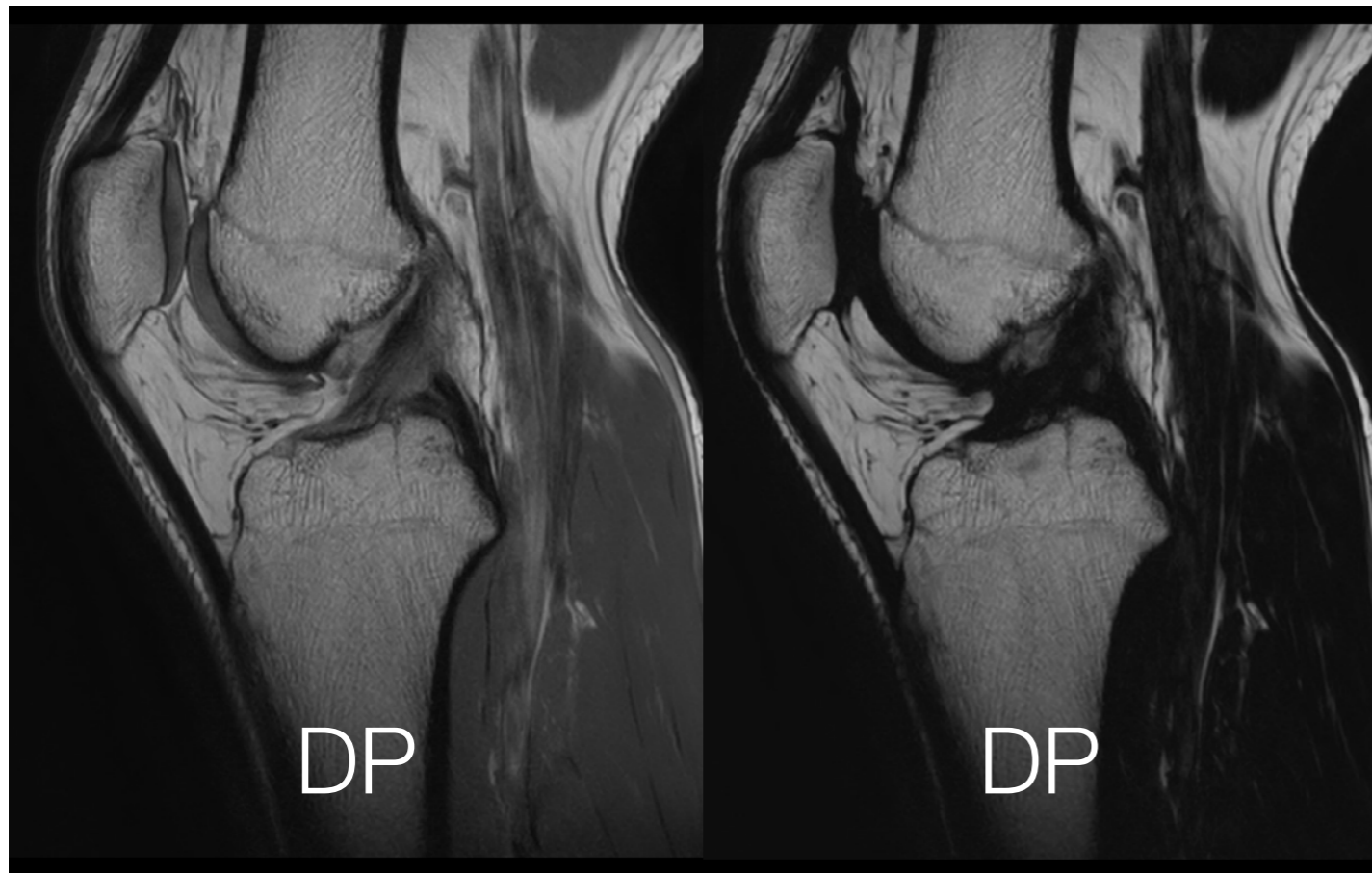
T1 - DP - T2 - T1 GADO

**IN PHASE**

Vraie pondération

**FAT**

Suppression de l'eau



# 1. DIXON séquence 4 en 1

**FLEX / IDEAL**



T1 - DP - T2 - T1 GADO

**IN PHASE**

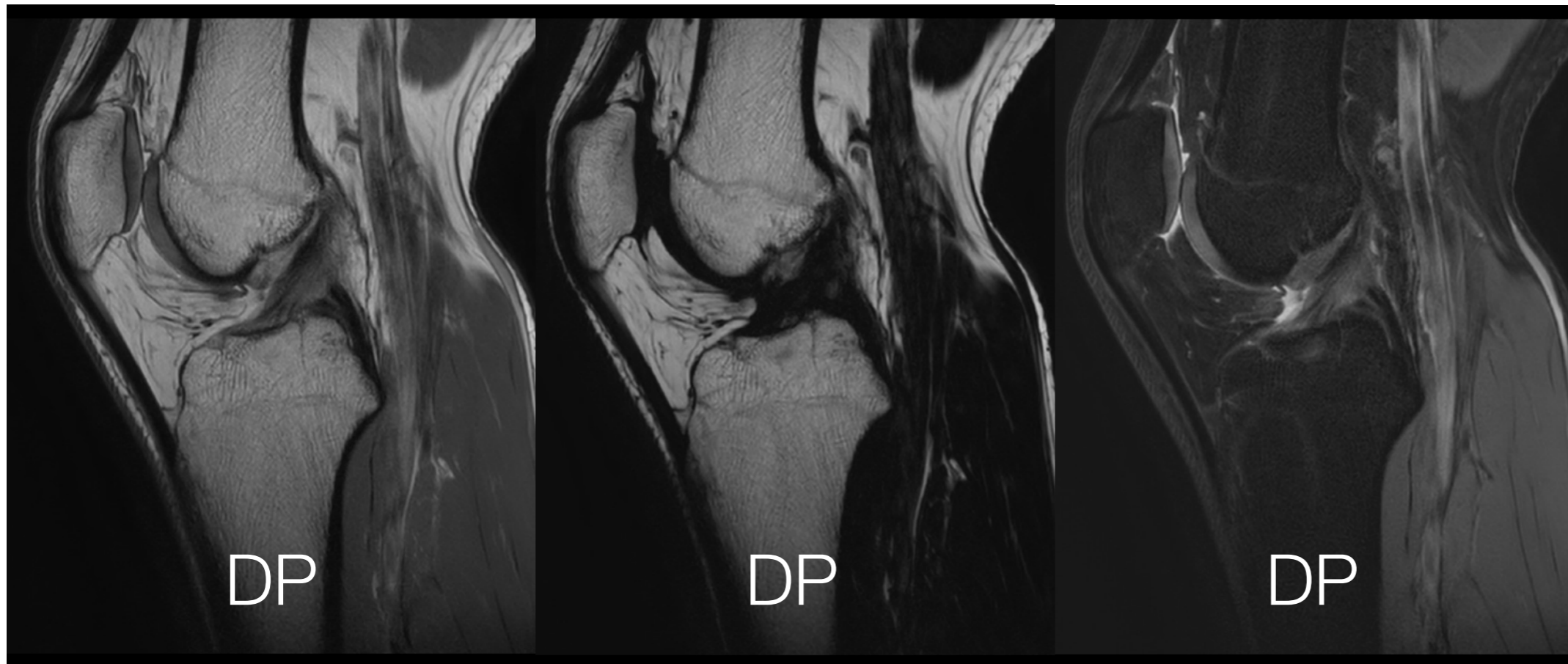
Vraie pondération

**FAT**

Suppression de l'eau

**WATER**

Suppression de la graisse



# 1. DIXON séquence 4 en 1

**FLEX / IDEAL**



T1 - DP - T2 - T1 GADO

**IN PHASE**

Vraie pondération

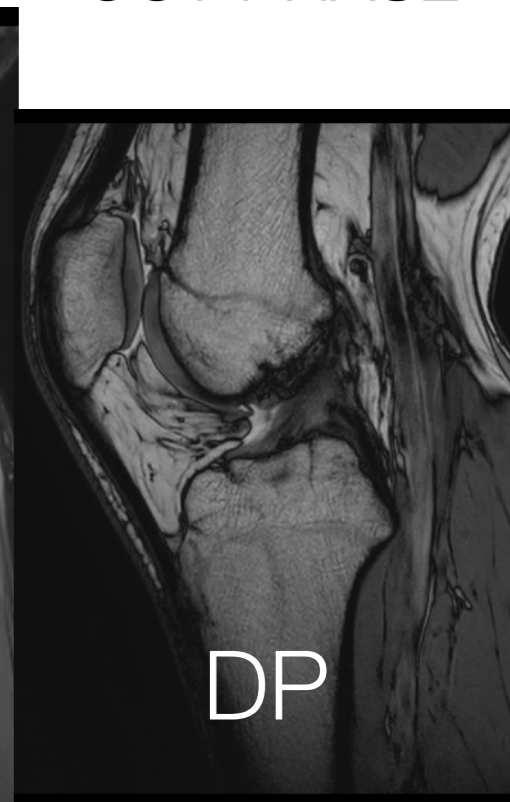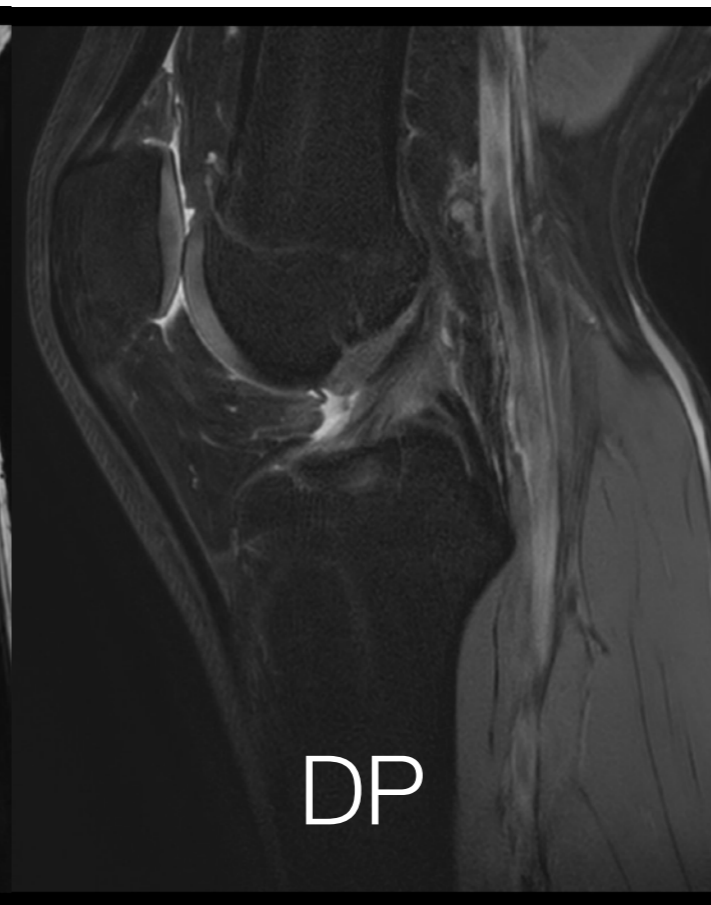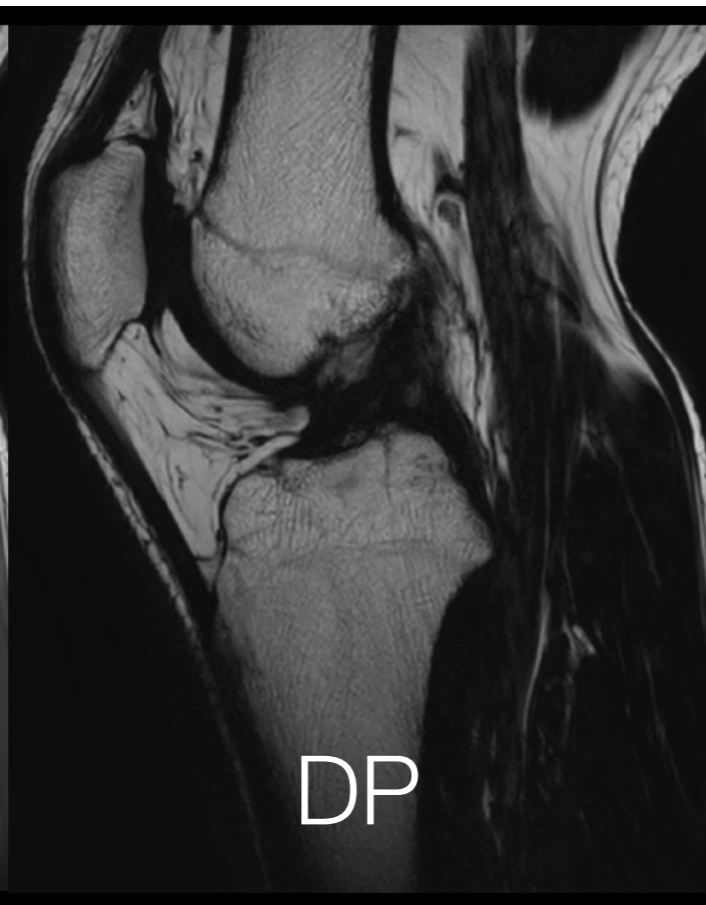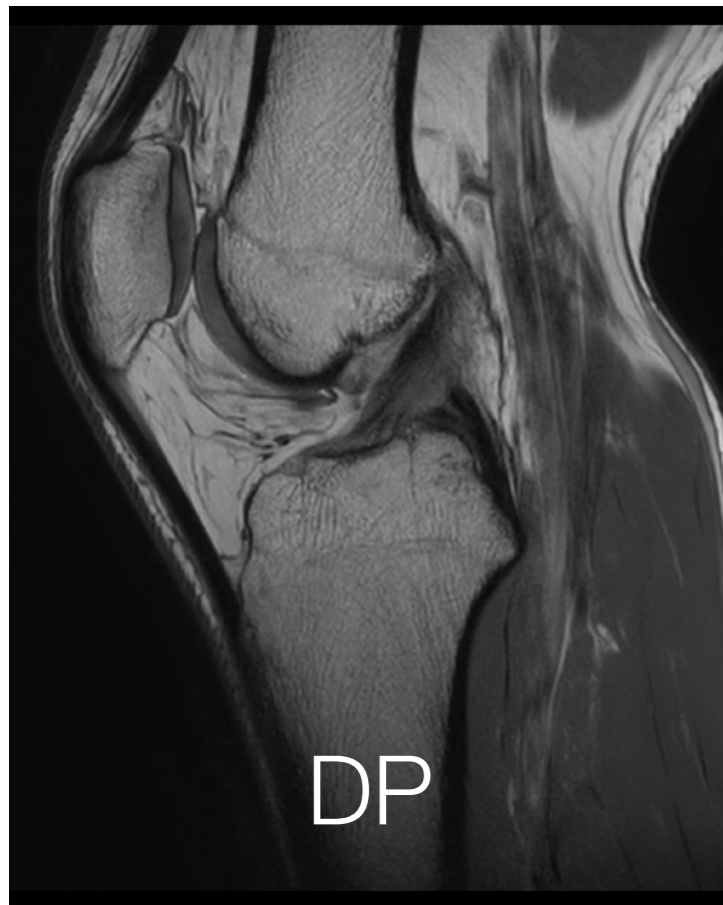**FAT**

Suppression de l'eau

**WATER**

Suppression de la graisse

OUT PHASE

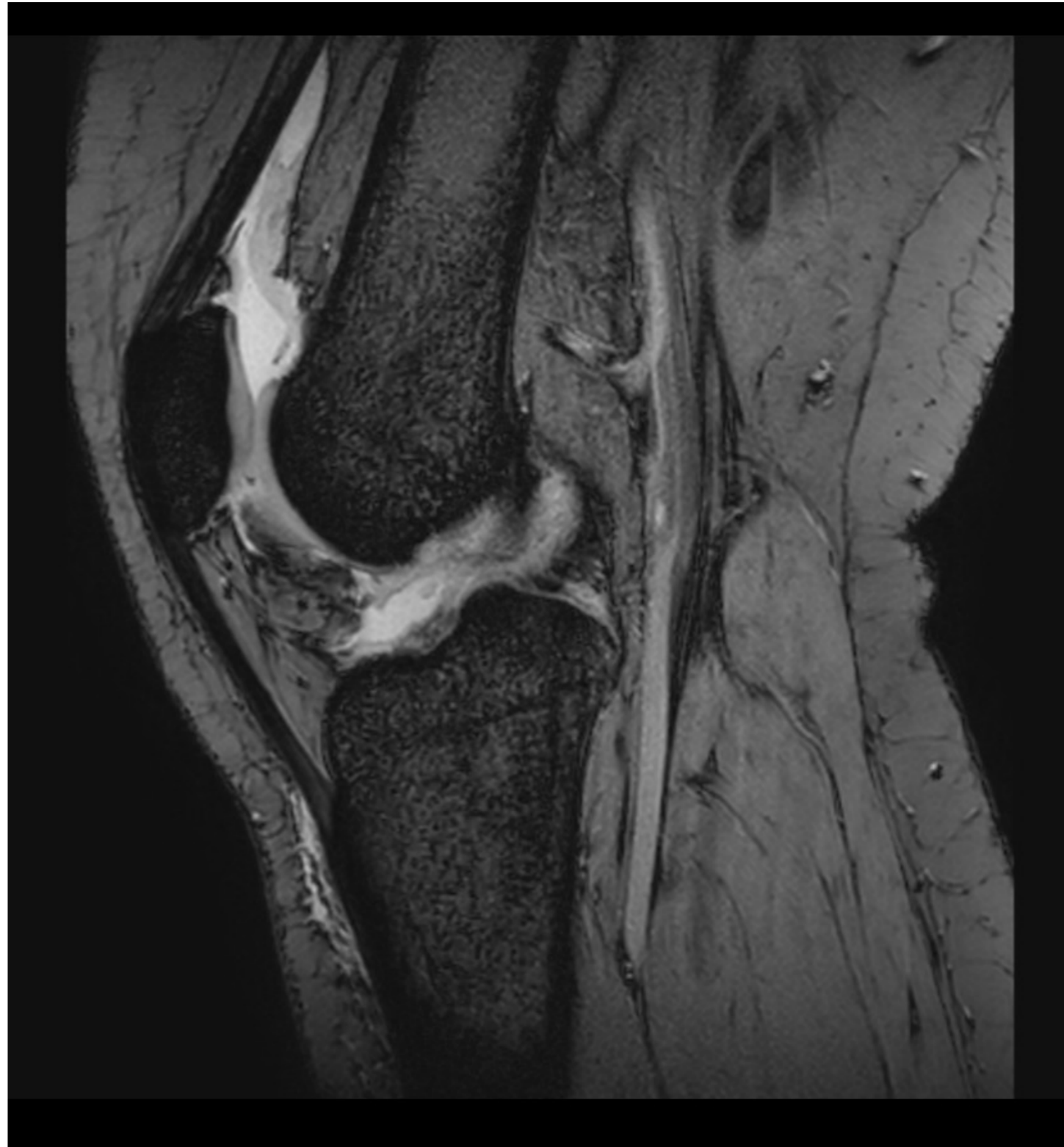

# 1. T2 ECHO de GRADIENT

## T2 EG

Sensibilise la détection  
de l'hémossidérine  
= **A signal**

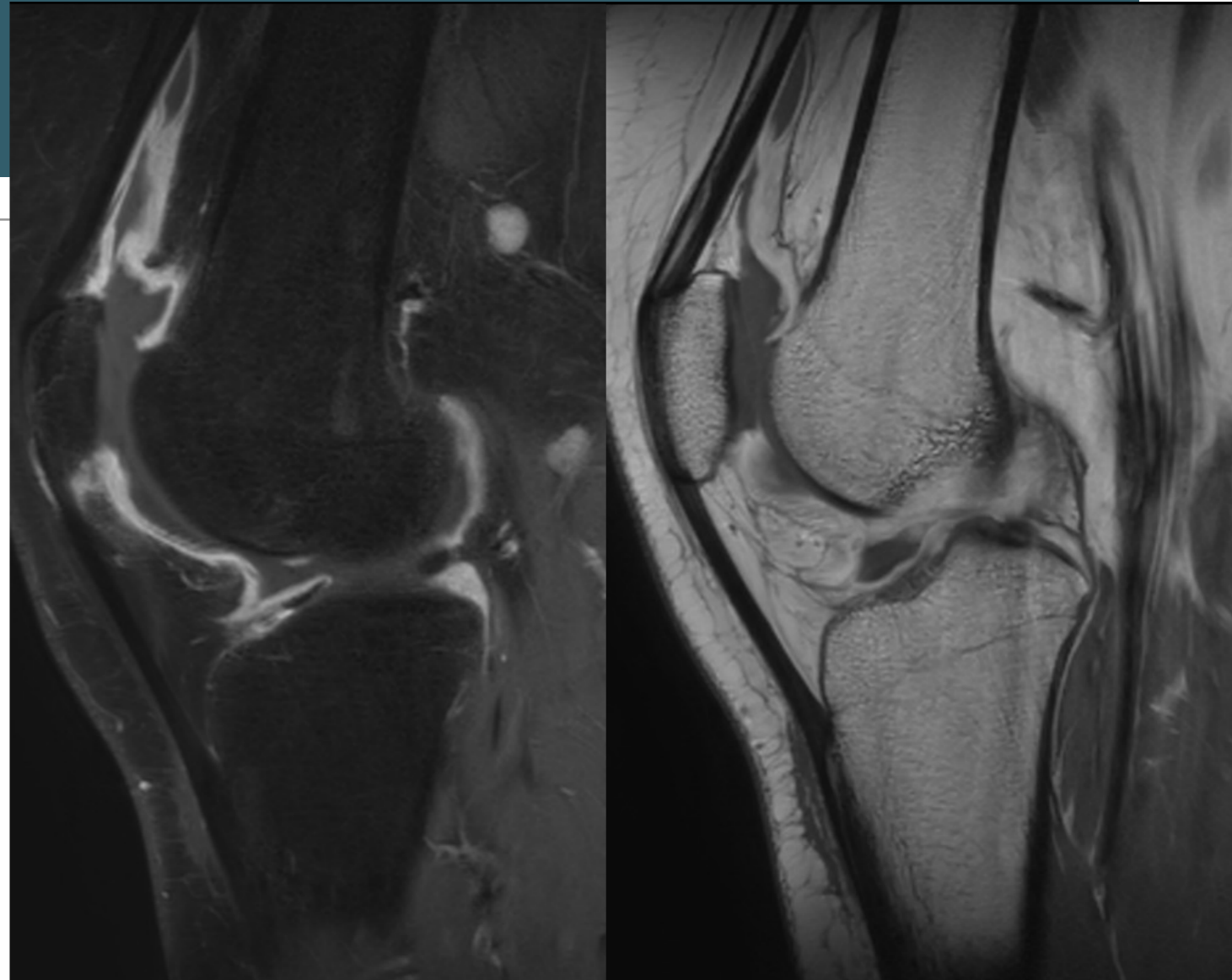
Synovite villo nodulaire  
Arthropathie Hémophilique  
Synovite chronique



# 1. GADOLINIUM

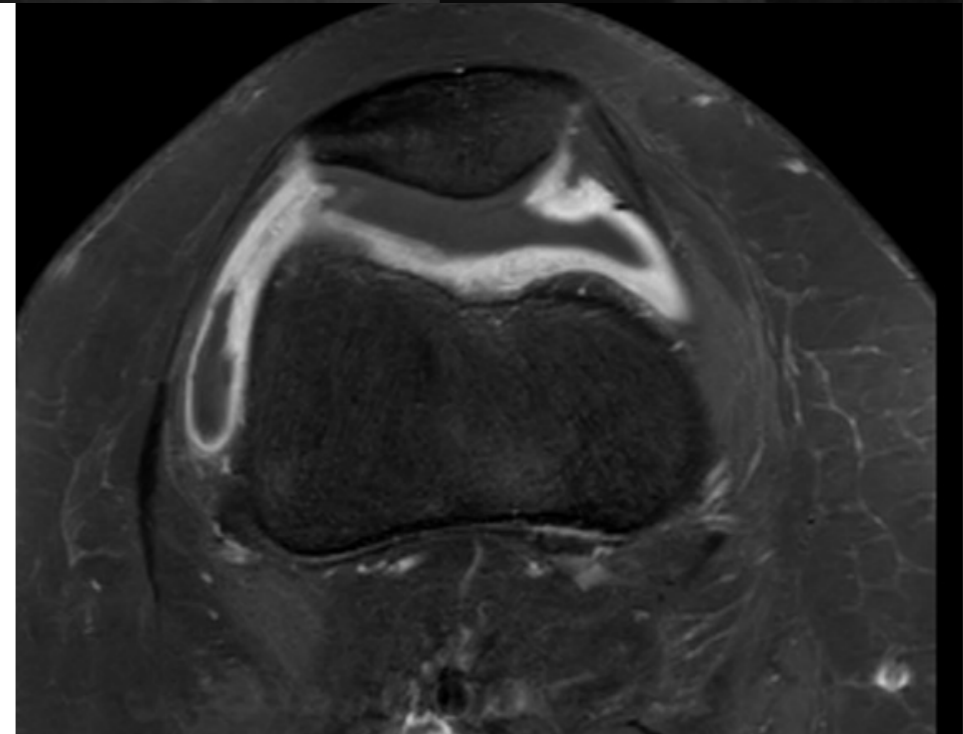
**T1 GADO +/- FS**

**T1 GADO DIXON**

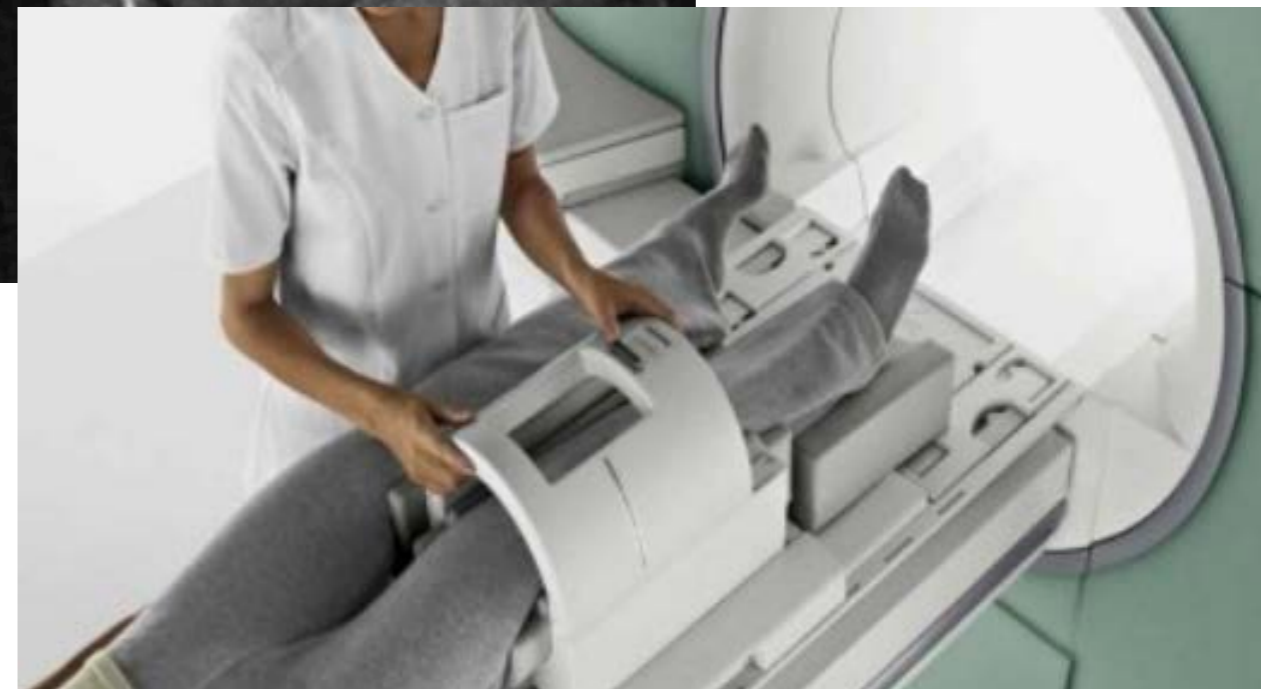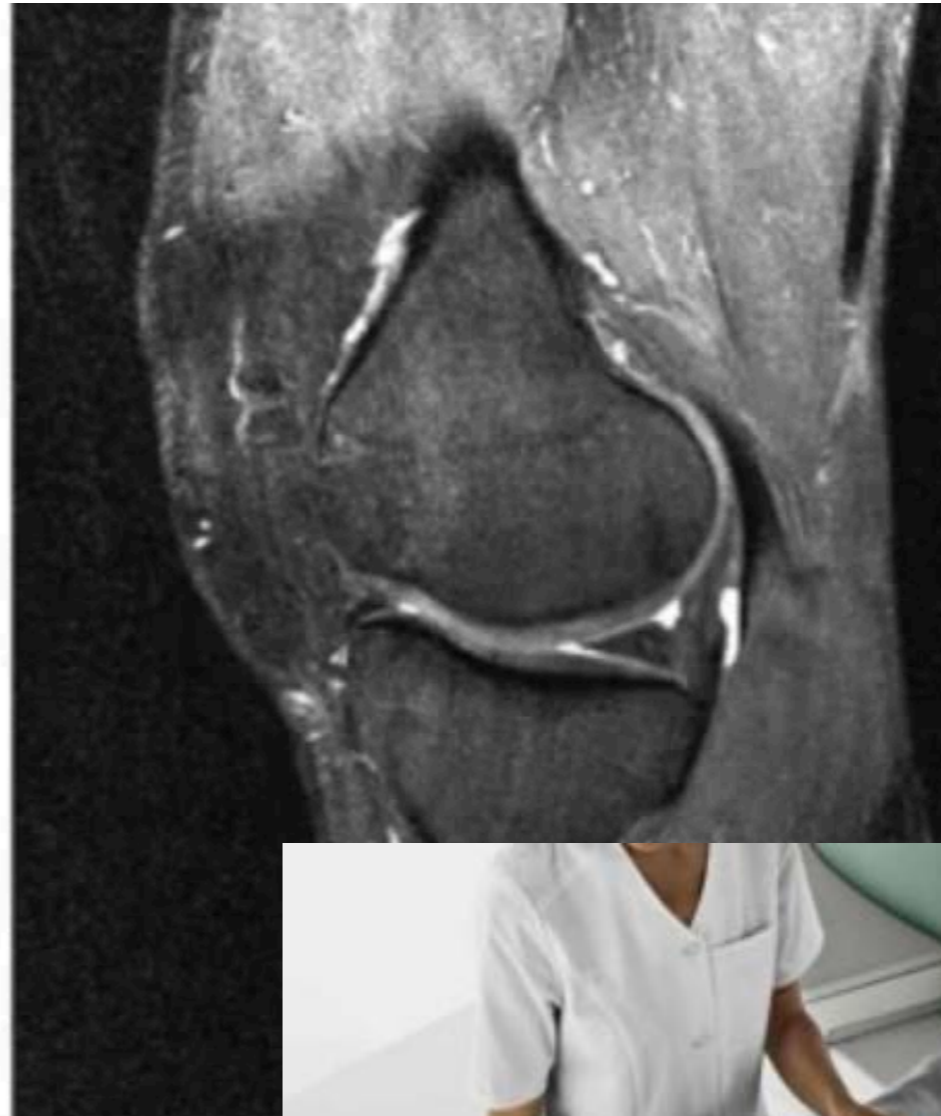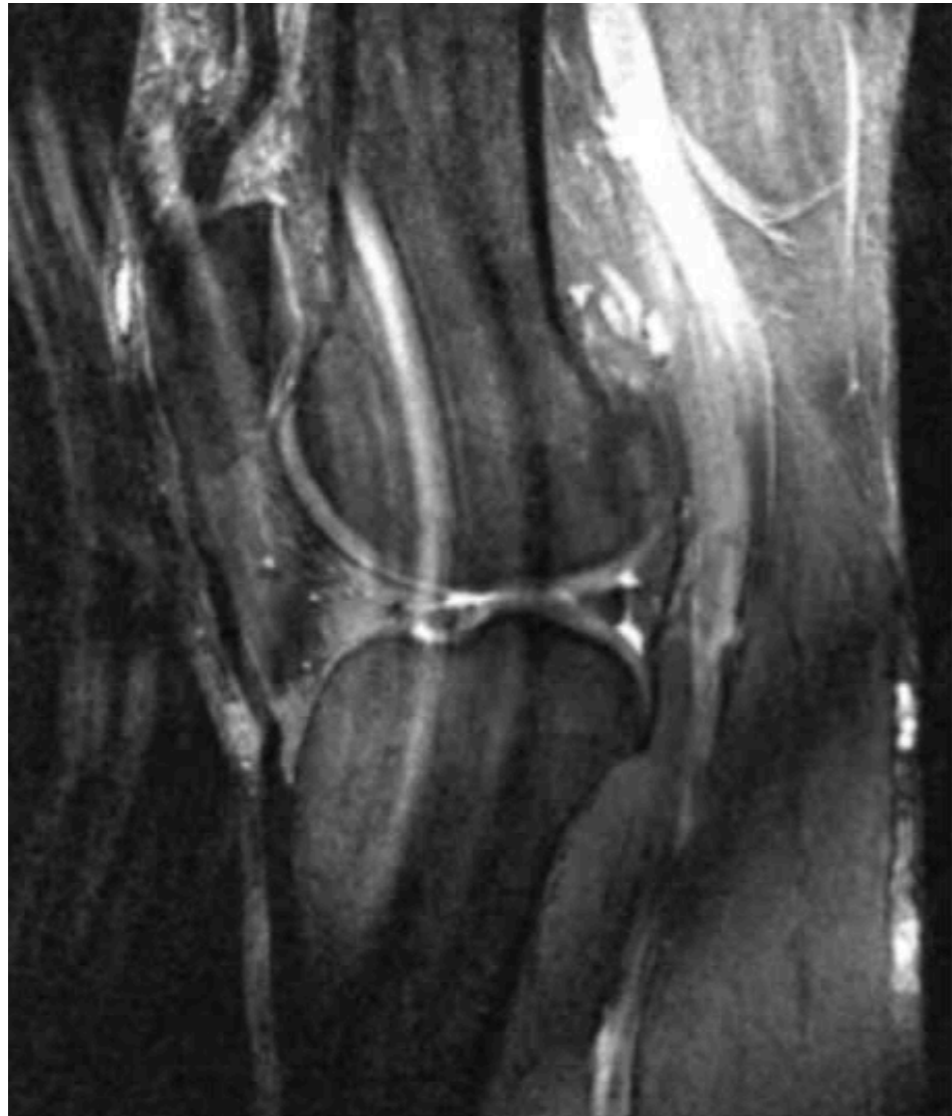


Prise de contraste de l'inflammation  
et de la vascularisation

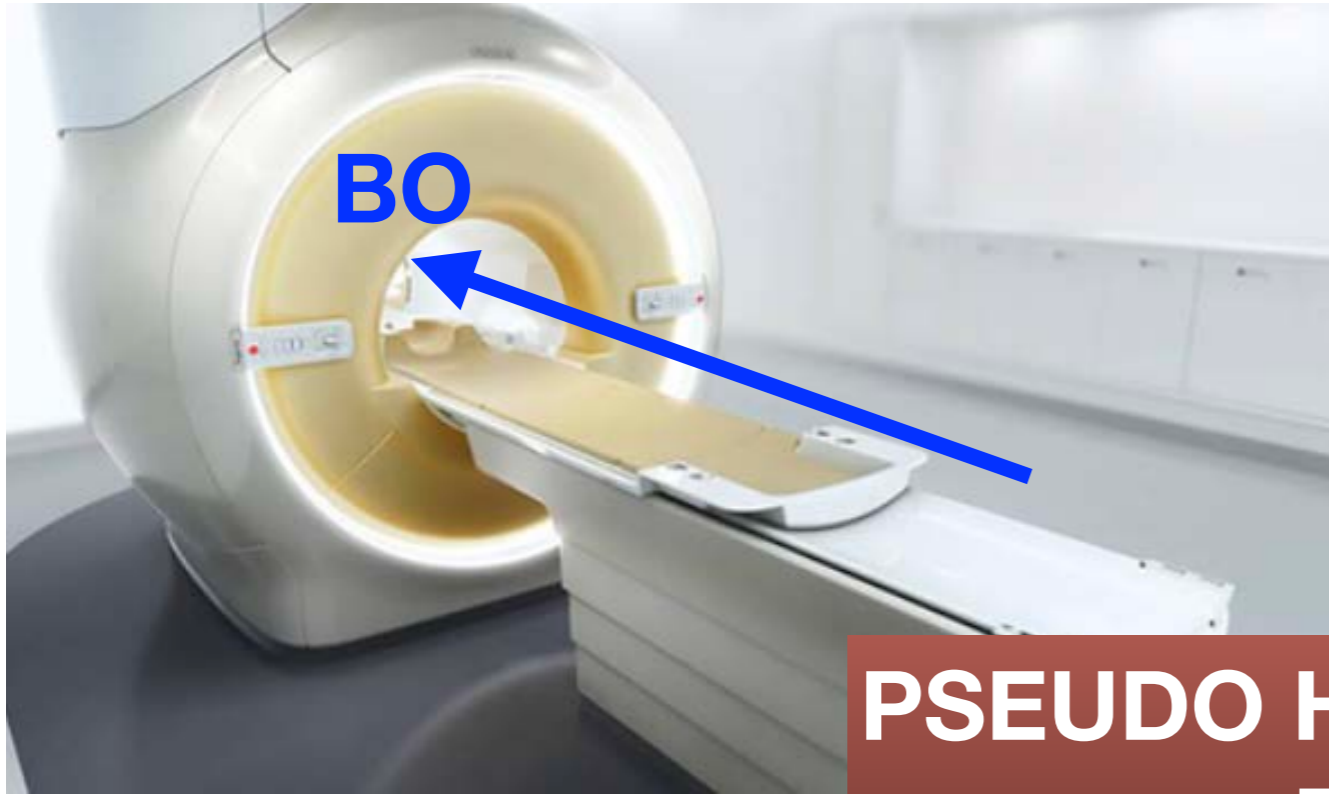
Augmentation du signal T1



# 1. Artefacts de Mouvements



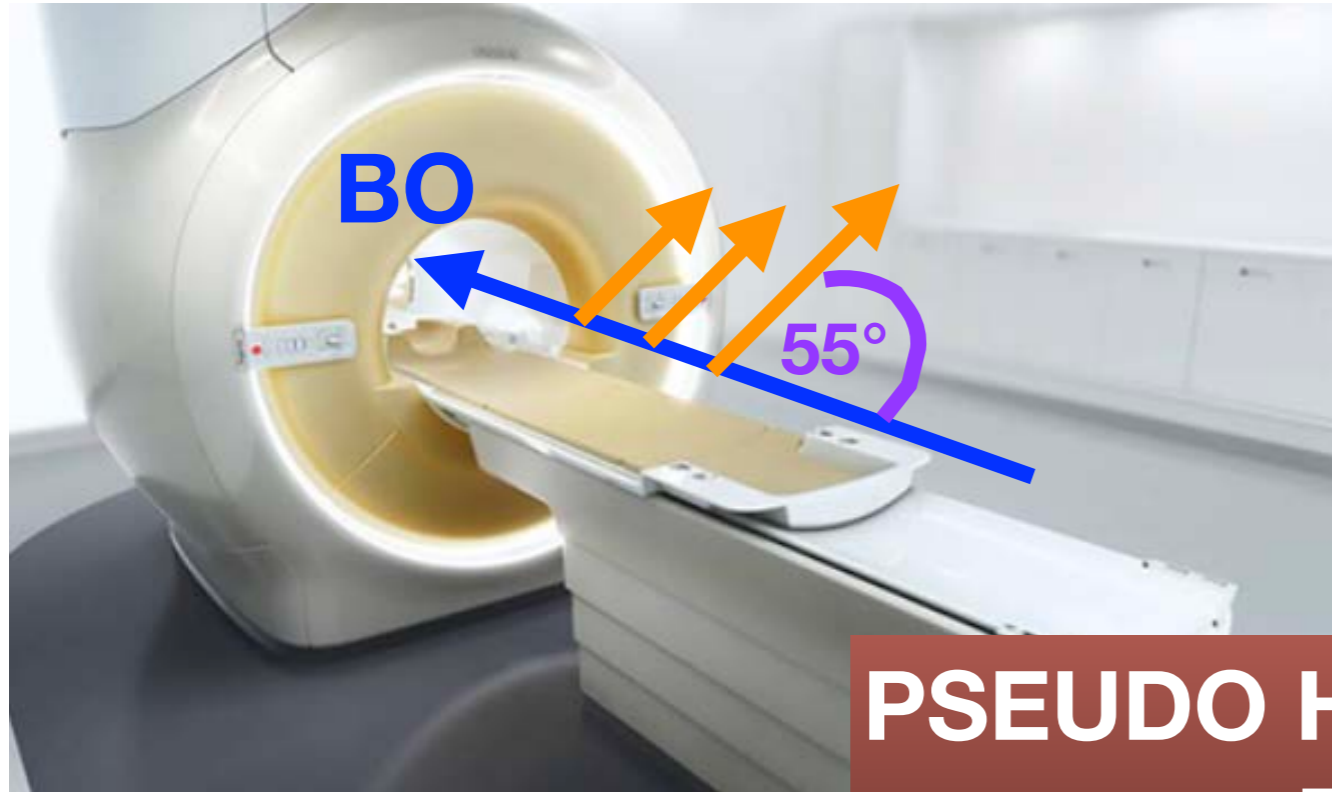# 1. Angle Magique



**PSEUDO HYPER SIGNAL  
DP FS**

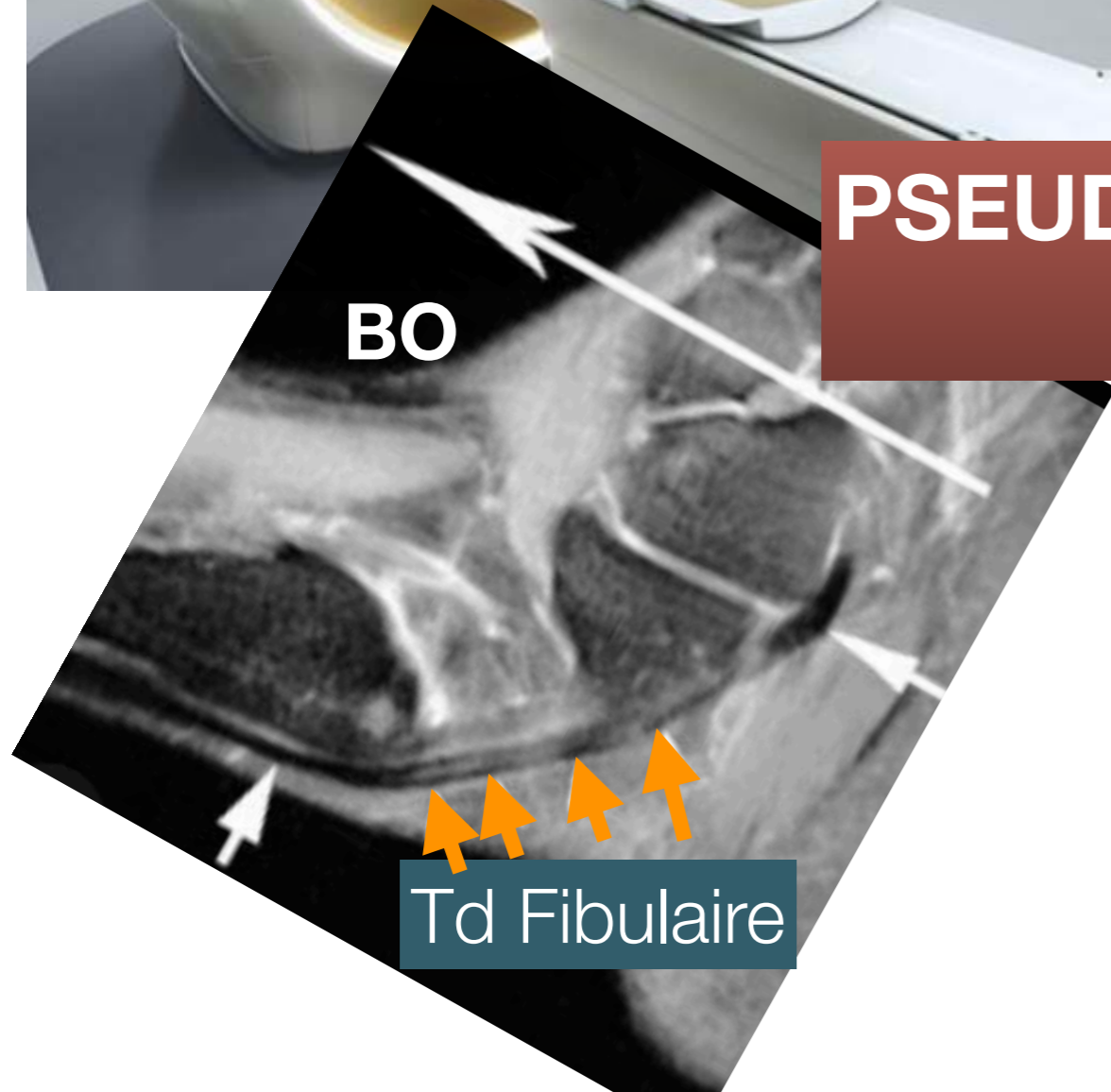



# 1. Angle Magique



**PSEUDO HYPER SIGNAL  
DP FS**

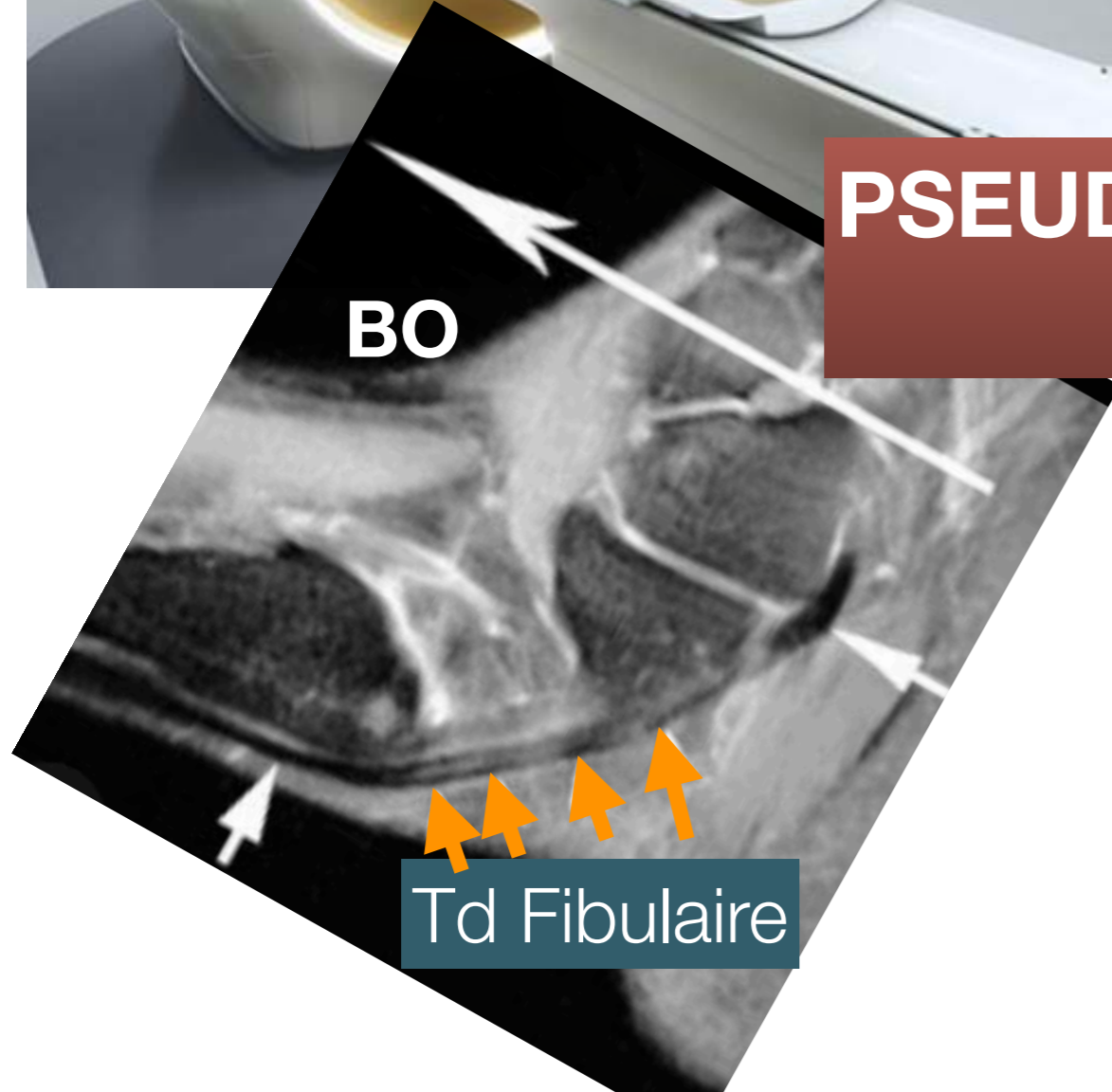

# 1. Angle Magique



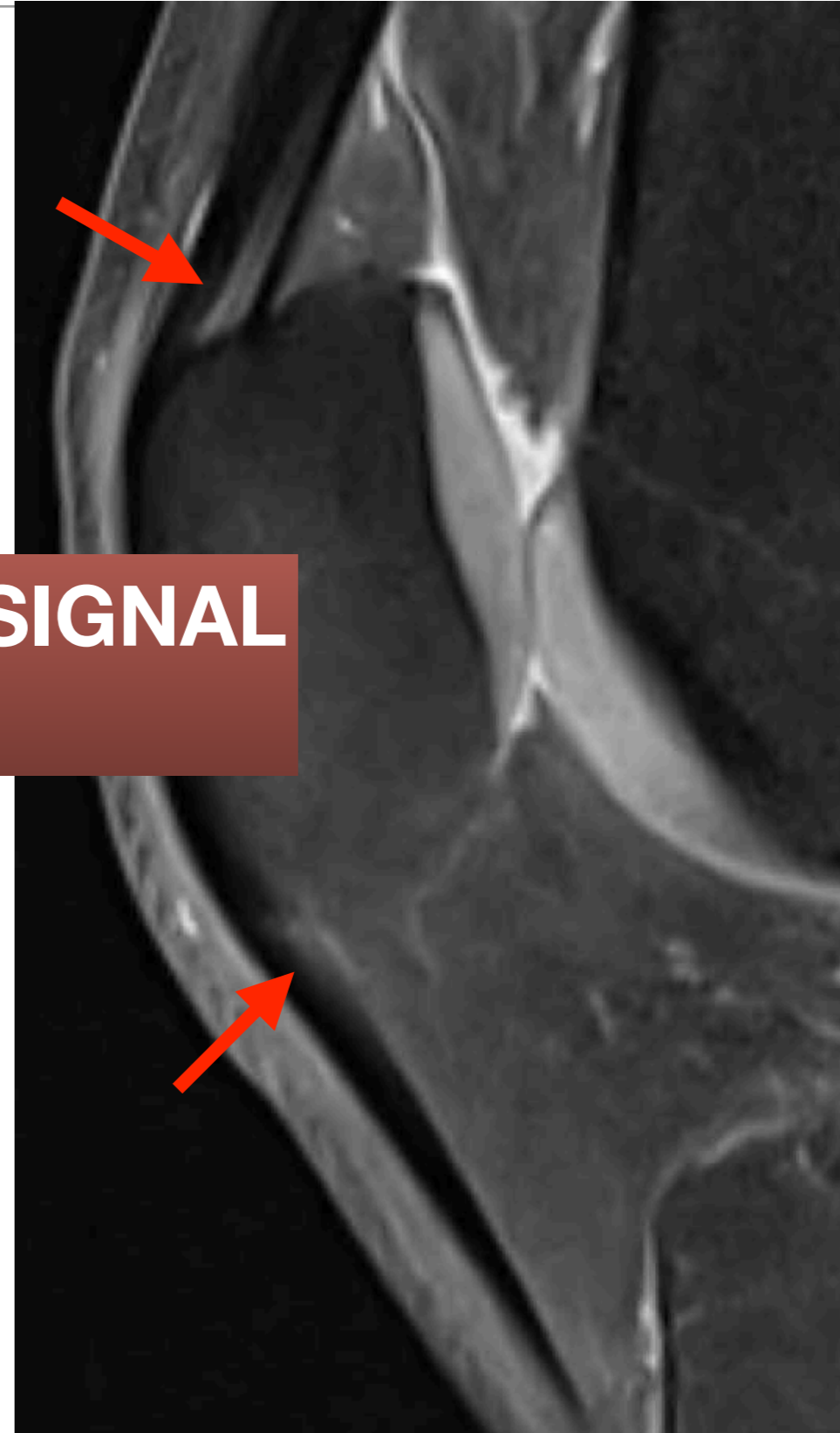
**PSEUDO HYPER SIGNAL  
DP FS**

**Td Fibulaire**

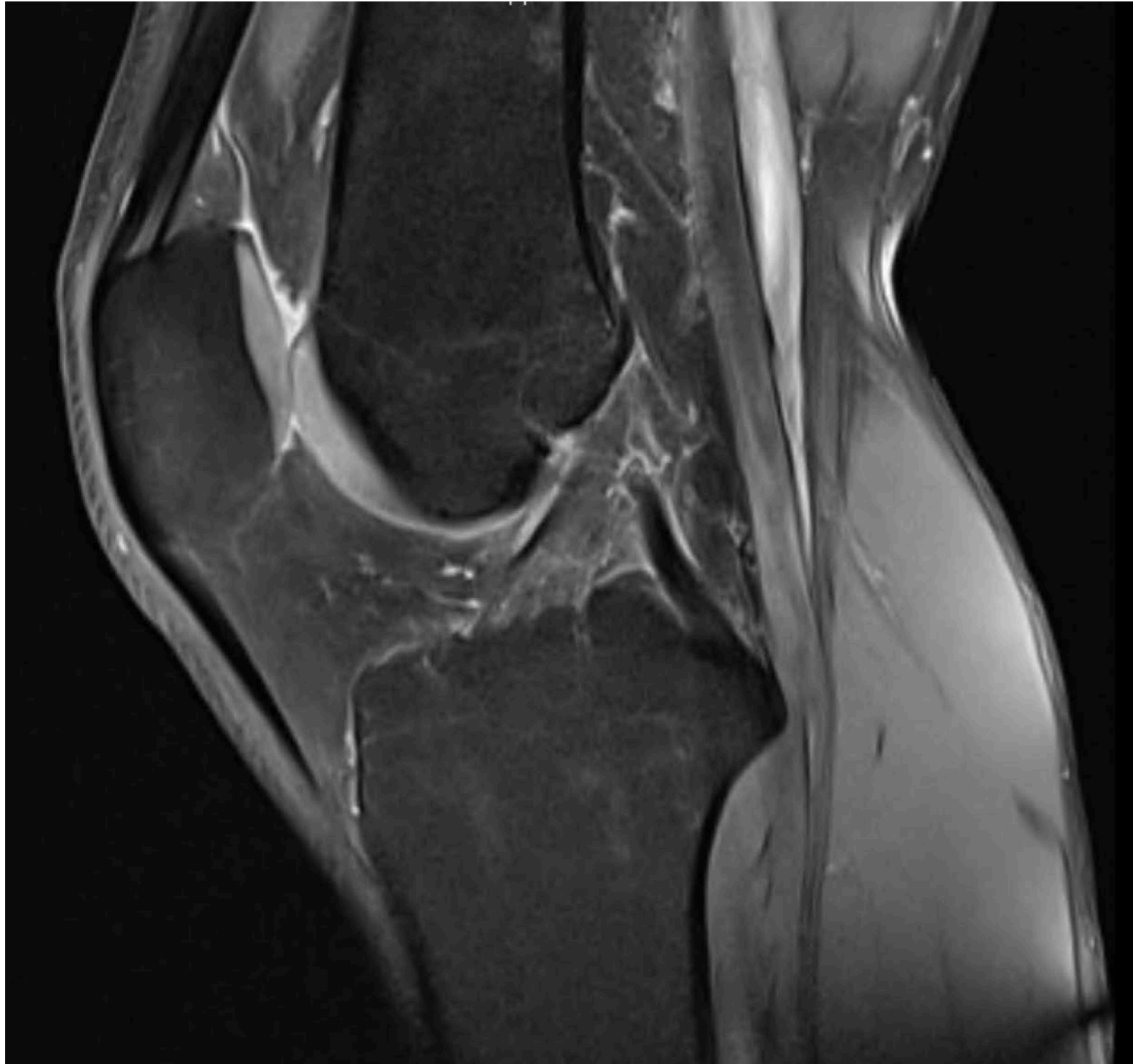# 1. Angle Magique



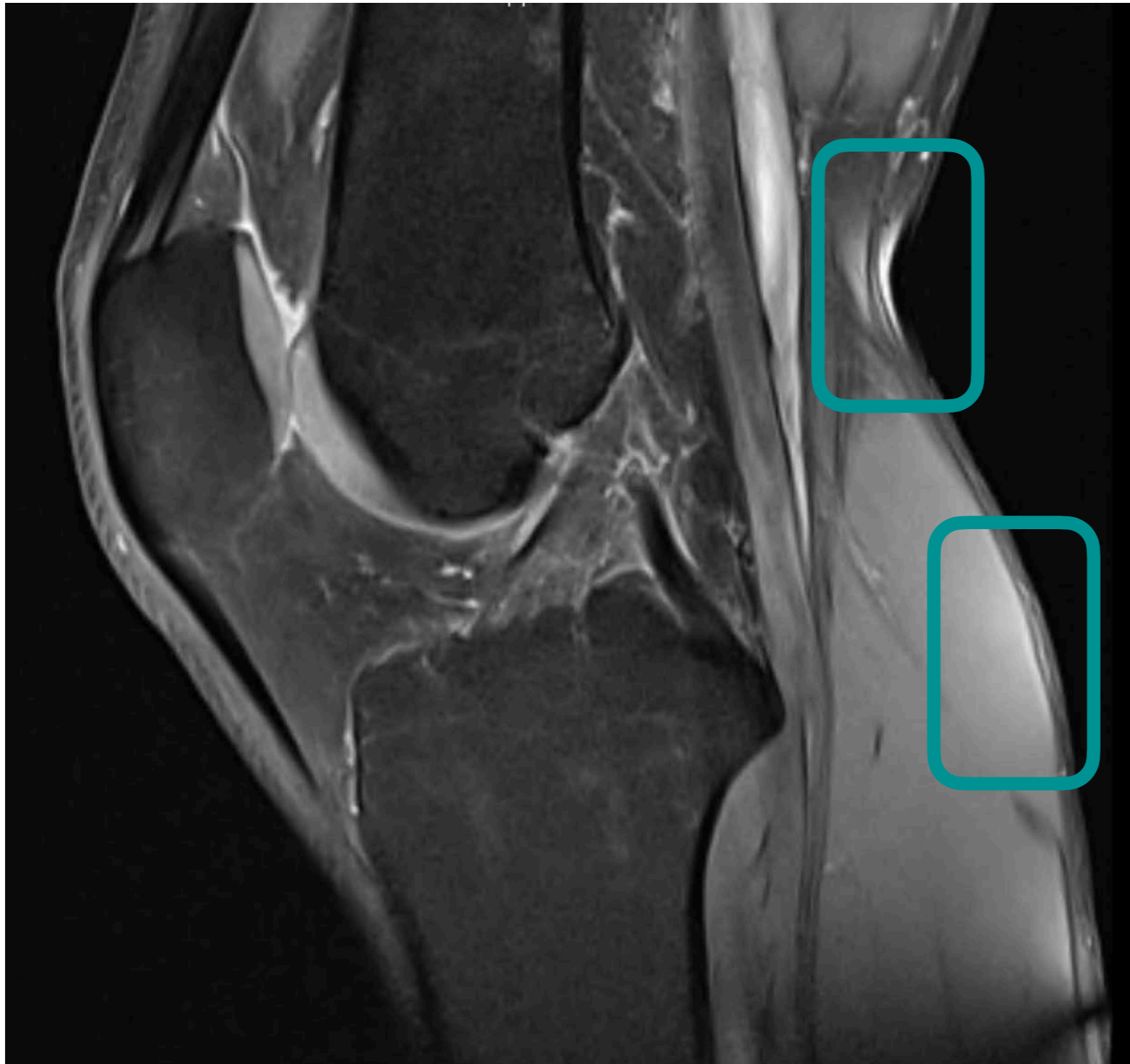
**PSEUDO HYPER SIGNAL  
DP FS**



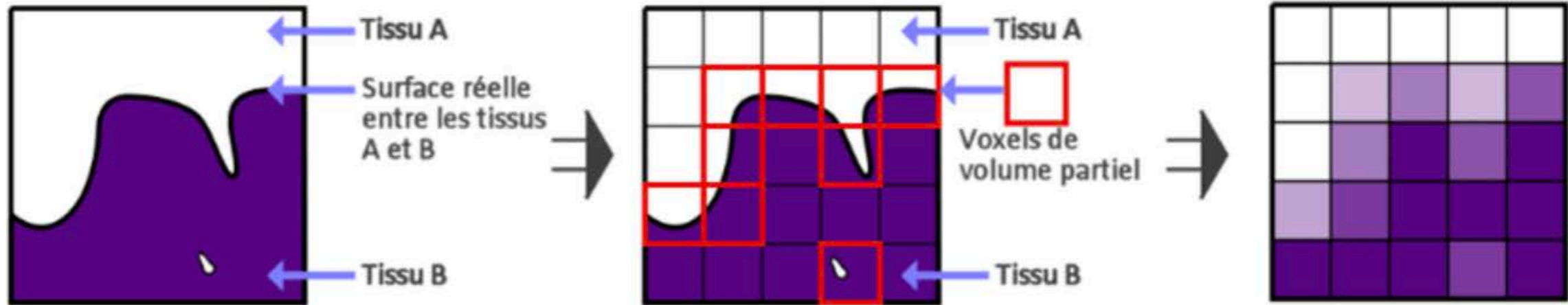
# 1. Défaut de saturation



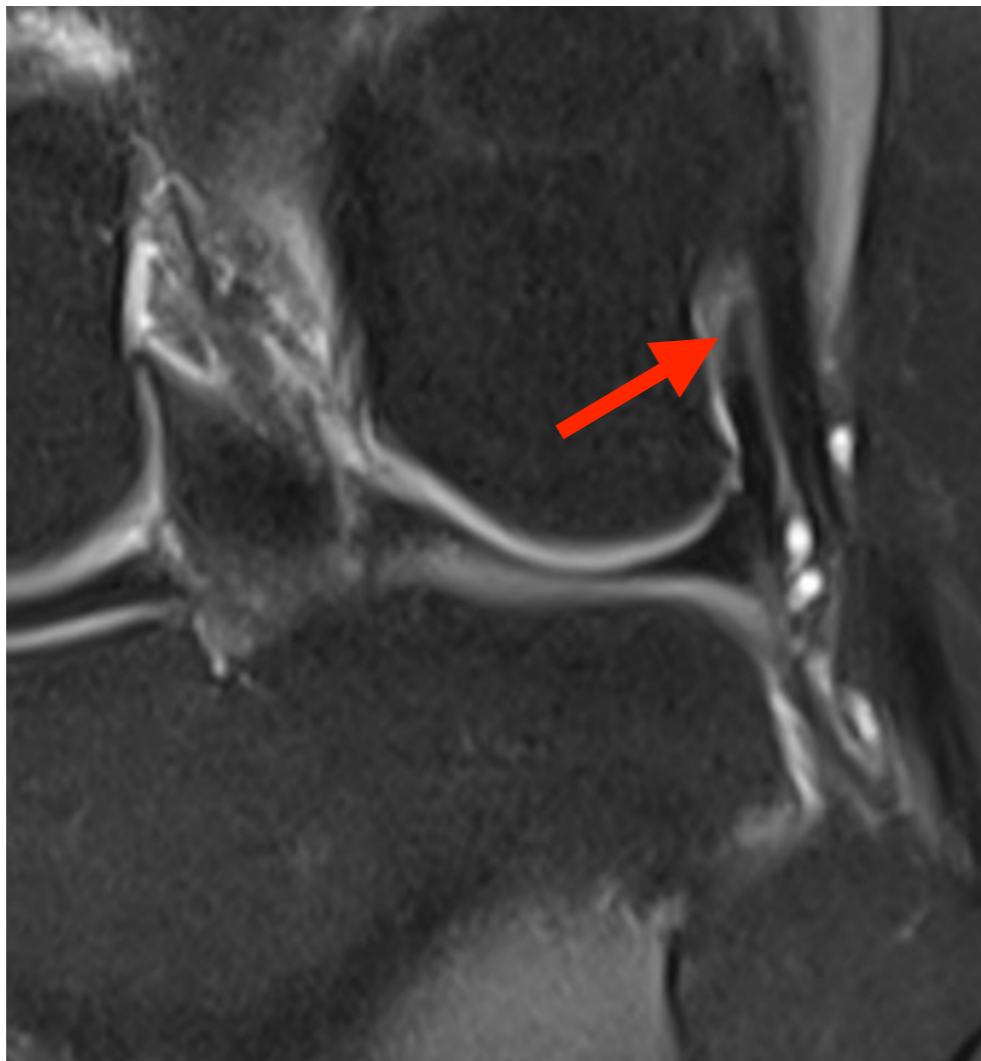
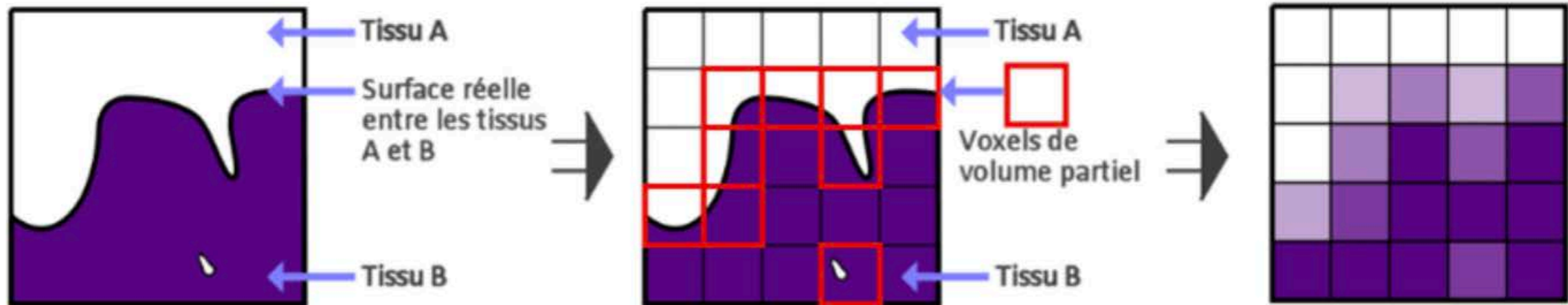
# 1. Défaut de saturation



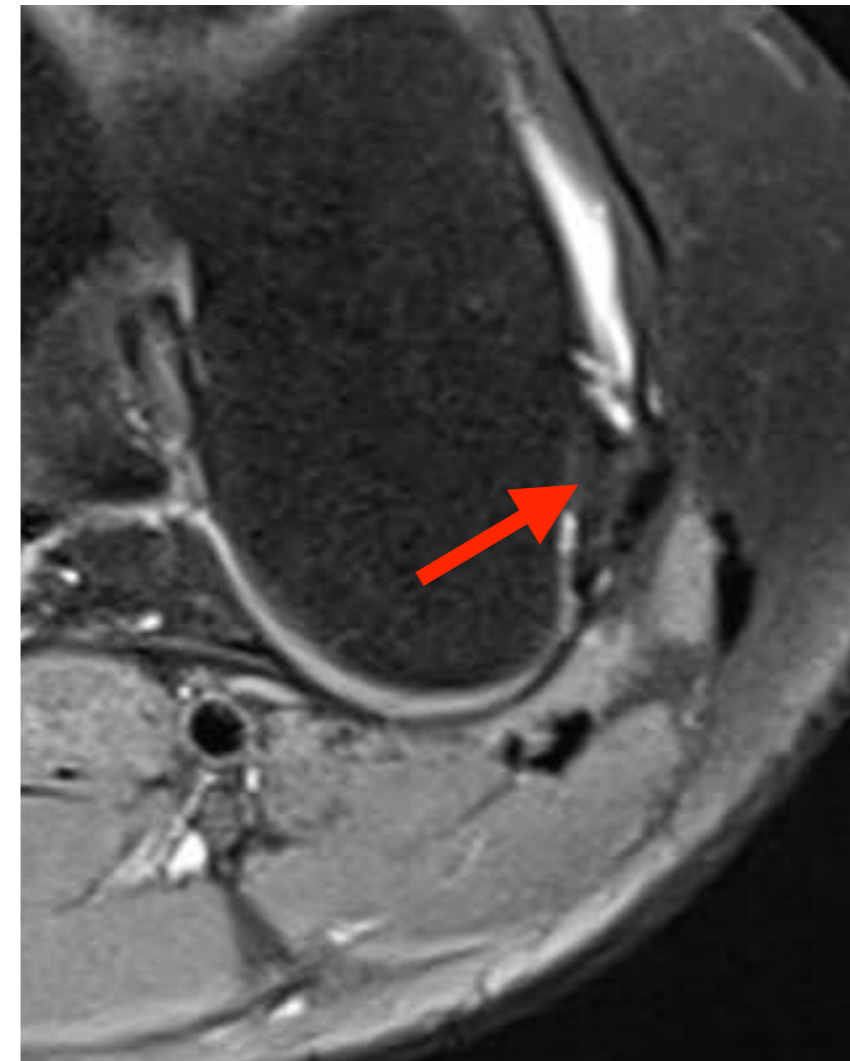
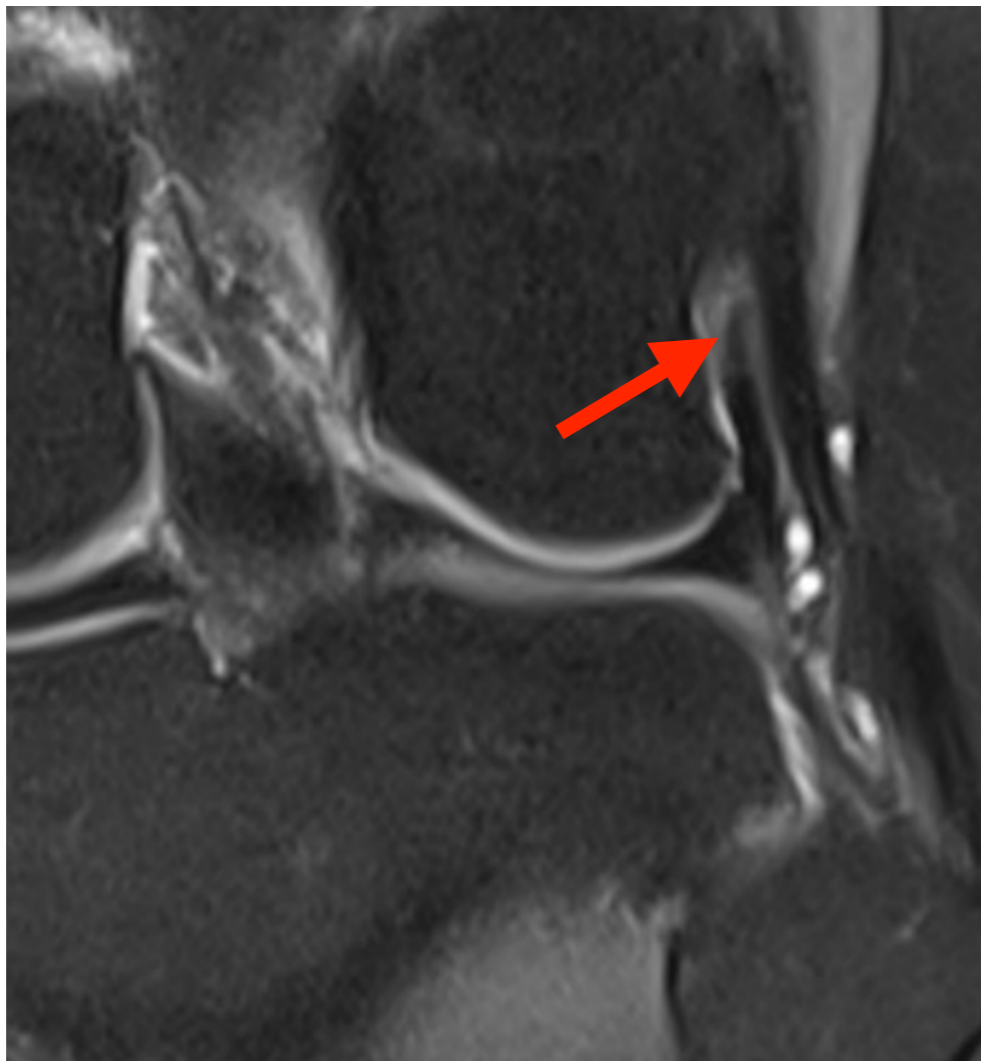
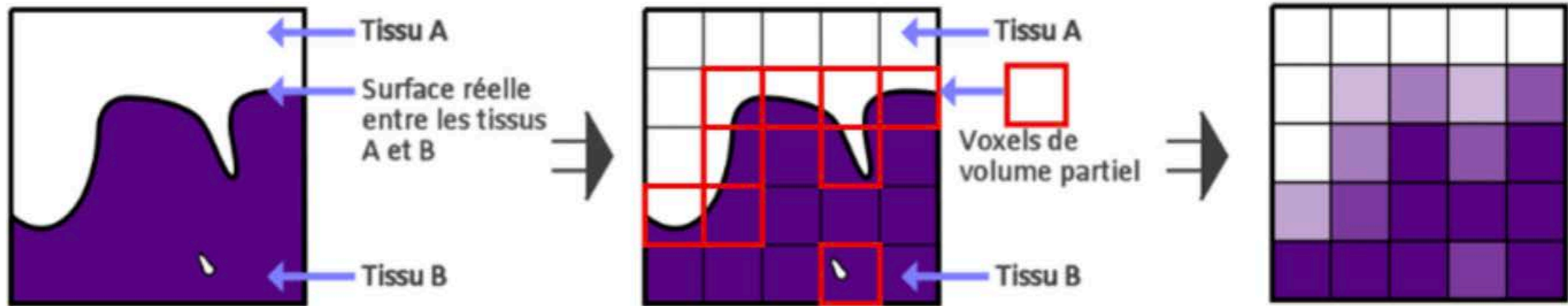
# 1. Volume partiel



# 1. Volume partiel

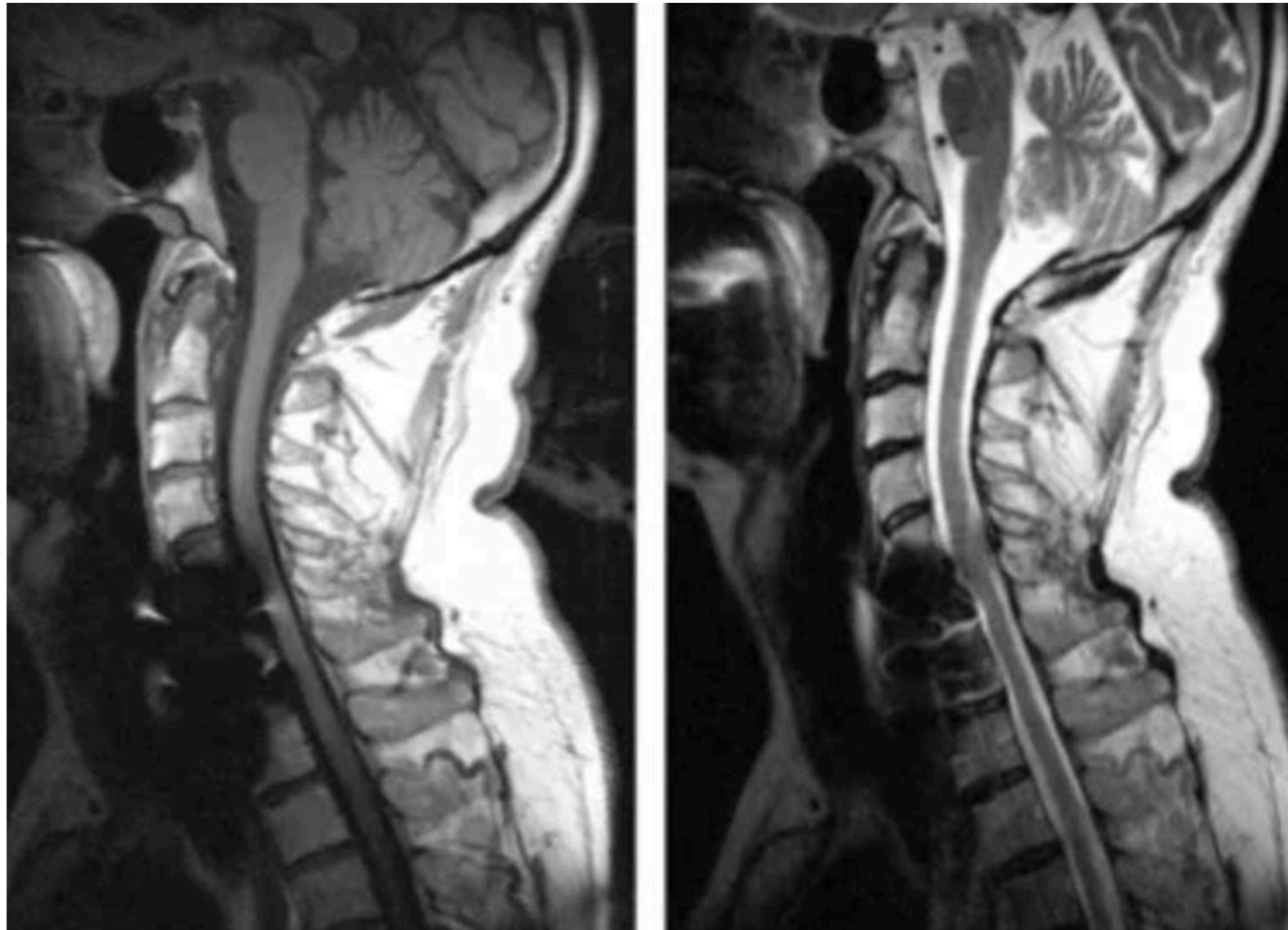


# 1. Volume partiel





# 1. Artefacts Métalliques



# 1. DIXON

Réduction des artefacts métalliques

Réduction des défauts de saturation de la graisse

Imagerie SANS et AVEC graisse

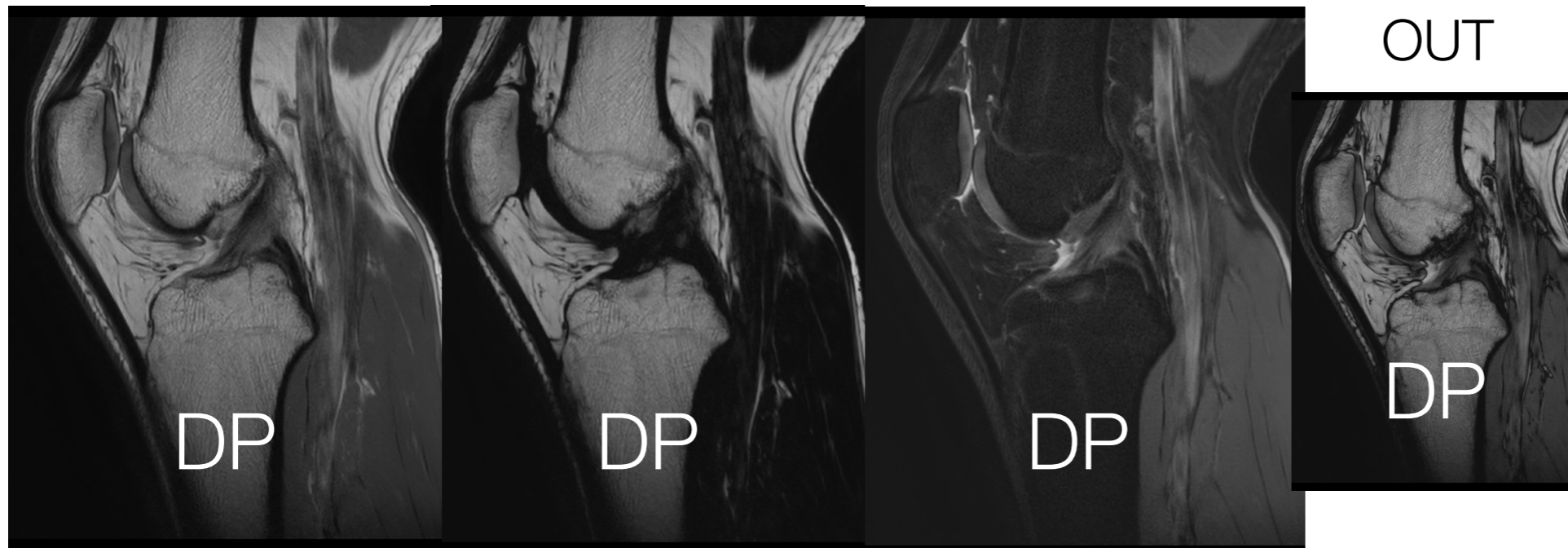
**IN PHASE**

**FAT**

**WATER**

Suppression de

OUT



# 1. DIXON

Réduction des artefacts métalliques

Réduction des défauts de saturation de la graisse

Imagerie SANS et AVEC graisse

Machine dépendant

Sensible aux Mvts

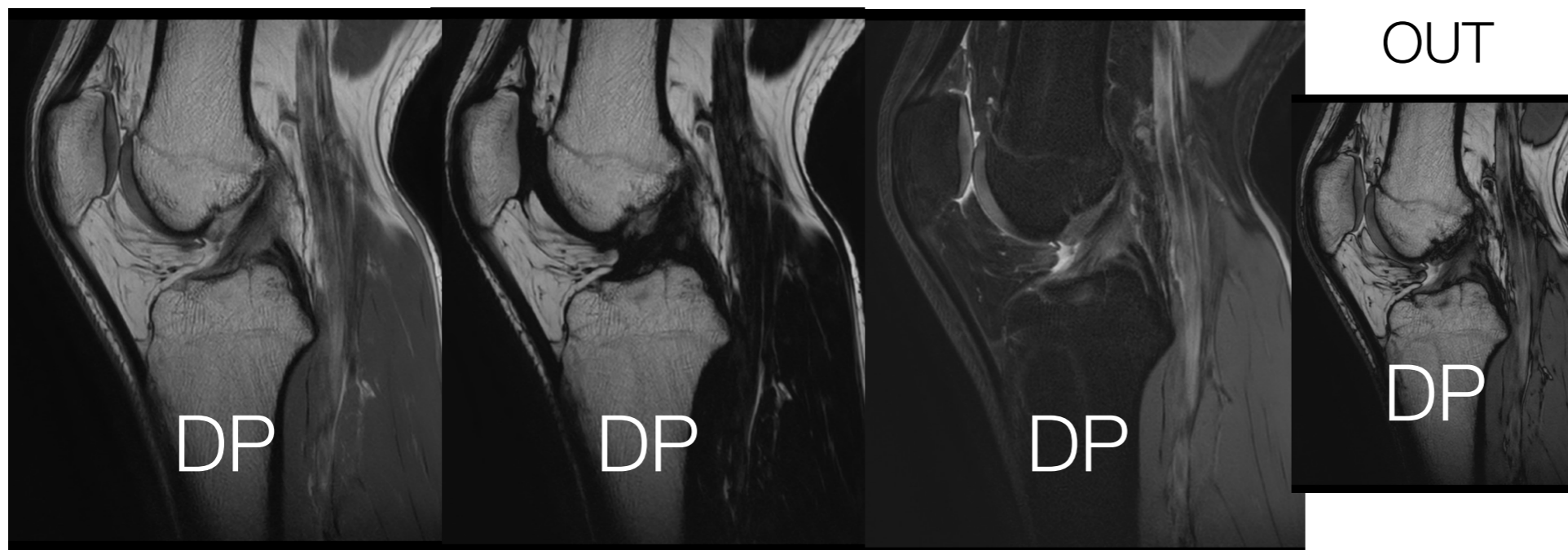
**IN PHASE**

**FAT**

**WATER**

Suppression de

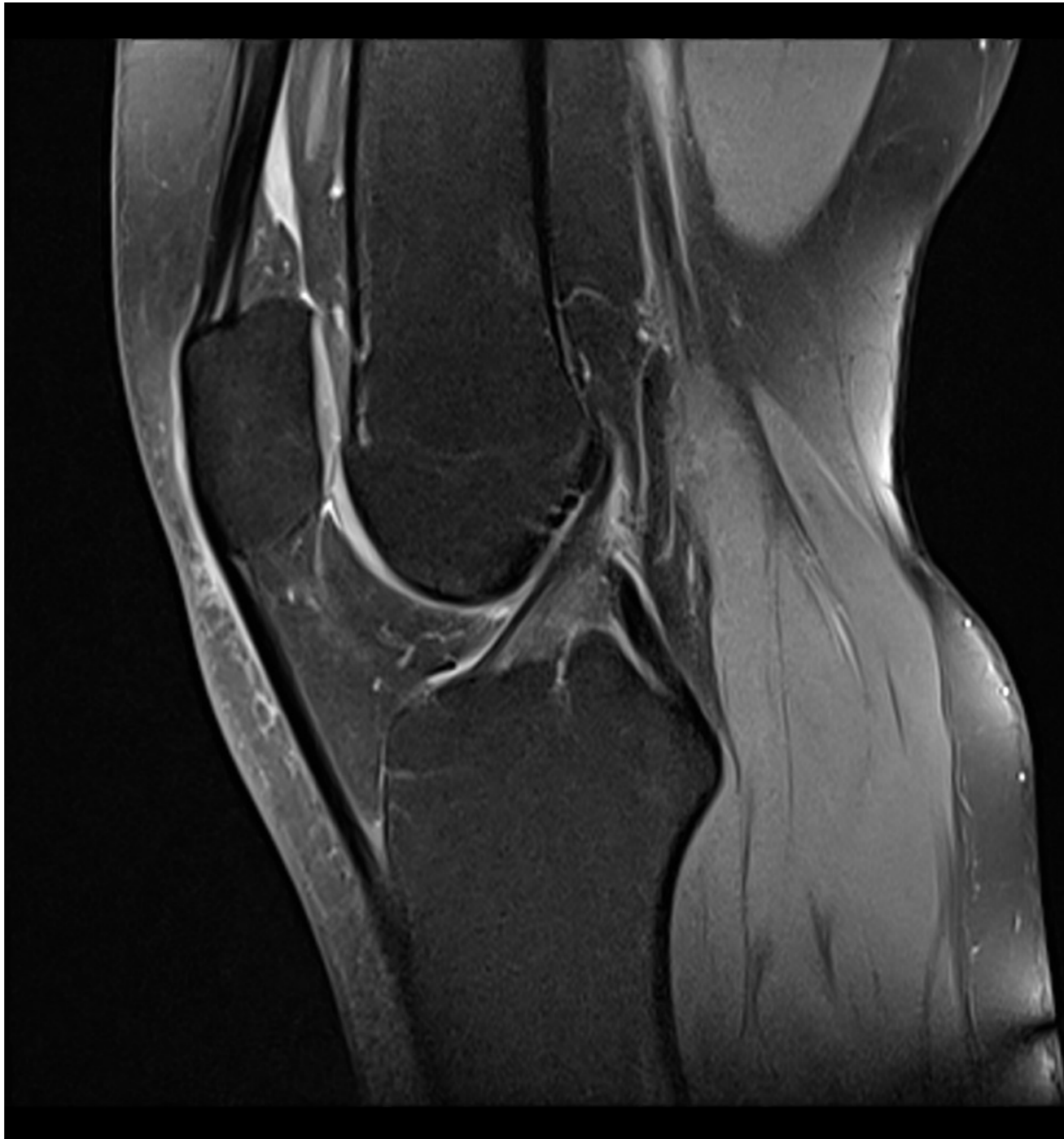OUT



## **2. Pivot central**

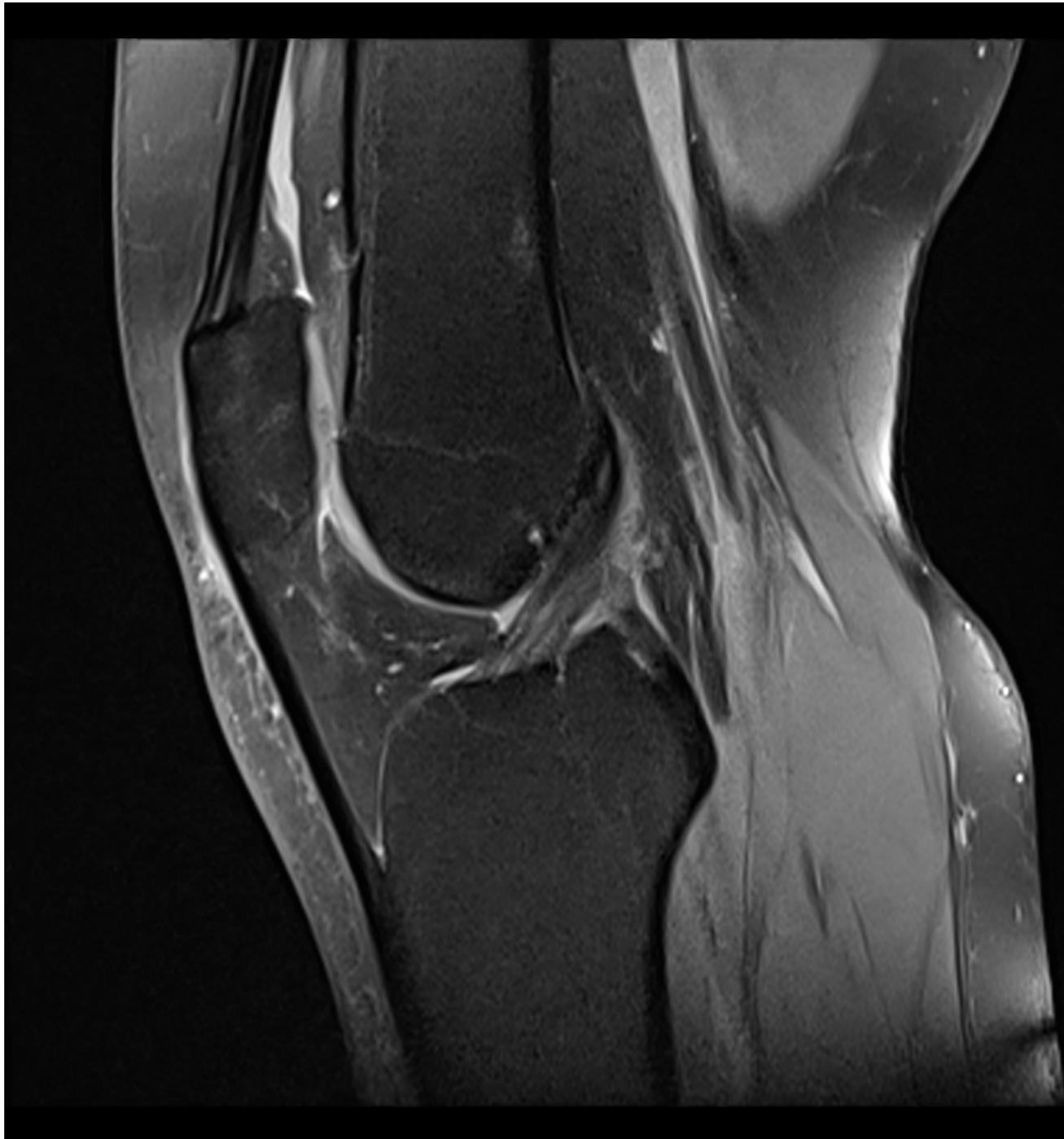
## 2. LCA normal

- LCA : aspect normal visible sur plusieurs coupes



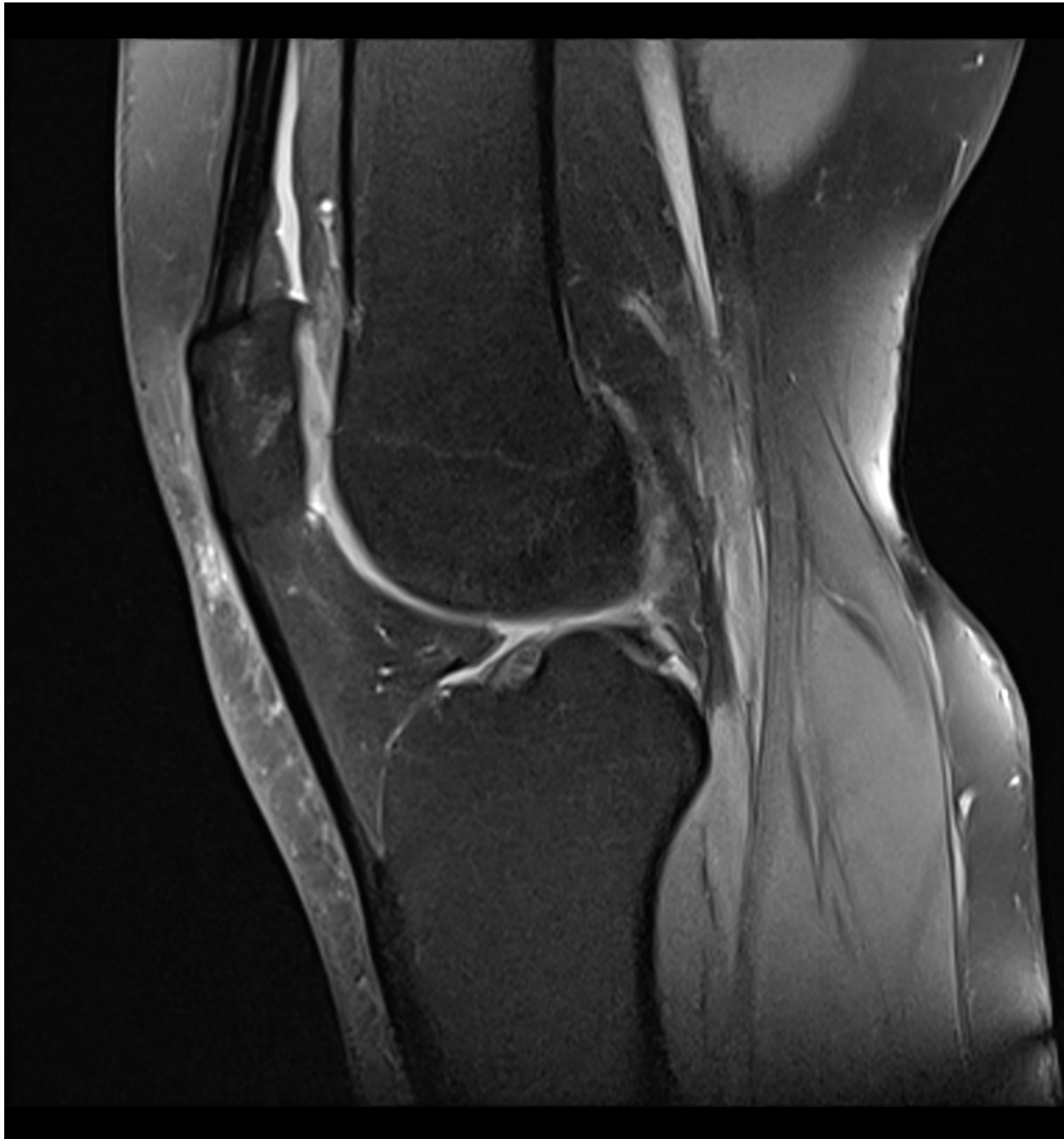## 2. LCA normal

- LCA : aspect normal visible sur plusieurs coupes



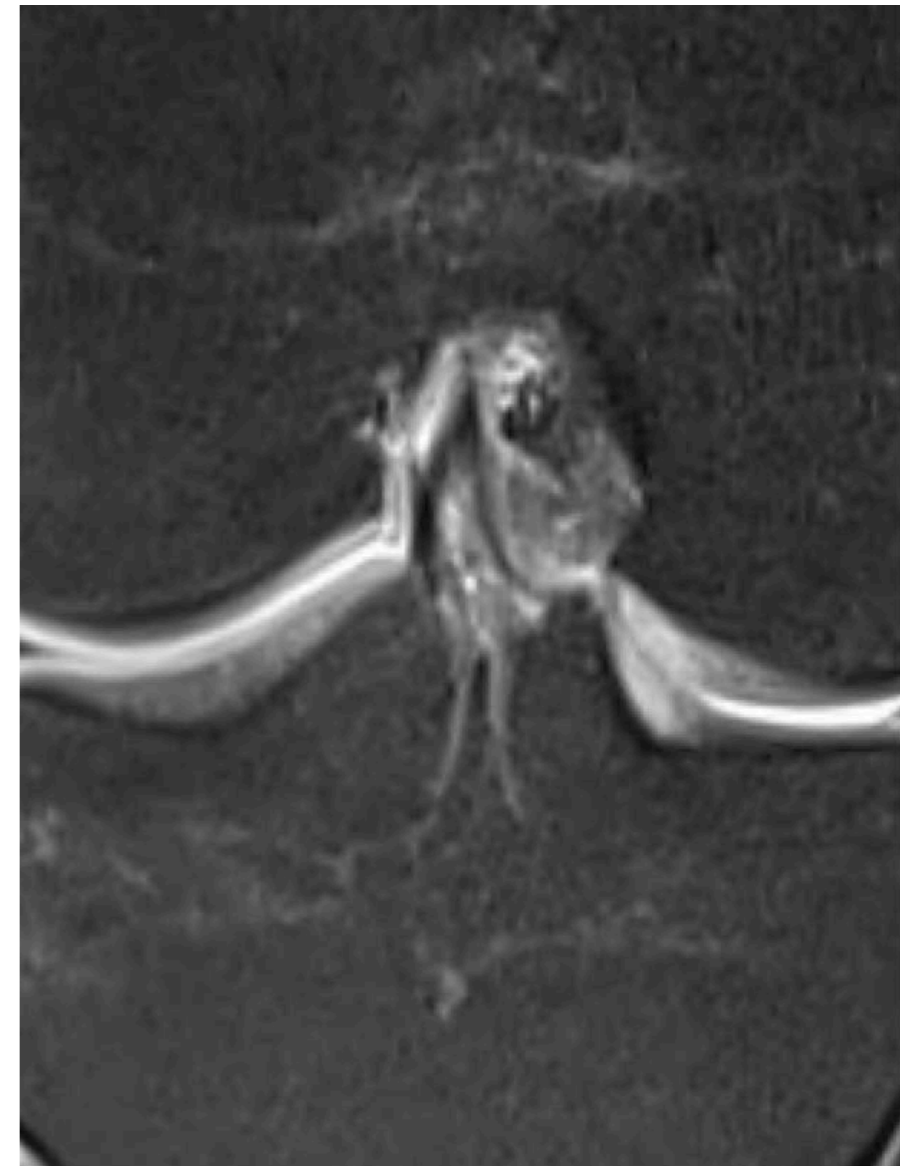
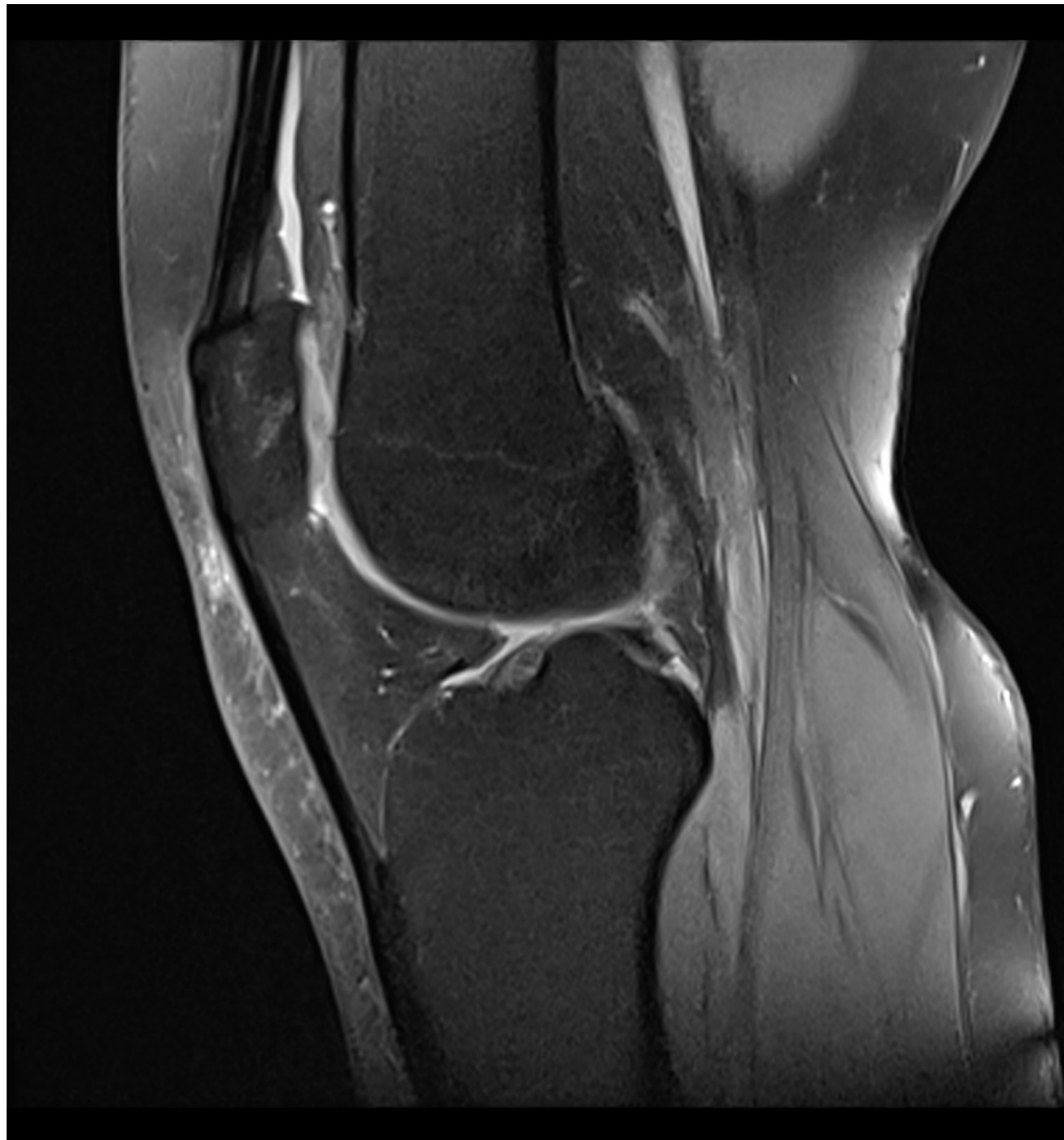## 2. LCA normal

- LCA : aspect normal visible sur plusieurs coupes



## 2. LCA normal

- LCA : aspect normal visible sur plusieurs coupes



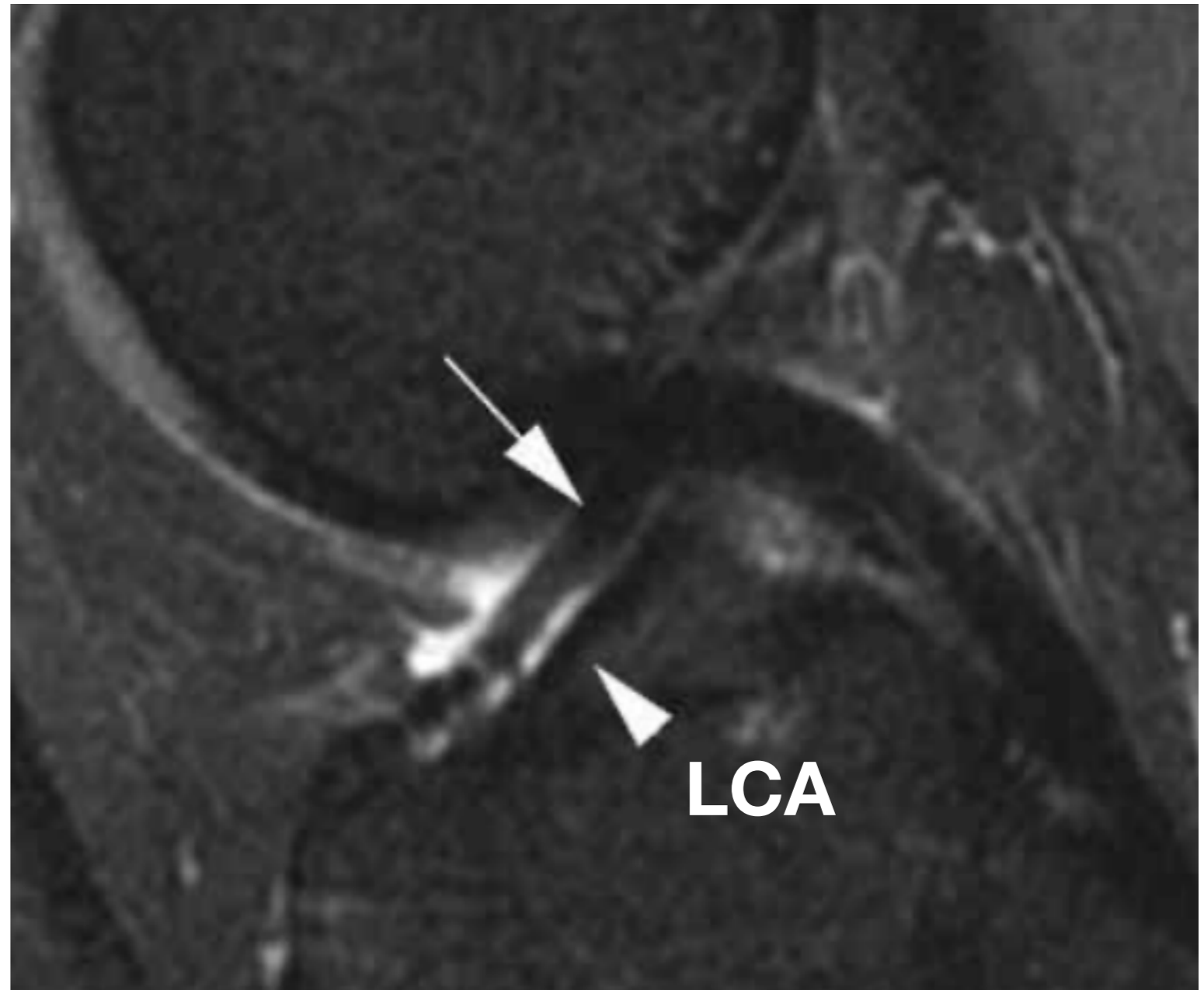


## 2. LCA normal

### **Pseudo DOUBLE LCA**

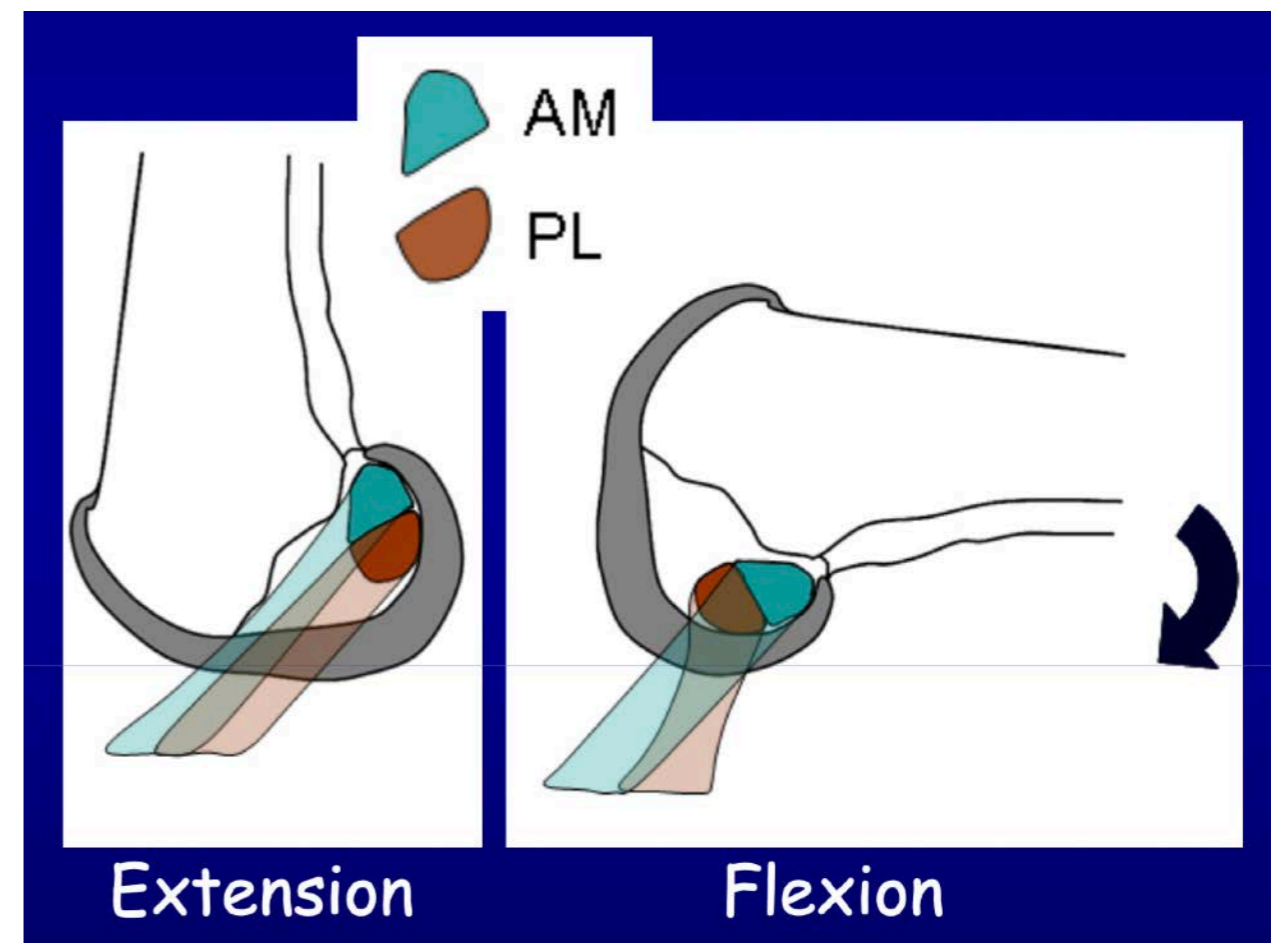
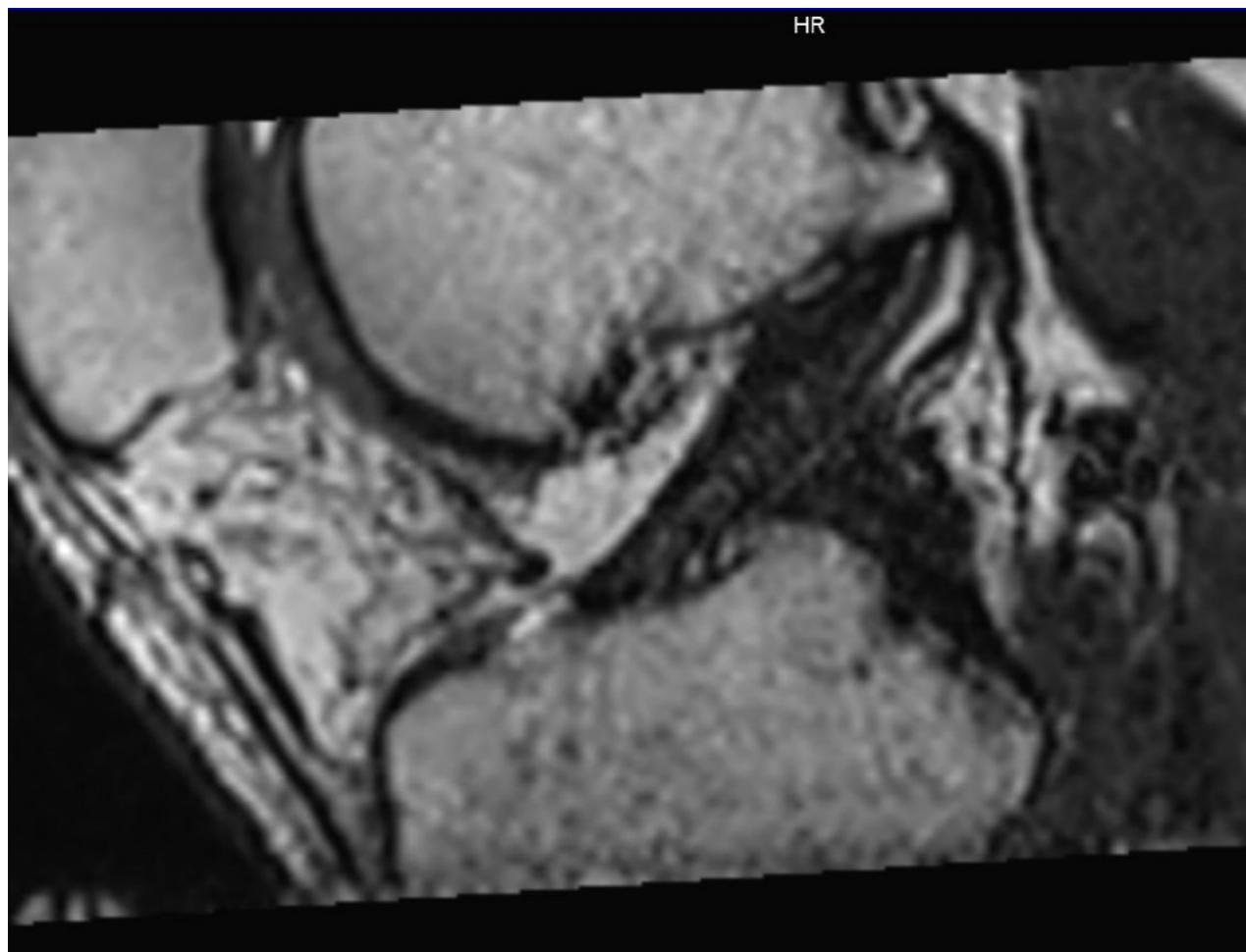
Plicae infra patellaire

Ligament ménisco-fémoral  
antéro-médial

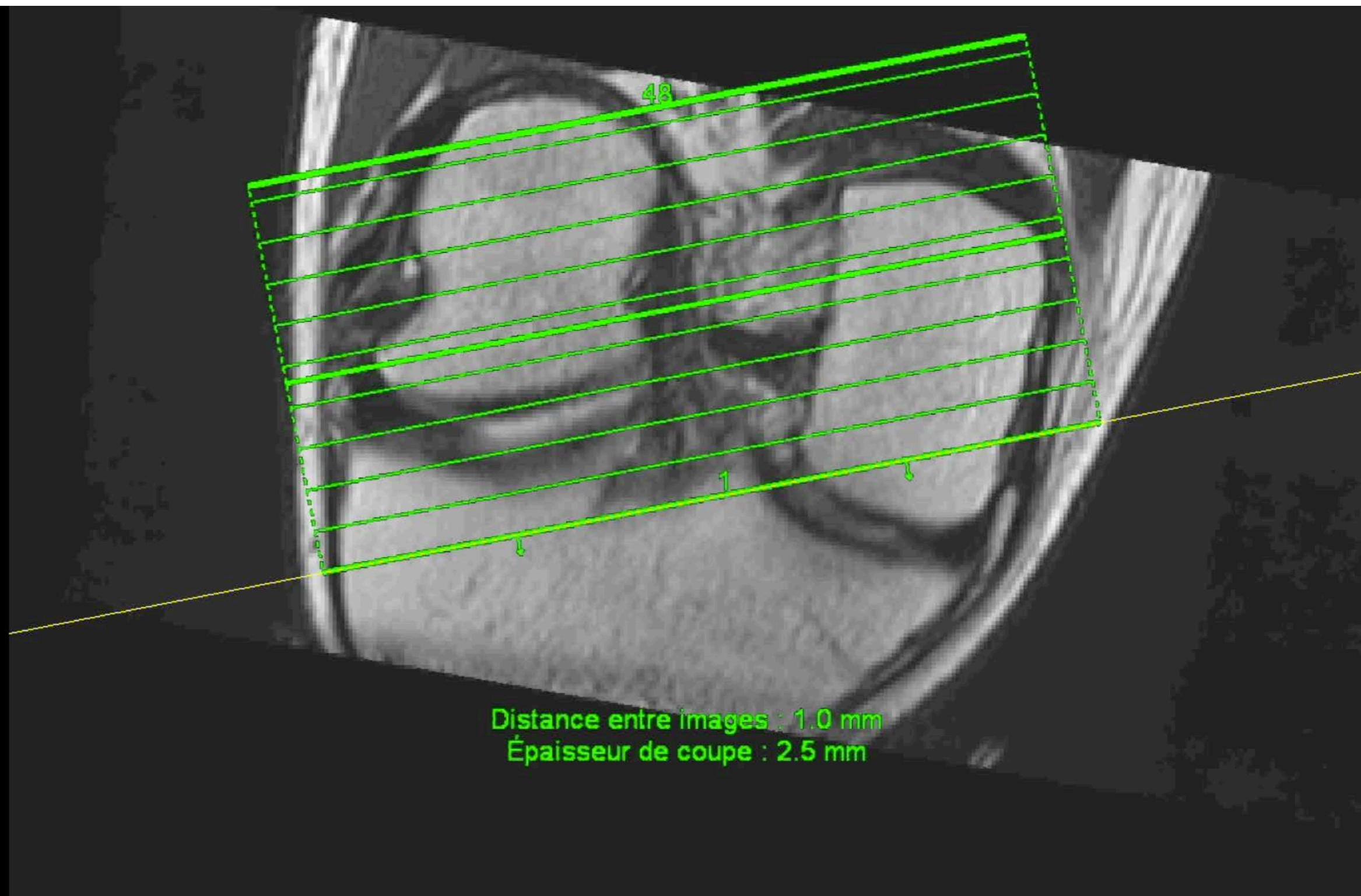


## 2. LCA normal

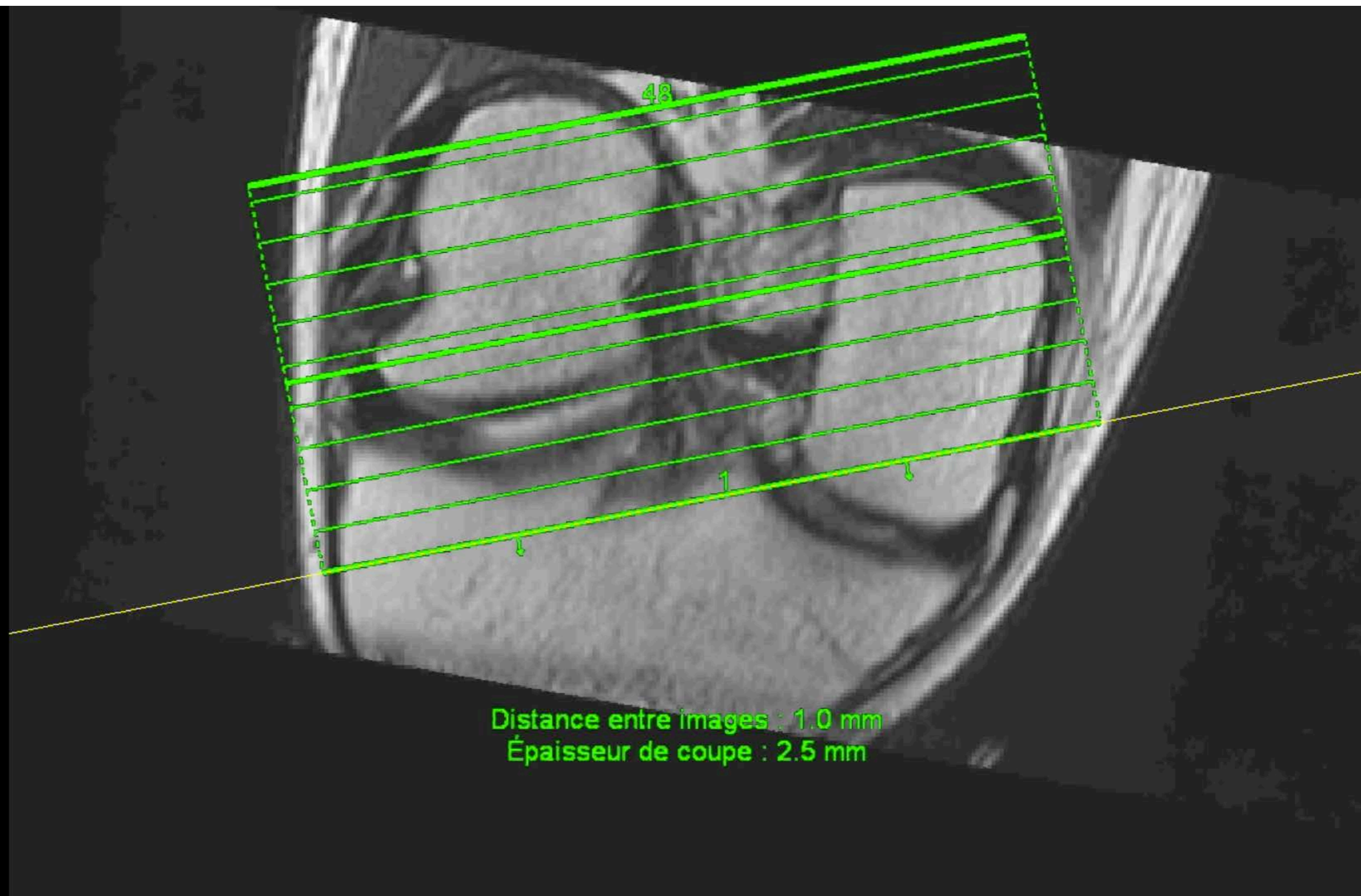
- 3D T2 : permet de reconstruire dans le plan du LCA avec individualisation de chaque faisceau



## 2. LCA normal

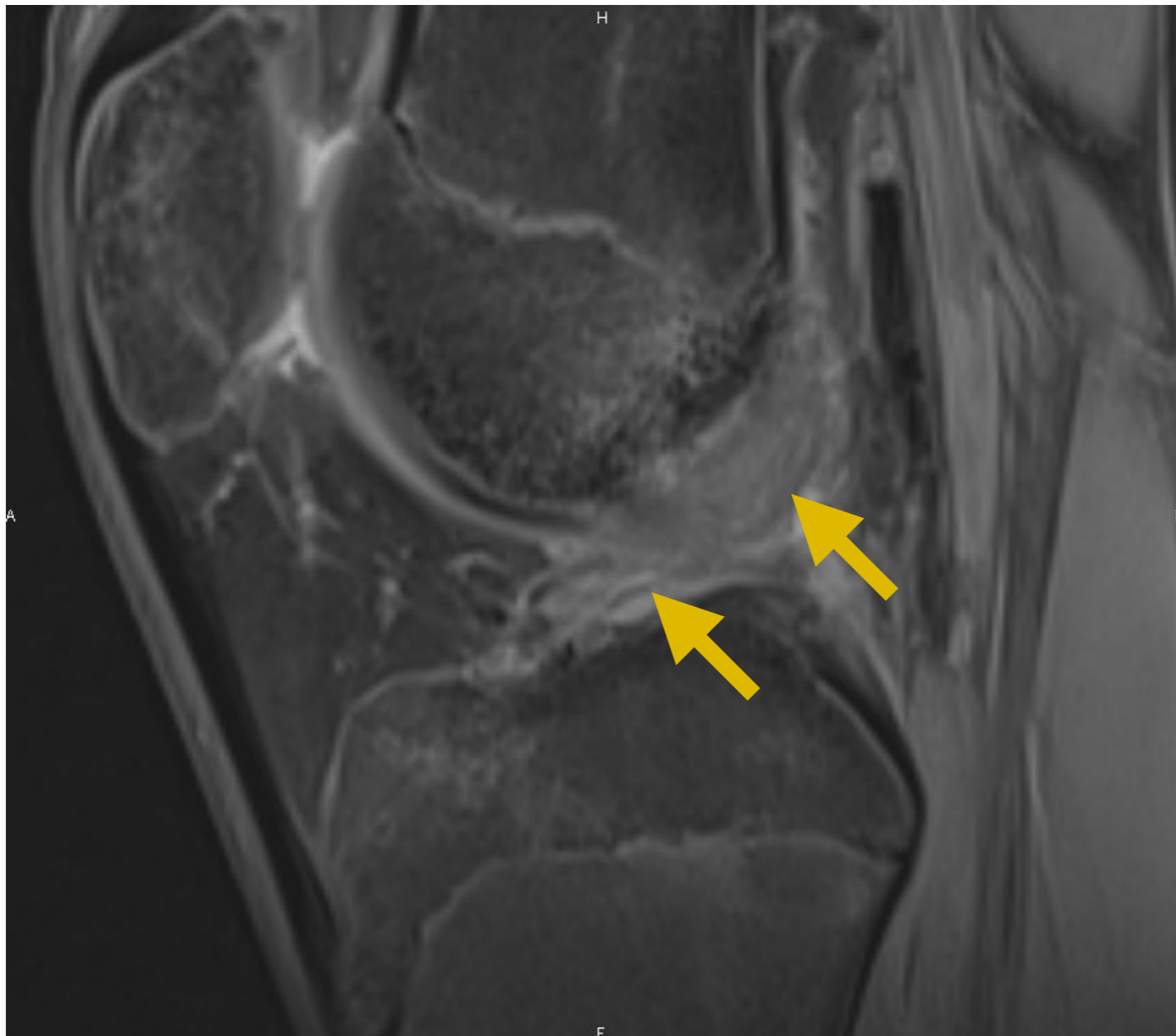

## 2. LCA normal



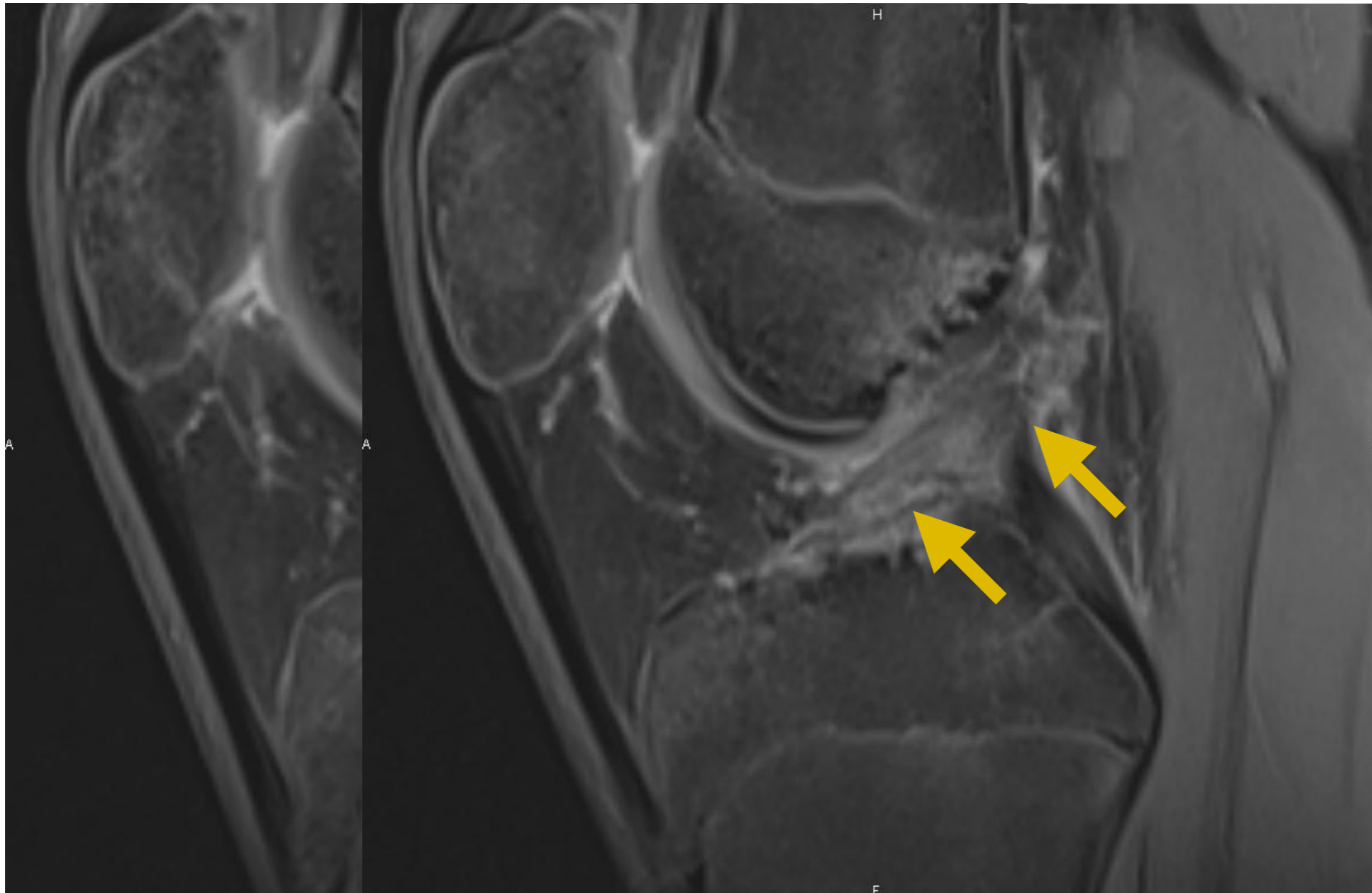
## 2. LCA

## Entorse Interstitielle



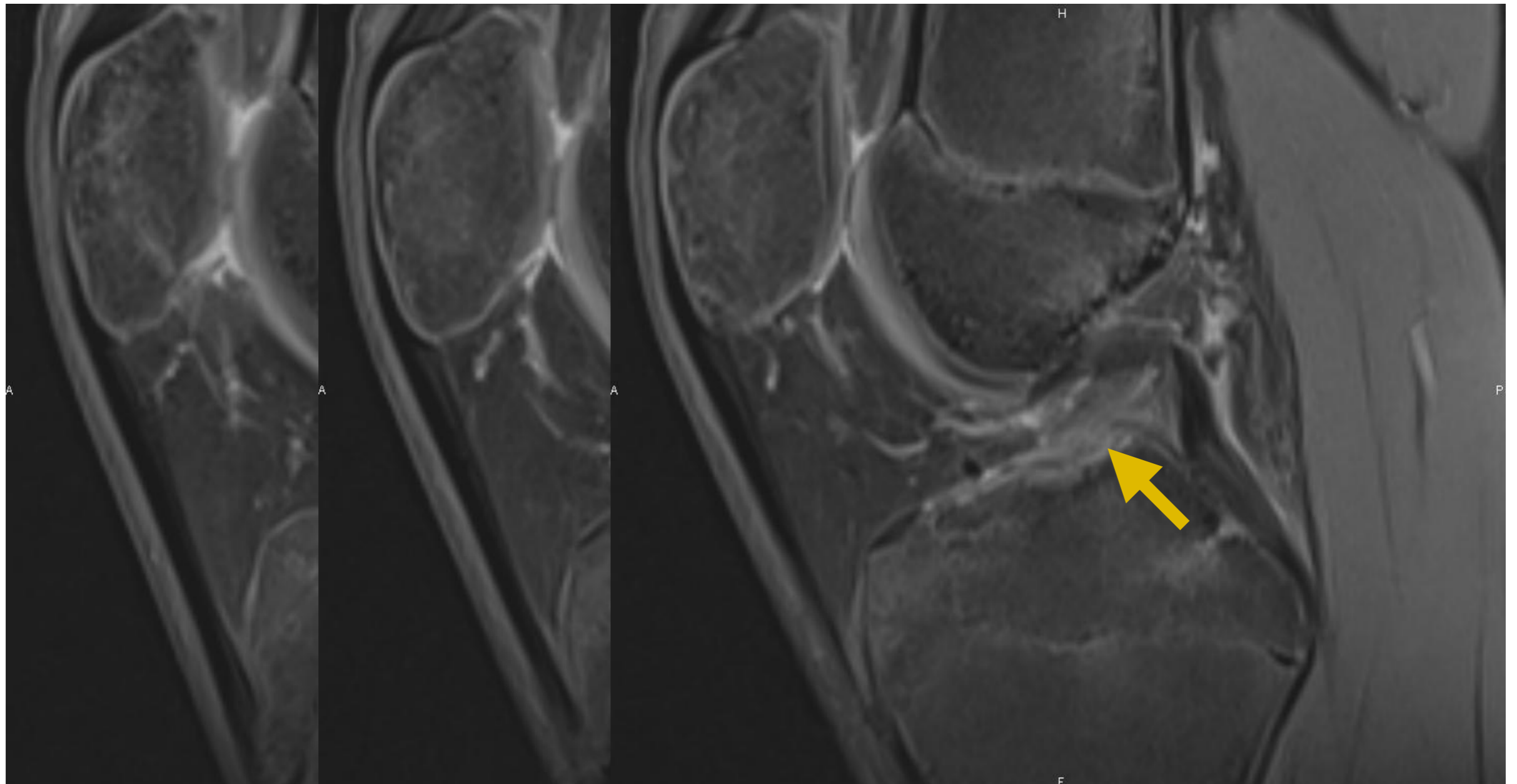
## 2. LCA

## Entorse Interstitielle



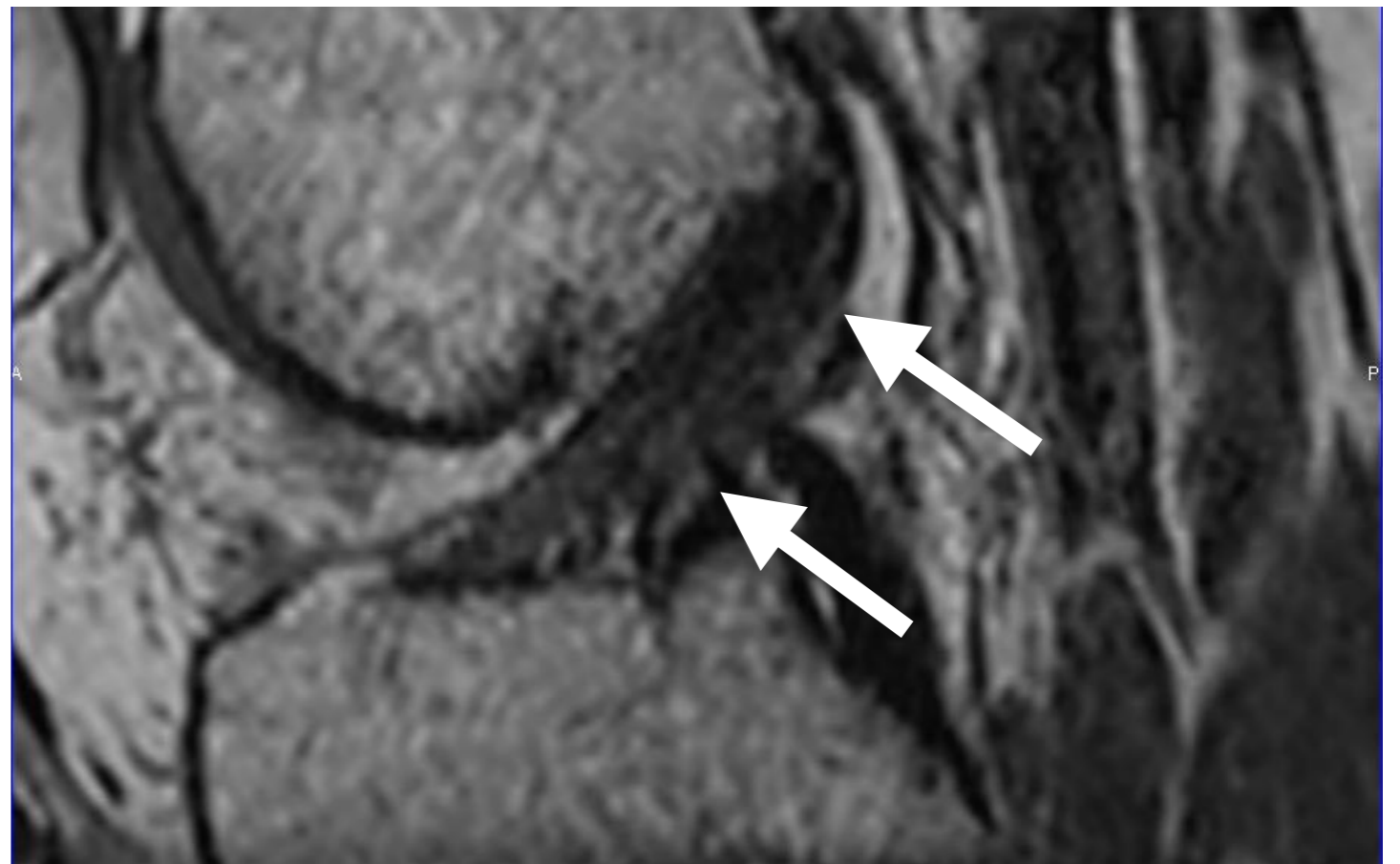
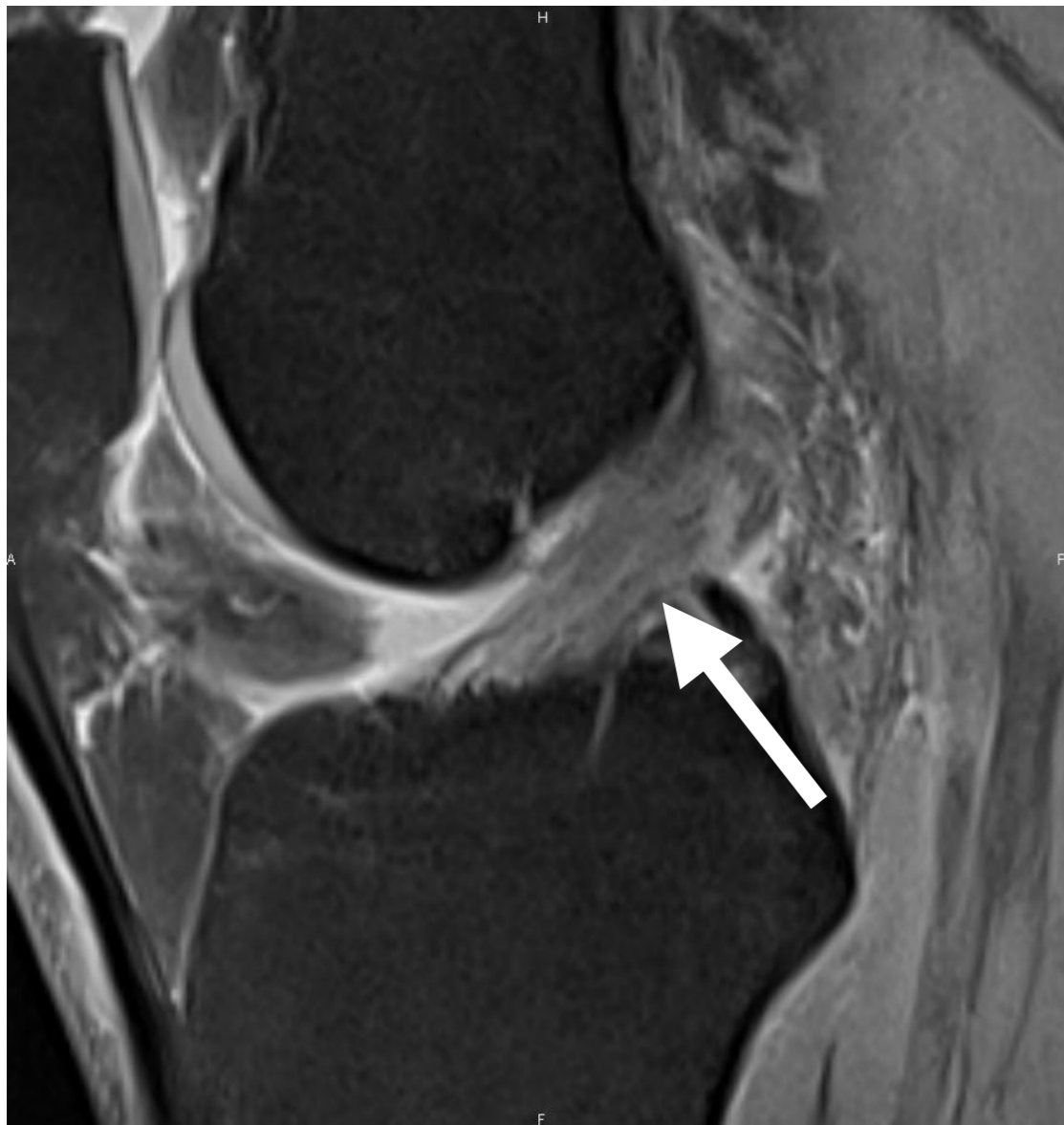## 2. LCA

## Entorse Interstitielle



## 2. LCA

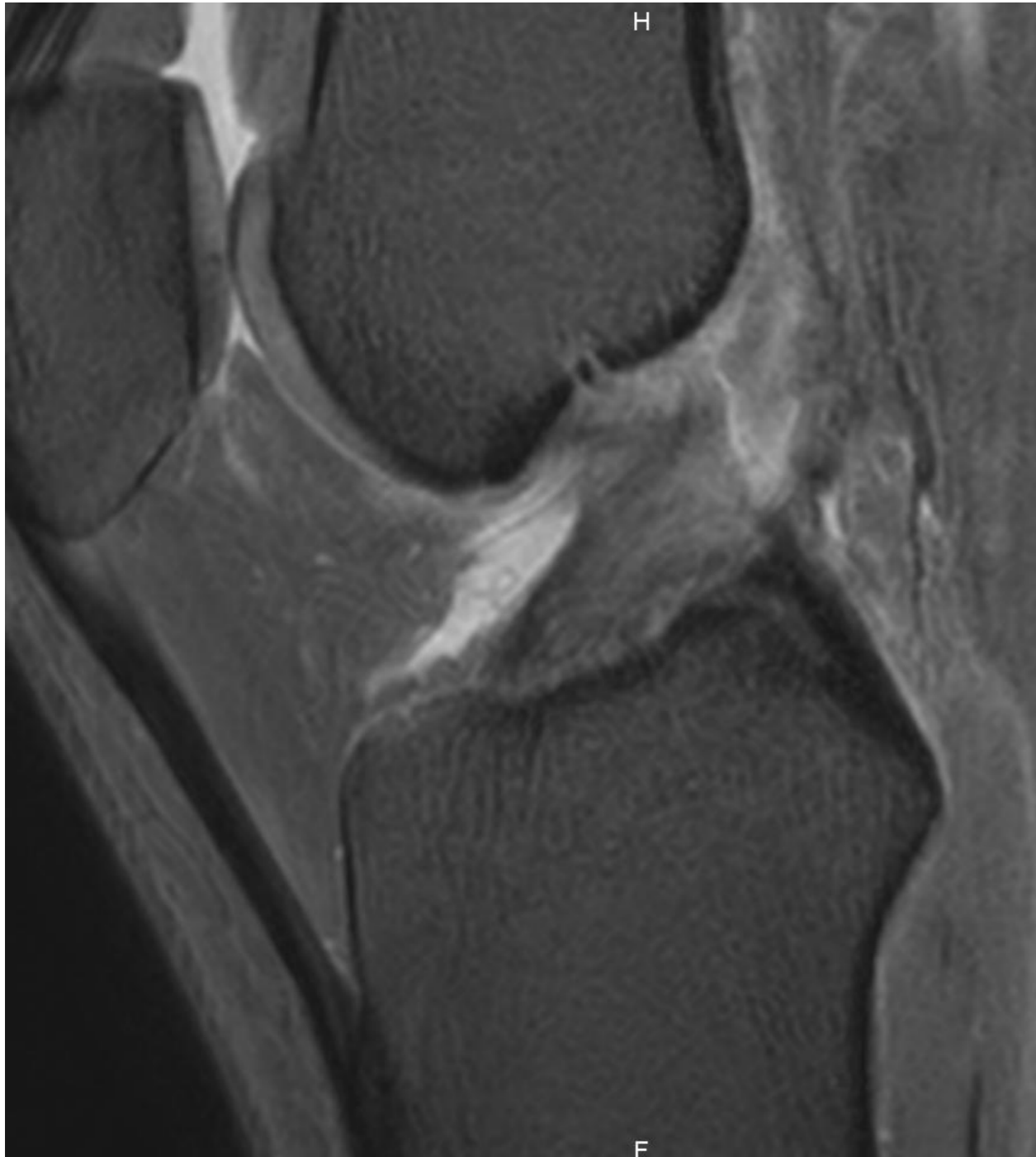
## Entorse Interstitielle





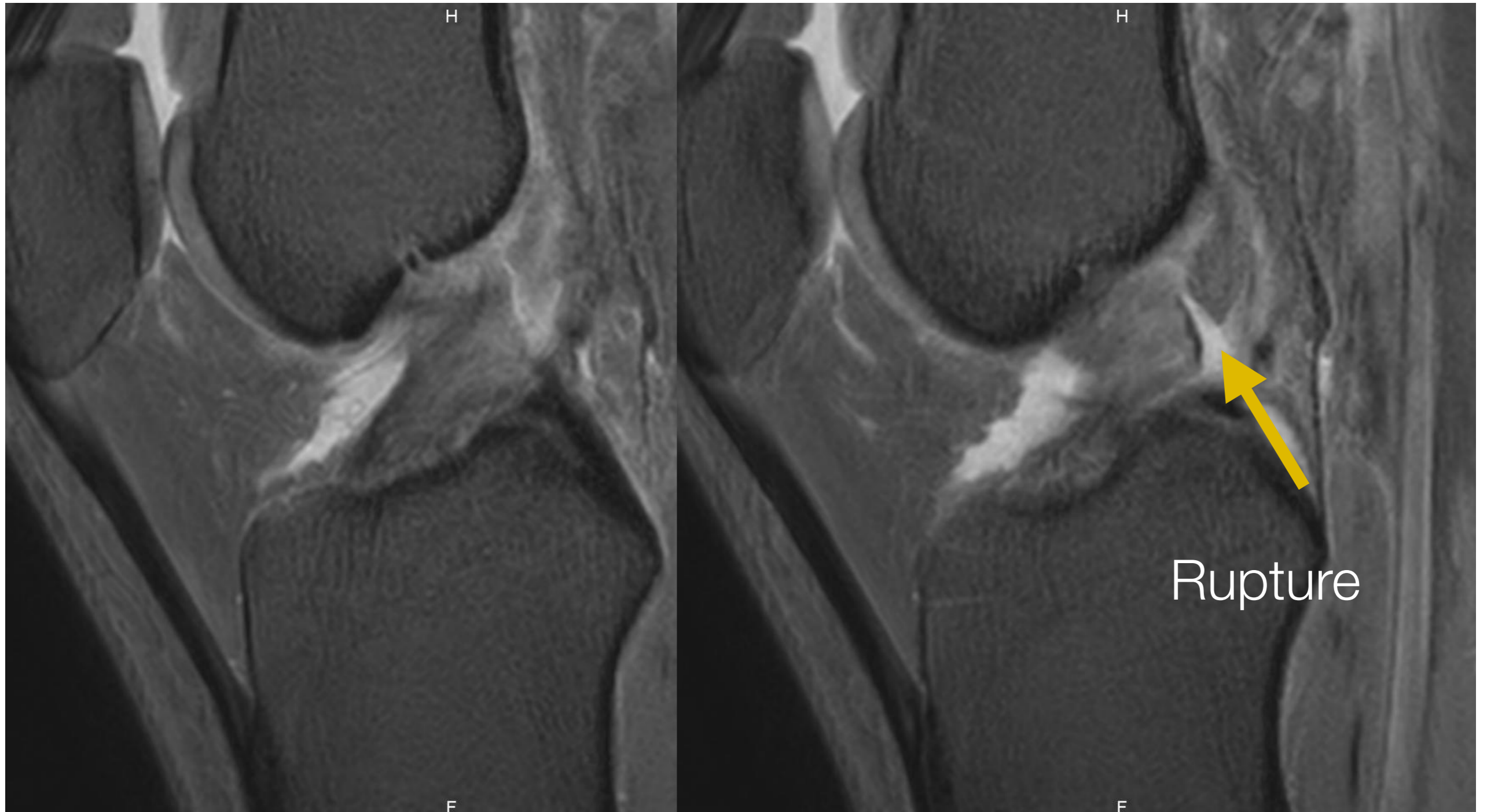
## 2. LCA

## Rupture Complète



## 2. LCA

## Rupture Complète



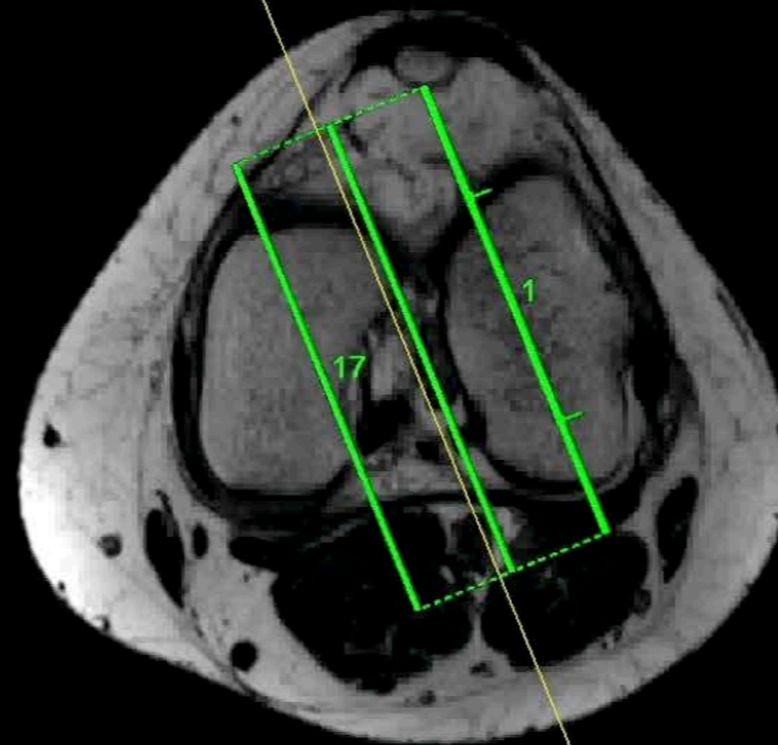
# 2. LCA

# Rupture Complète

dummyPatName!  
01-1960  
dummyPatID!  
XE: F  
om :1.0  
: 1010  
1/18  
:116.9

DummyInstName  
11-02-20  
11:31

Série actuelle  
AFL



Distance entre images : 2.0 mm  
Épaisseur de coupe : 2.0 mm

iv:  
: 0.3  
:1200.0  
: 152.0  
: 90.0  
:1859  
1069

DummySeriesDe  
Ingenia Elition

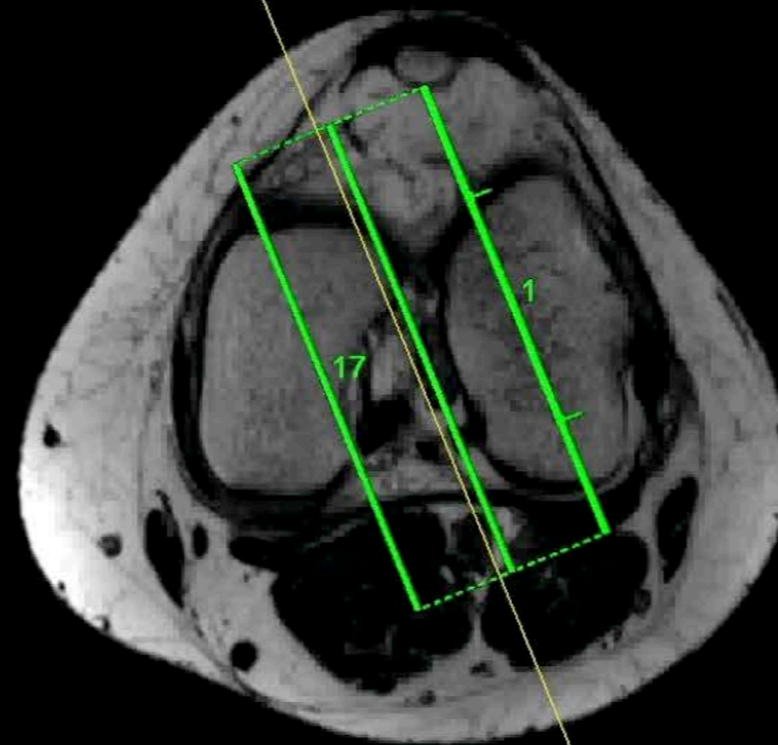
# 2. LCA

# Rupture Complète

dummyPatName!  
01-1960  
dummyPatID!  
XE: F  
om :1.0  
: 1010  
1/18  
:116.9

DummyInstName  
11-02-20  
11:31

Série actuelle  
AFL



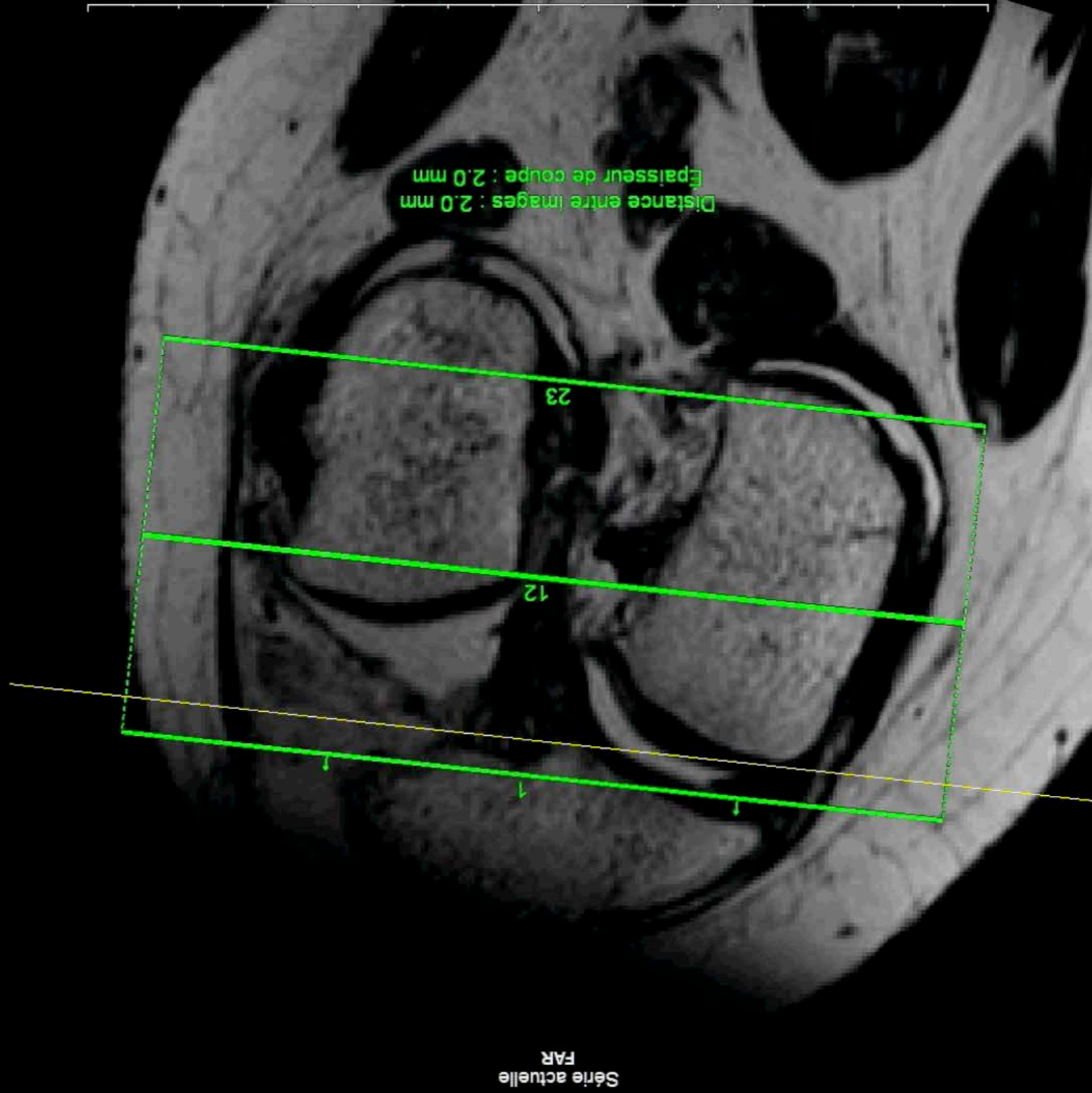
Distance entre images : 2.0 mm  
Épaisseur de coupe : 2.0 mm

iv:  
: 0.3  
:1200.0  
: 152.0  
: 90.0  
:1859  
1069

DummySeriesDe  
Ingenia Elition

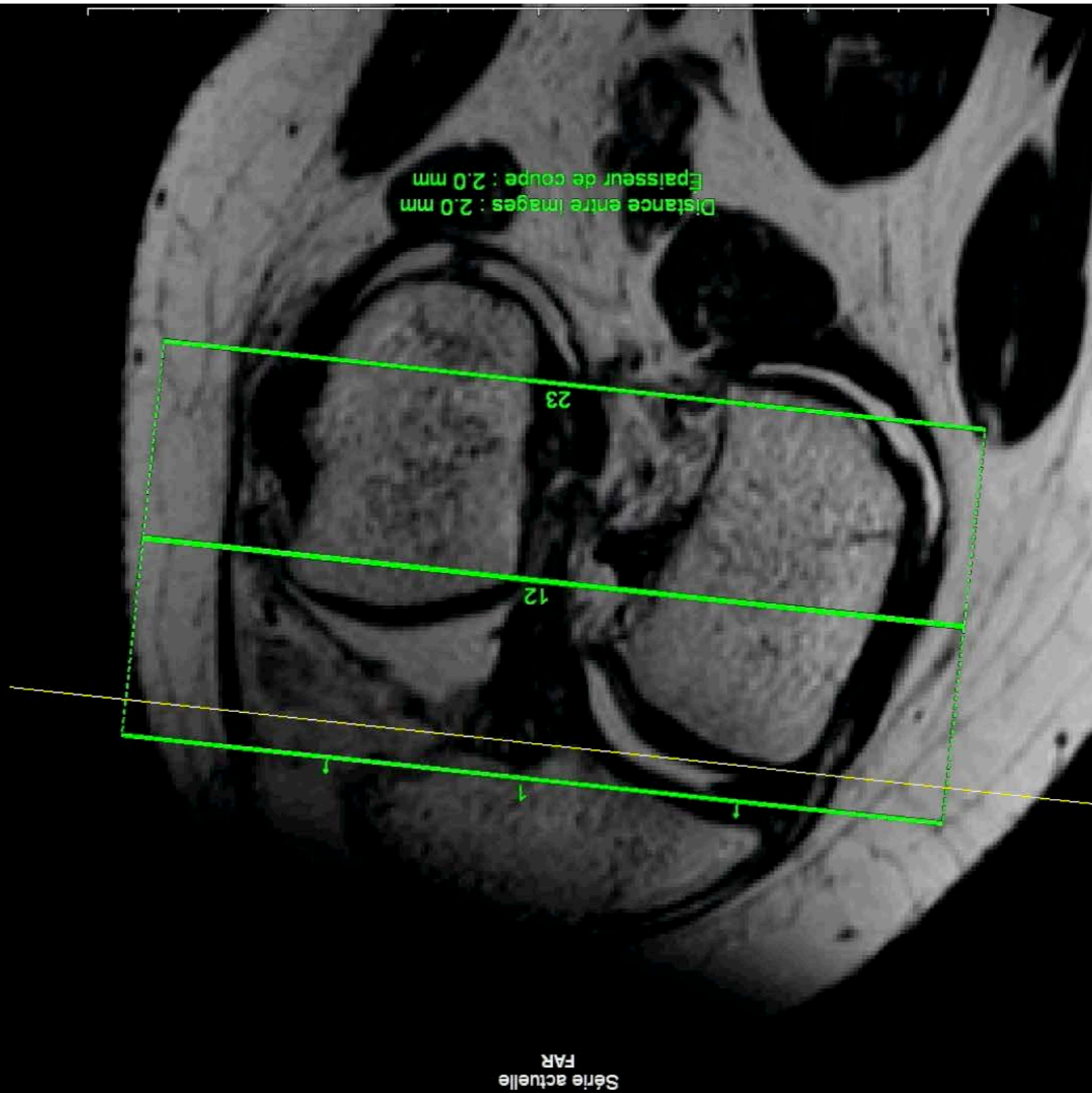
## 2. LCA

# Rupture Complète



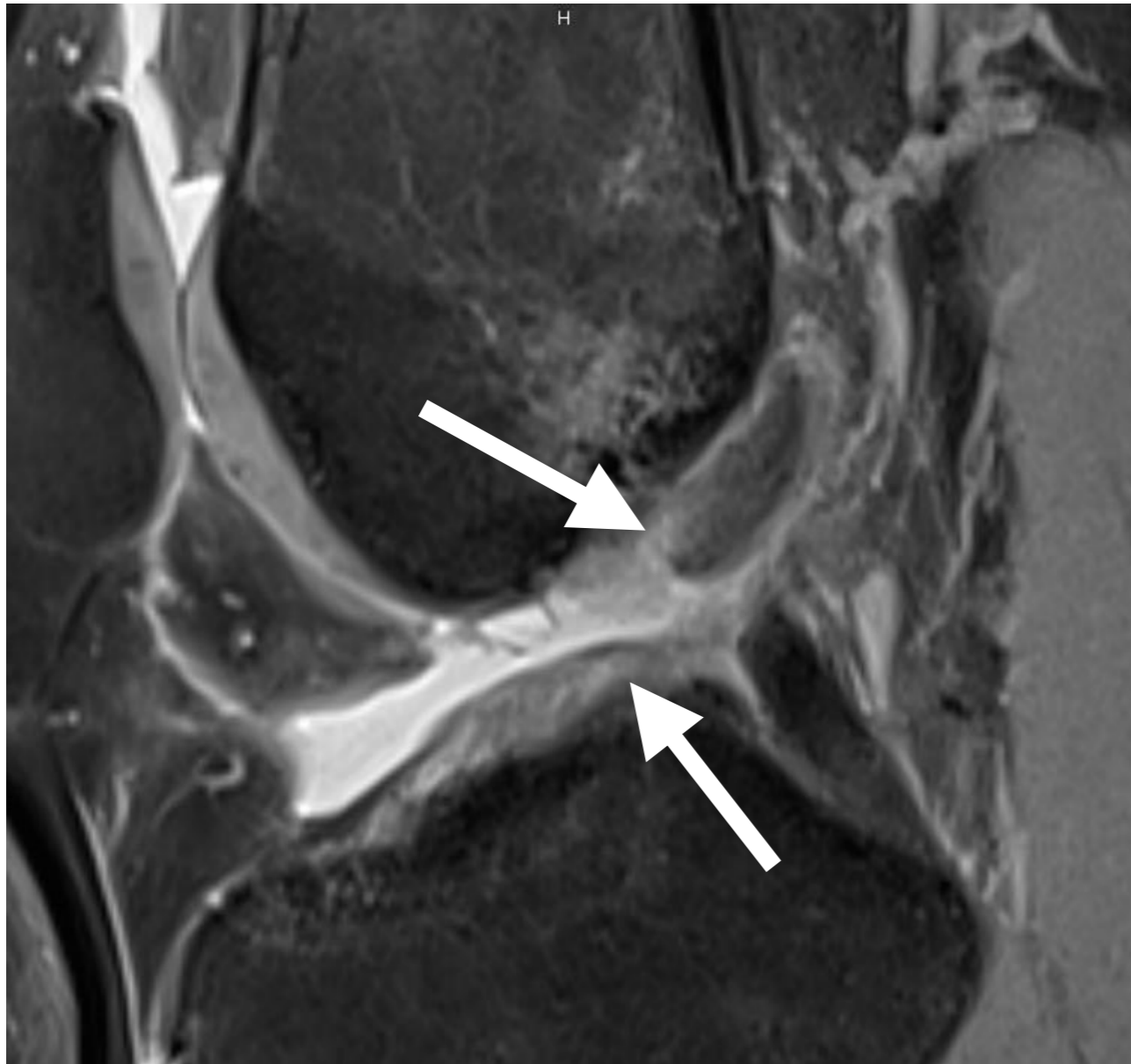
## 2. LCA

## Rupture Complète



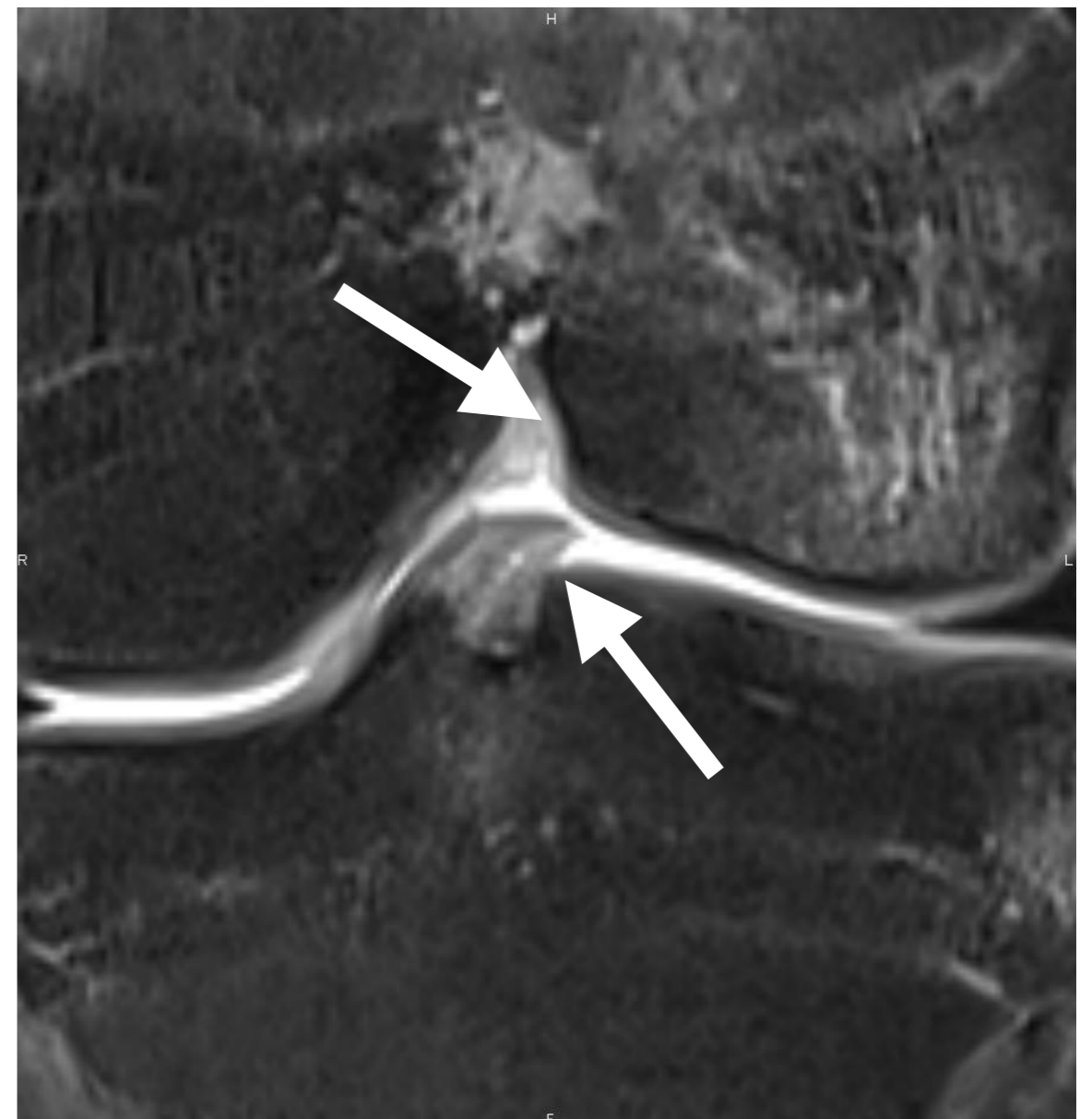
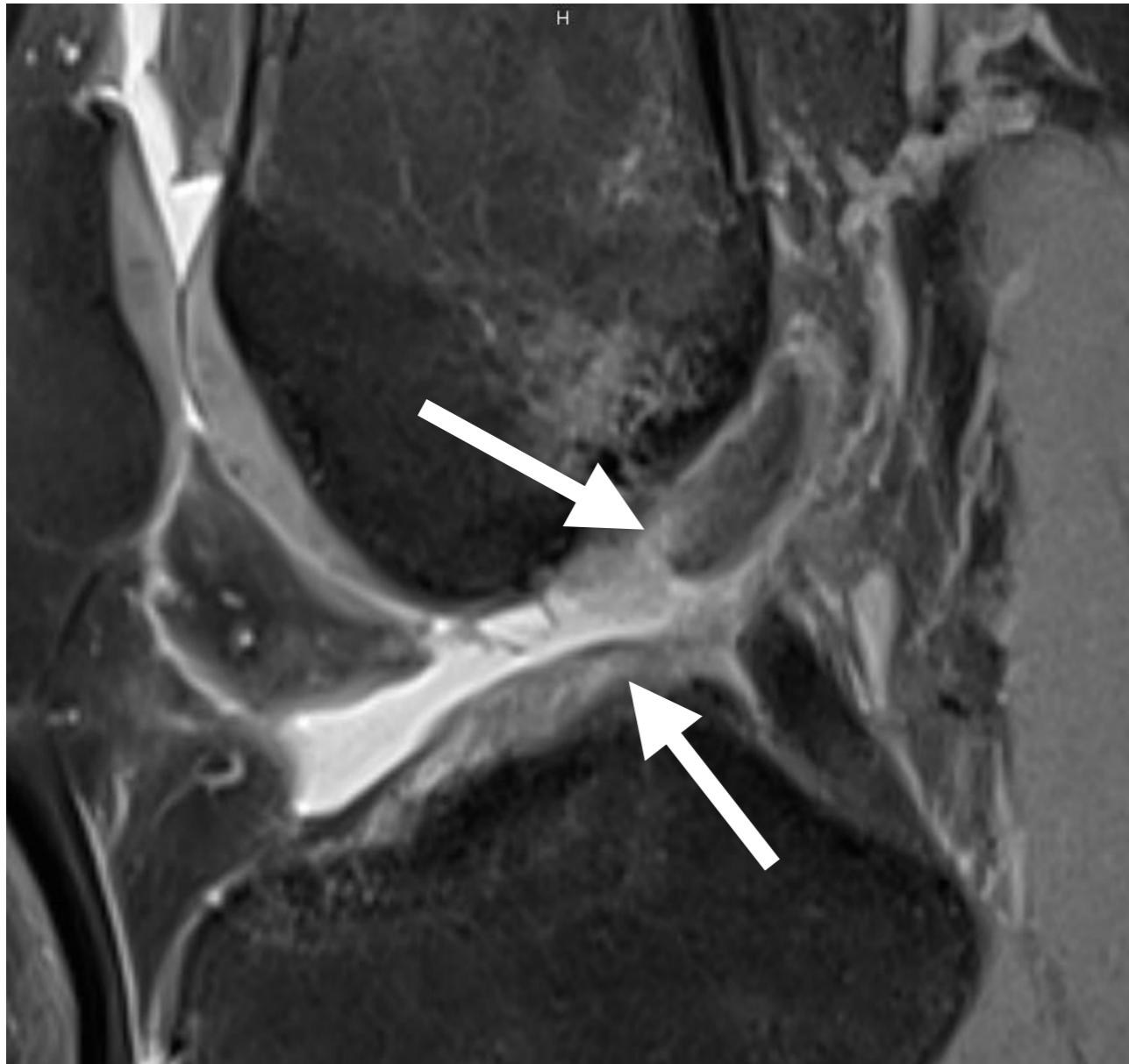
## 2. LCA

## Rupture Complète



## 2. LCA

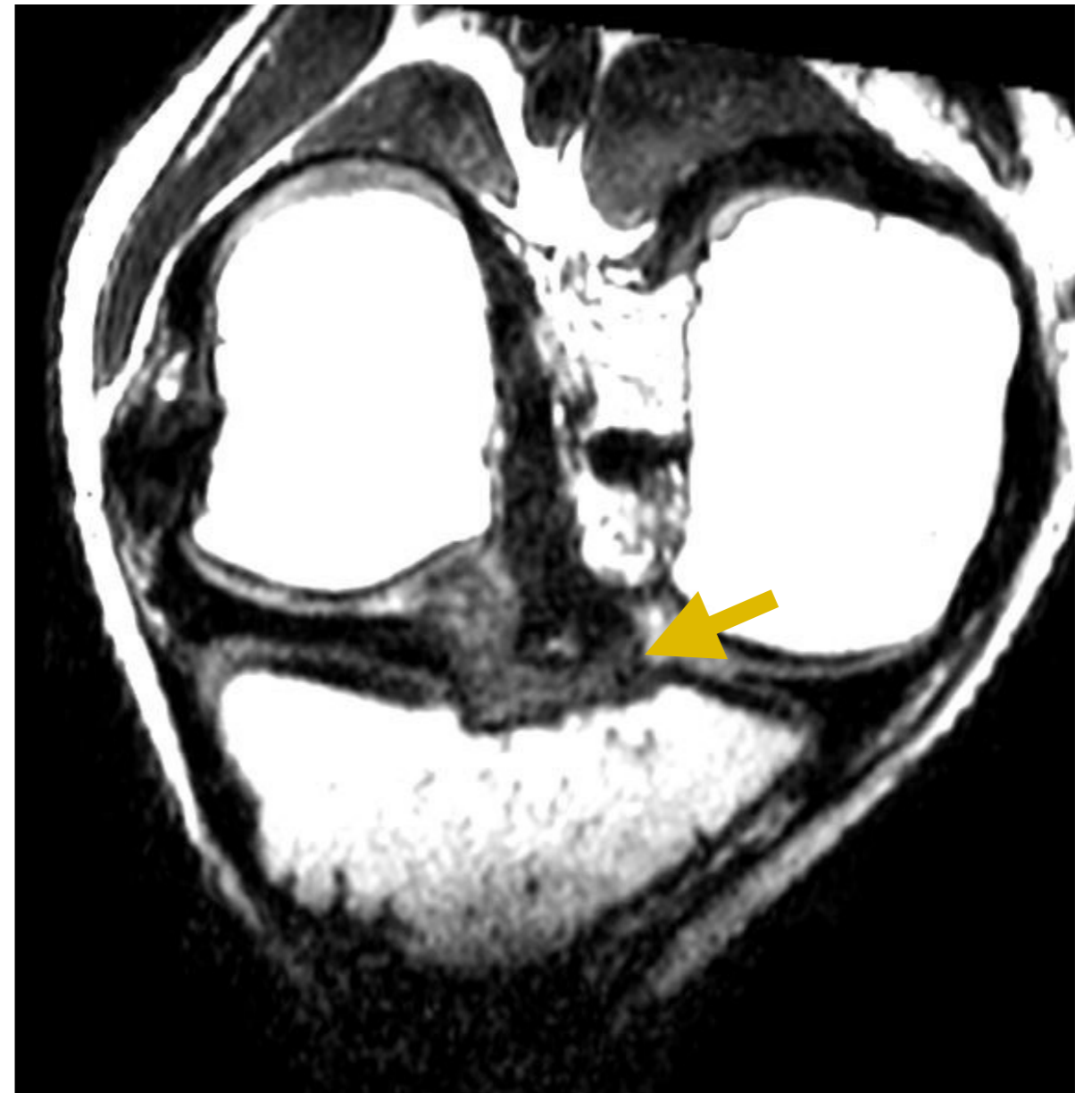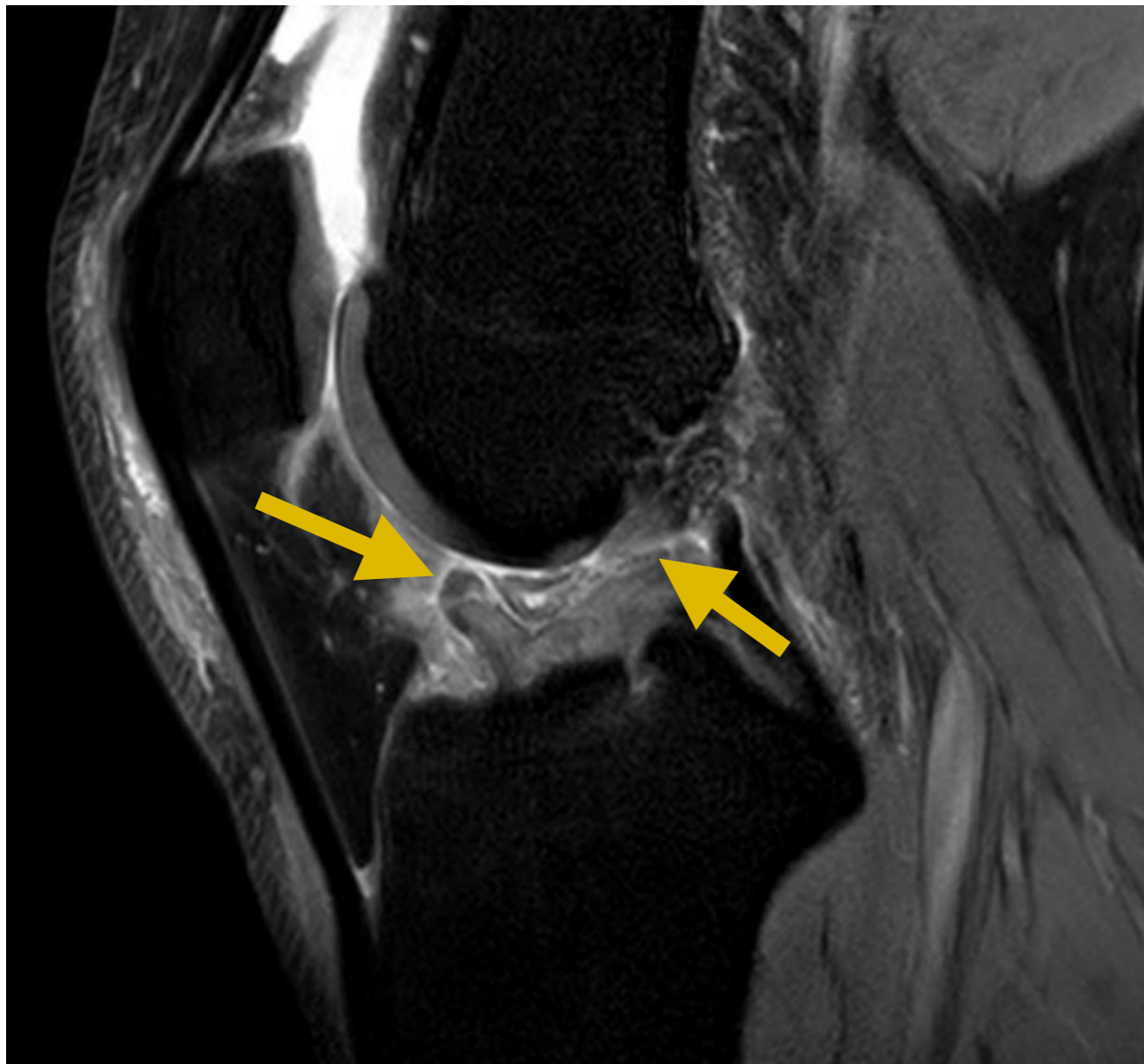
## Rupture Complète





## 2. LCA

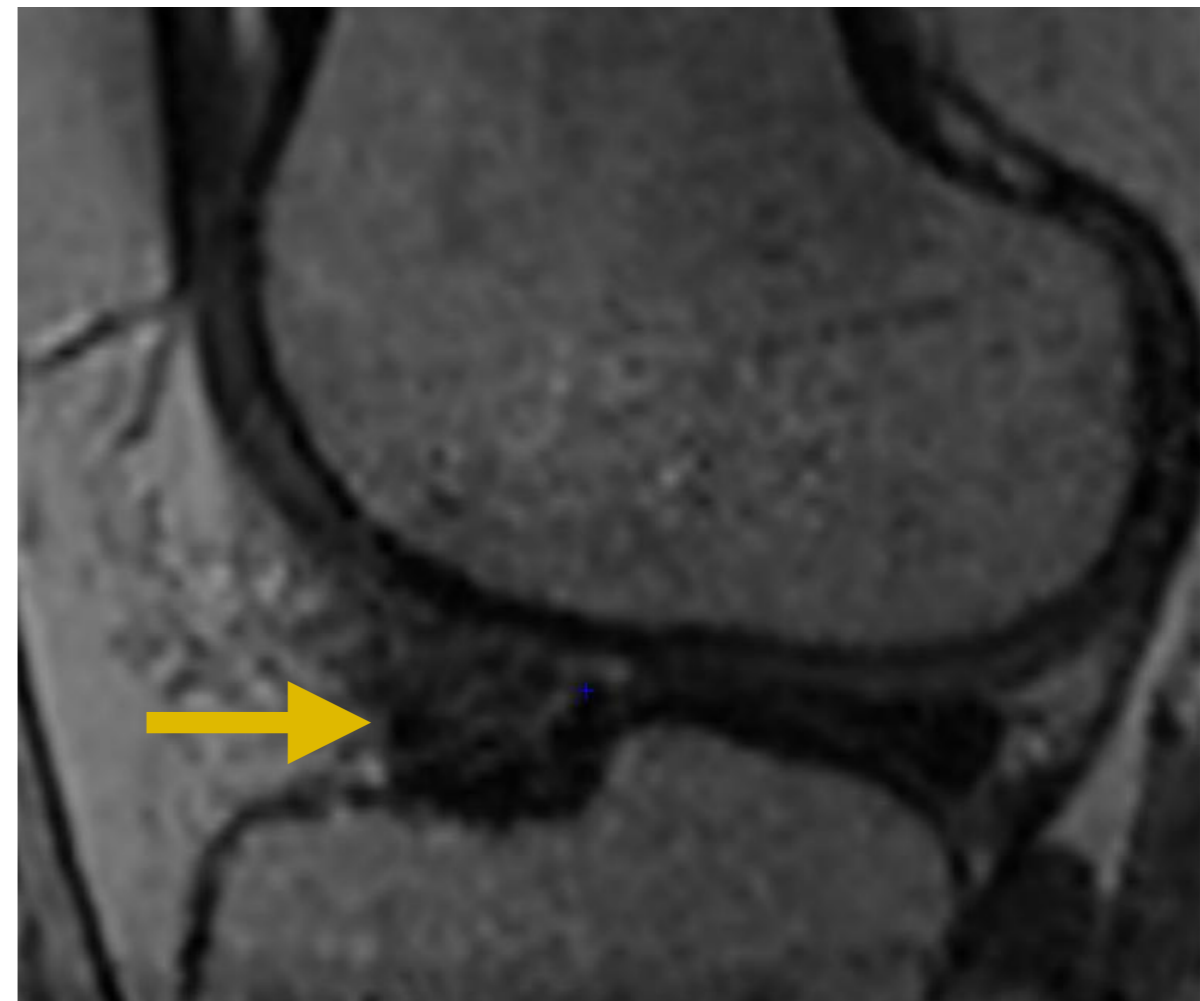
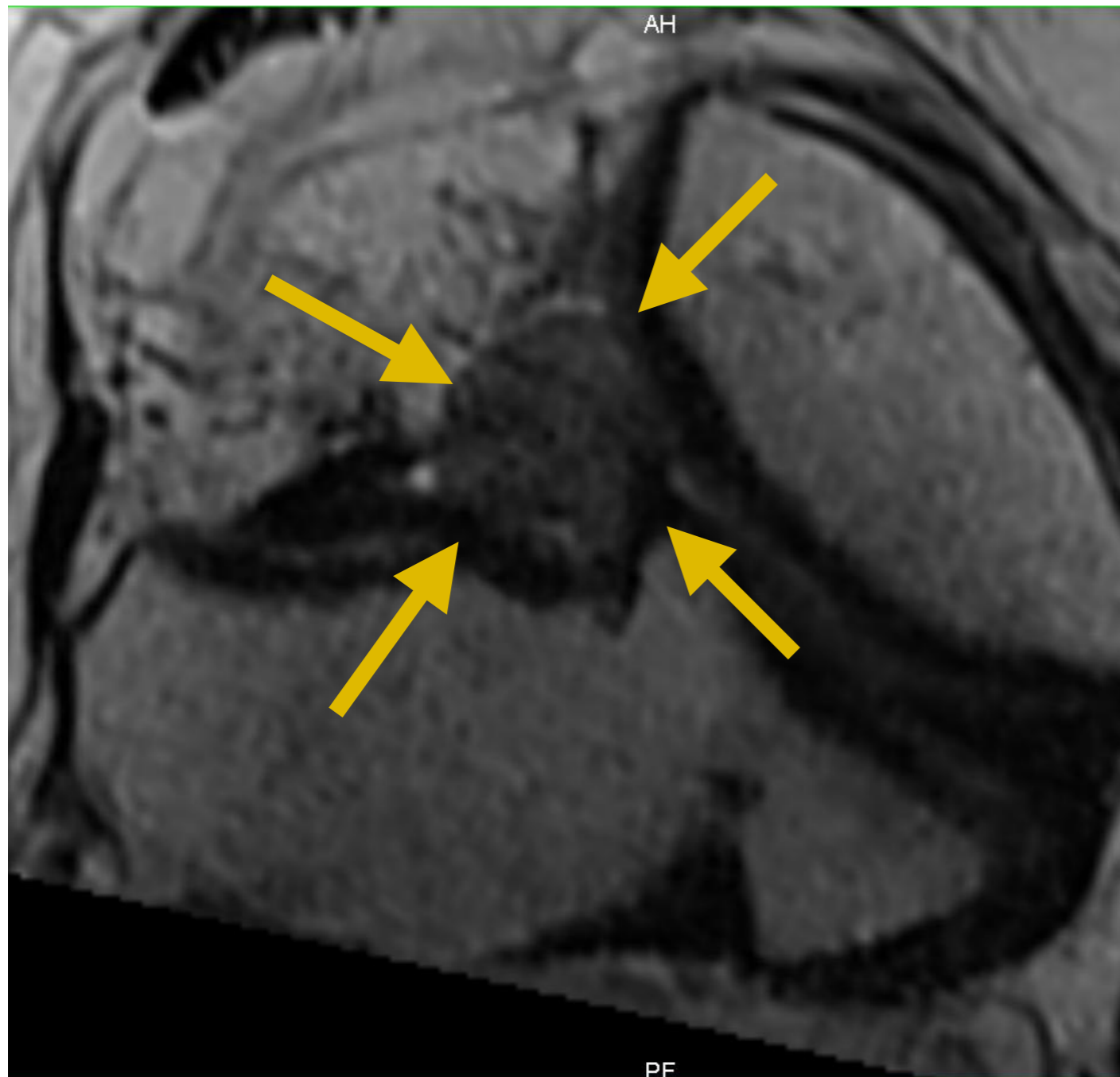## Rupture Complète



## 2. LCA

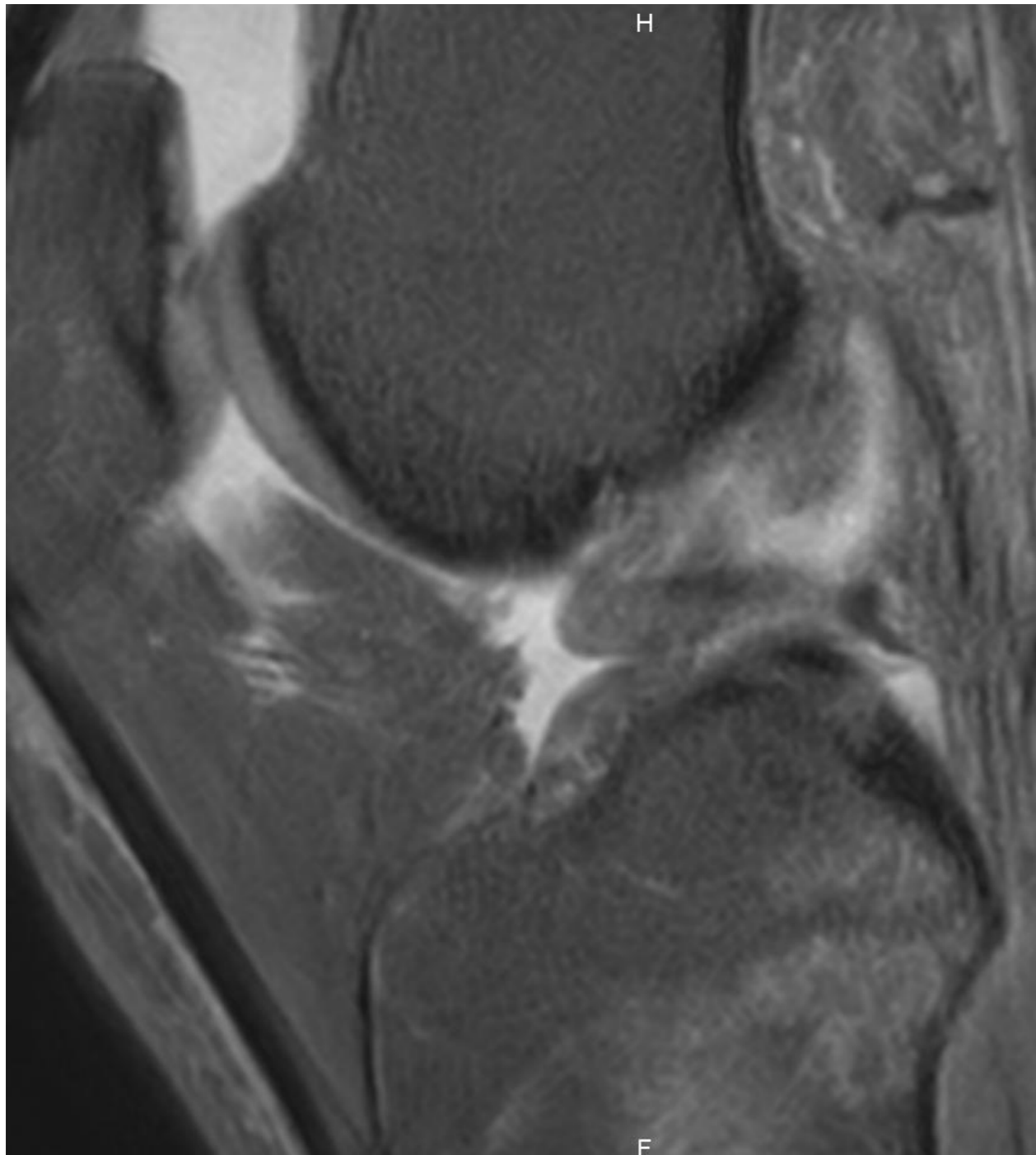
## Rupture Complète

- LCA : cyclope pré op



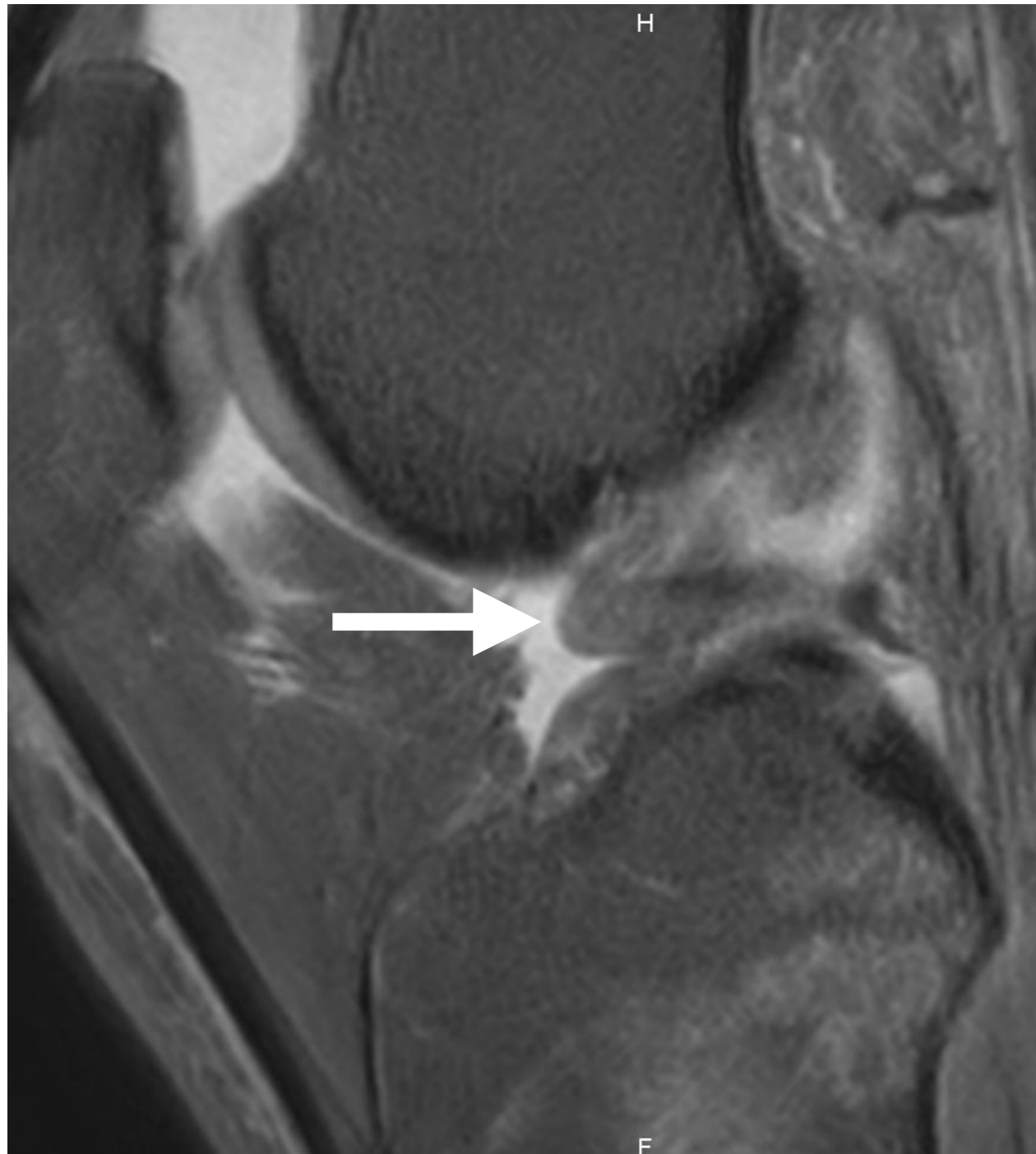## 2. LCA

## Rupture Partielle



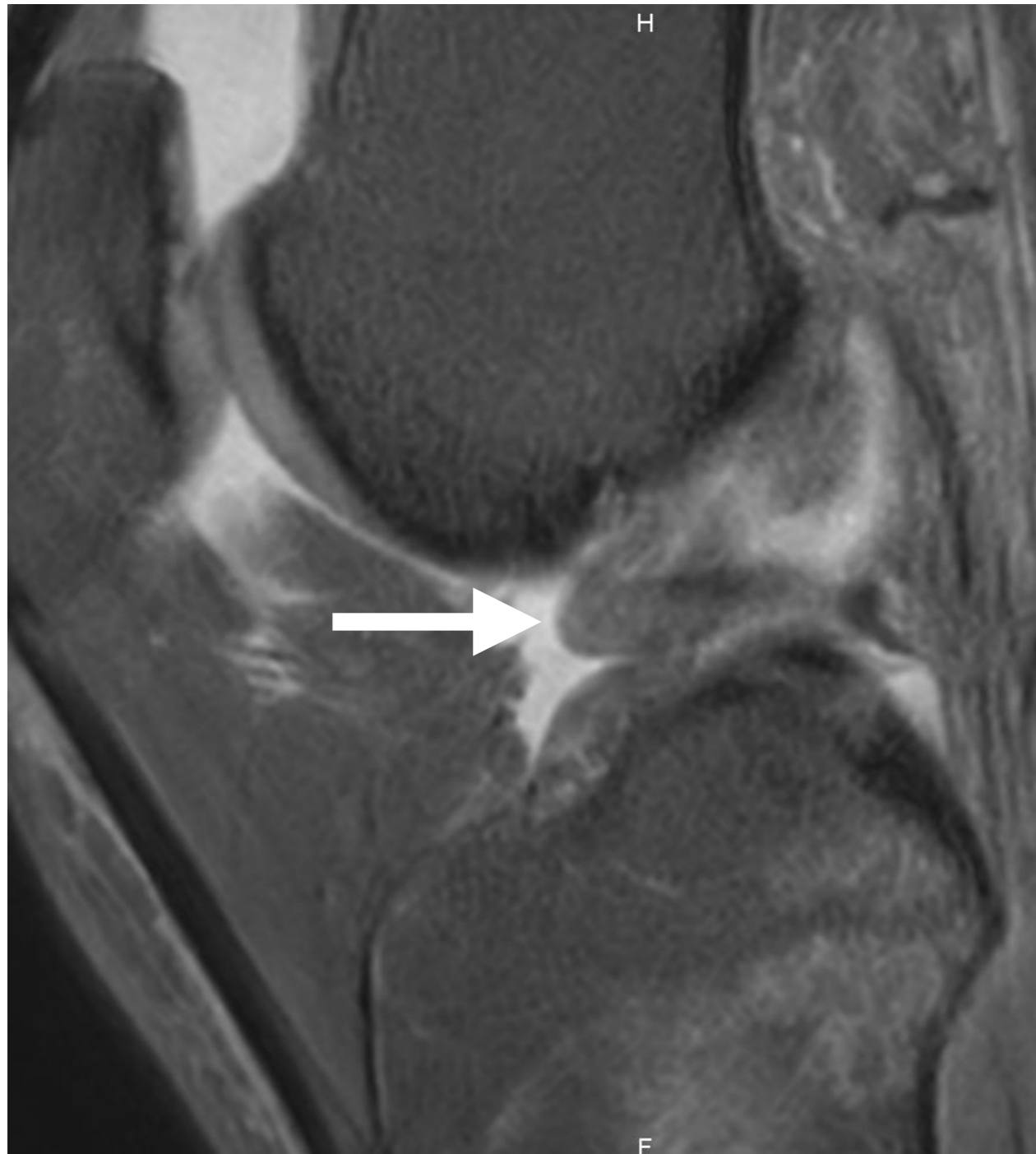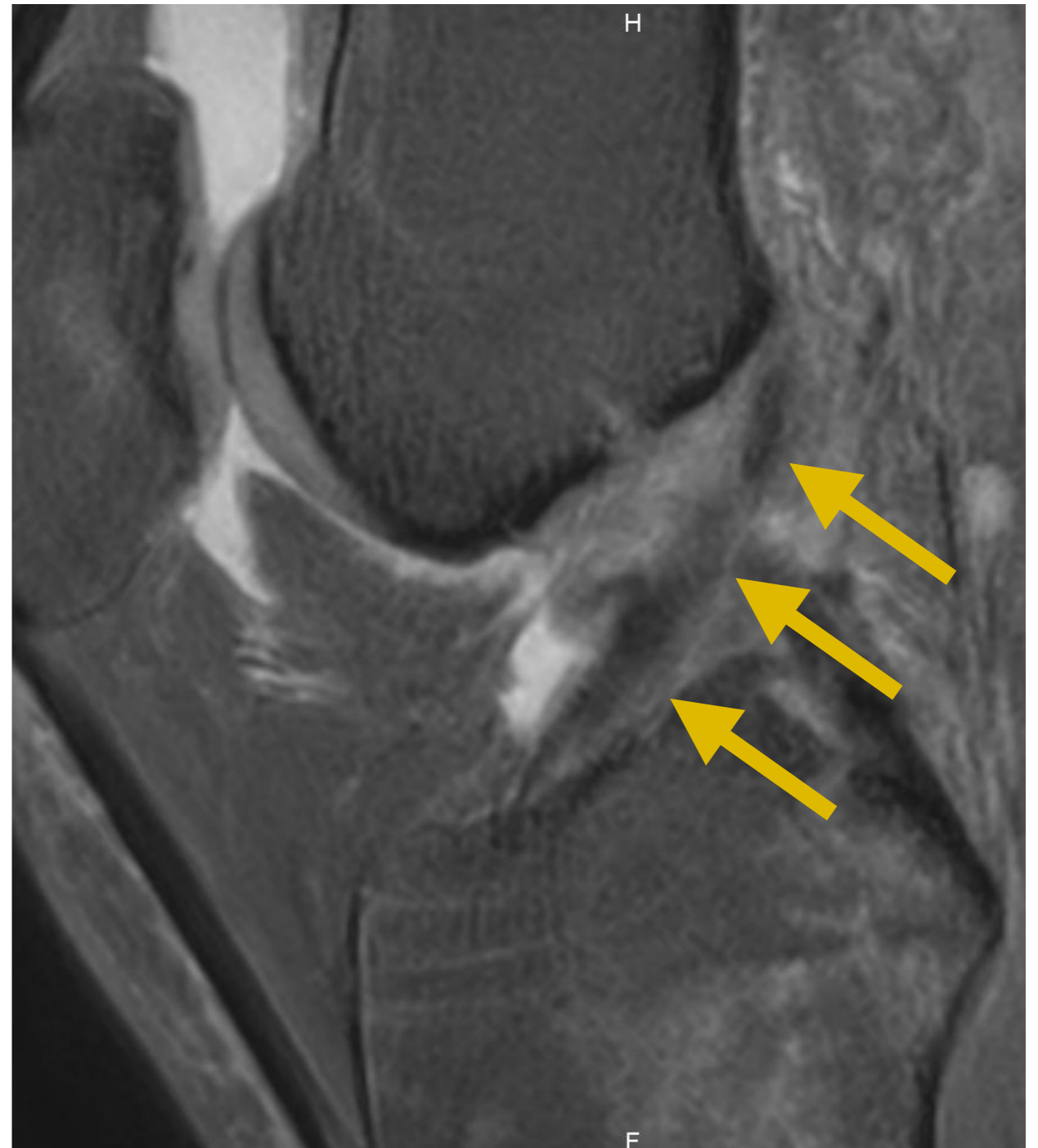
## 2. LCA

## Rupture Partielle



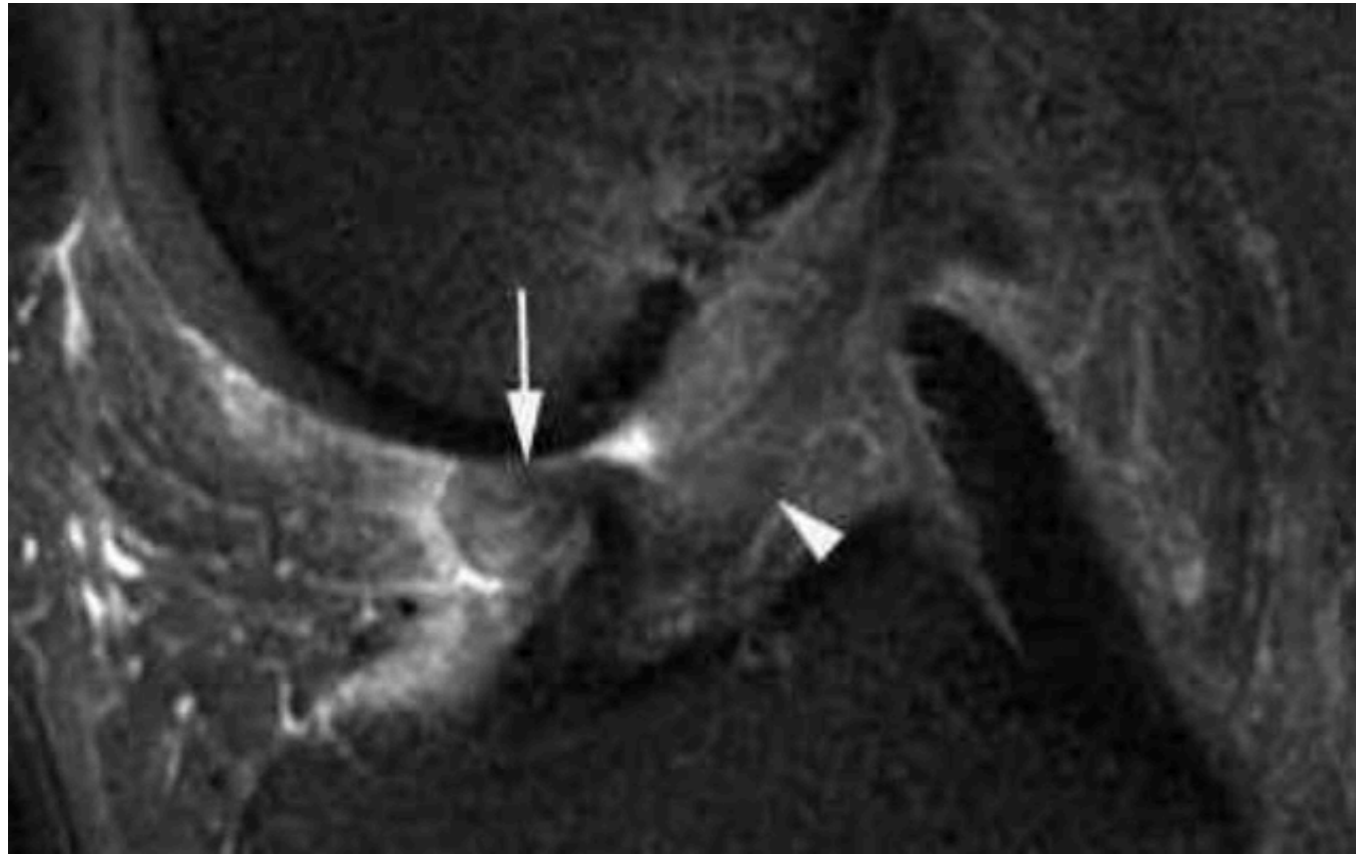
## 2. LCA

## Rupture Partielle



## 2. LCA

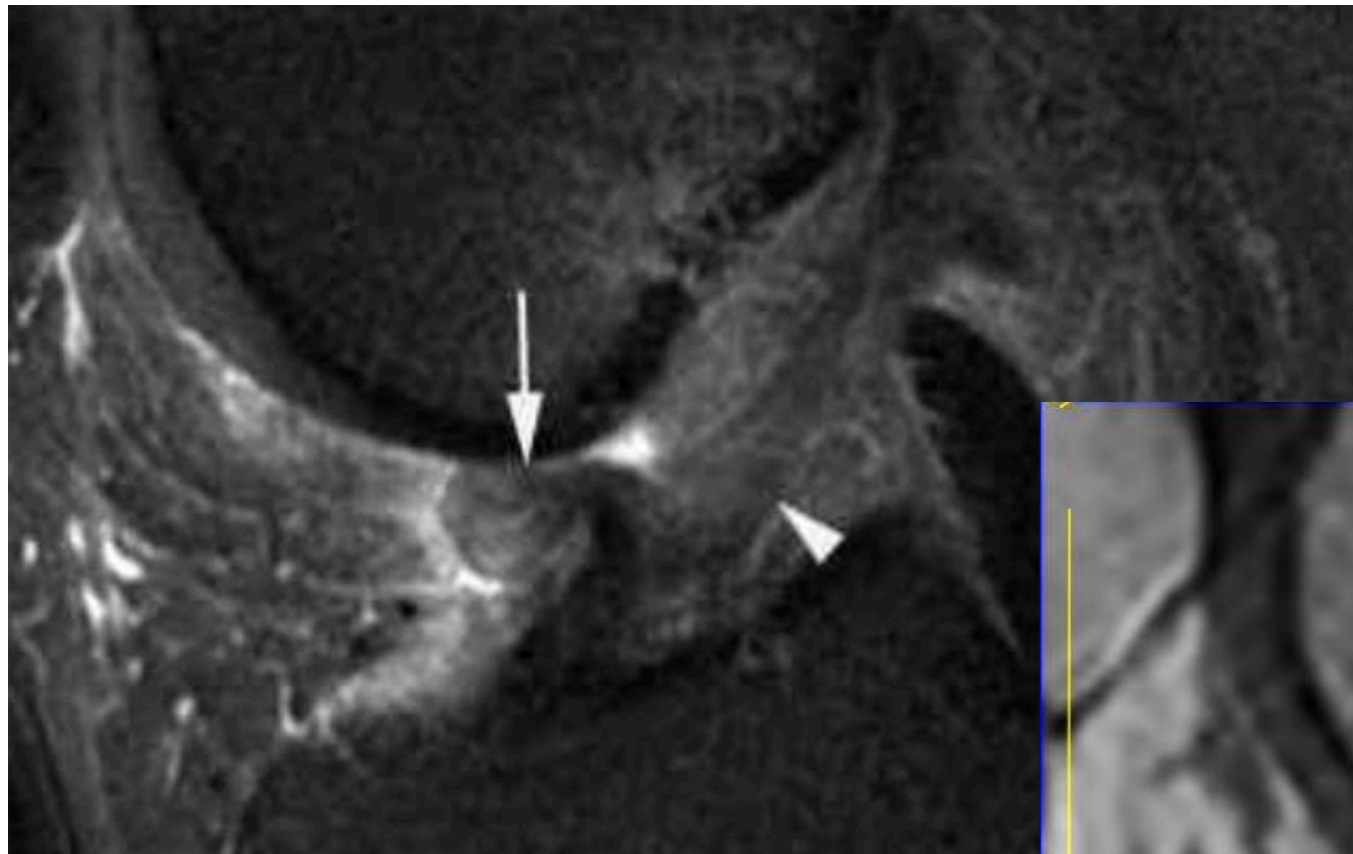
## Rupture Partielle



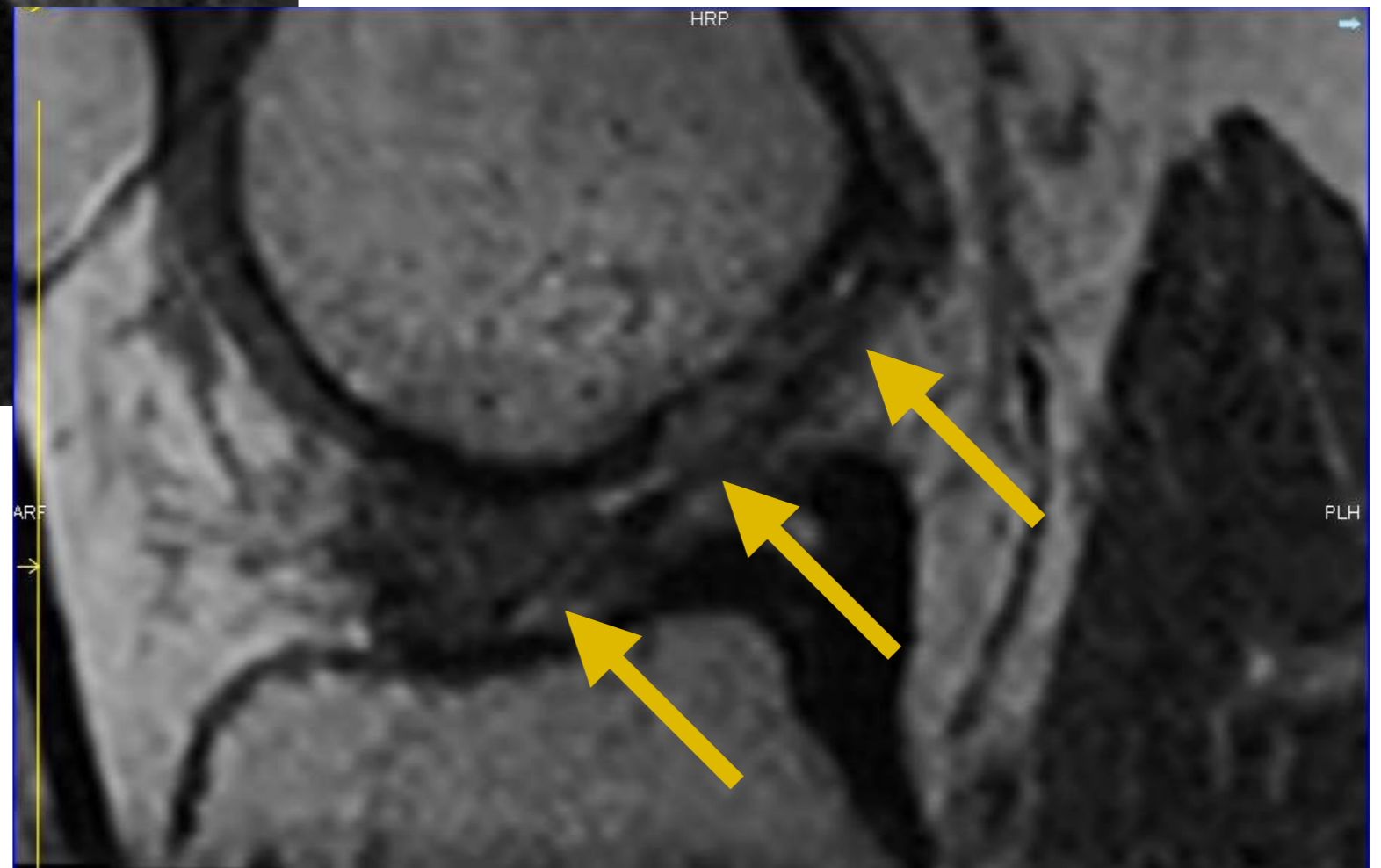
**Rupture  
uni-fasciculaire**

## 2. LCA

## Rupture Partielle



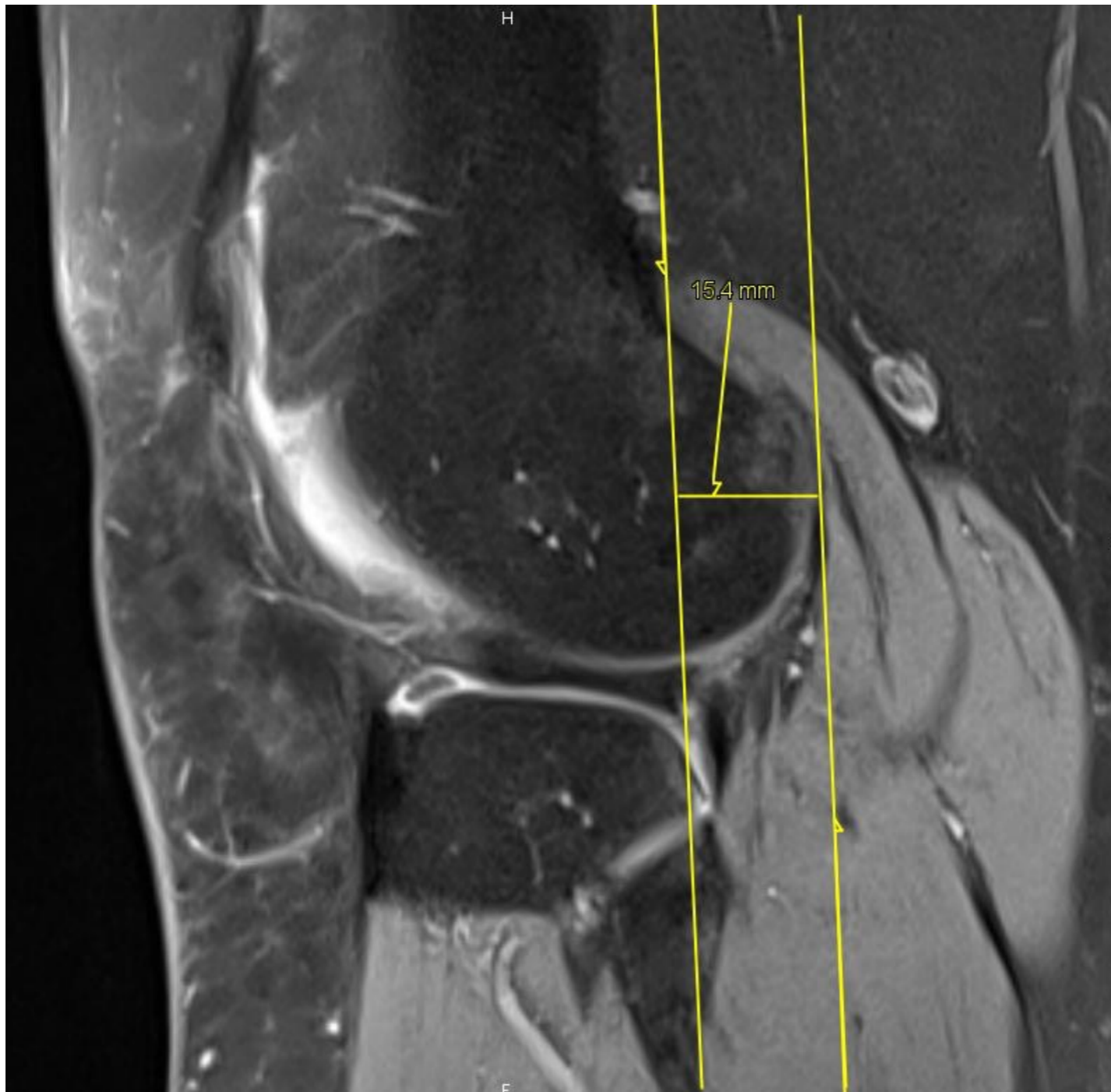
**Rupture  
uni-fasciculaire**



## 2. LCA

## Rupture Partielle

- Rupture partielle mais...

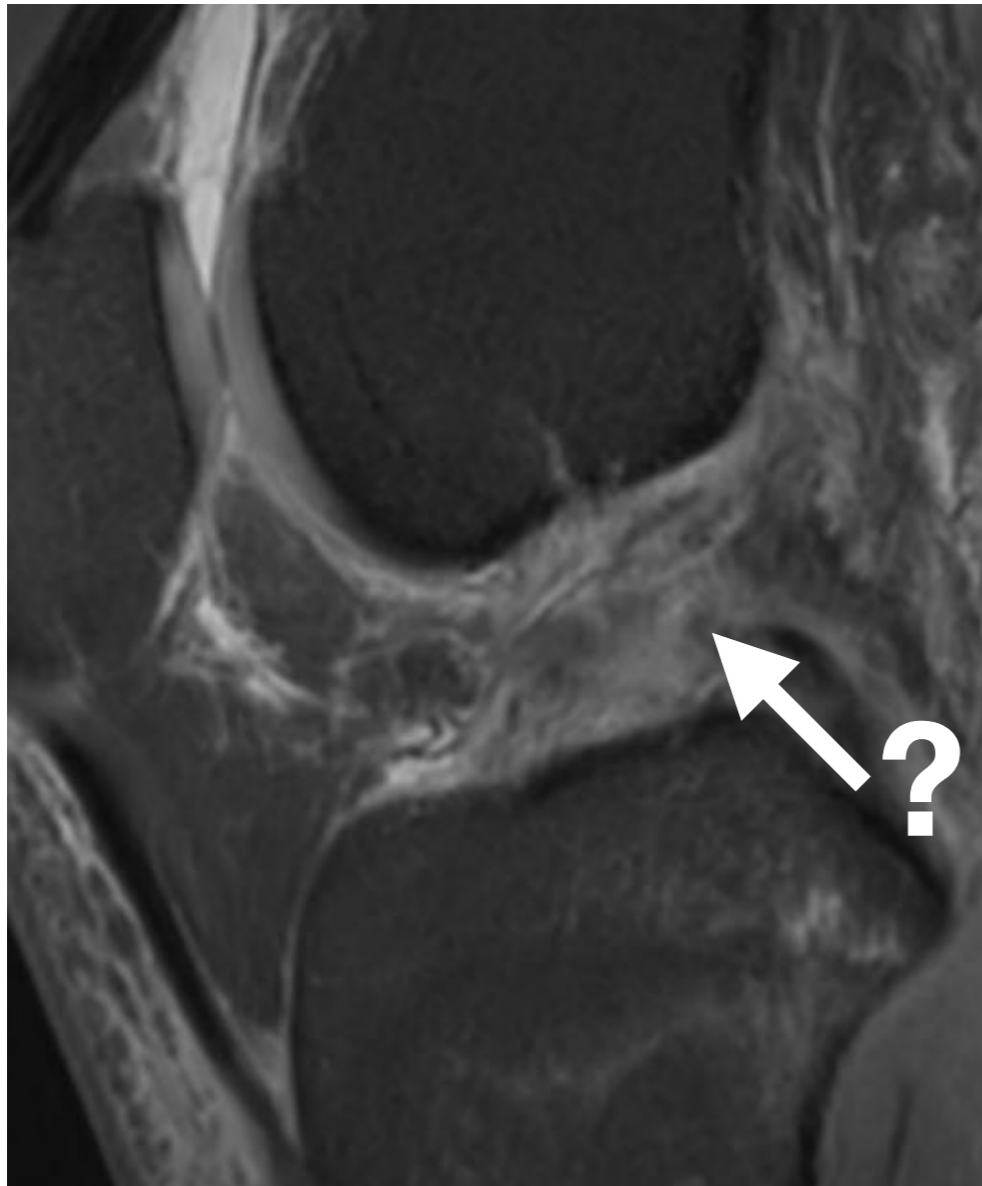


Tiroir antérieur  
spontané



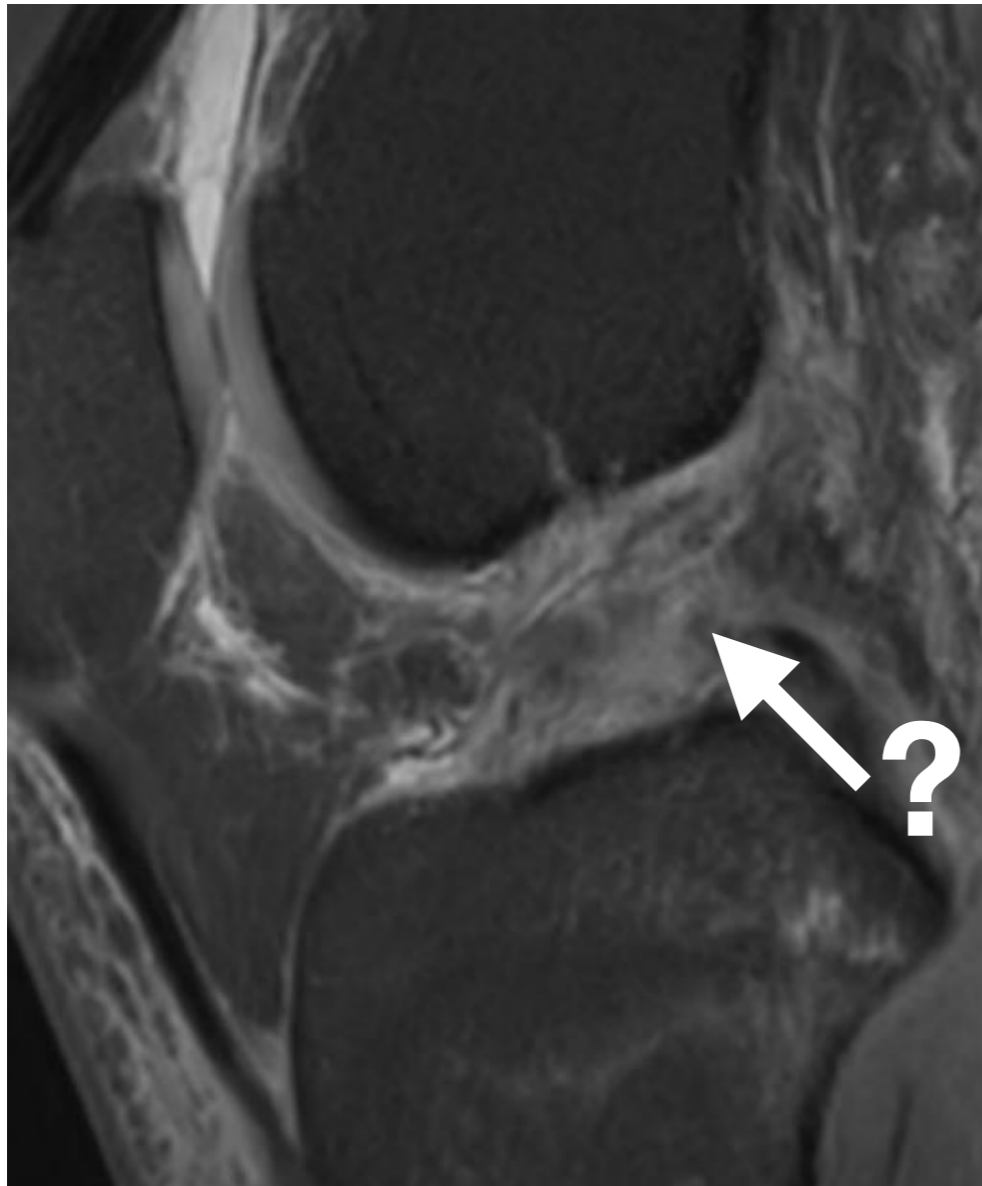
## 2. LCA

## Rupture Partielle



## 2. LCA

## Rupture Partielle



1 an plus  
tard

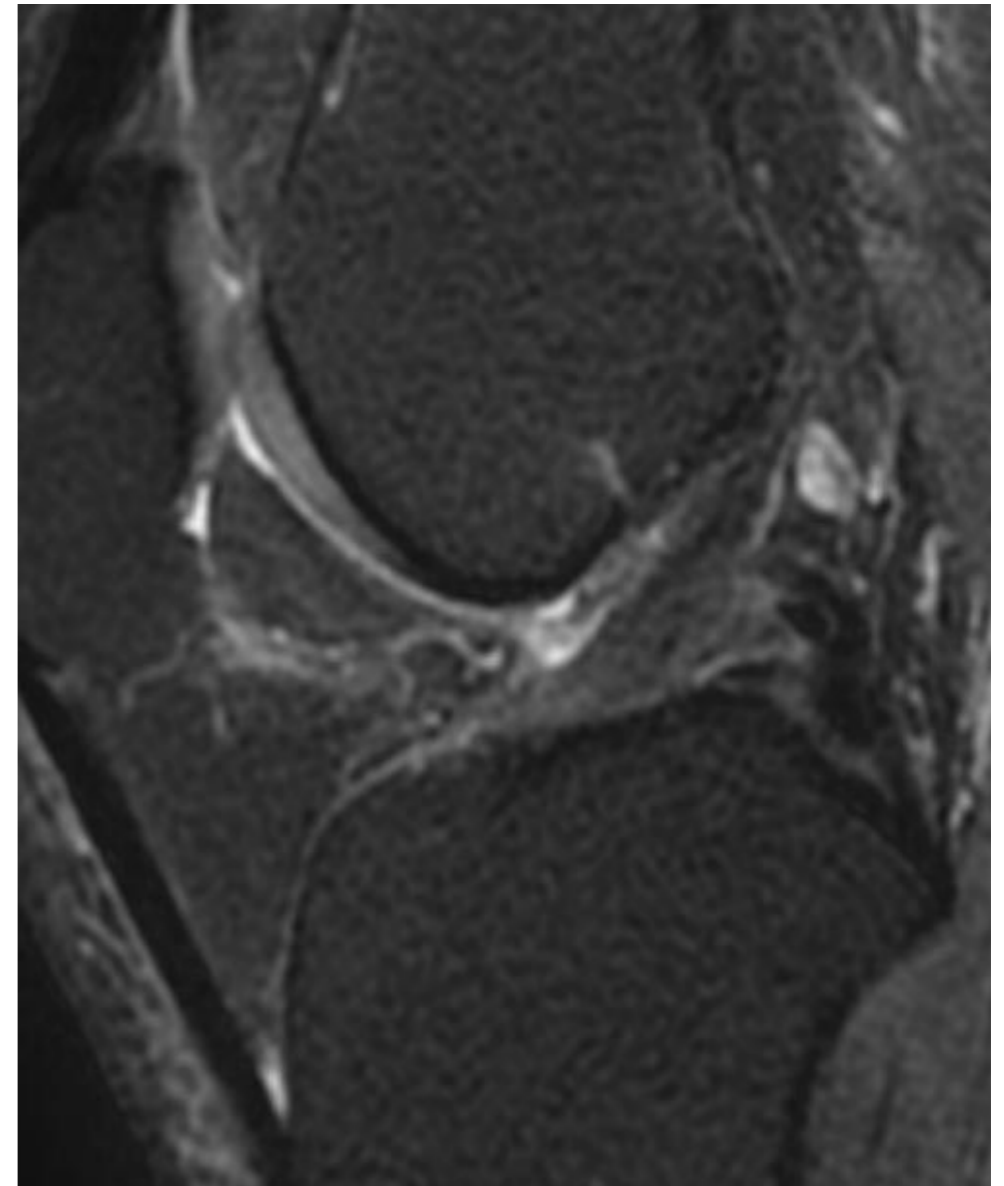


## 2. LCA

## Rupture Partielle

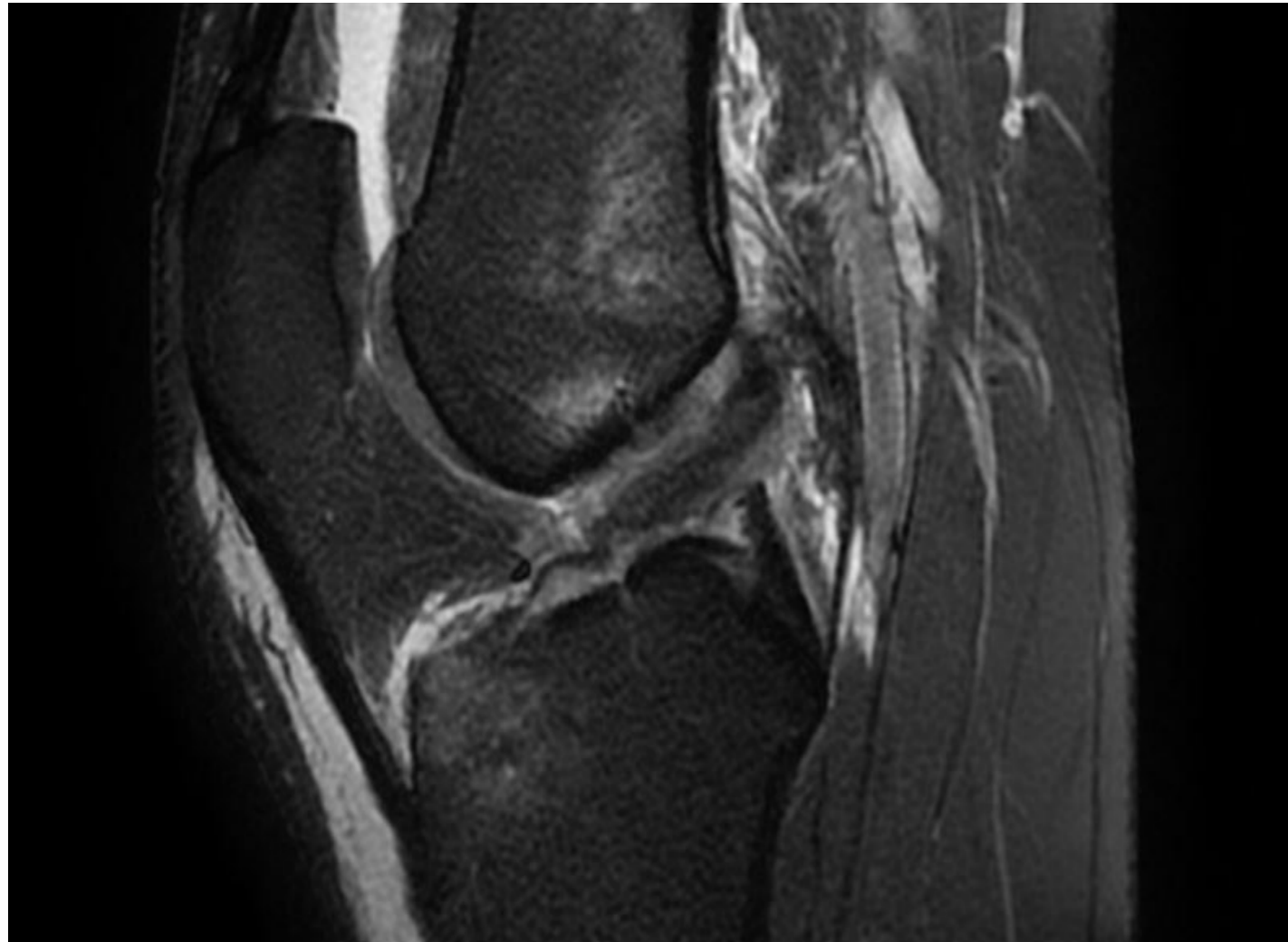


1 an plus  
tard



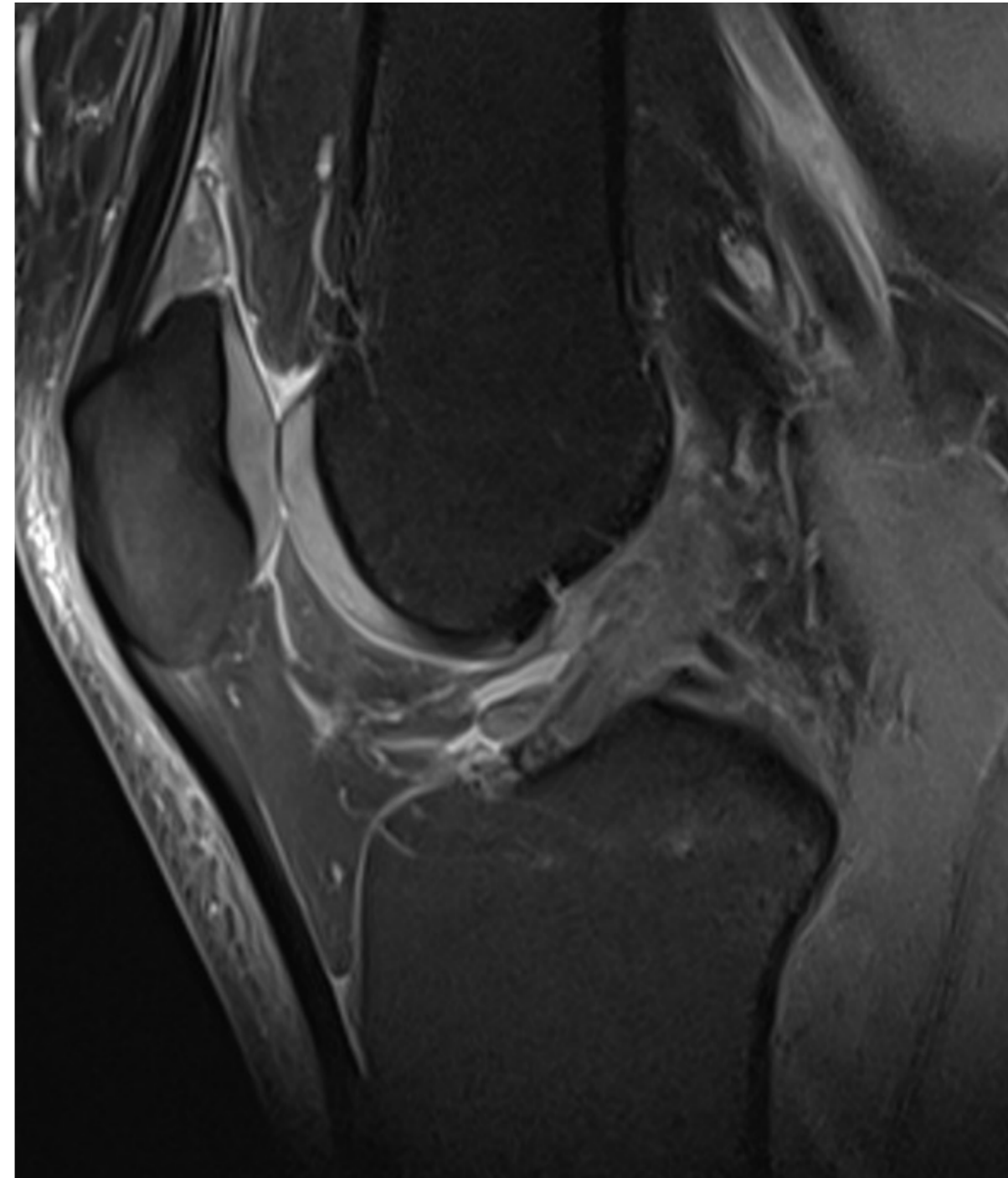
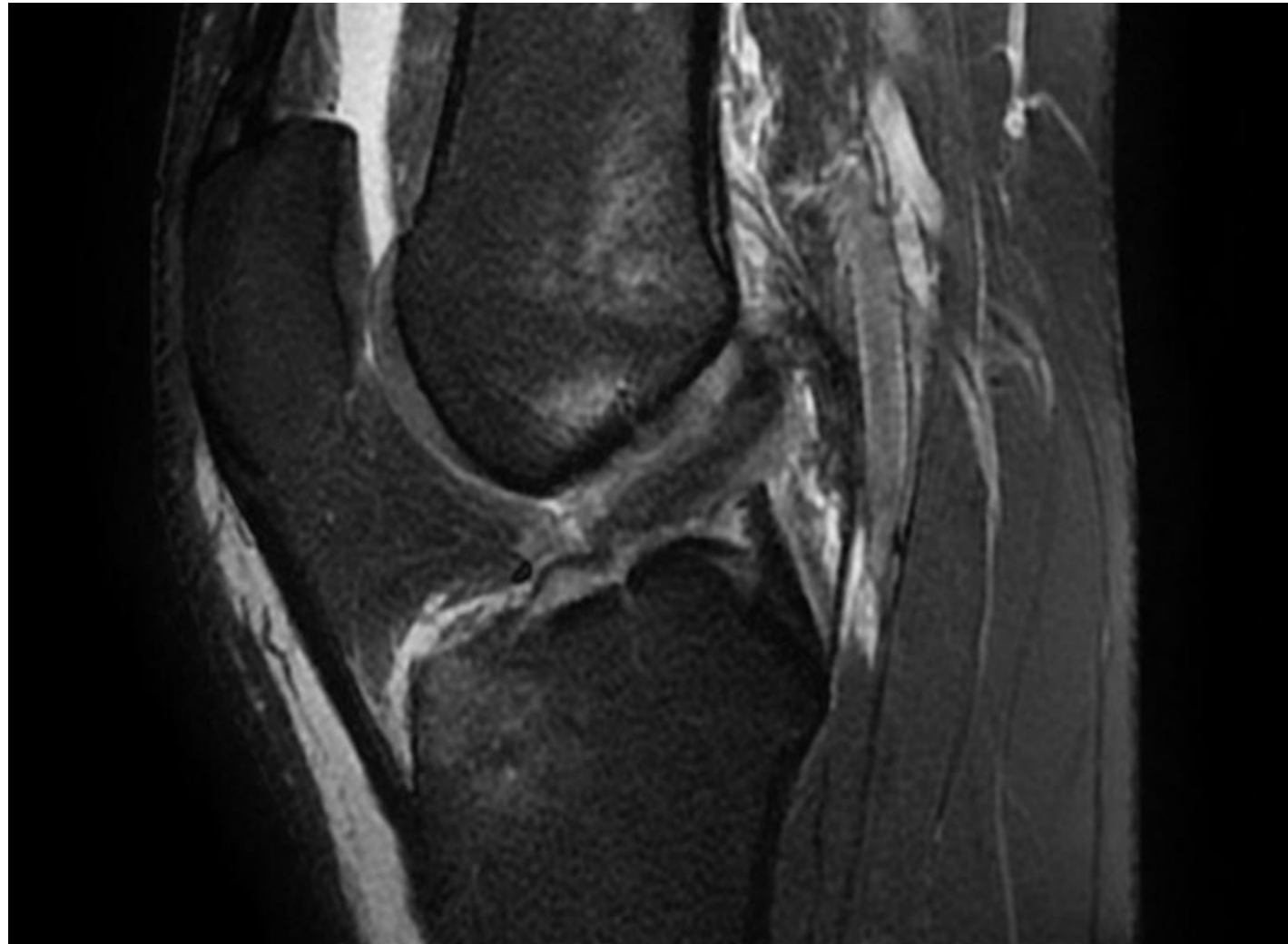
## 2. LCA

## Rupture Partielle



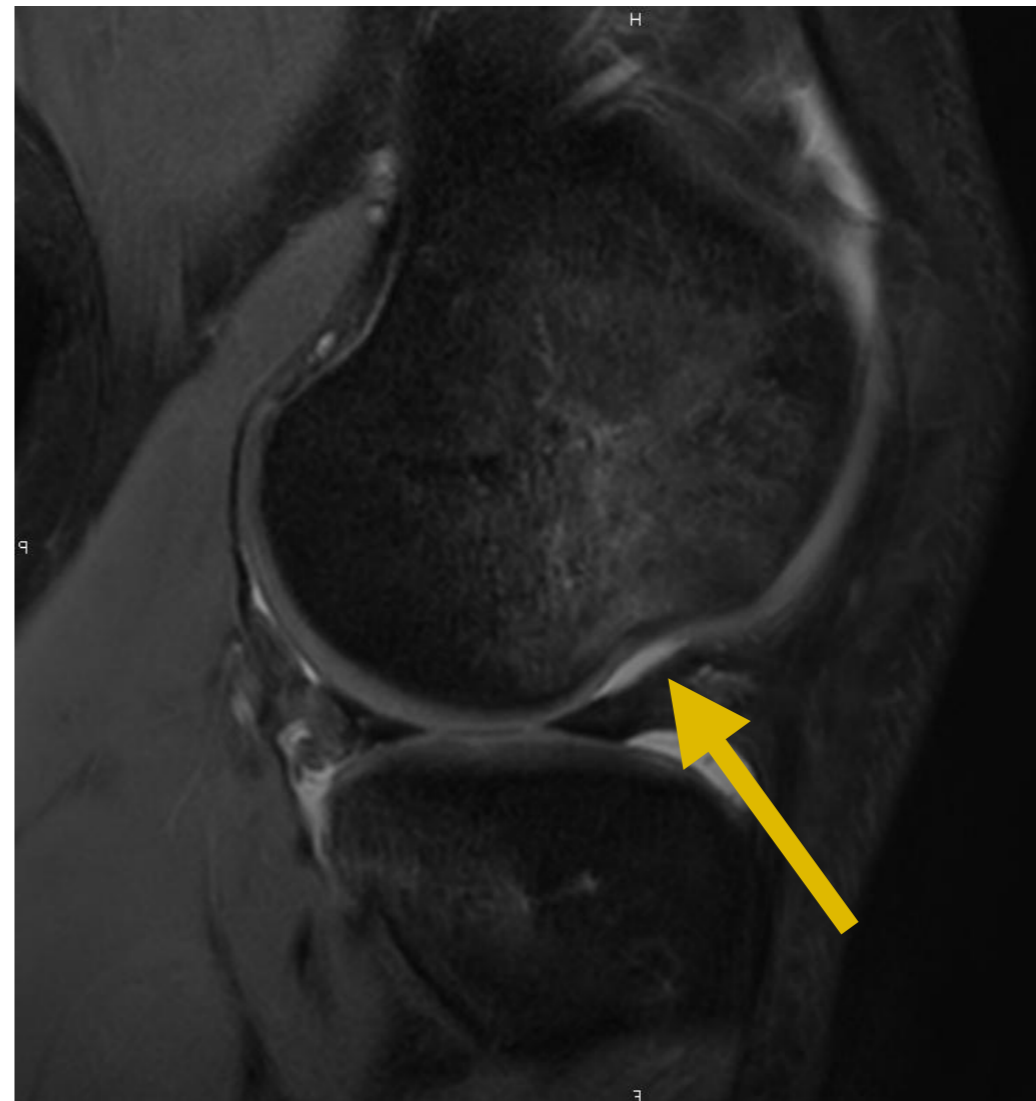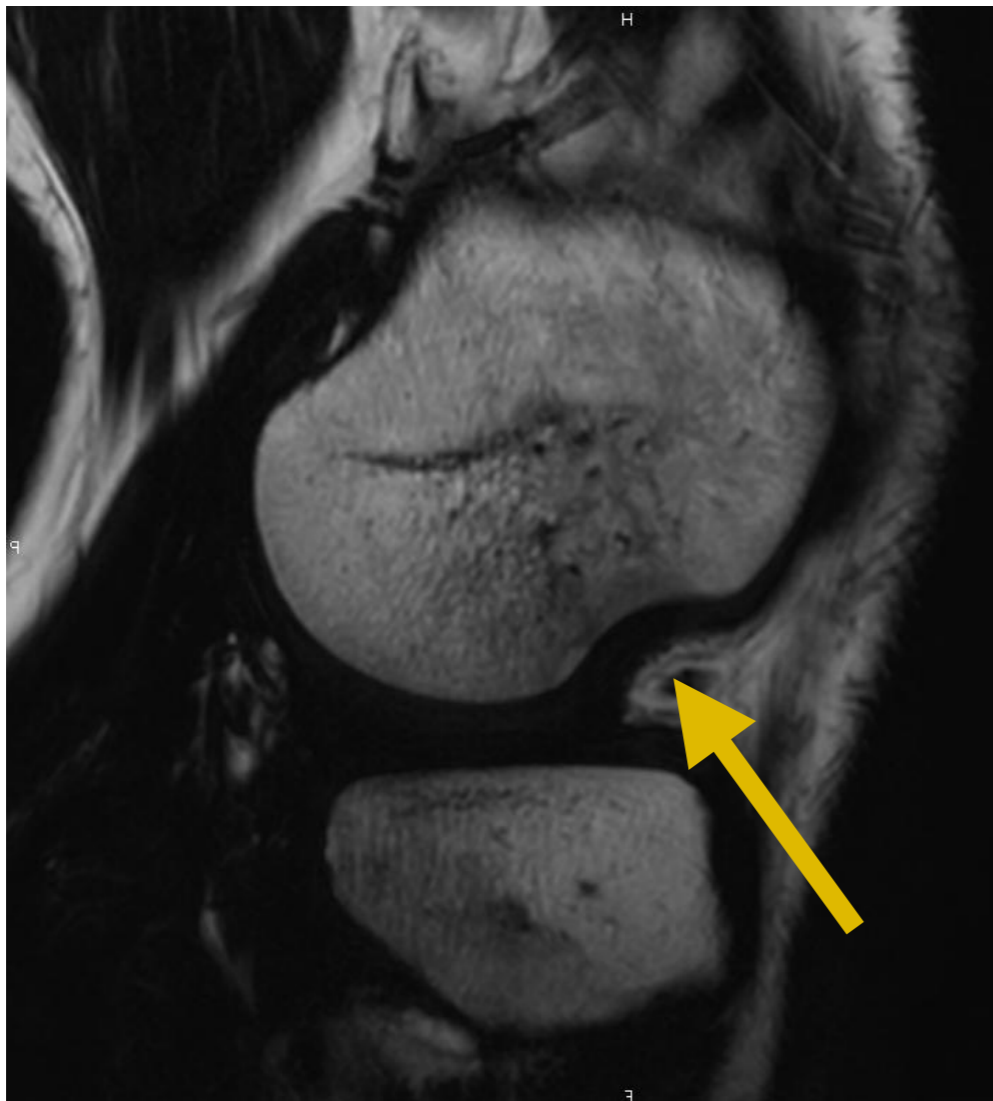
## 2. LCA

## Rupture Partielle



## 2. LCA Signes INDIRECTS

- LCA : encoche condyle latéral

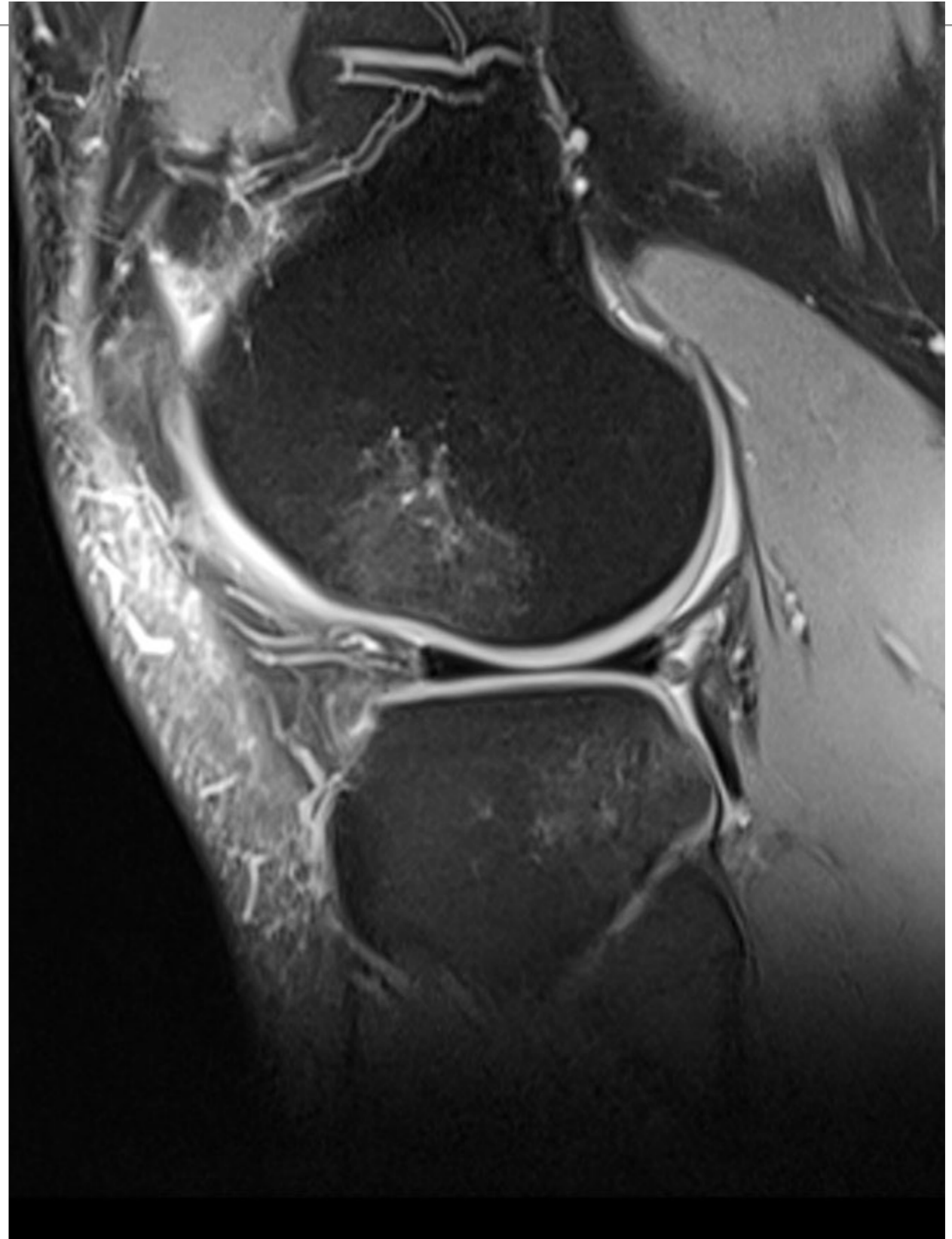


## 2. LCA

## Signes INDIRECTS

OEDEME OSSEUX

EN MIROIR +++ LCA

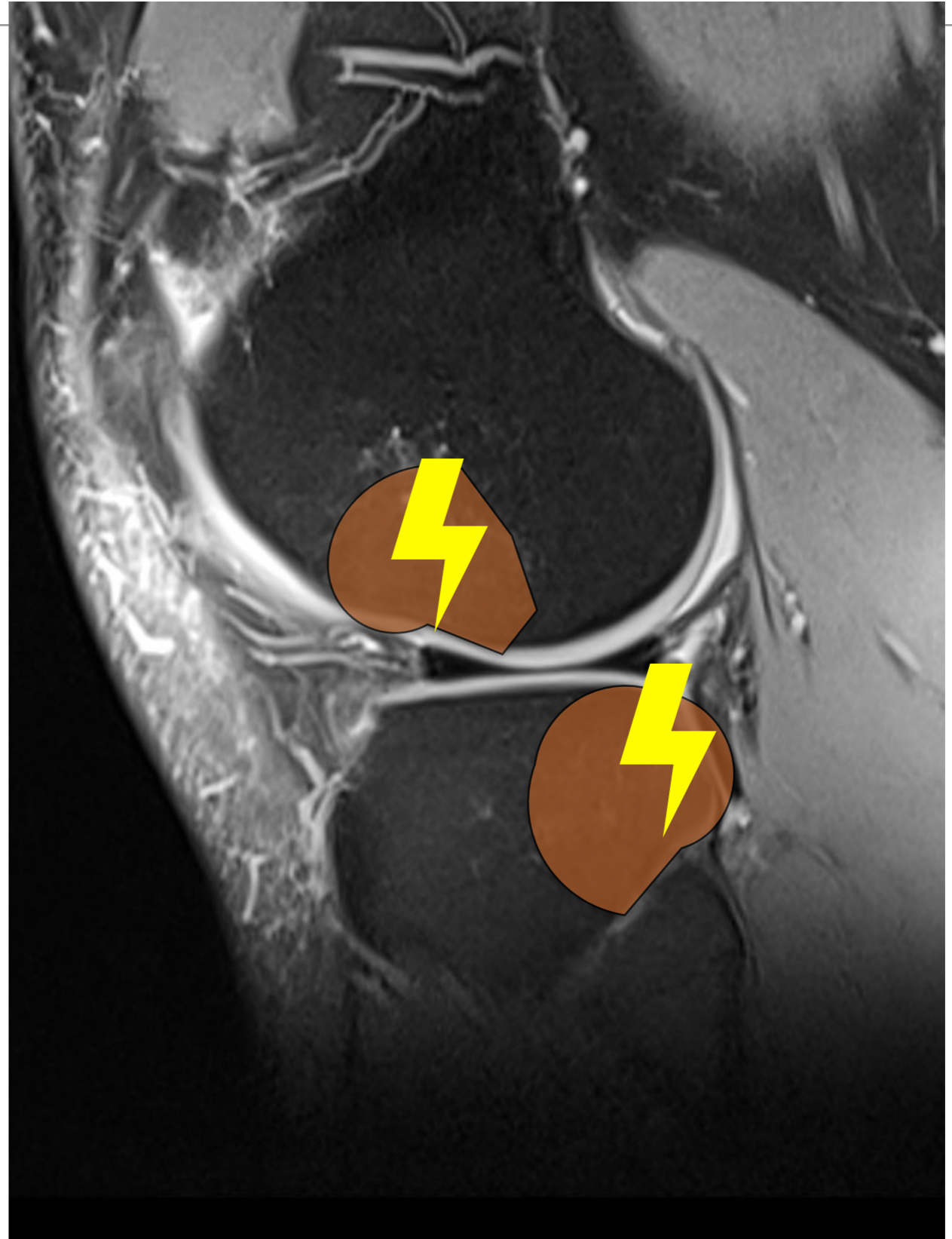


## 2. LCA

## Signes INDIRECTS

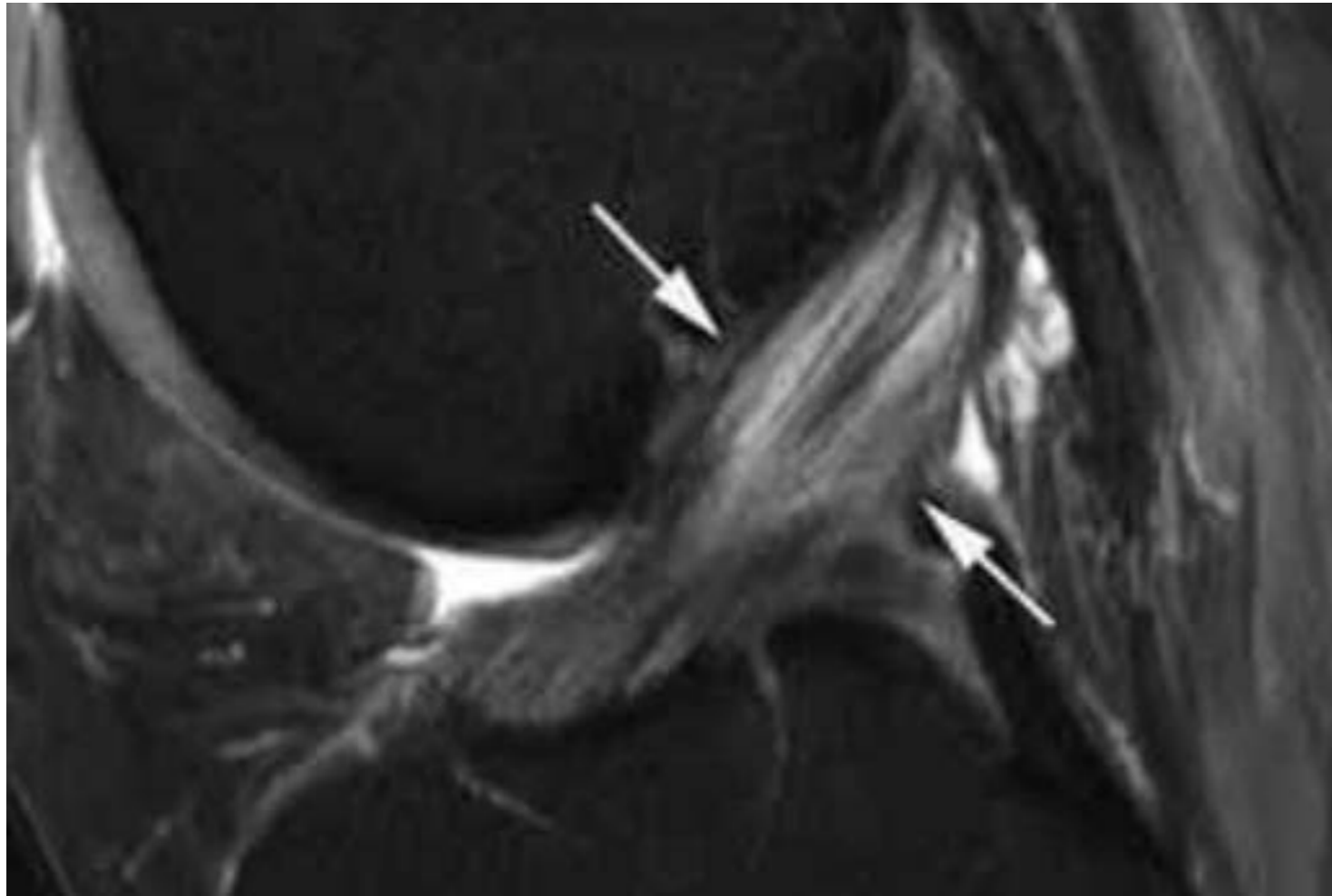
OEDEME OSSEUX

EN MIROIR +++ LCA





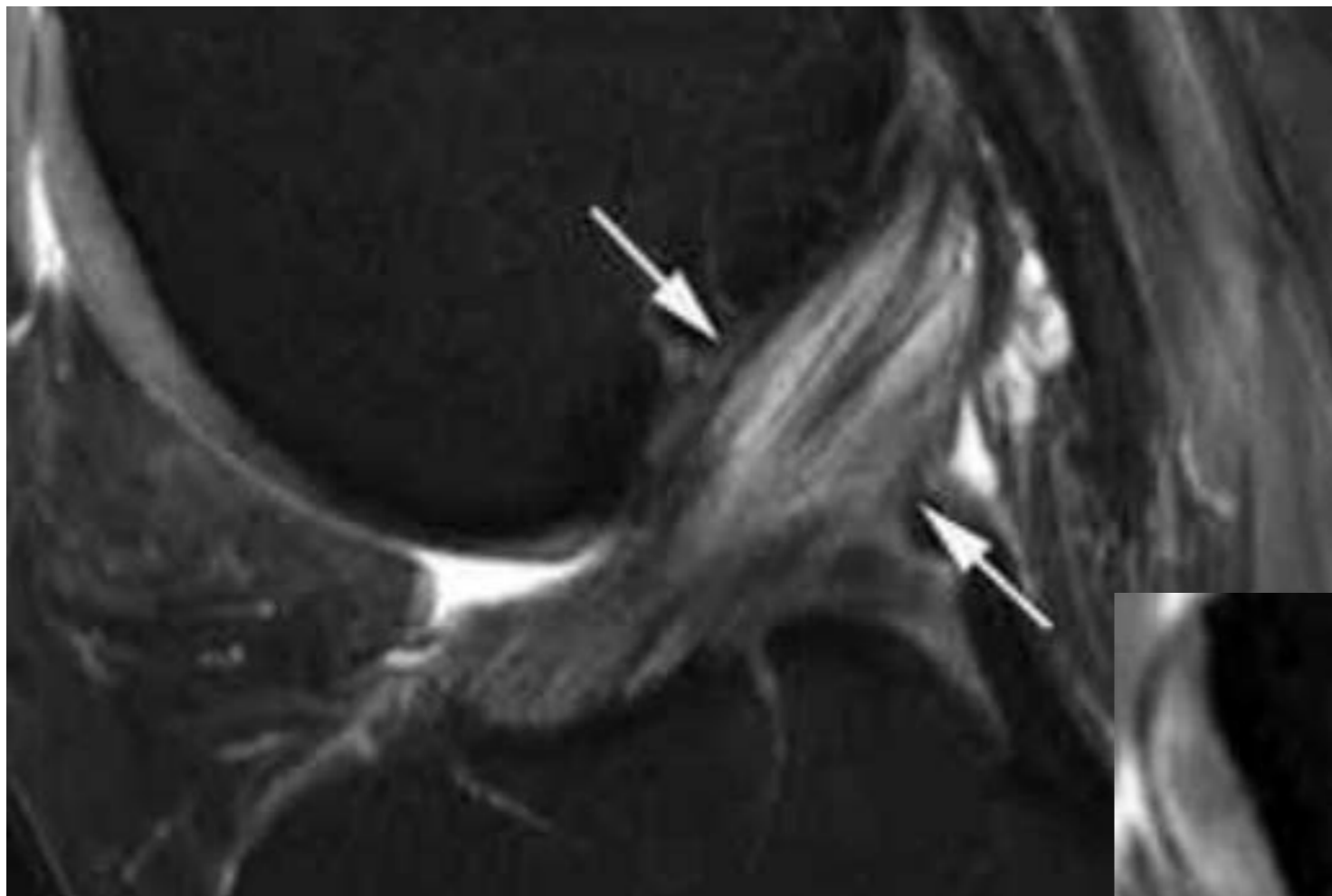
## 2. LCA Diag Différentiel



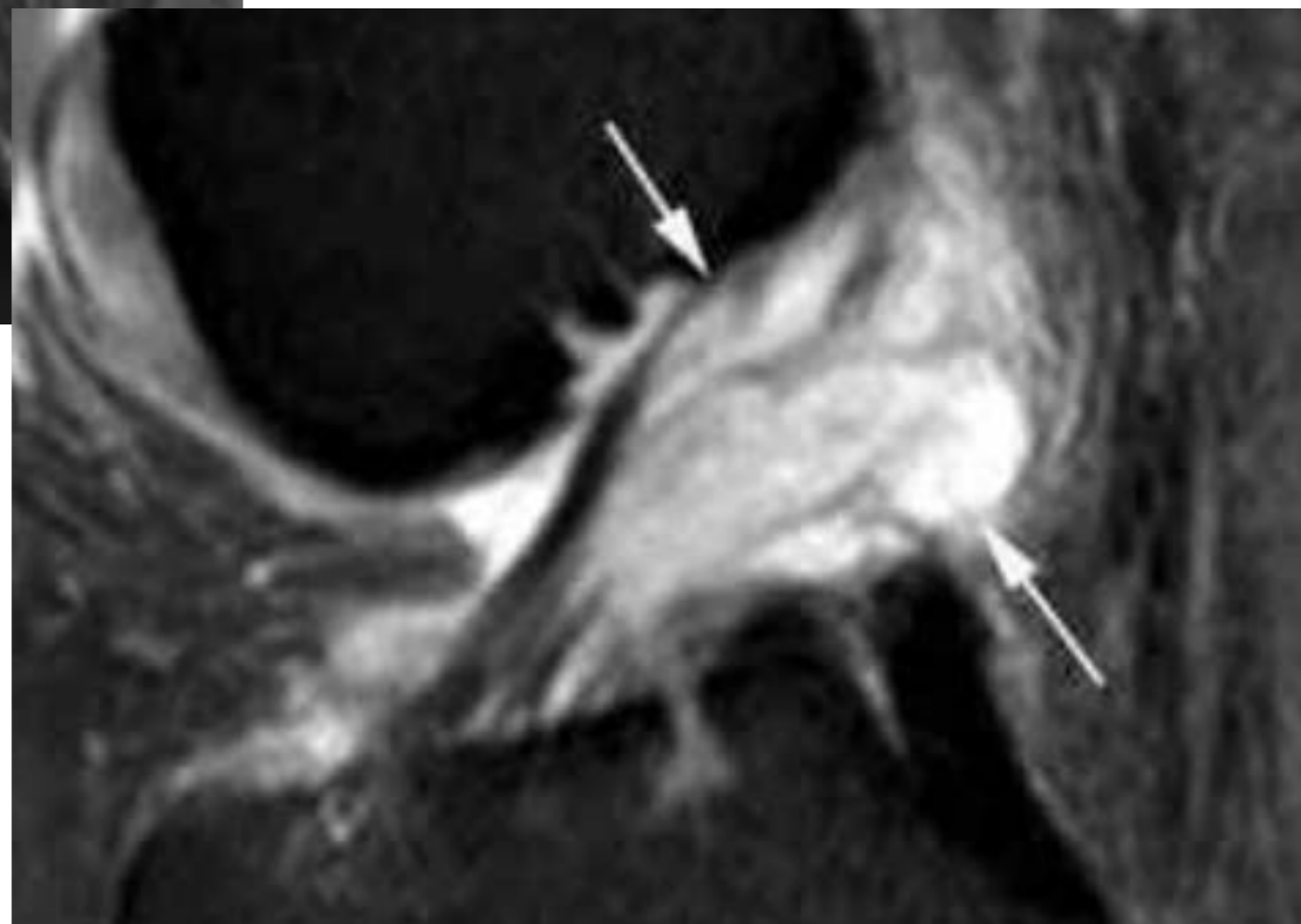
Dégénérescence  
Kystique Mucoïde

## 2. LCA

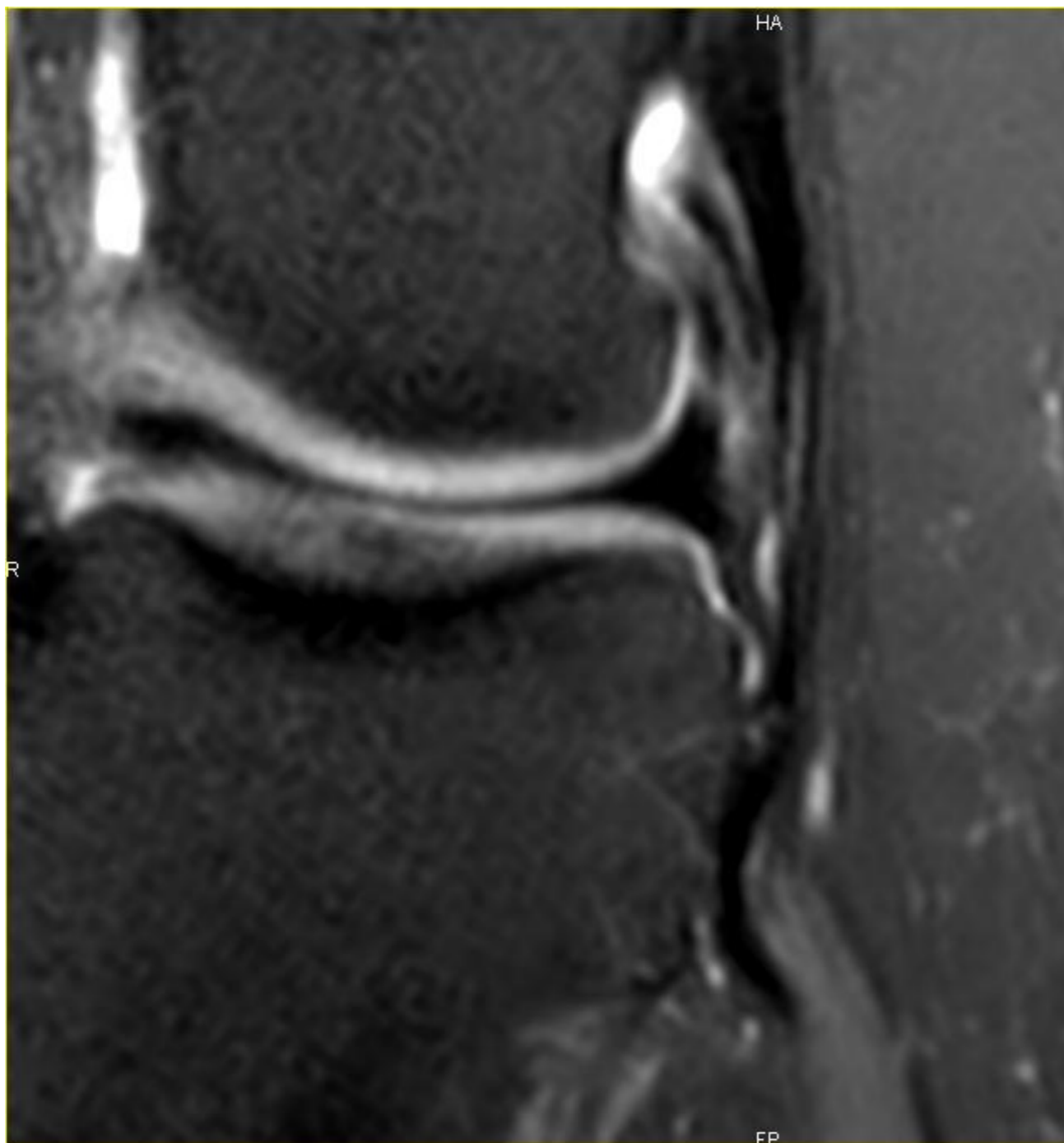
## Diag Différentiel



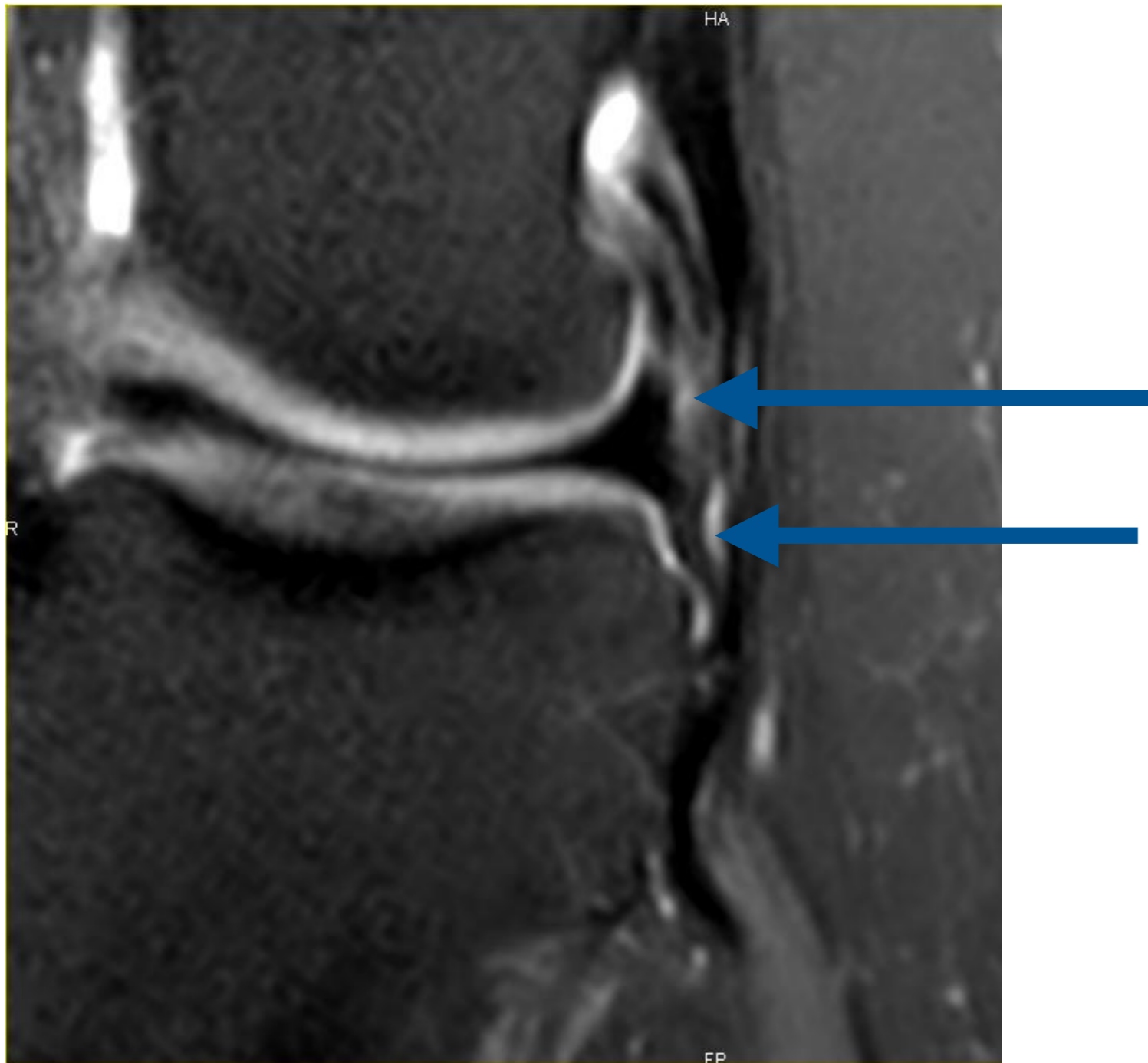
Dégénérescence  
Kystique Mucoïde



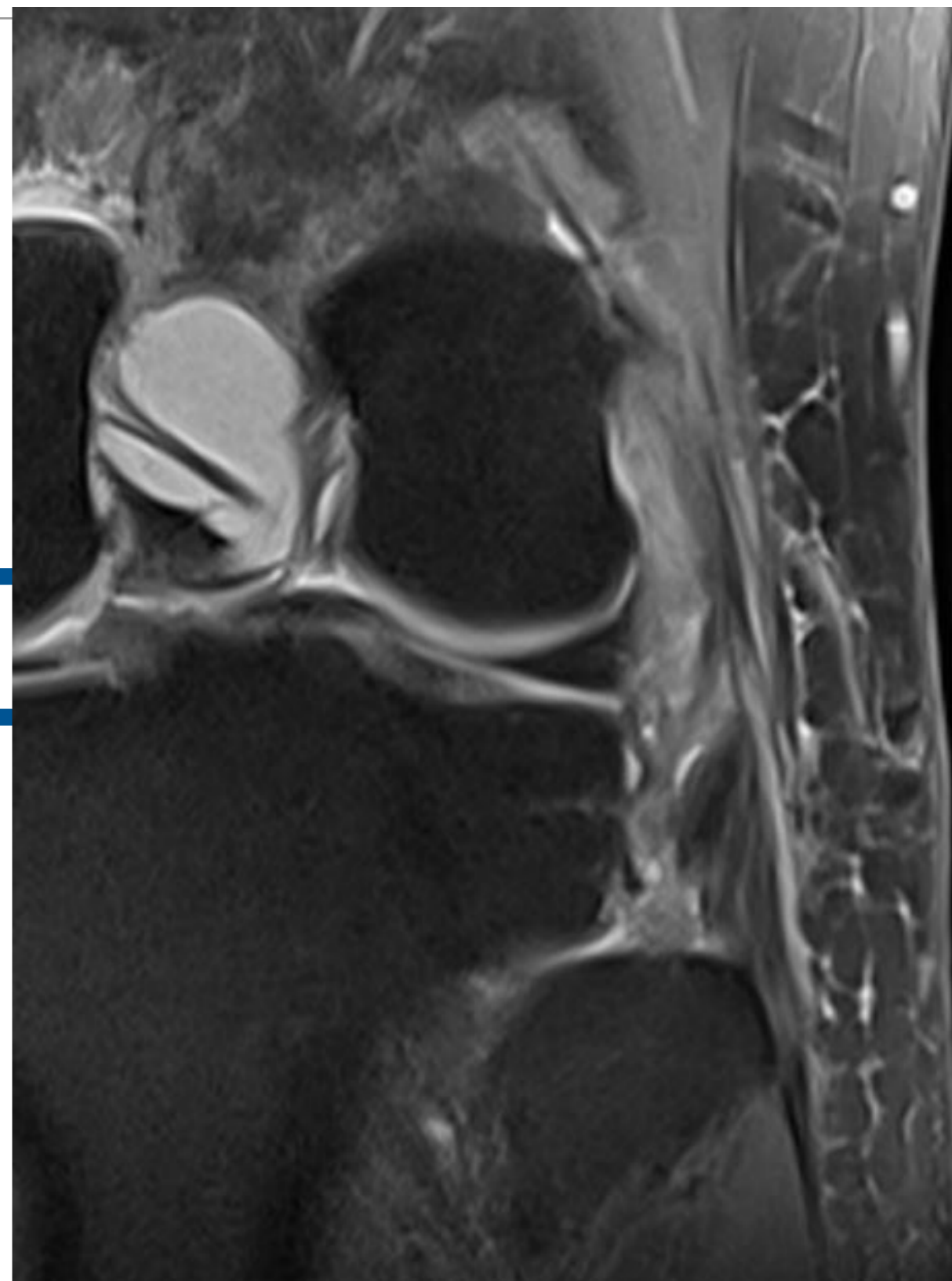
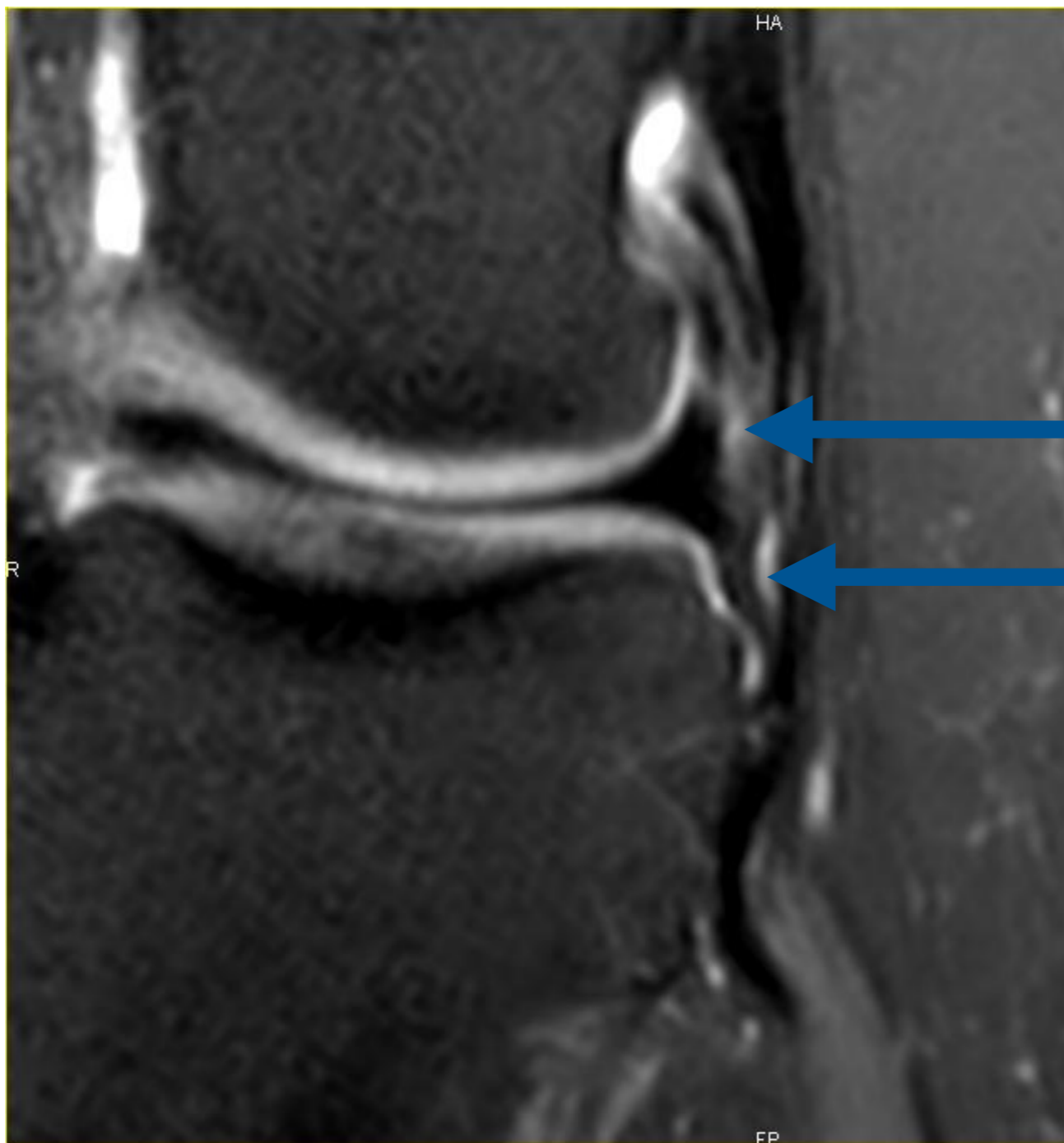
## 2. Ligament Antéro Latéral LAL



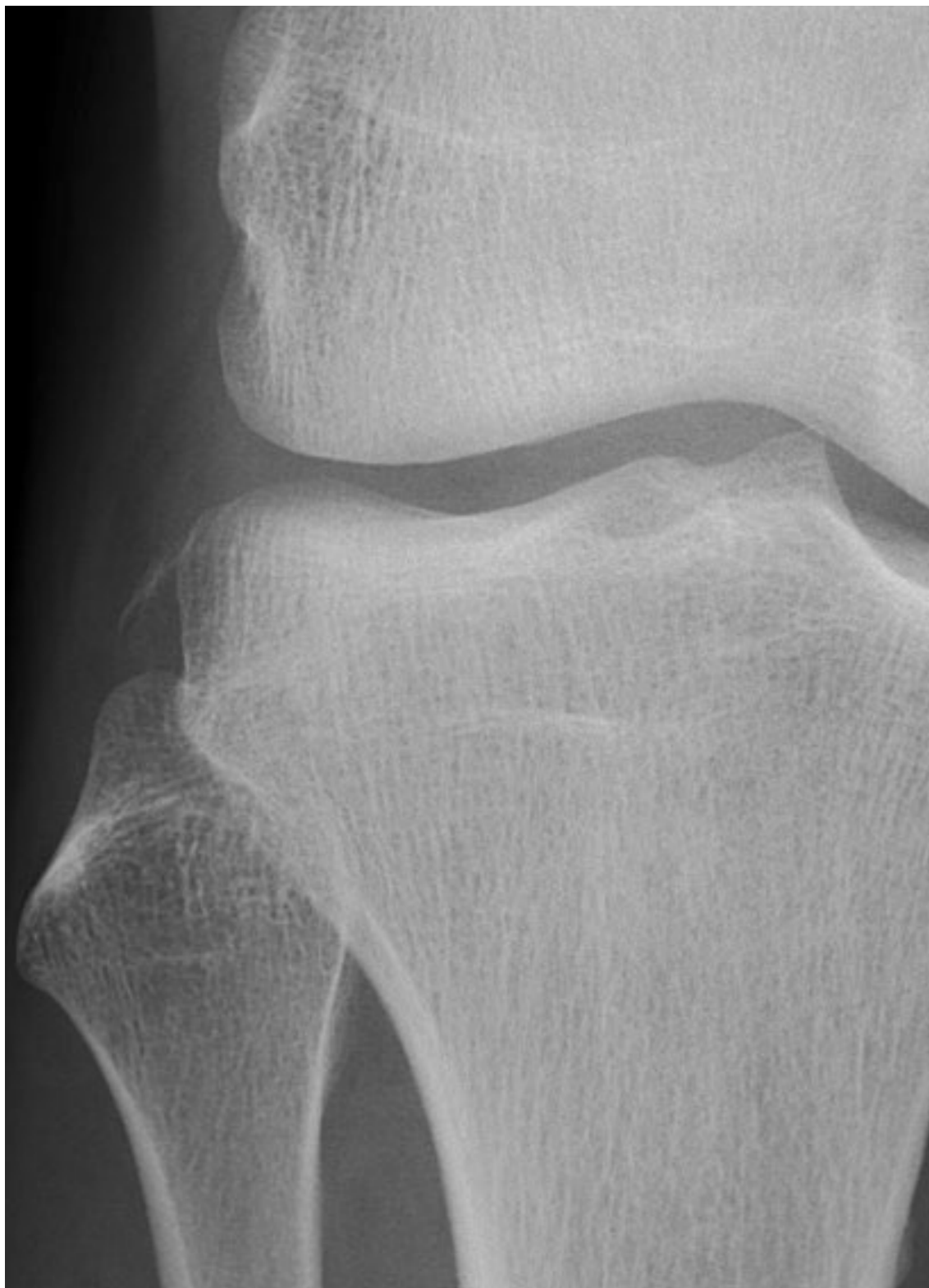## 2. Ligament Antéro Latéral LAL



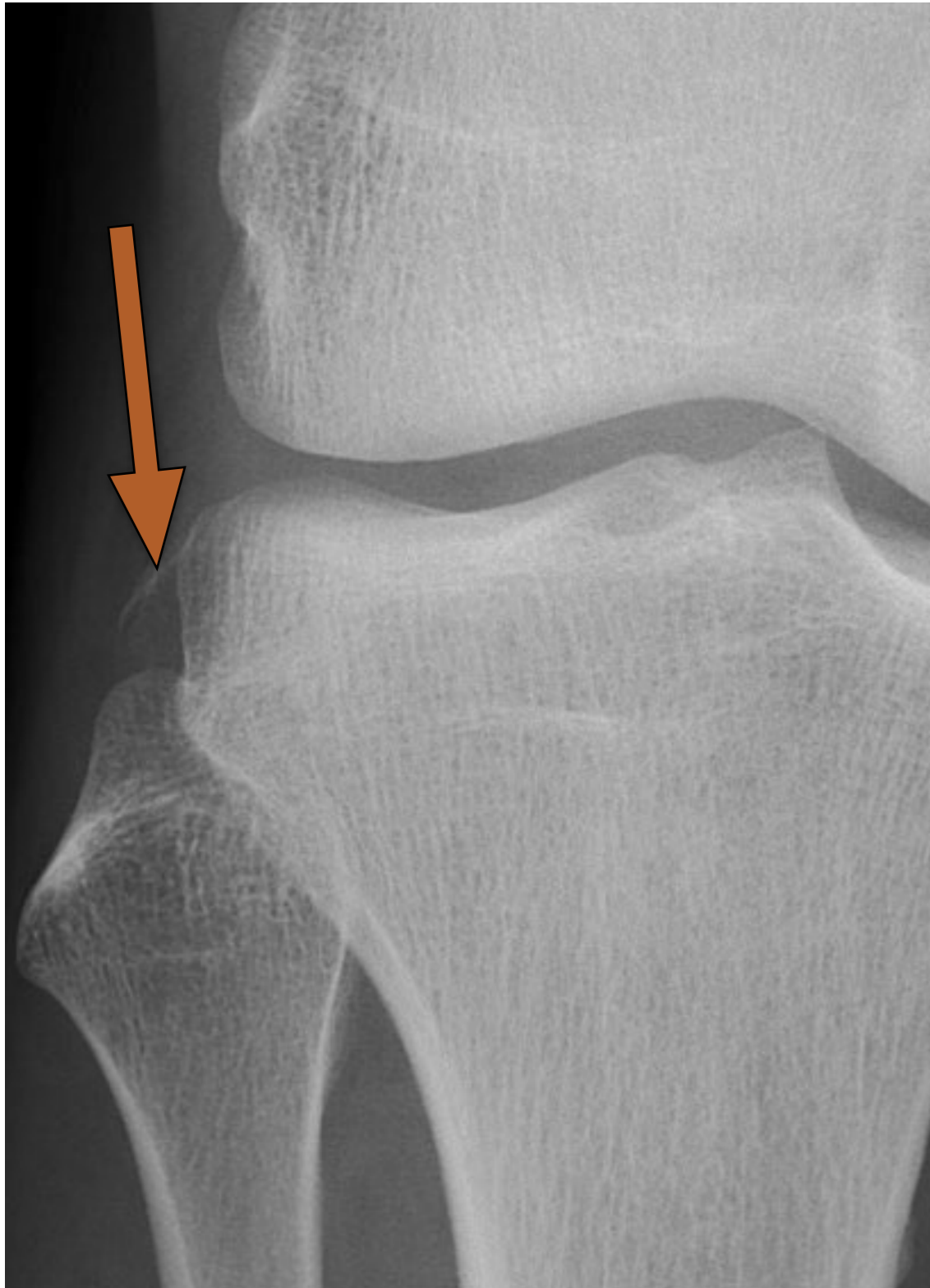## 2. Ligament Antéro Latéral LAL



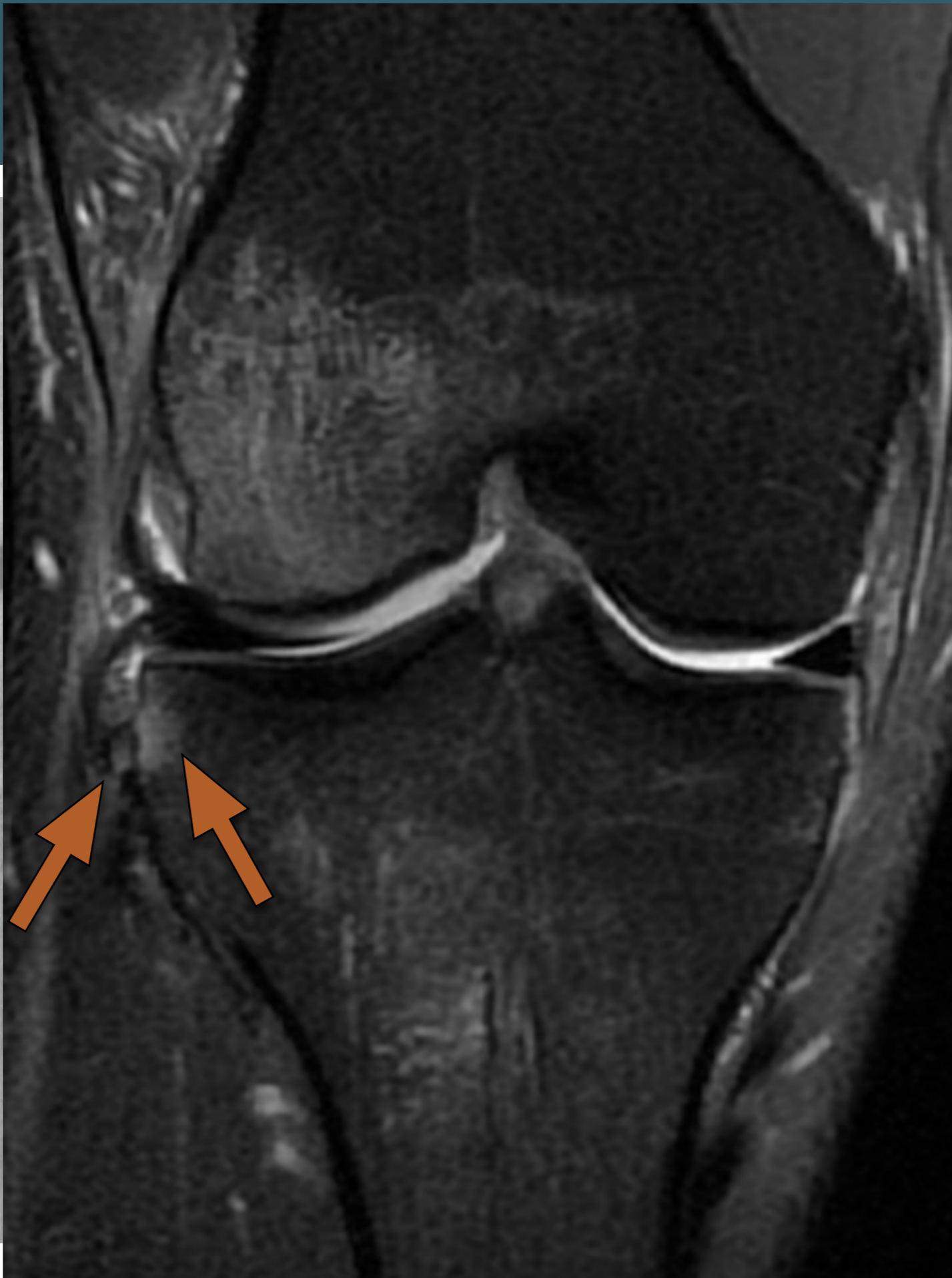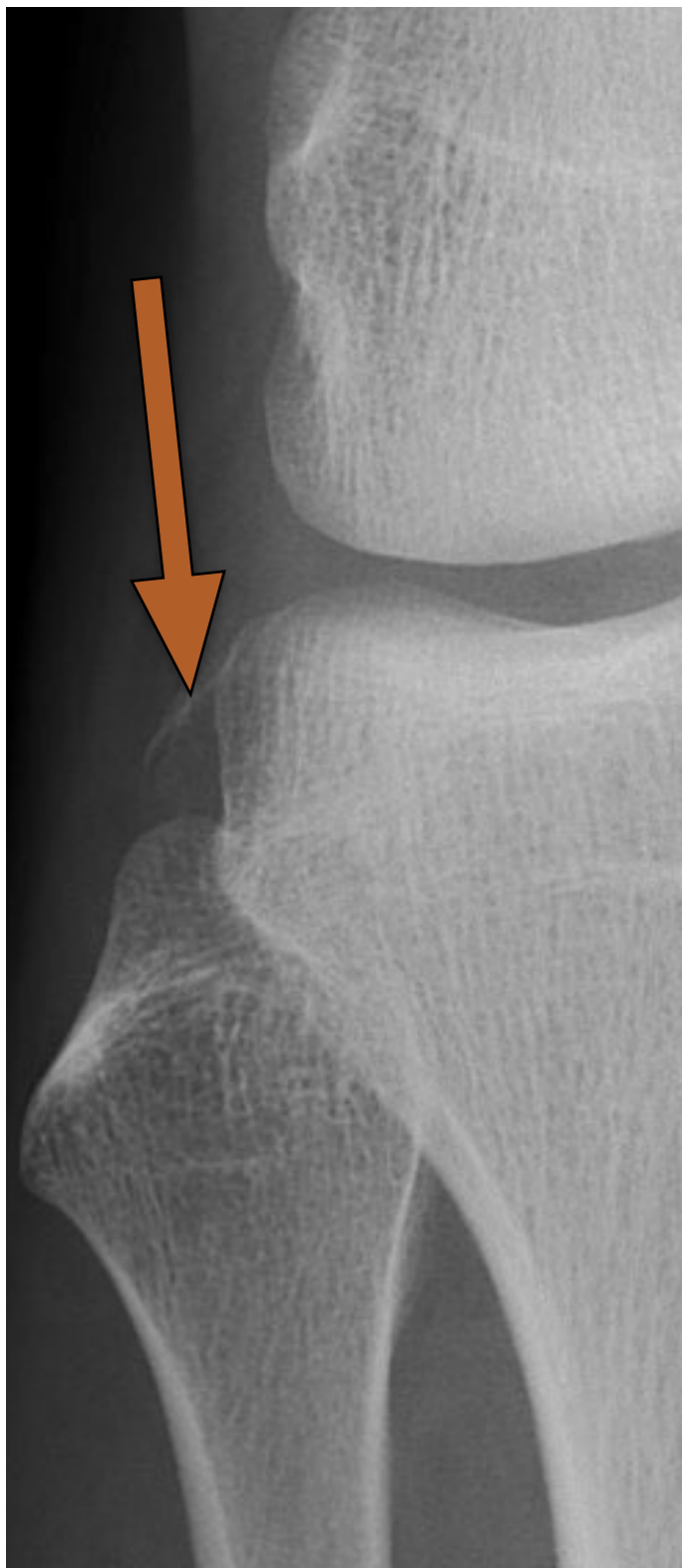## 2. LAL



## 2. LAL

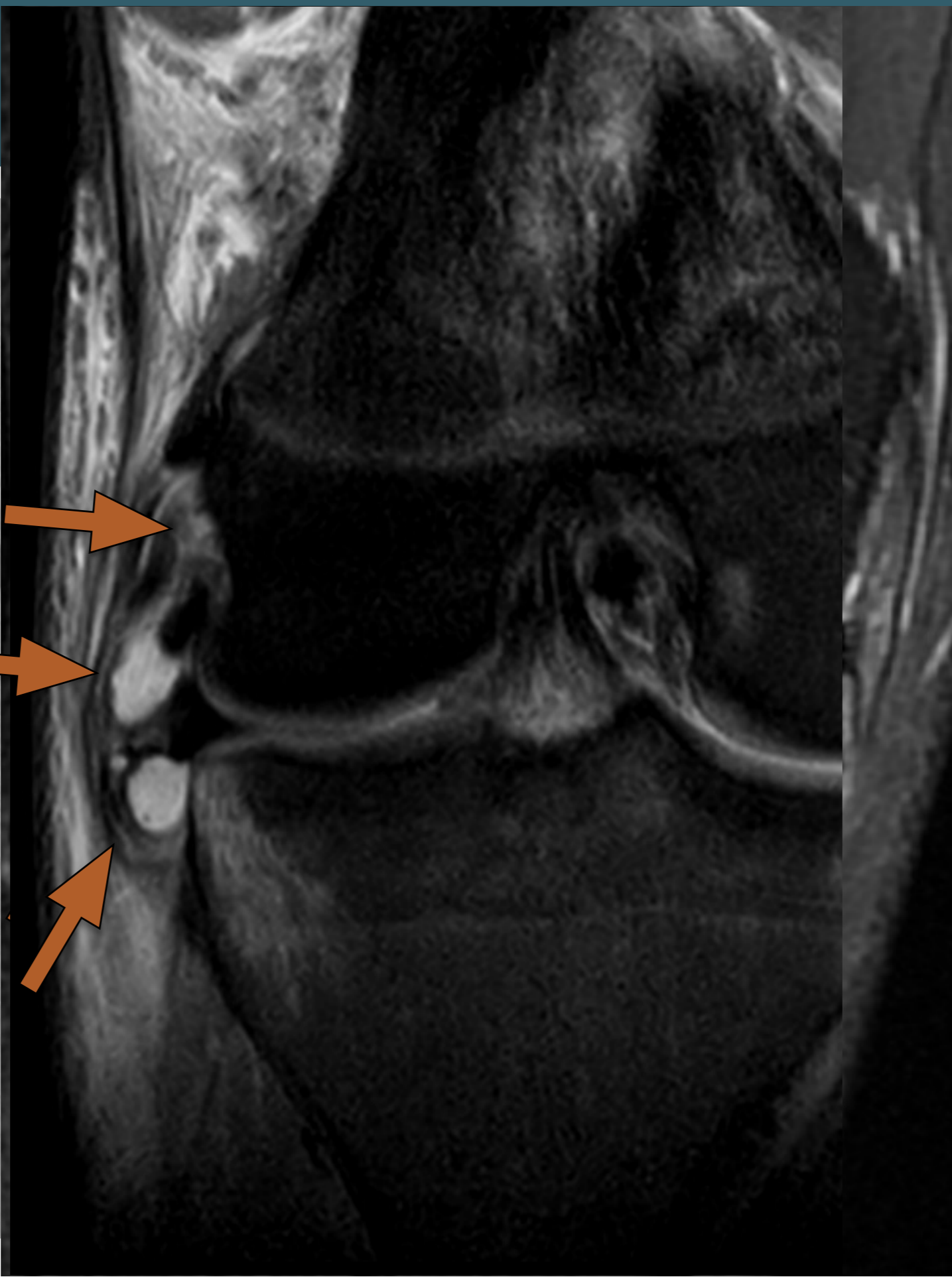
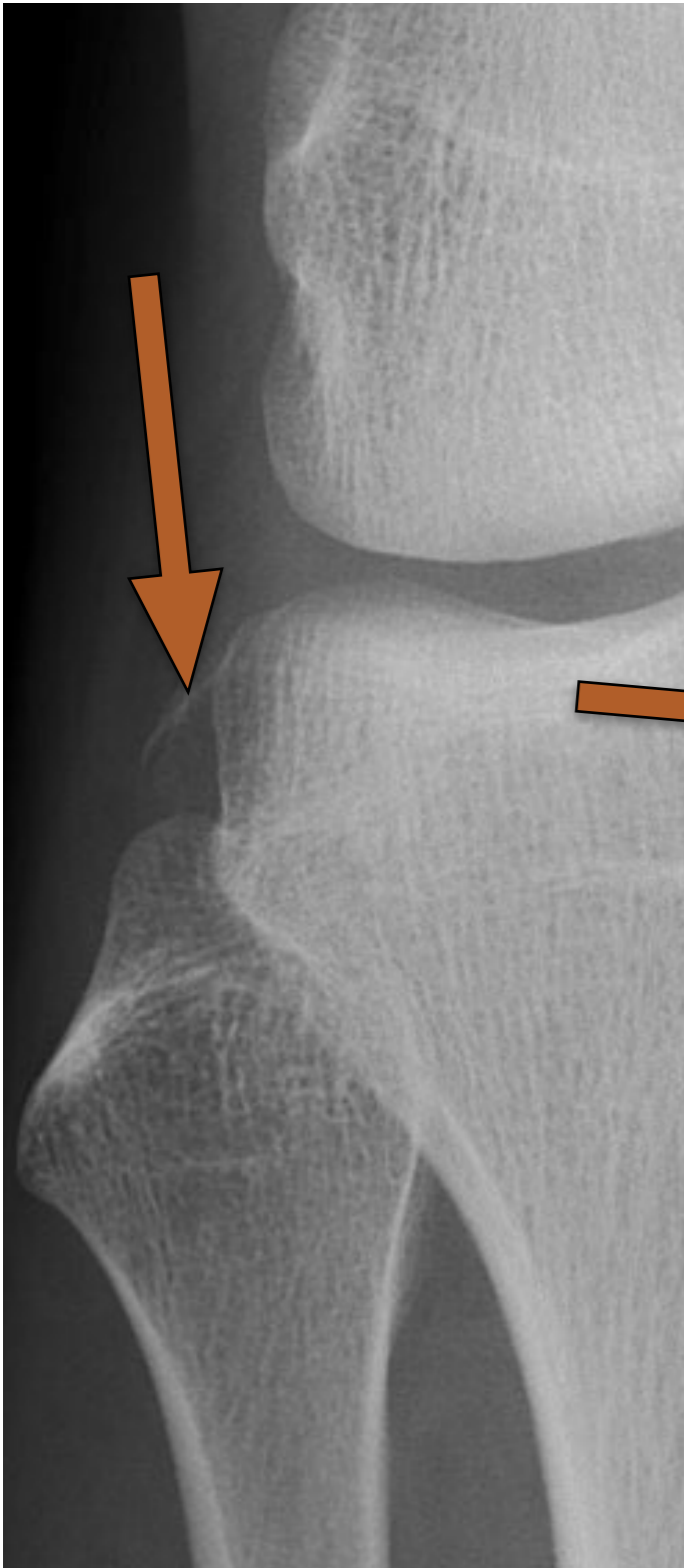


## 2. LAL

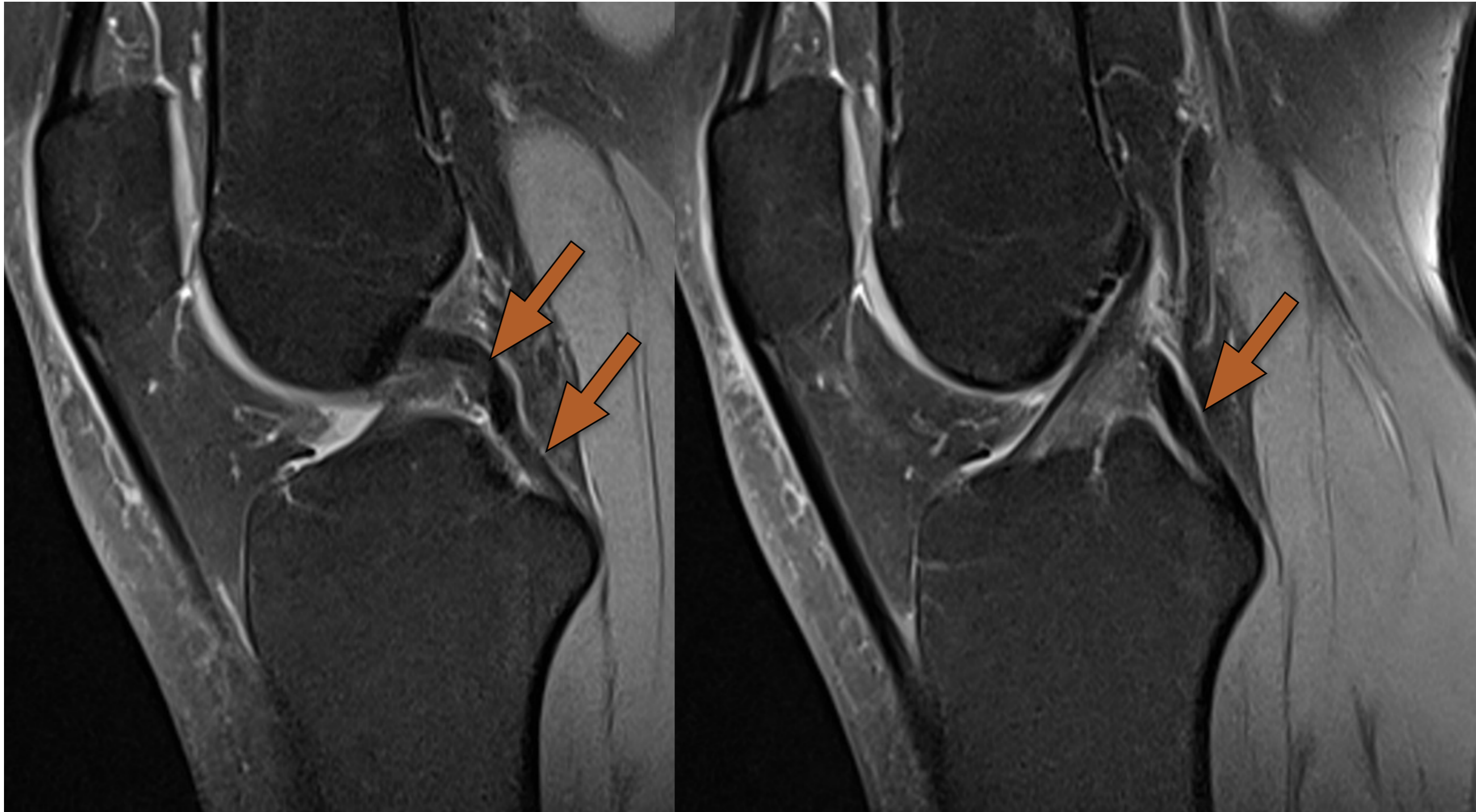




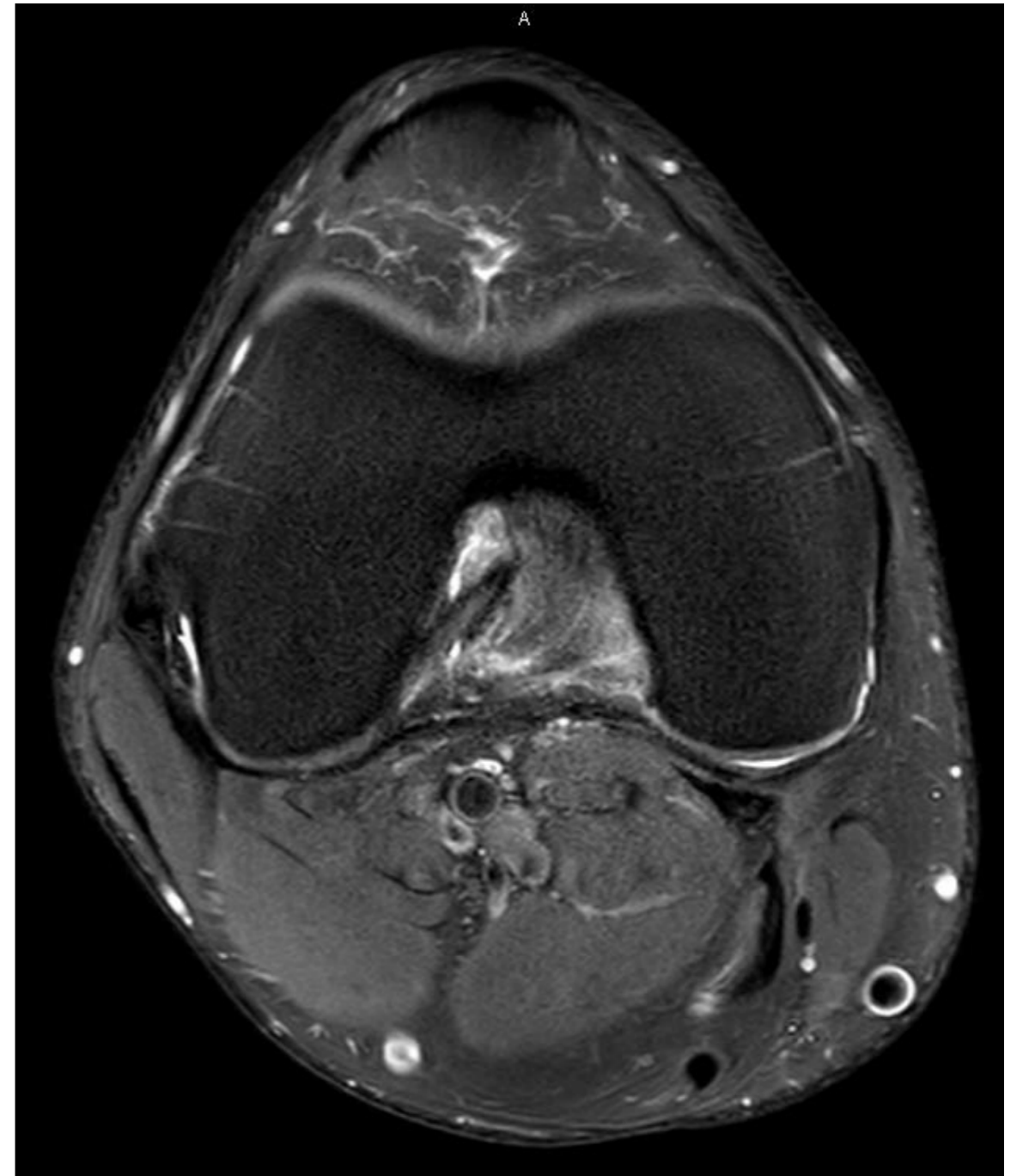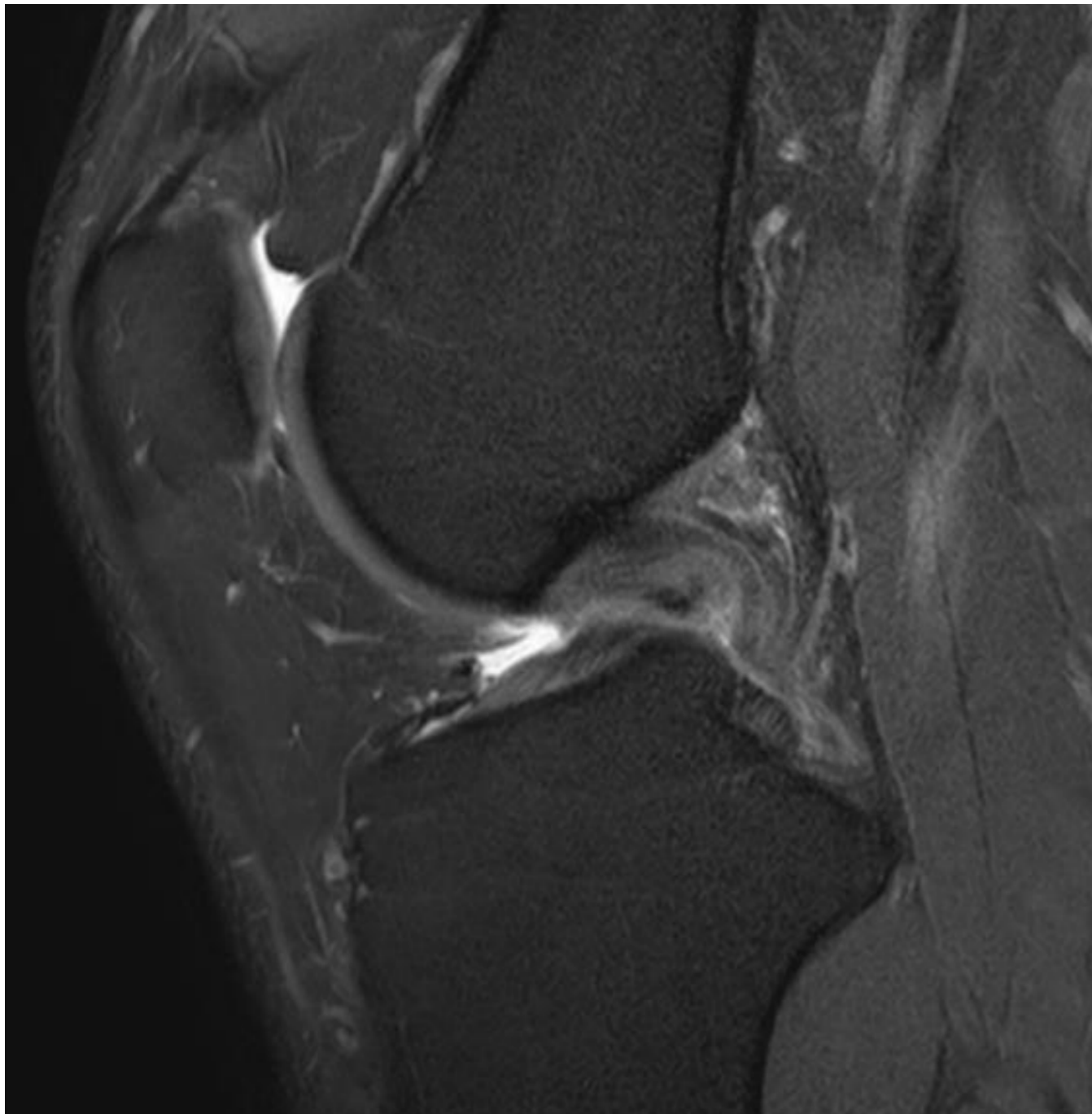
# 2. LAL



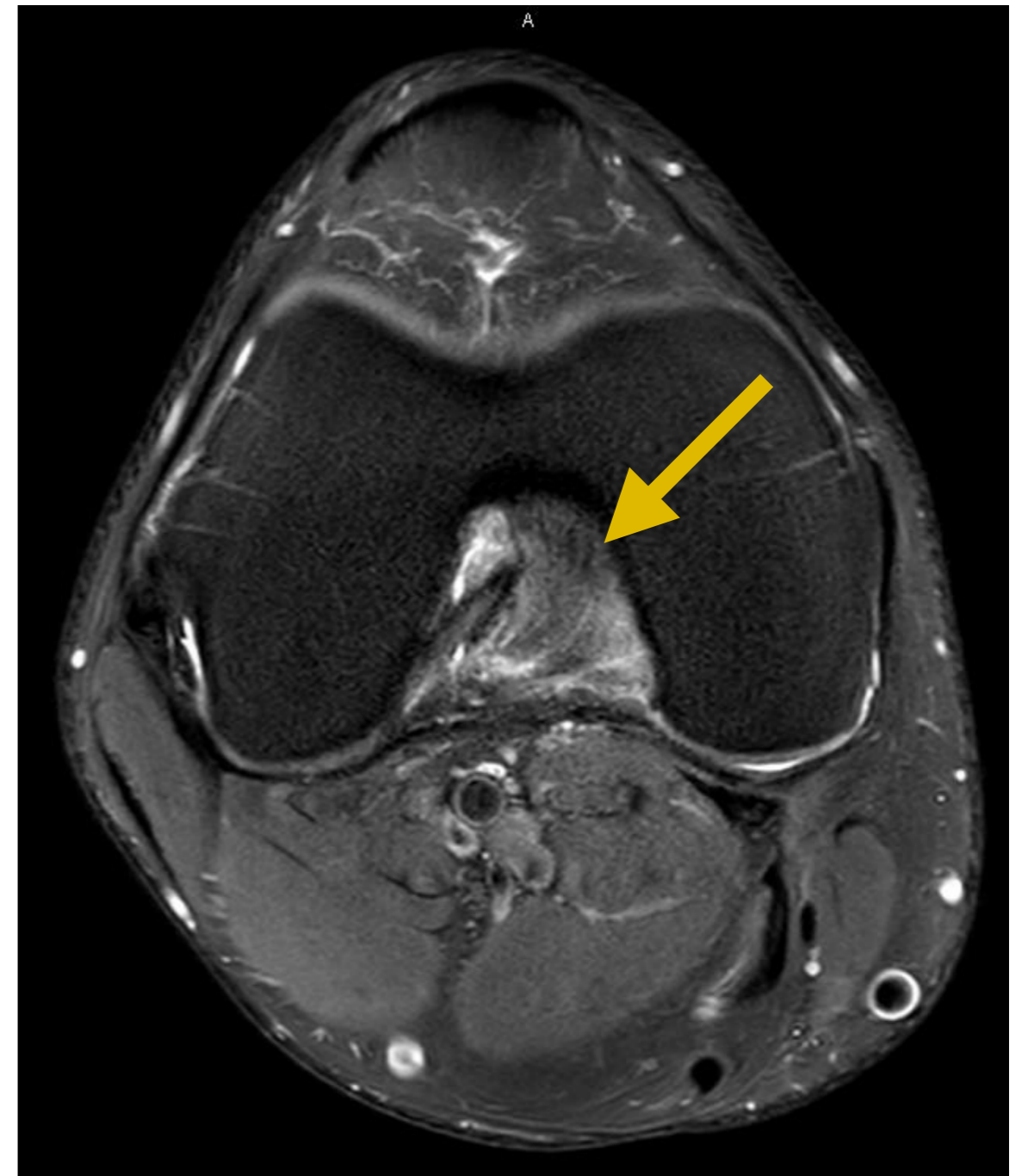
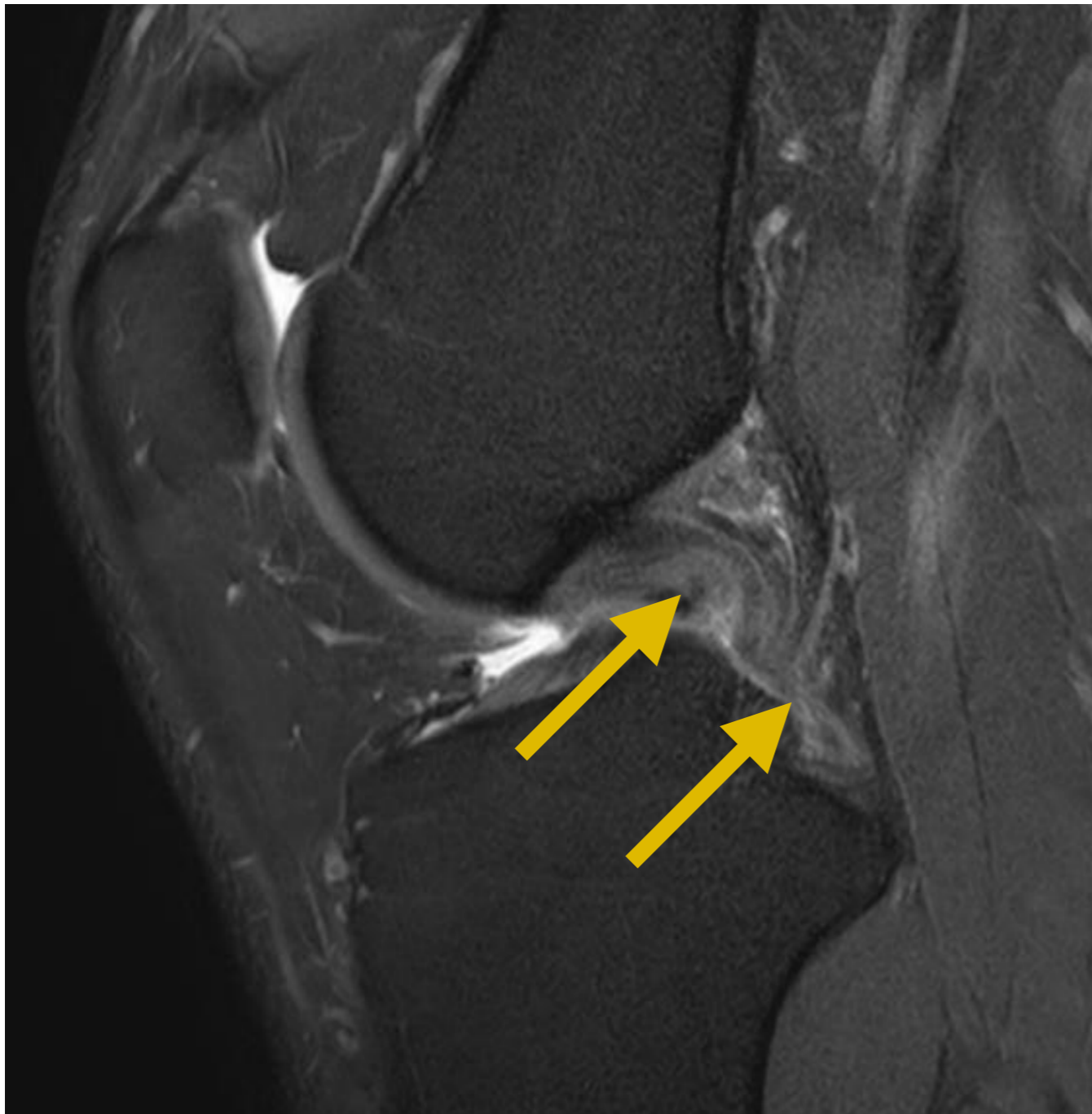
## 2. LCP normal



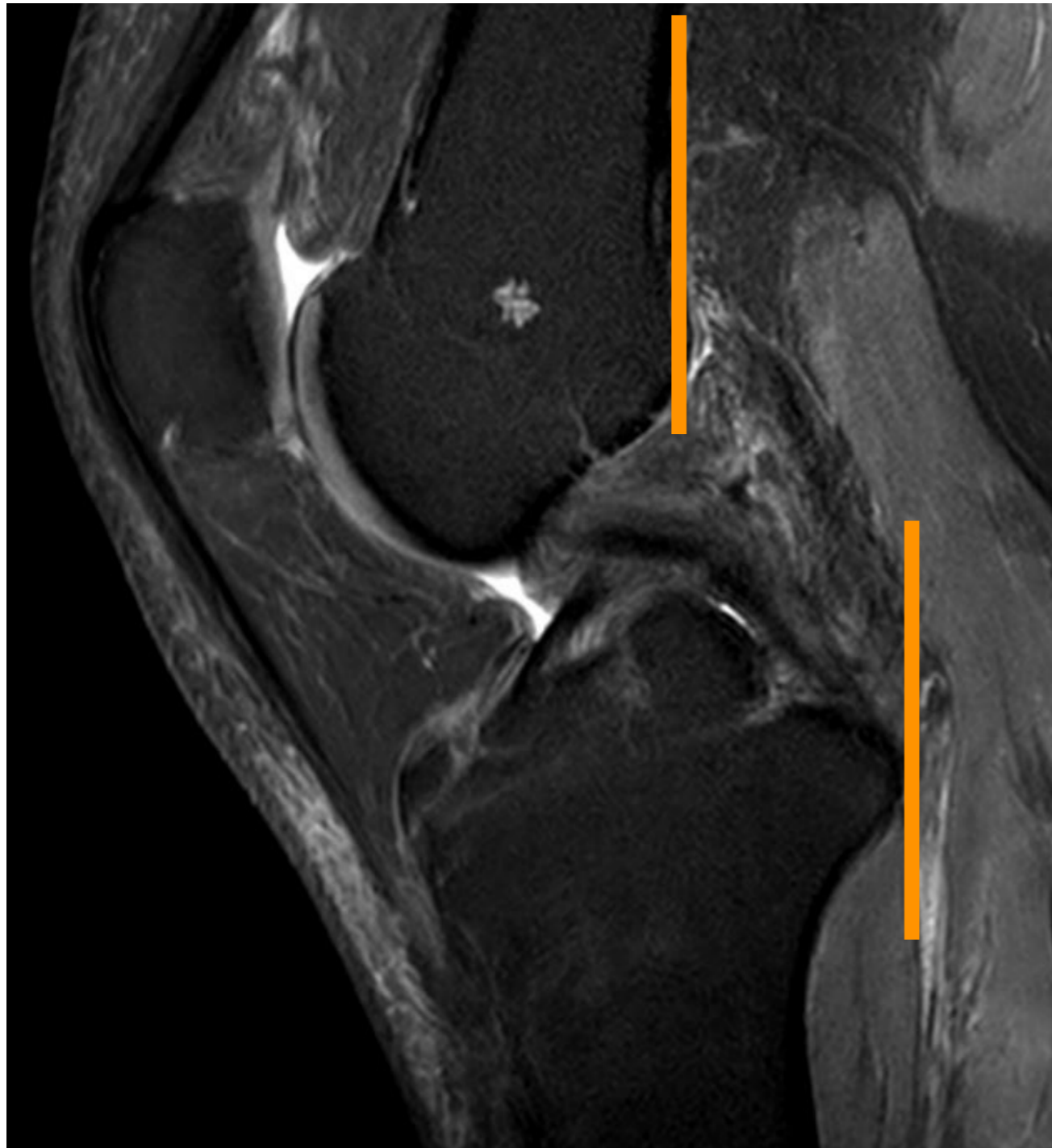## 2. LCP Entorse Interstitielle



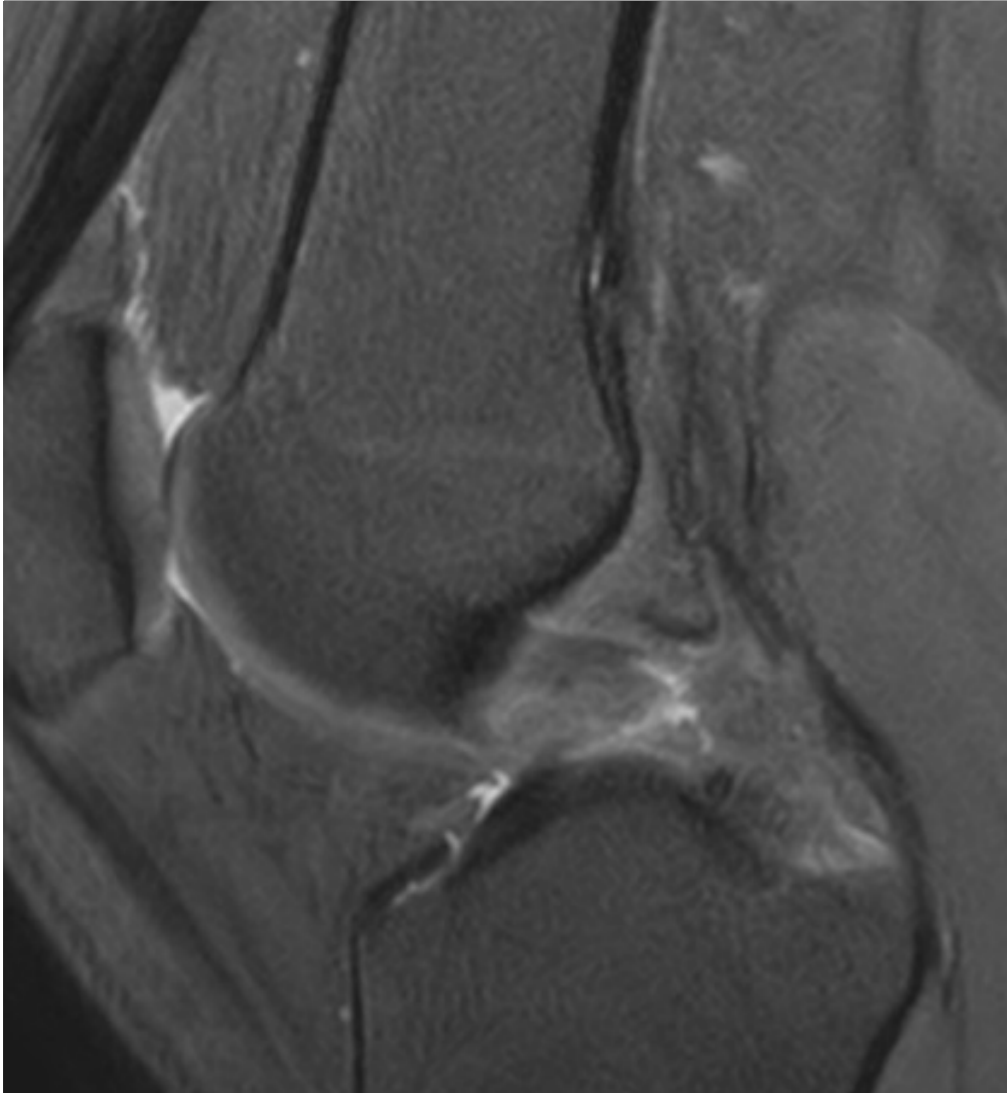
## 2. LCP Entorse Interstitielle



## 2. LCP Entorse Interstitielle



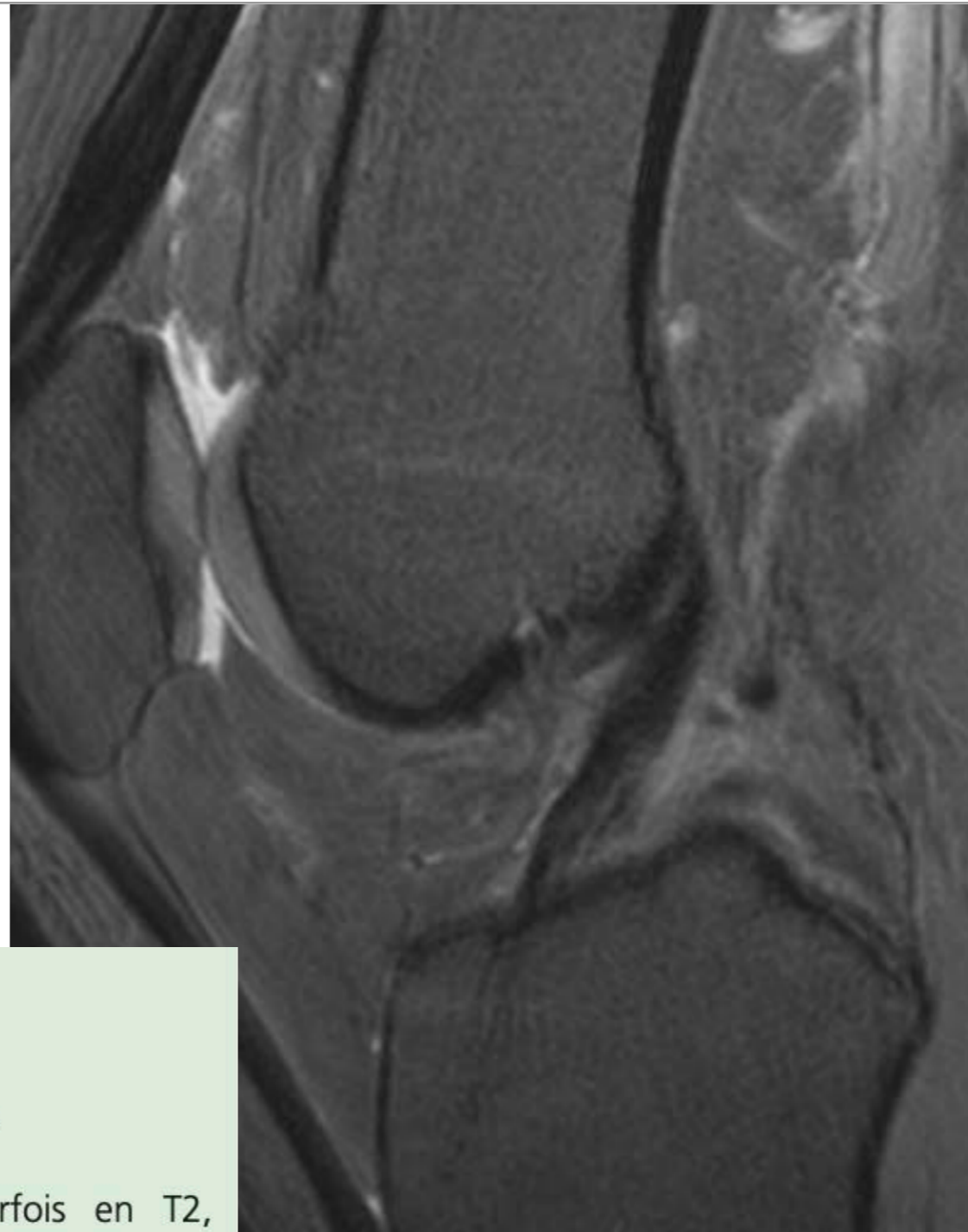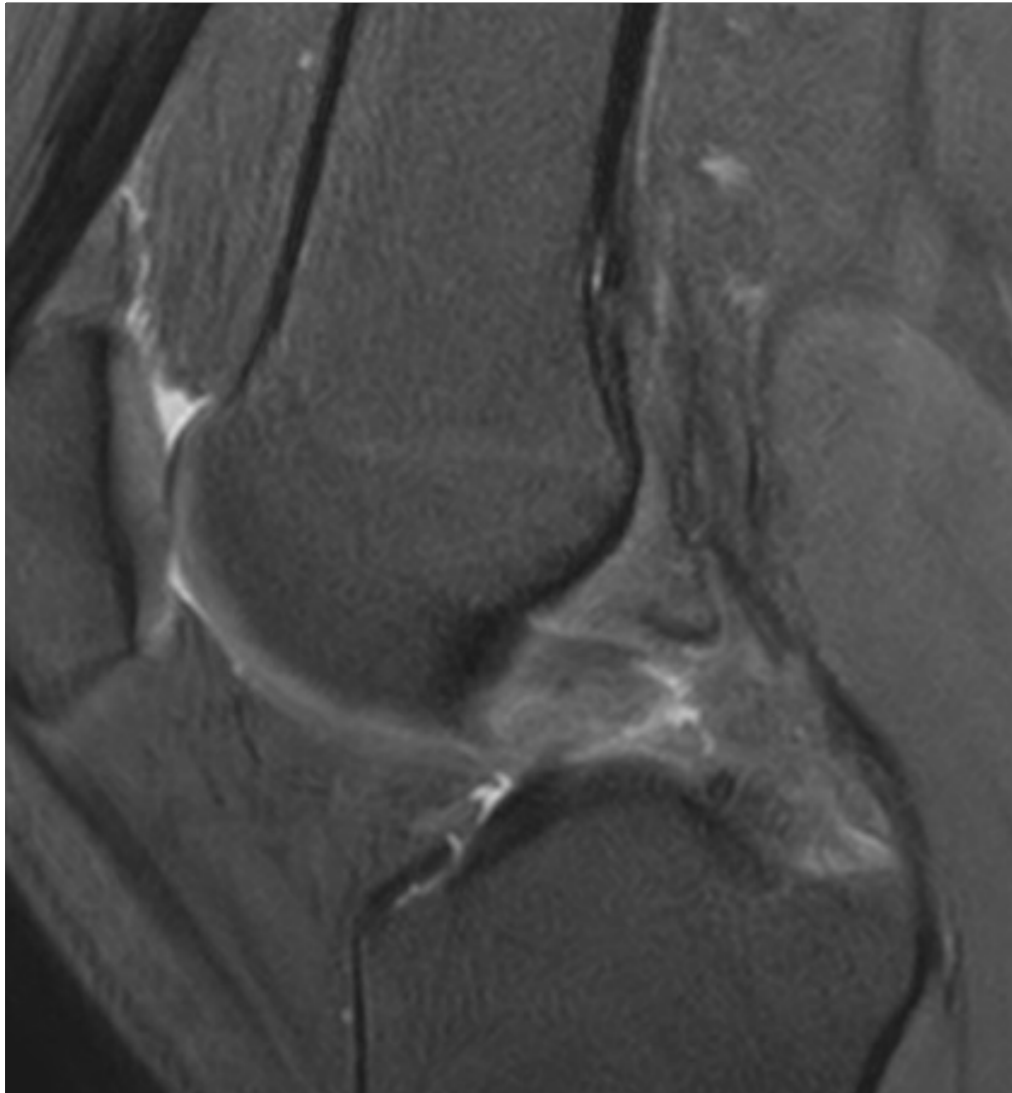
## 2. LCP Rupture



### Signes directs

- Solution de continuité complète
- Épaississement global ou segmentaire  $\geq 7$  mm
- Anomalies de ses contours (mal définis)
- Hypersignal ligamentaire relatif en T1, parfois en T2, segmentaire ou global
- Rupture chronique : LCP intact (fibrose cicatricielle), aminci, allongé, focalement épaissi

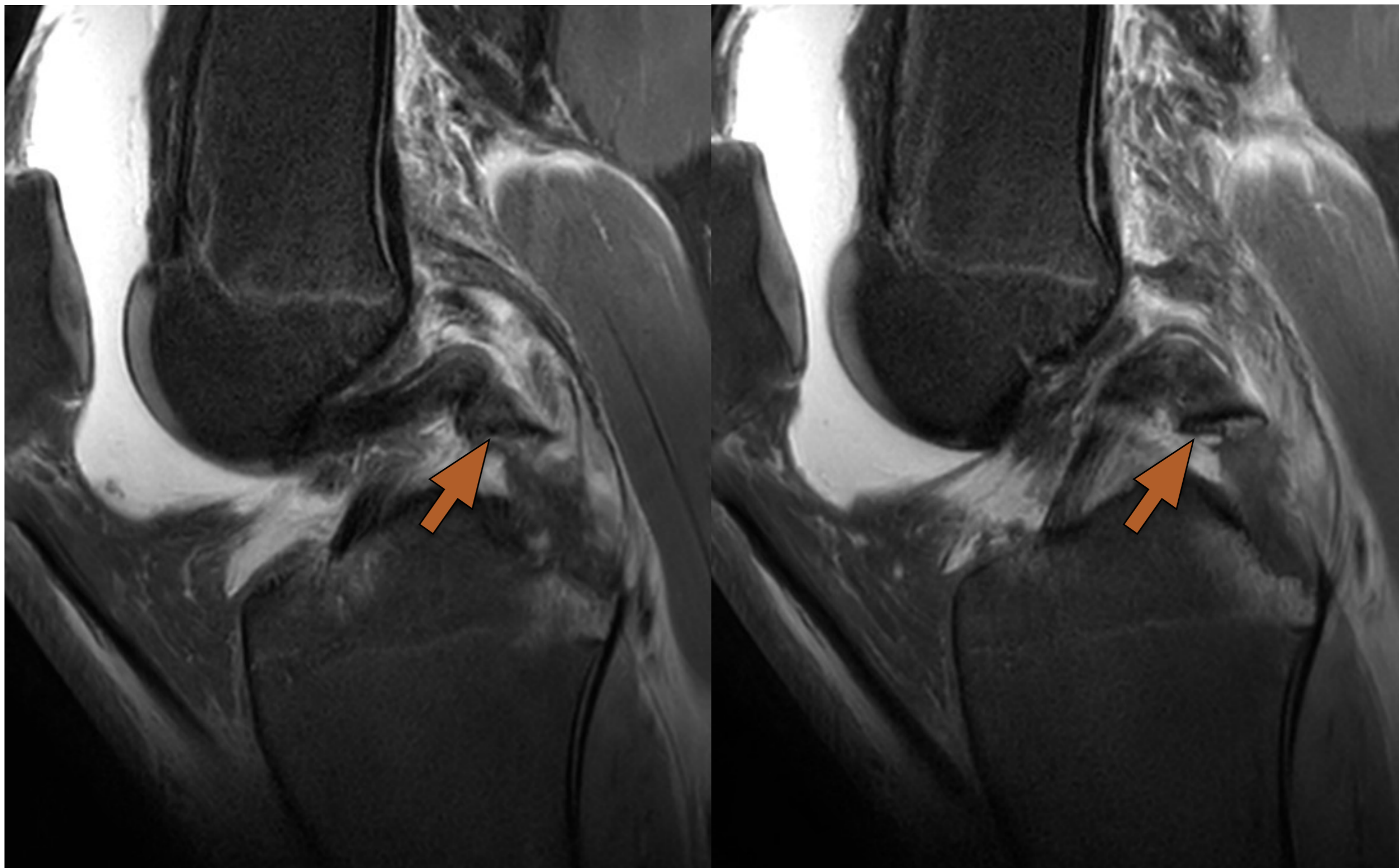
## 2. LCP Rupture



### Signes directs

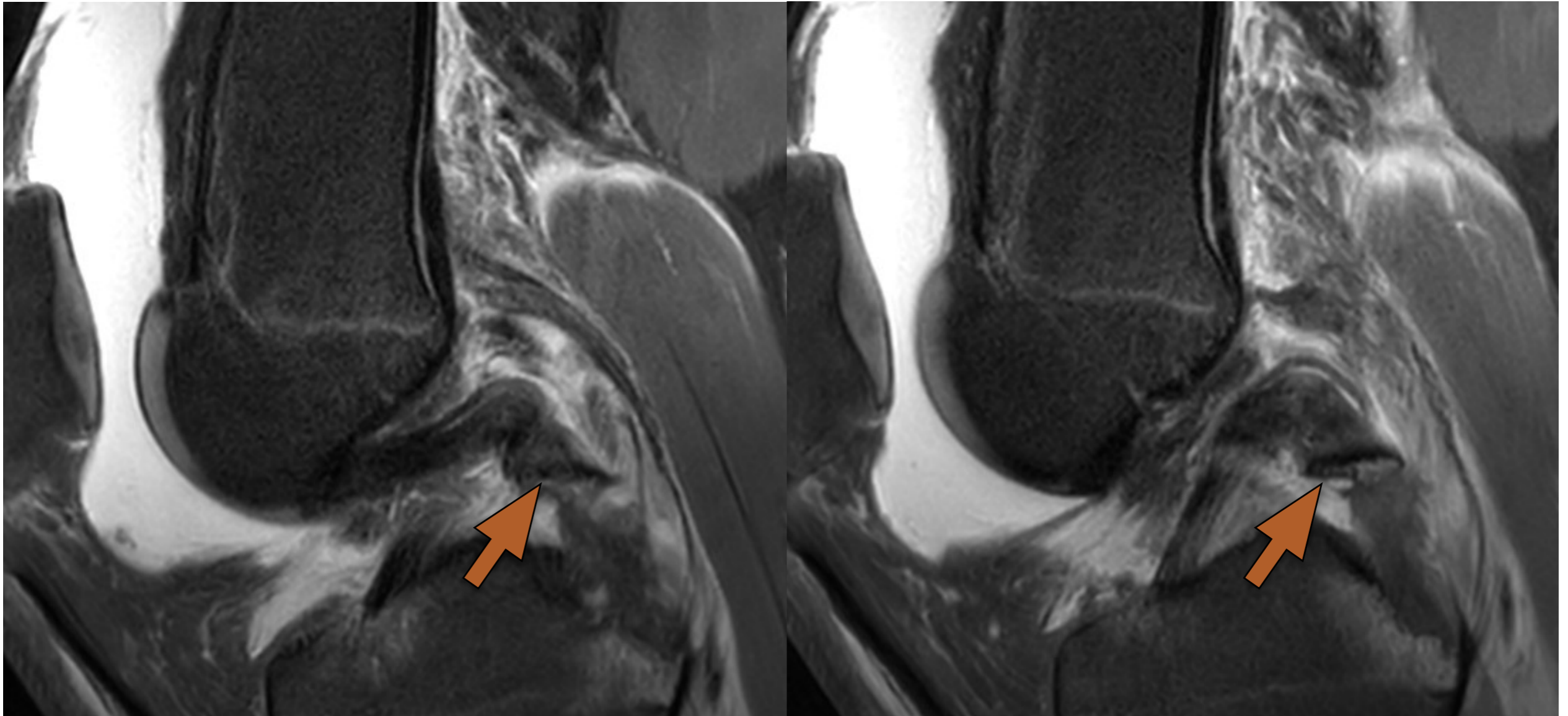
- Solution de continuité complète
- Épaississement global ou segmentaire  $\geq 7$  mm
- Anomalies de ses contours (mal définis)
- Hypersignal ligamentaire relatif en T1, parfois en T2, segmentaire ou global
- Rupture chronique : LCP intact (fibrose cicatricielle), aminci, allongé, focalement épaissi

## 2. LCP Rupture





## 2. LCP Rupture

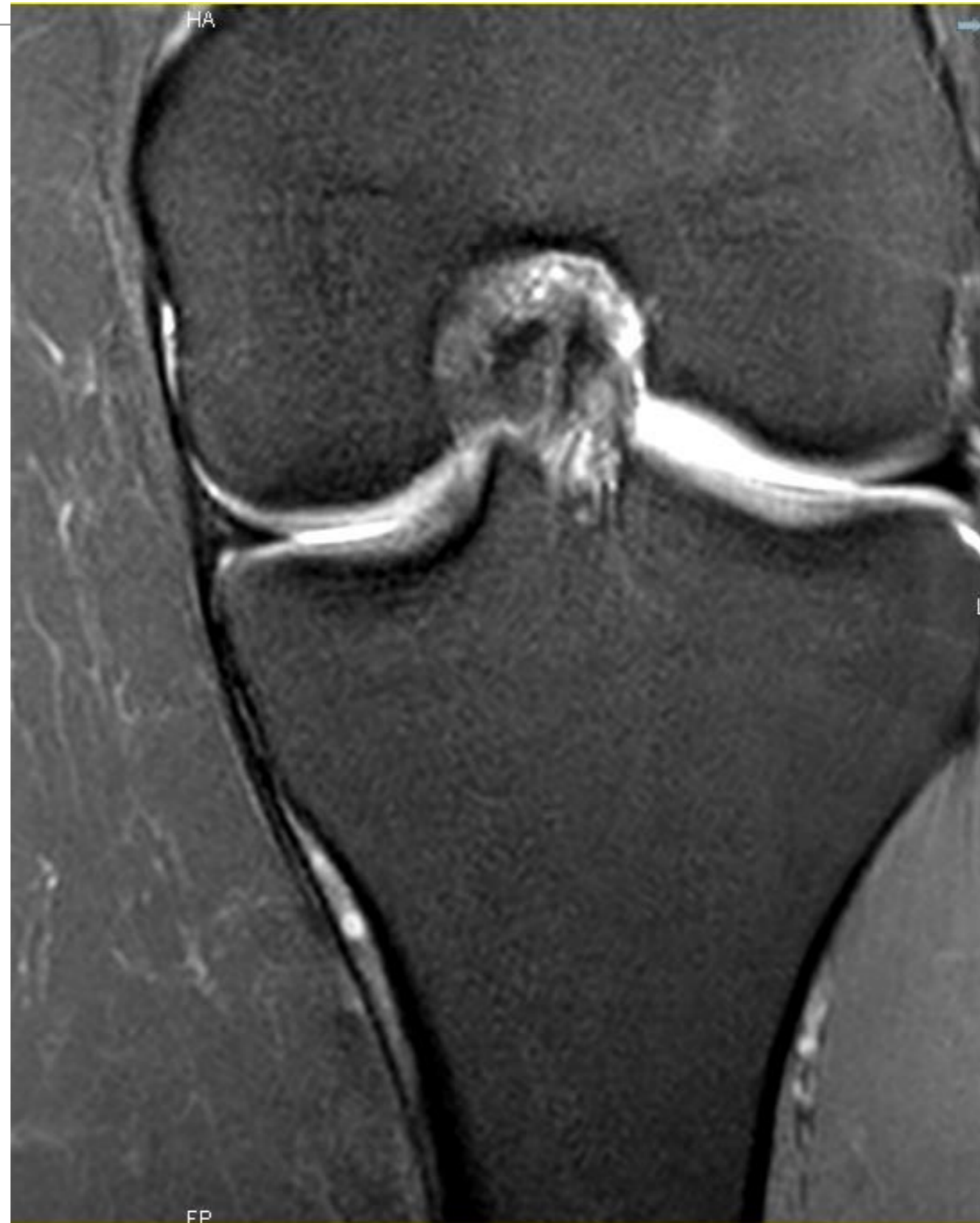

### Signes indirects

- Avulsion osseuse de l'aire intercondyalaire postérieure
- Contusions osseuses (*kissing injury*)
- Tiroir postérieur spontané du compartiment médial  $\geq 3$  mm
- Fracture de Segond inversée

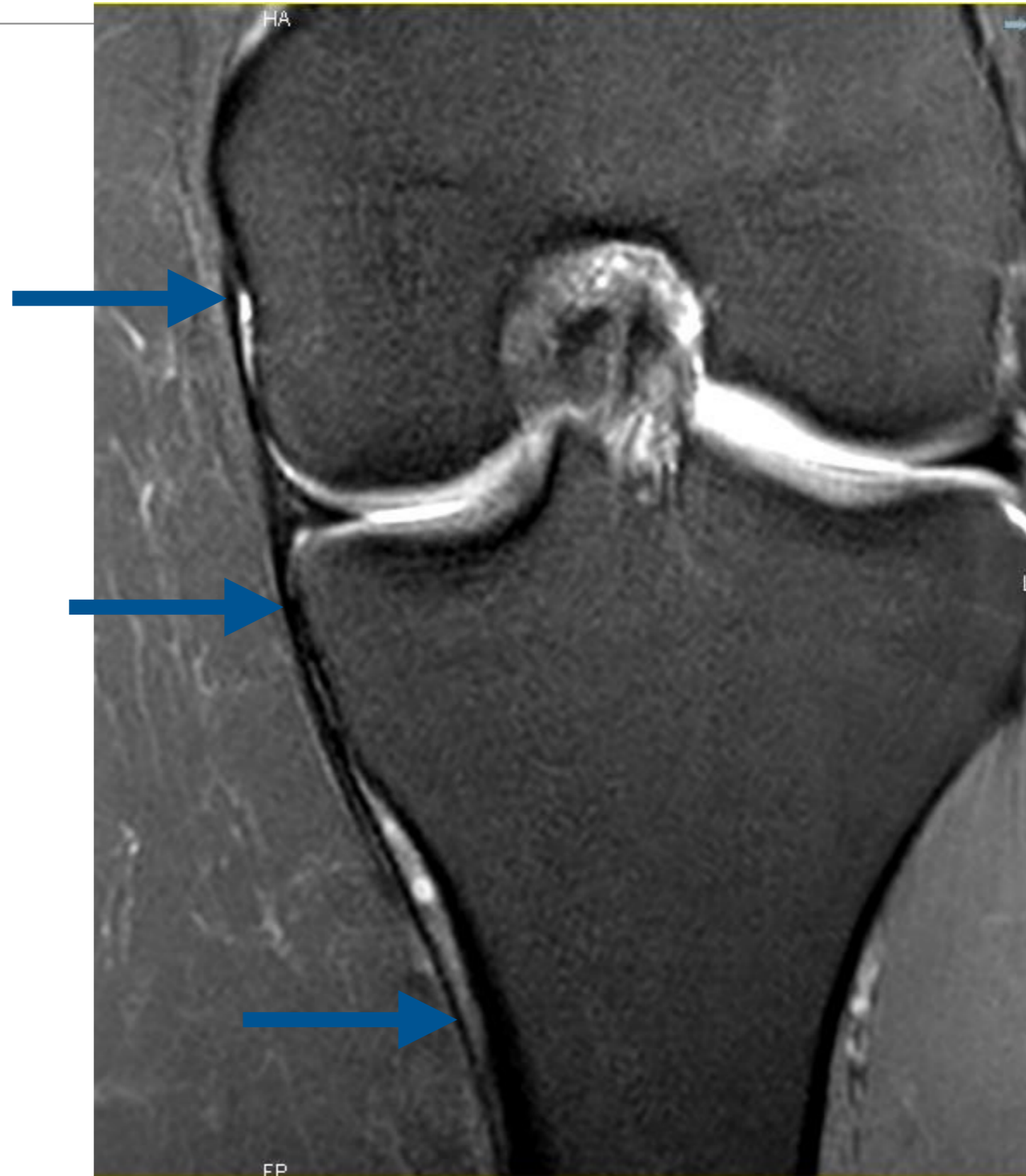
# **3. Ligaments et points d'angle**

### 3. Ligament Collatéral Médial



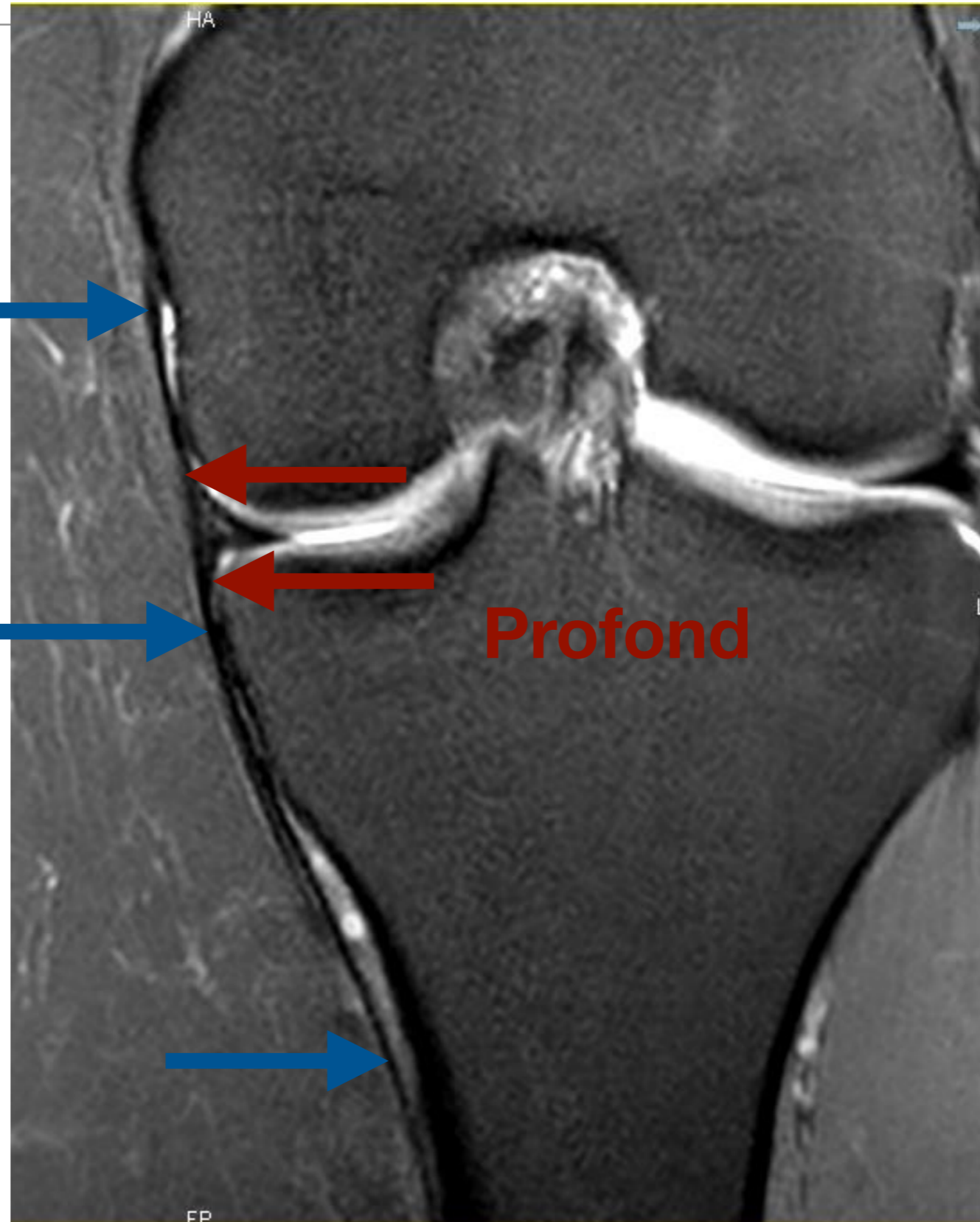
### 3. Ligament Collatéral Médial

**Superficiel**



### 3. Ligament Collatéral Médial

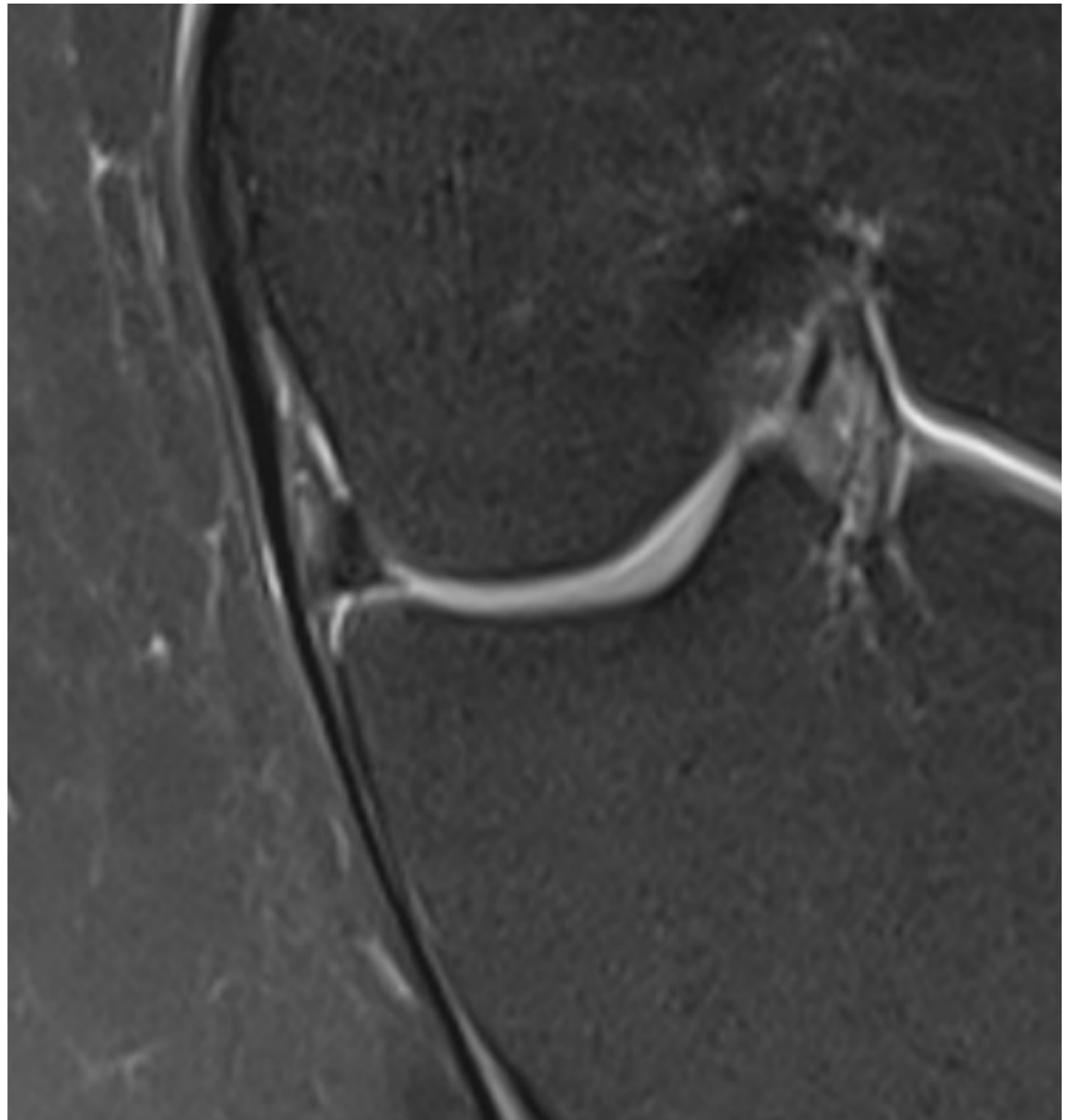
**Superficiel**



**Profond**

### 3. Ligament Collatéral Médial

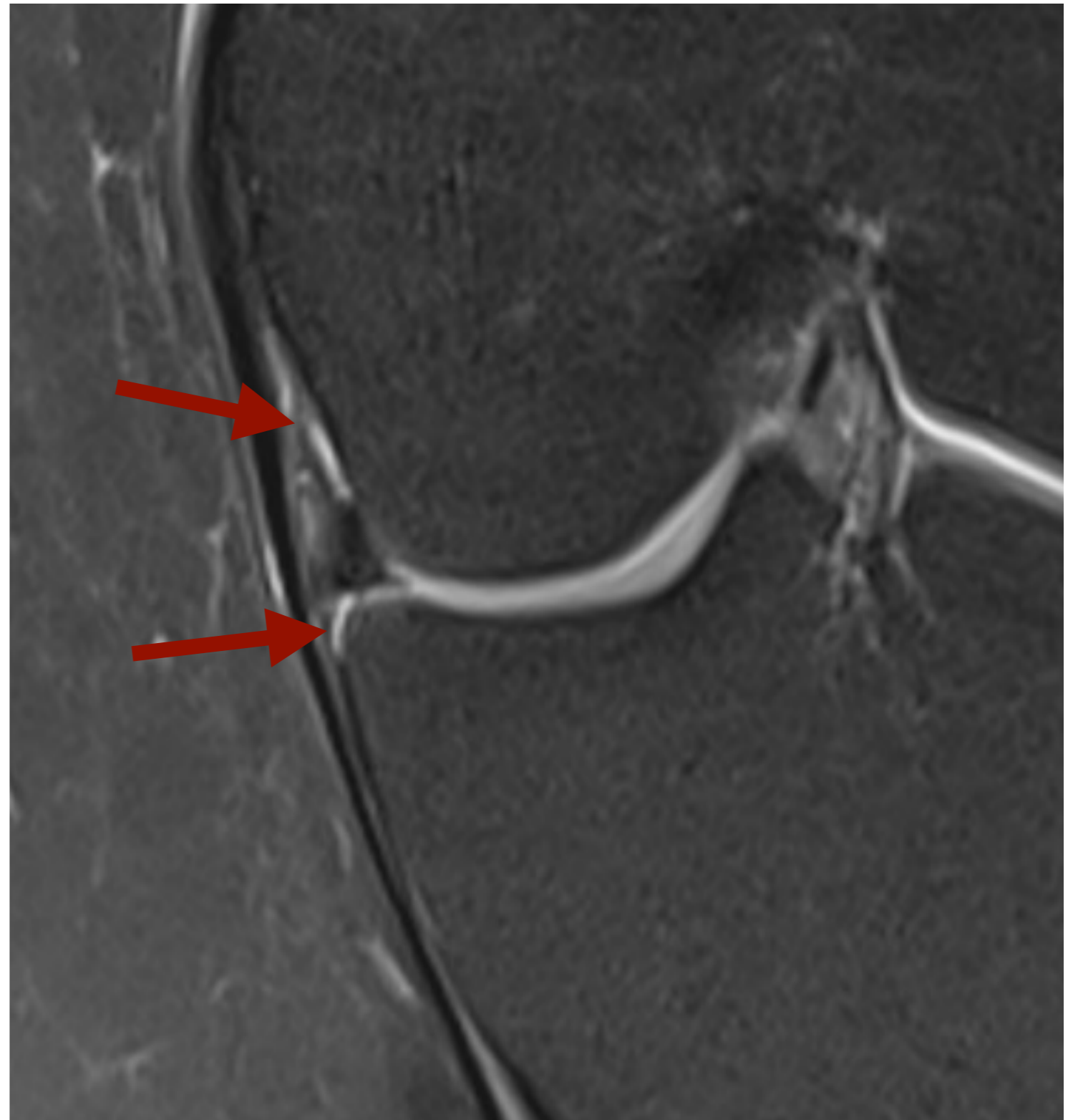---



### 3. Ligament Collatéral Médial

**LCM Profond**

**Ménisco-fémoral**  
**Ménisco-tibial**



# 3. Ligament Collatéral Médial

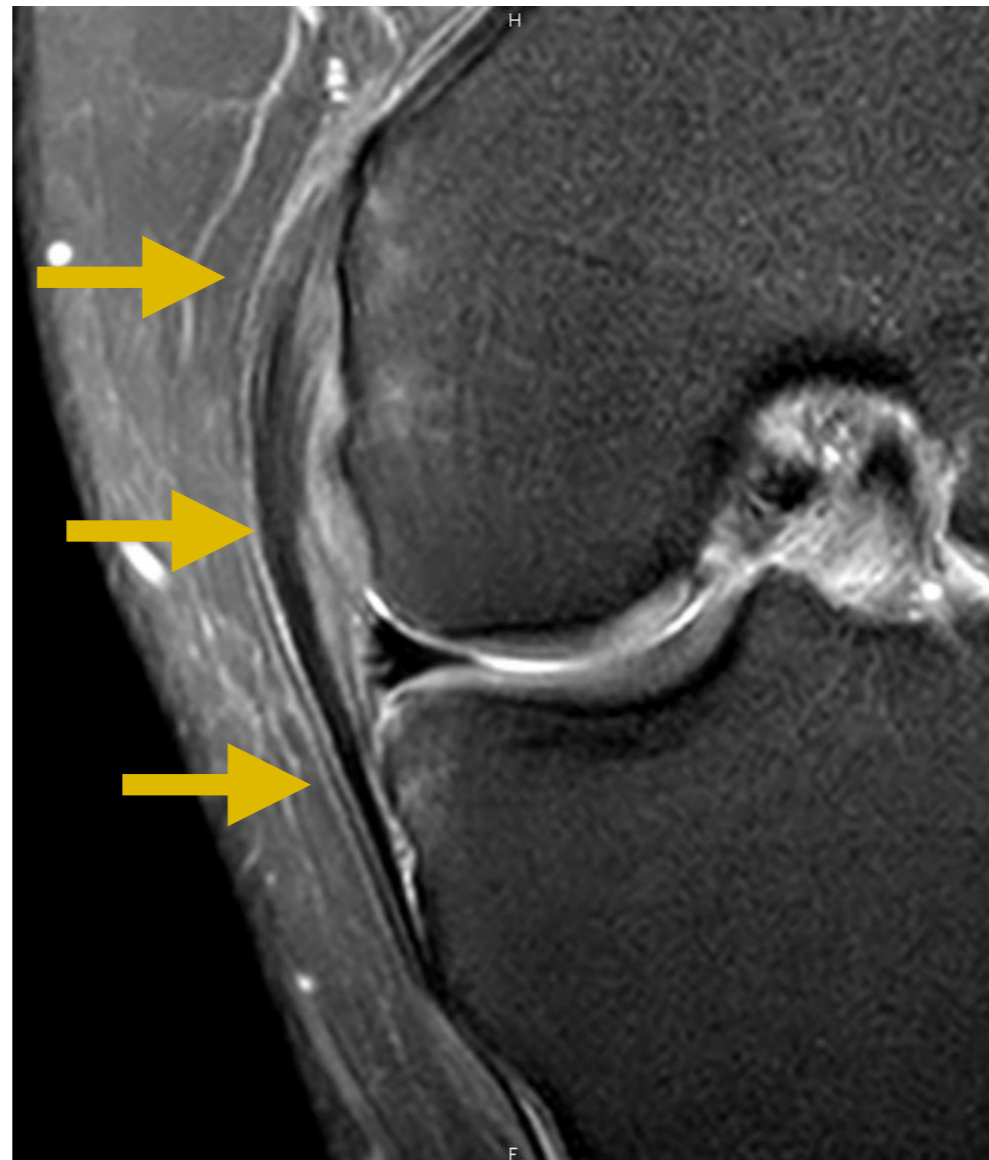
---

- LCM : analyse de chaque faisceau
  - GRADE 1 : **HYPERSIGNAL DP ligamentaire, non liquidien**
  - GRADE 2 : fissure ligamentaire en **HYPERSIGNAL DP LIQUIDIEN**
    - +/- distension ?
  - GRADE 3 : **Rupture**



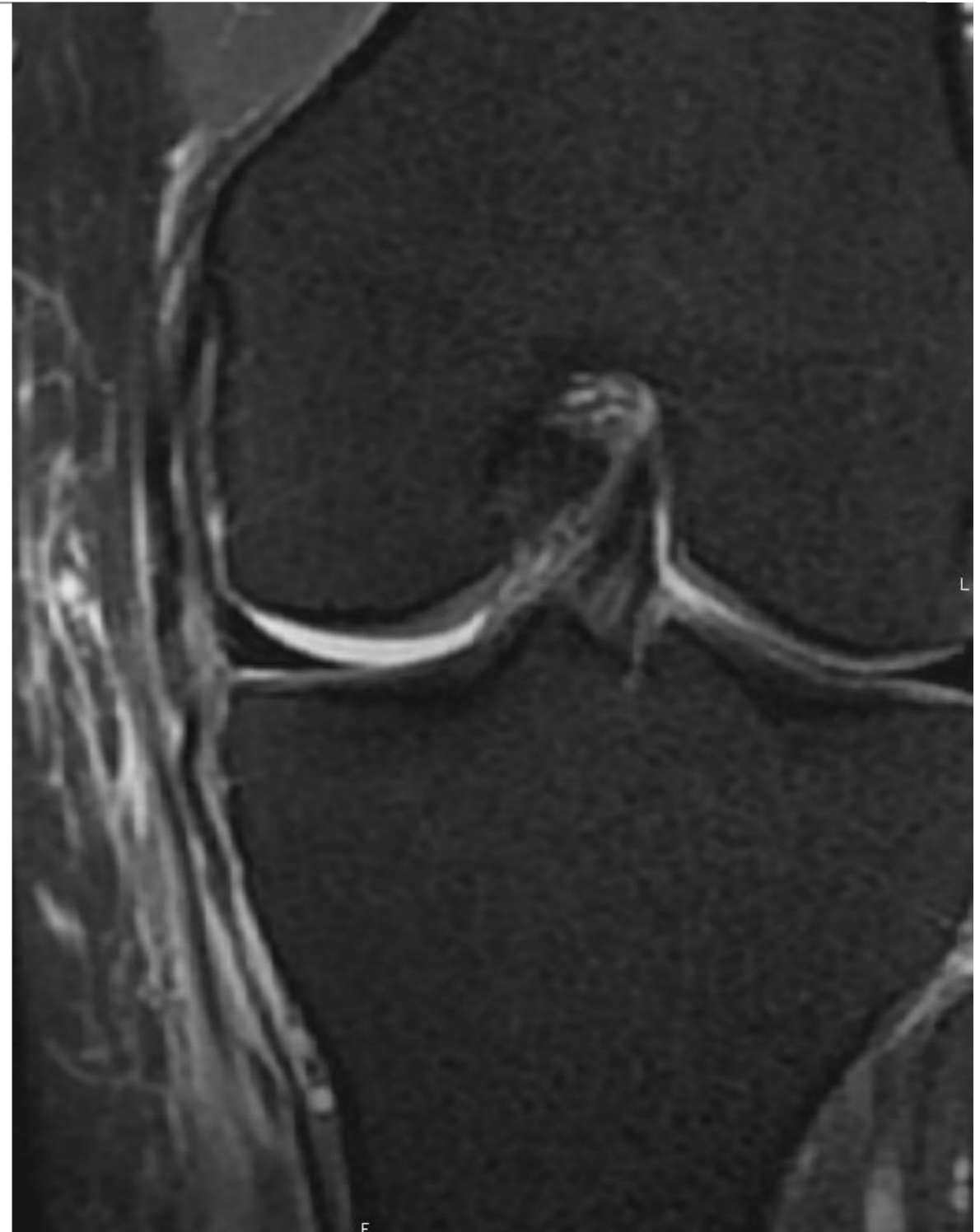
# 3. Ligament Collatéral Médial

- Grade 1



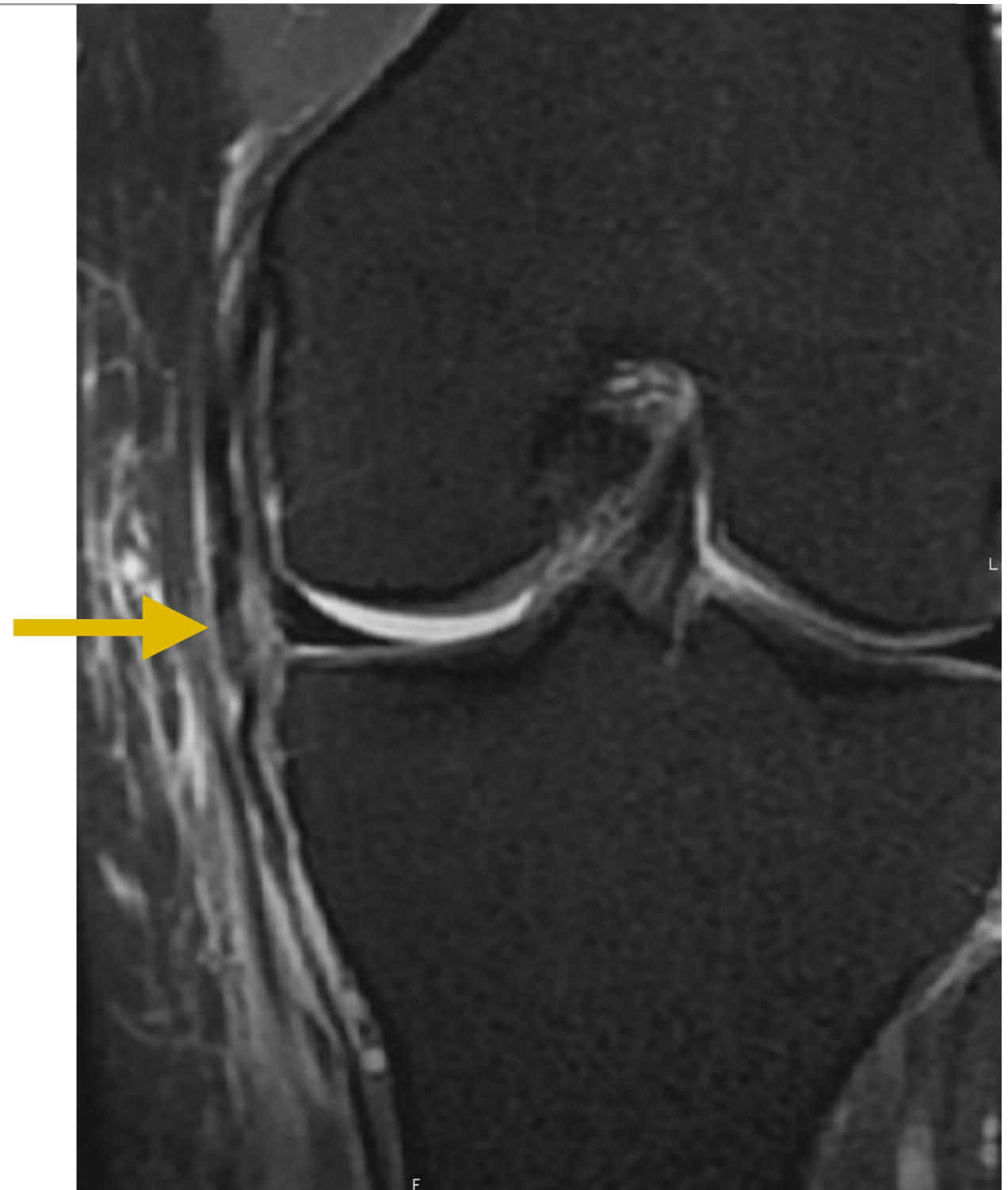
### 3. Ligament Collatéral Médial

- Grade 2
- Mais distension faisceau superficiel



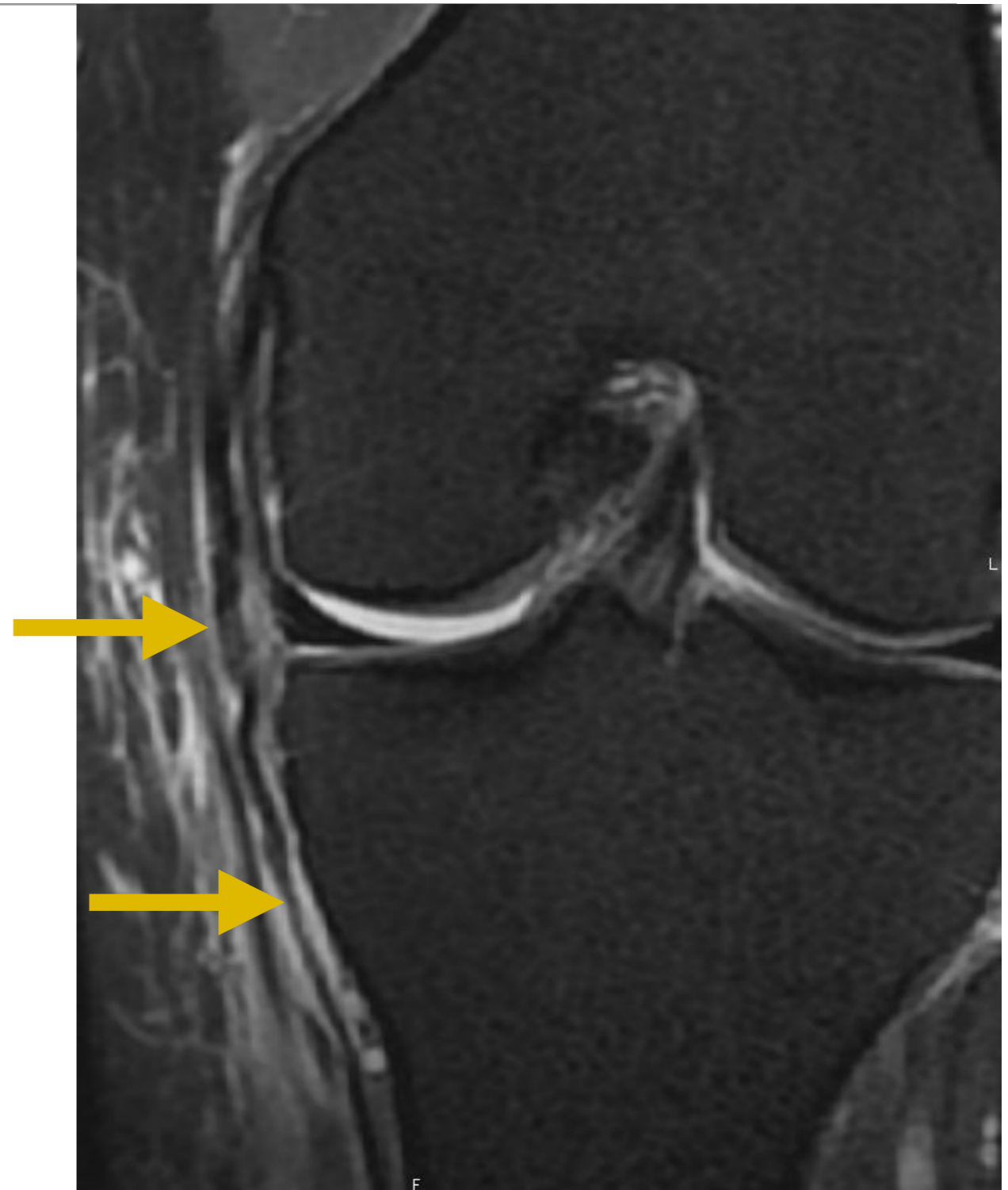
### 3. Ligament Collatéral Médial

- Grade 2
- Mais distension faisceau superficiel



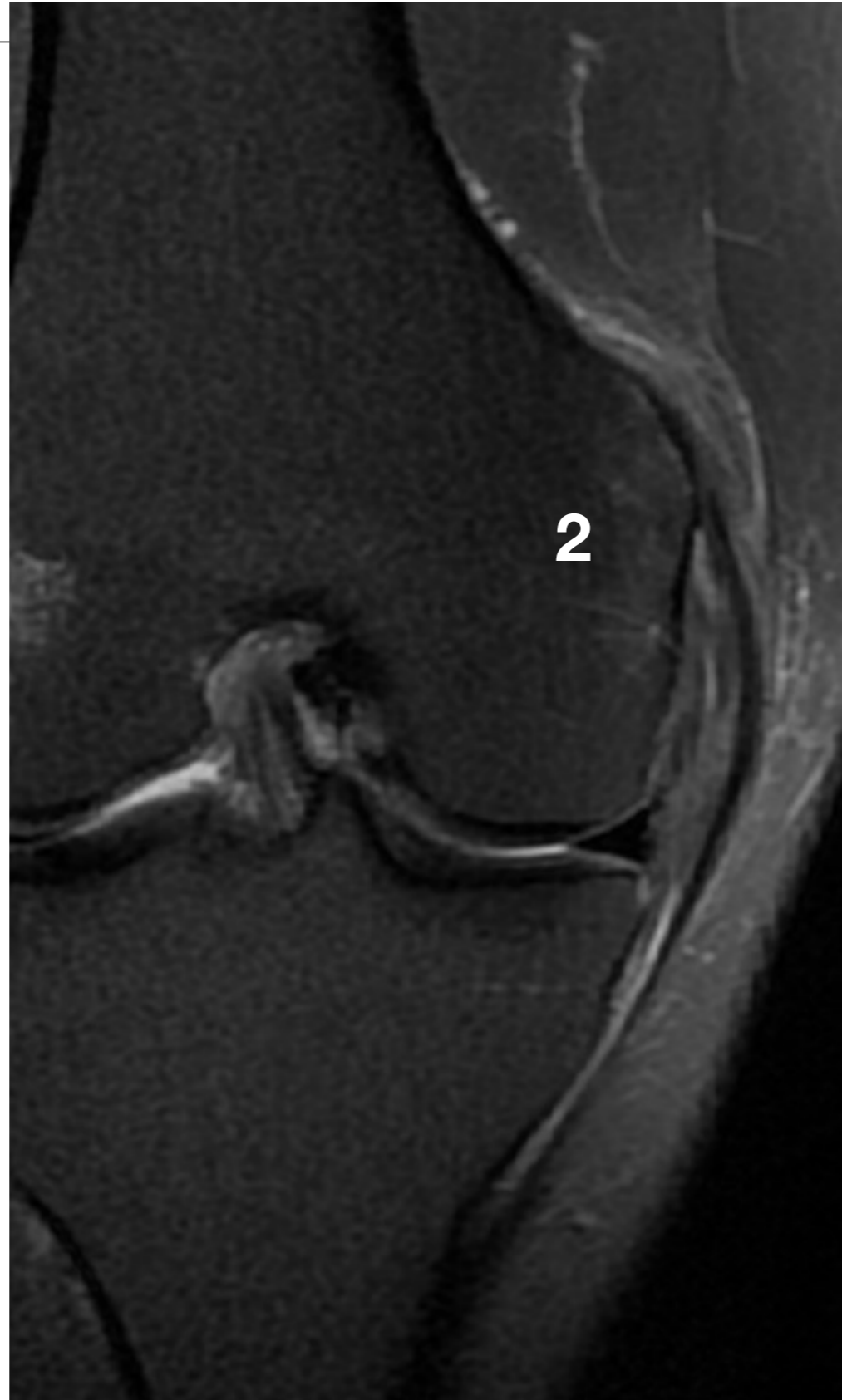### 3. Ligament Collatéral Médial

- Grade 2
- Mais distension faisceau superficiel



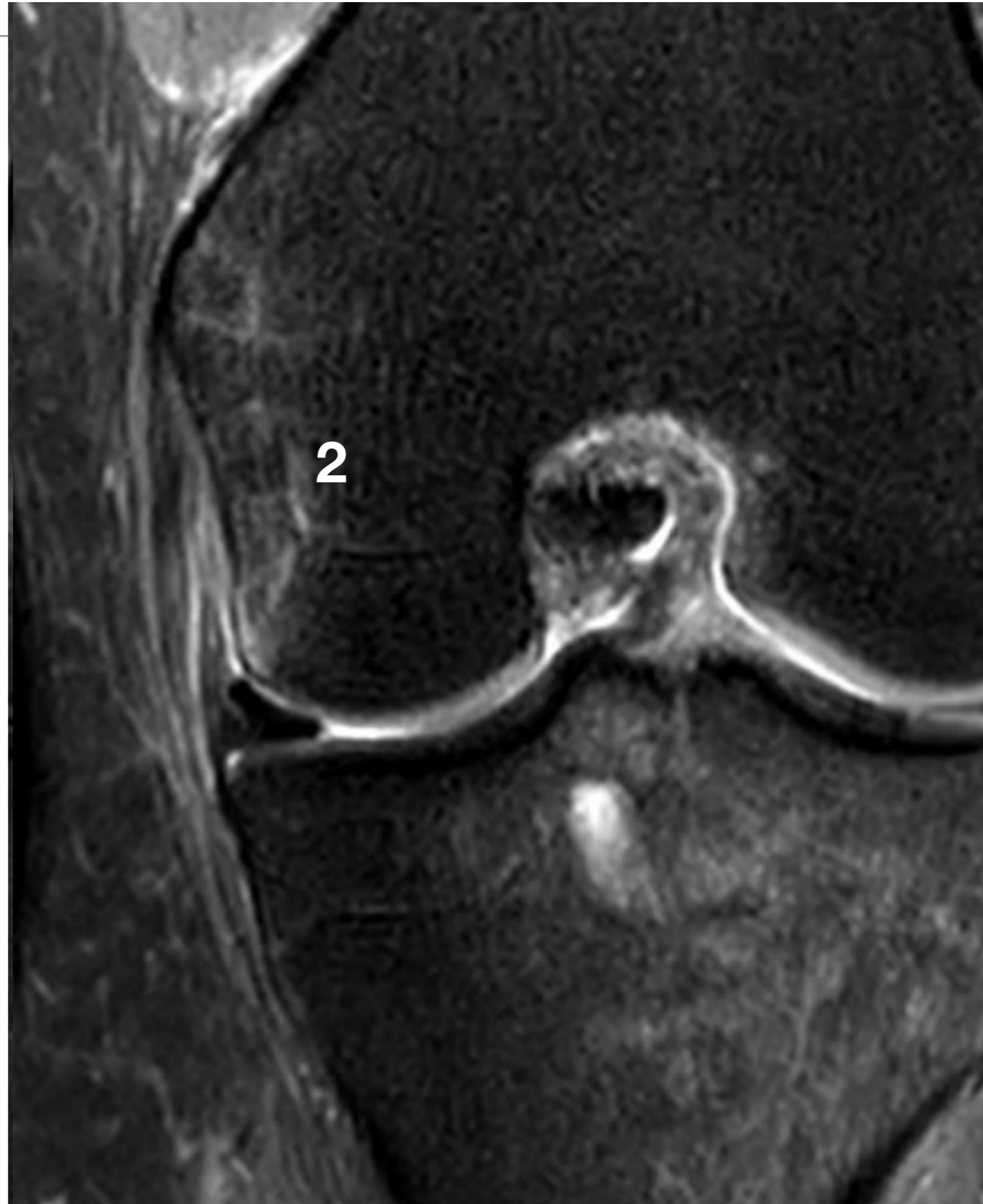### 3. Ligament Collatéral Médial

- Grade 2

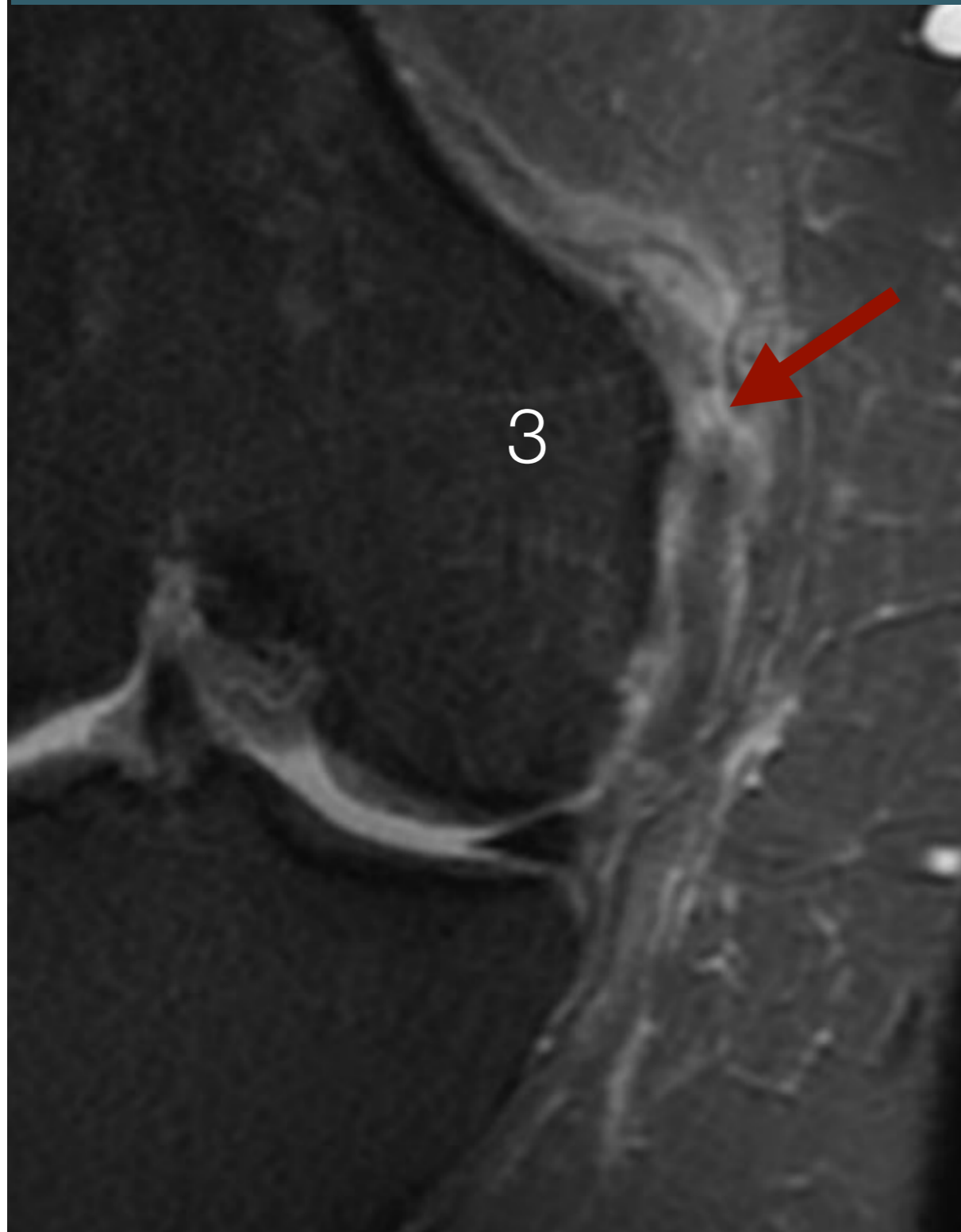


### 3. Ligament Collatéral Médial

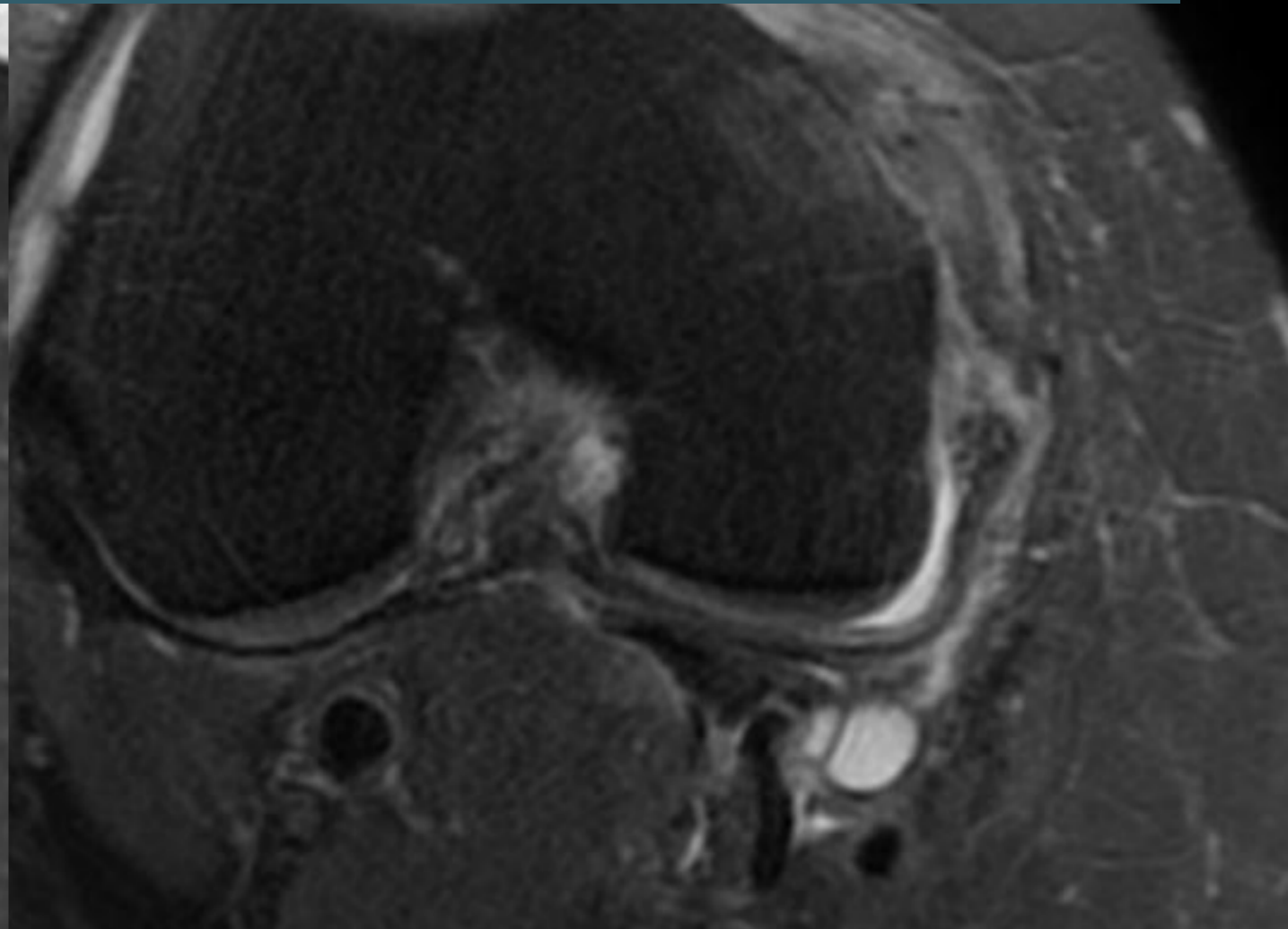
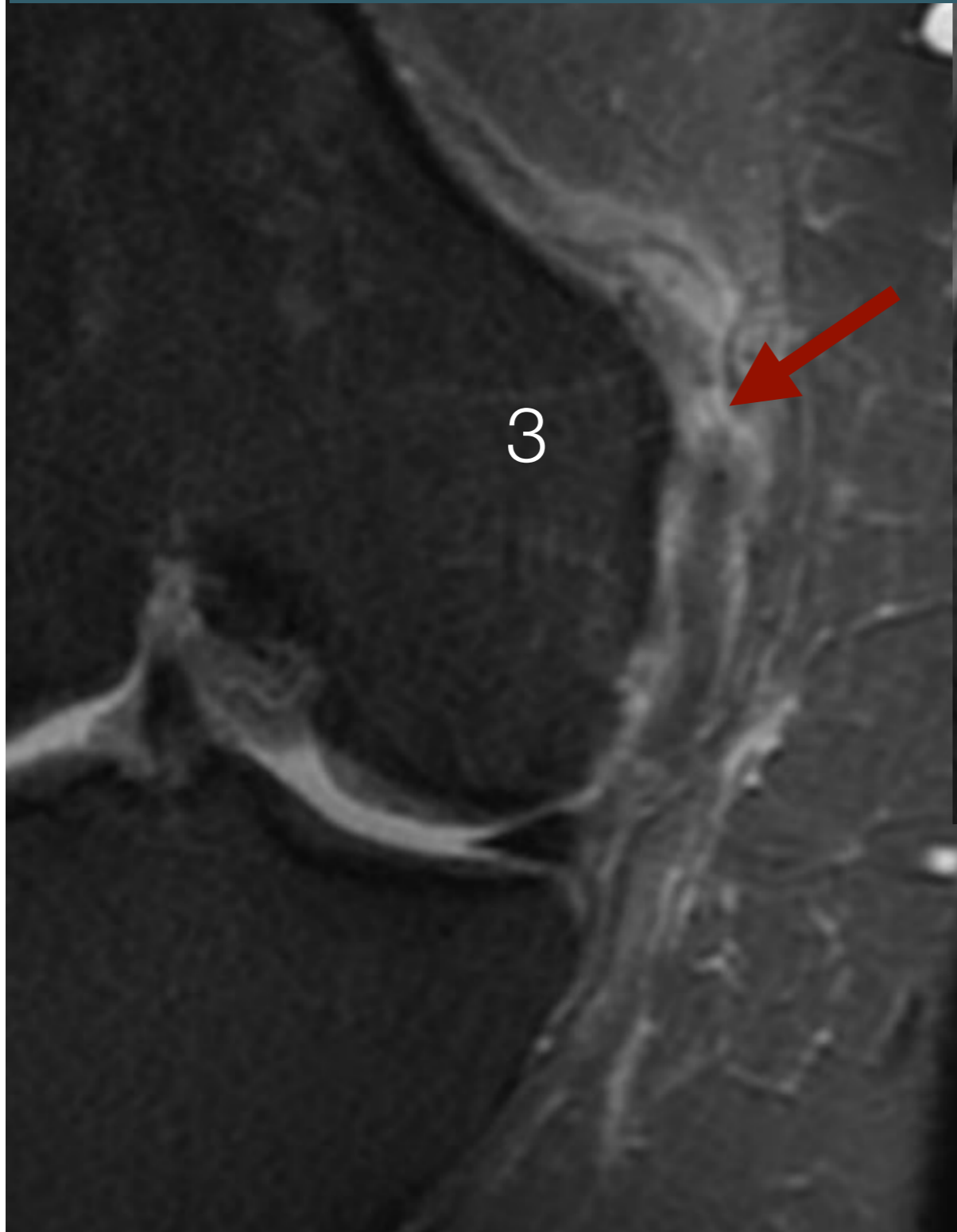
- Grade 2



### 3. Ligament Collatéral Médial

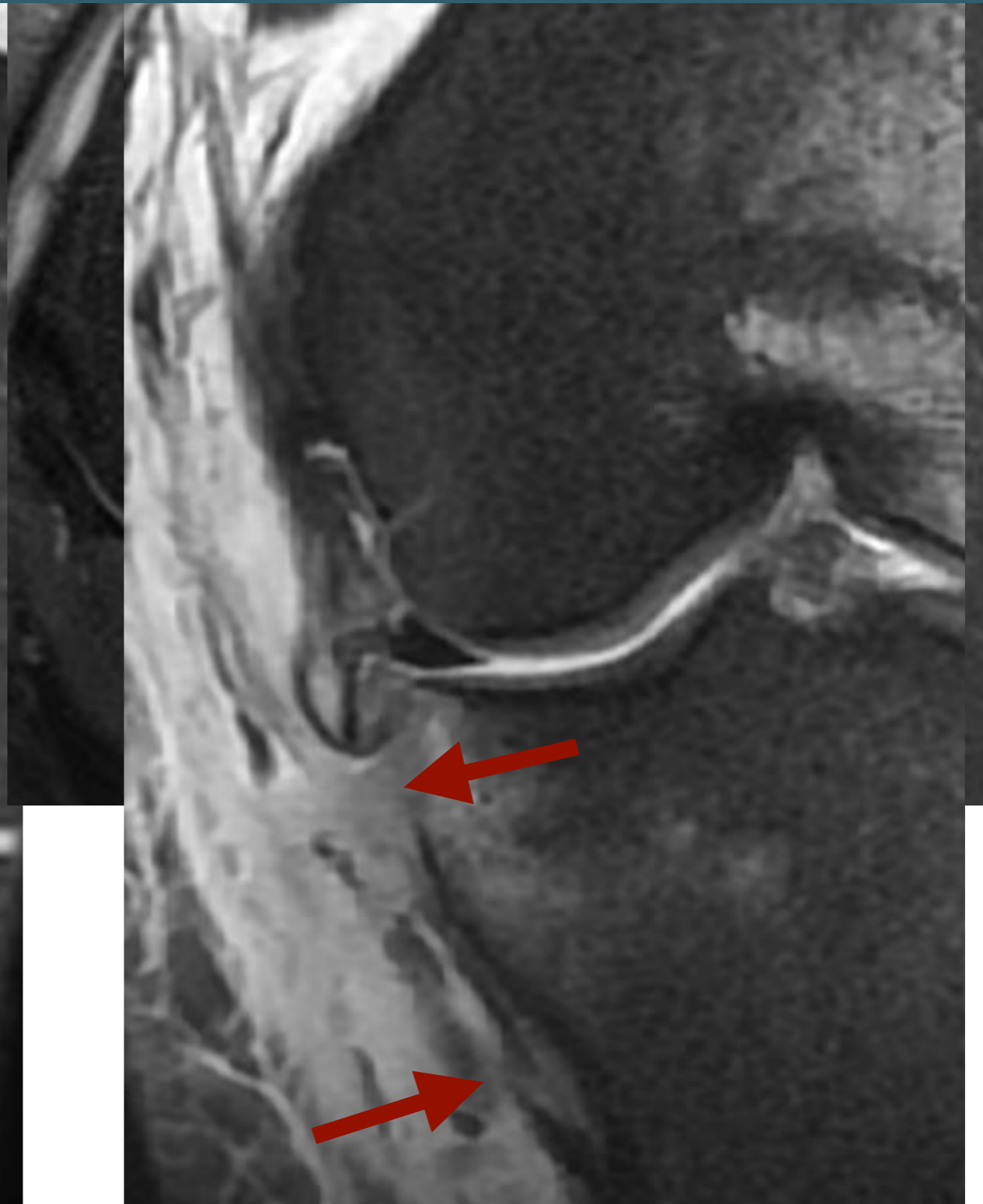
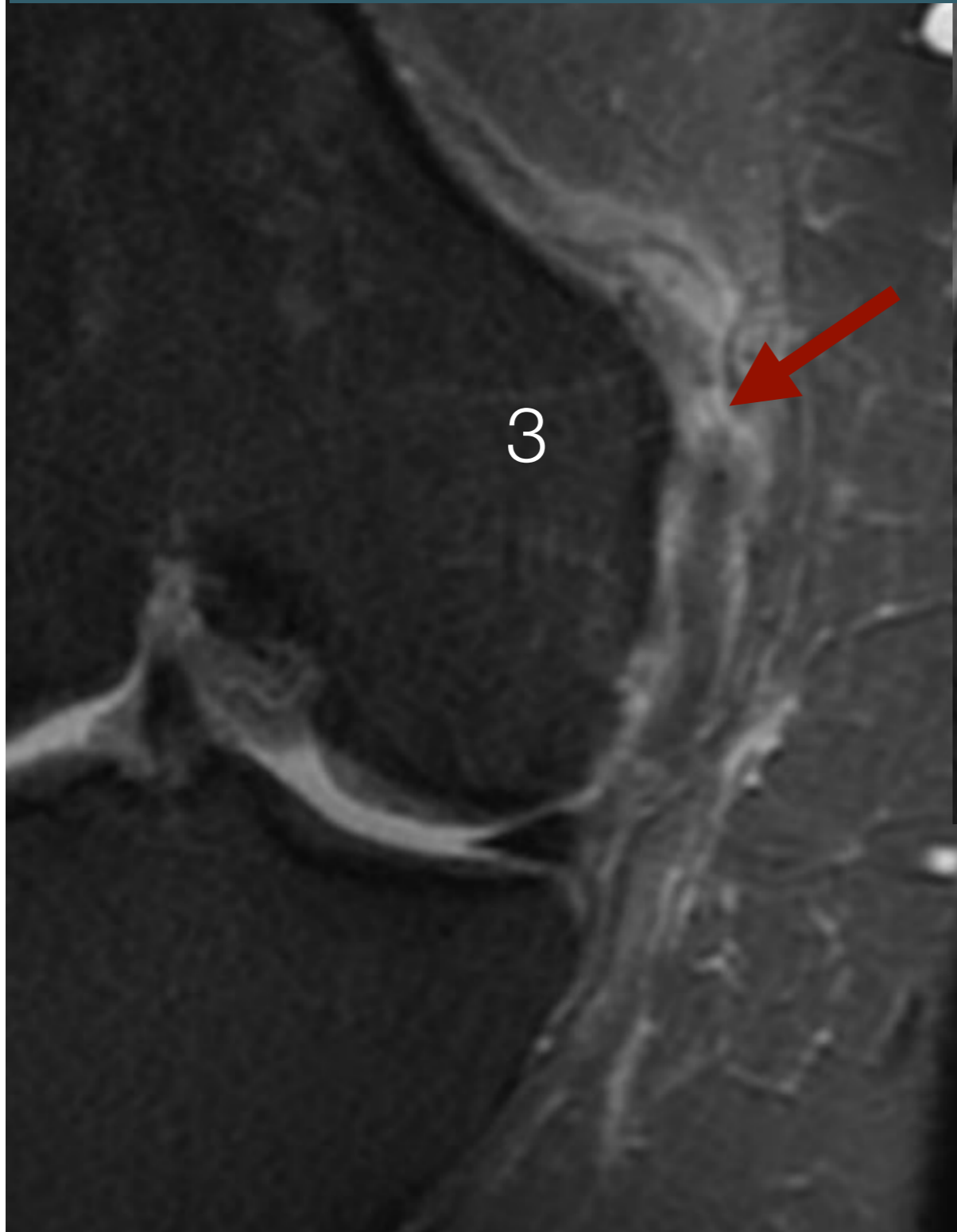


### 3. Ligament Collatéral Médial





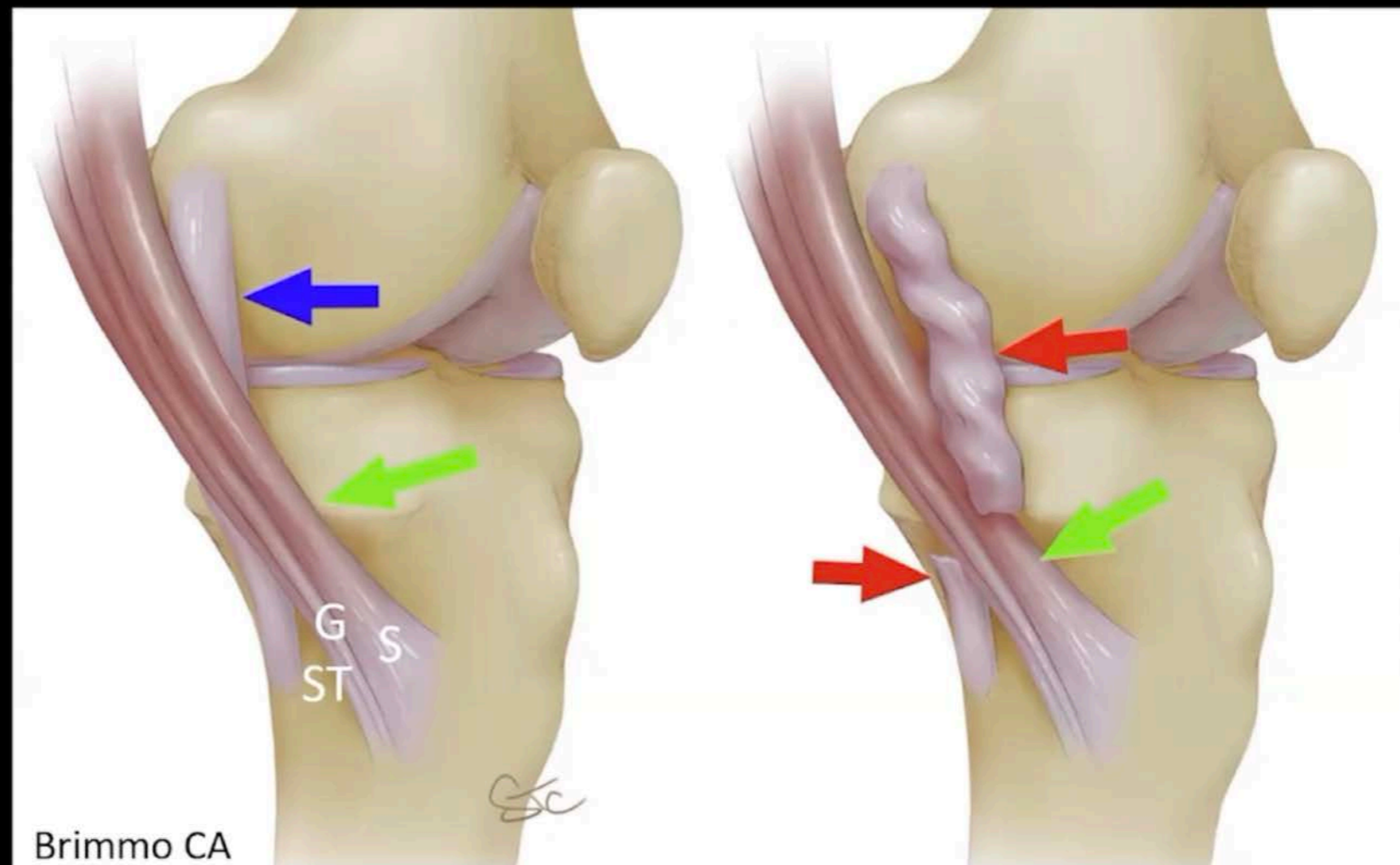
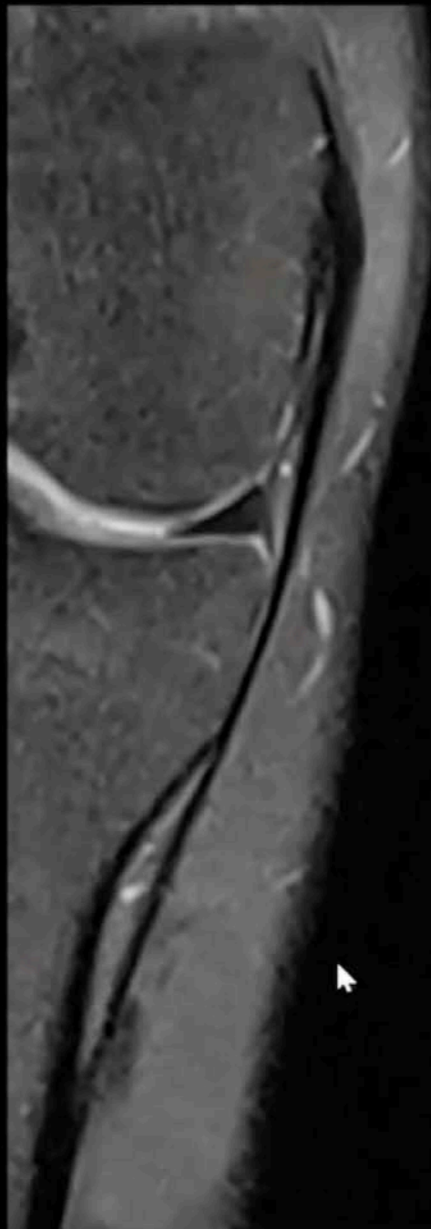### 3. Ligament Collatéral Médial



# 3. Ligament Collatéral Médial

LCM superficiel

- . siège: tibial distal
- . effet Stener ?

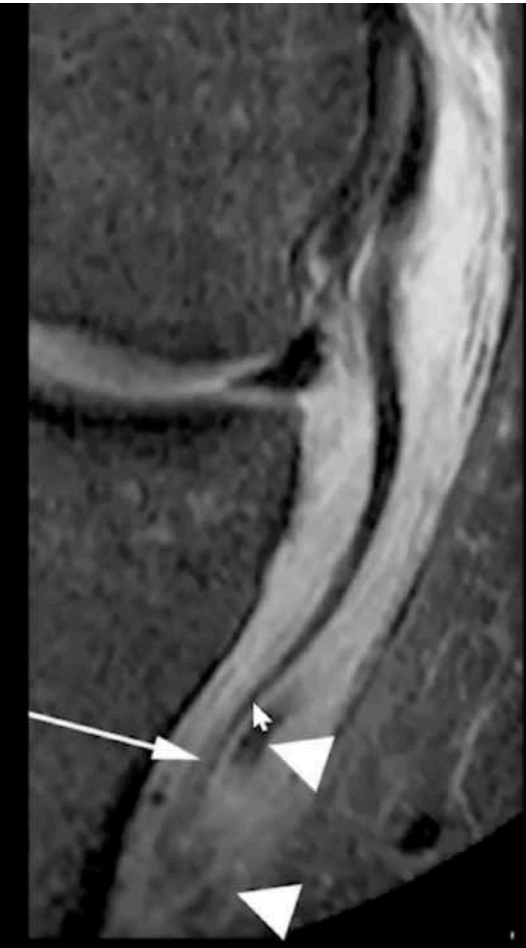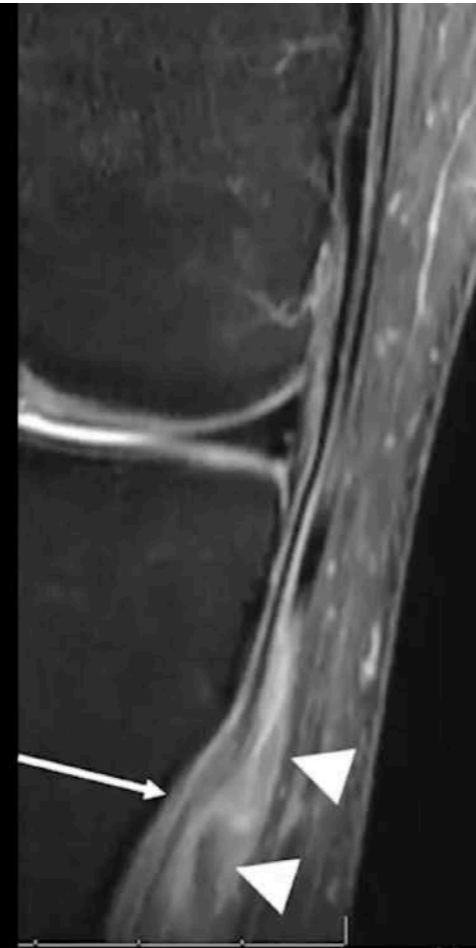

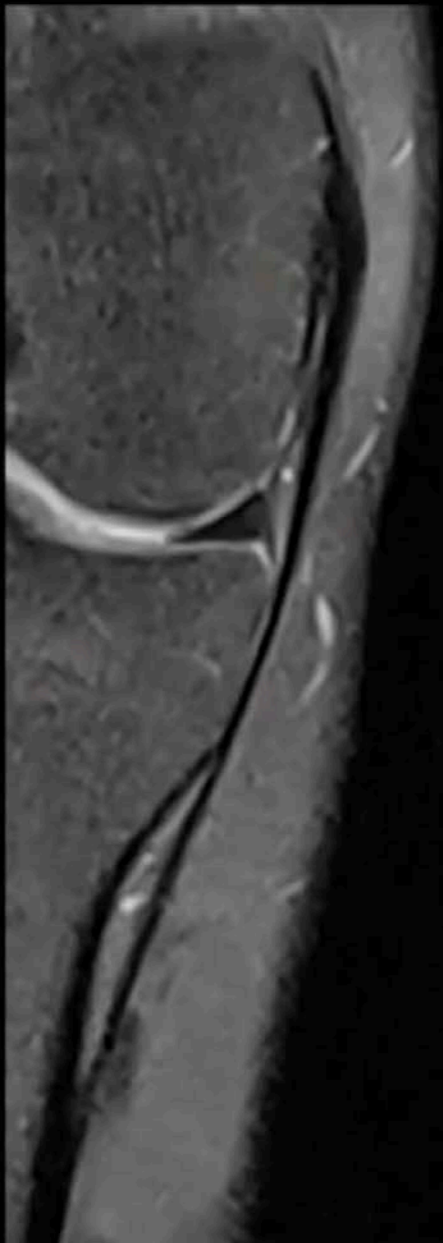
Brimmo CA

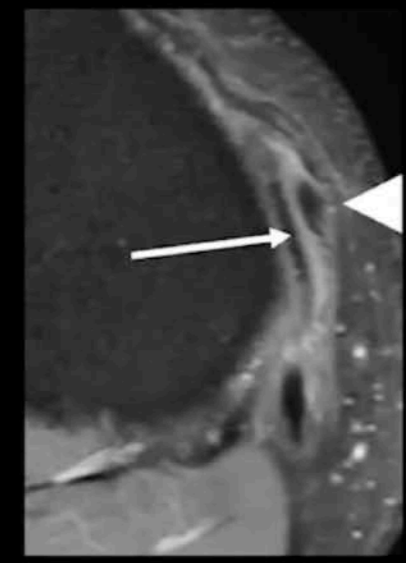
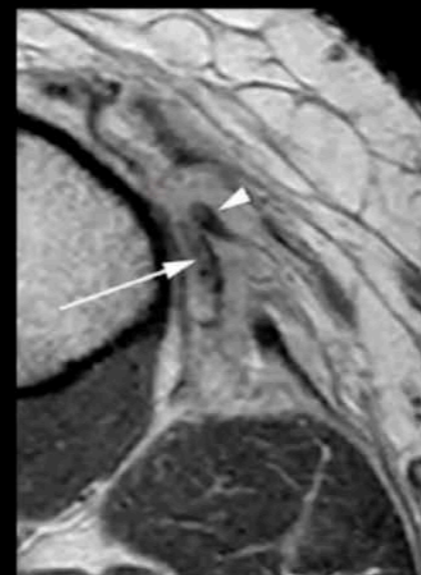# 3. Ligament Collatéral Médial

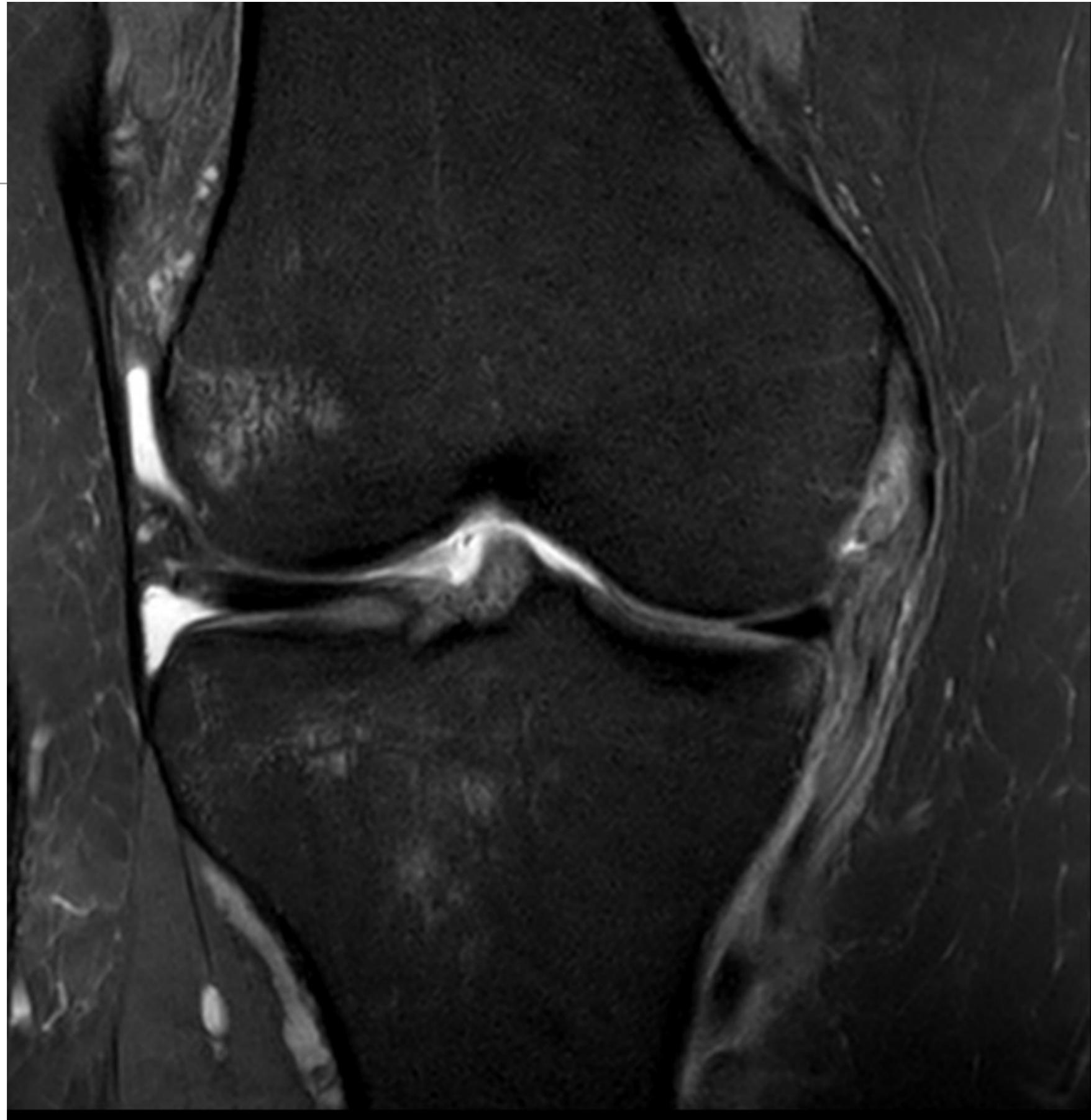LCM superficiel

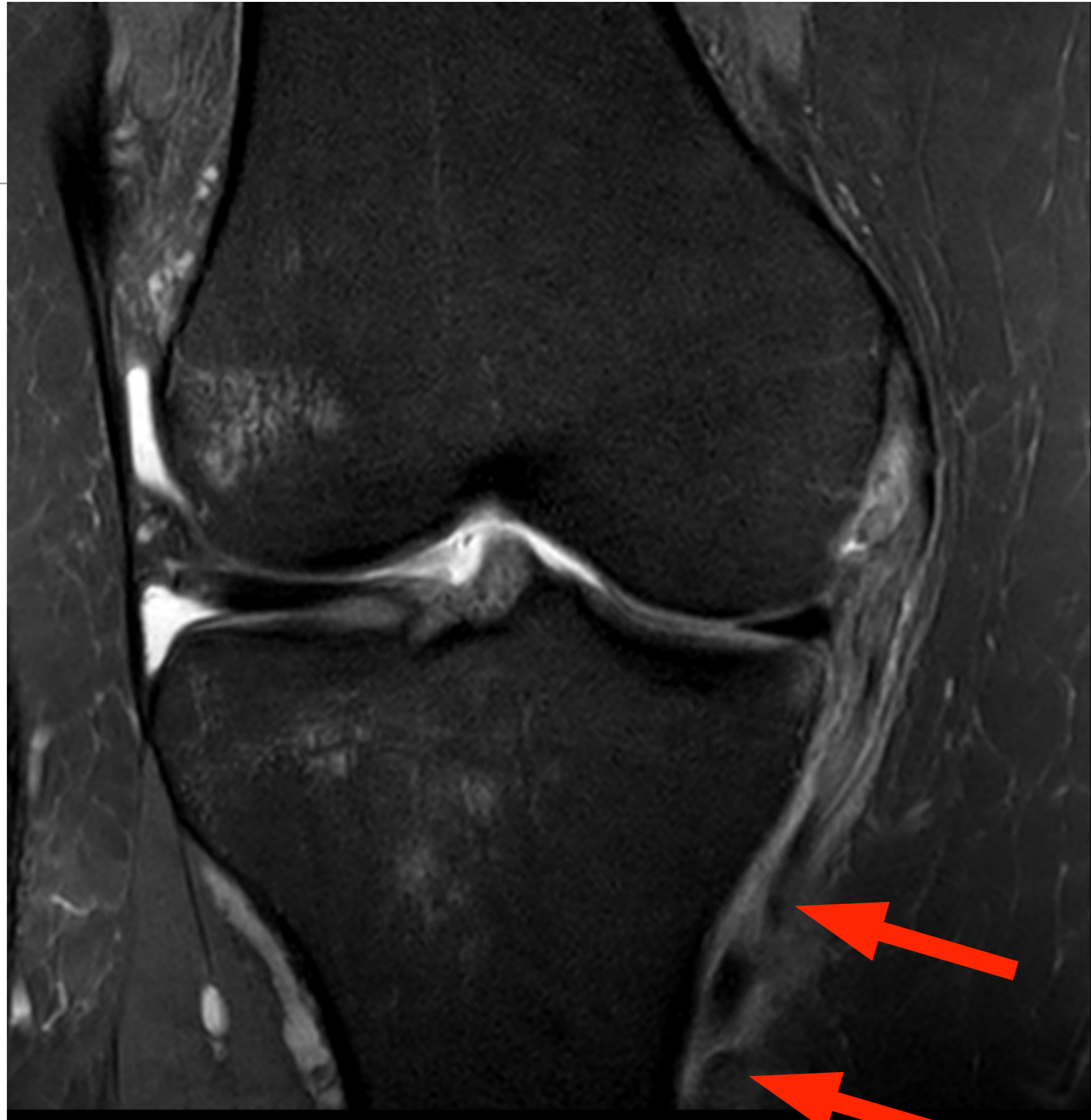- . siège: tibial distal
- . effet Stener ?

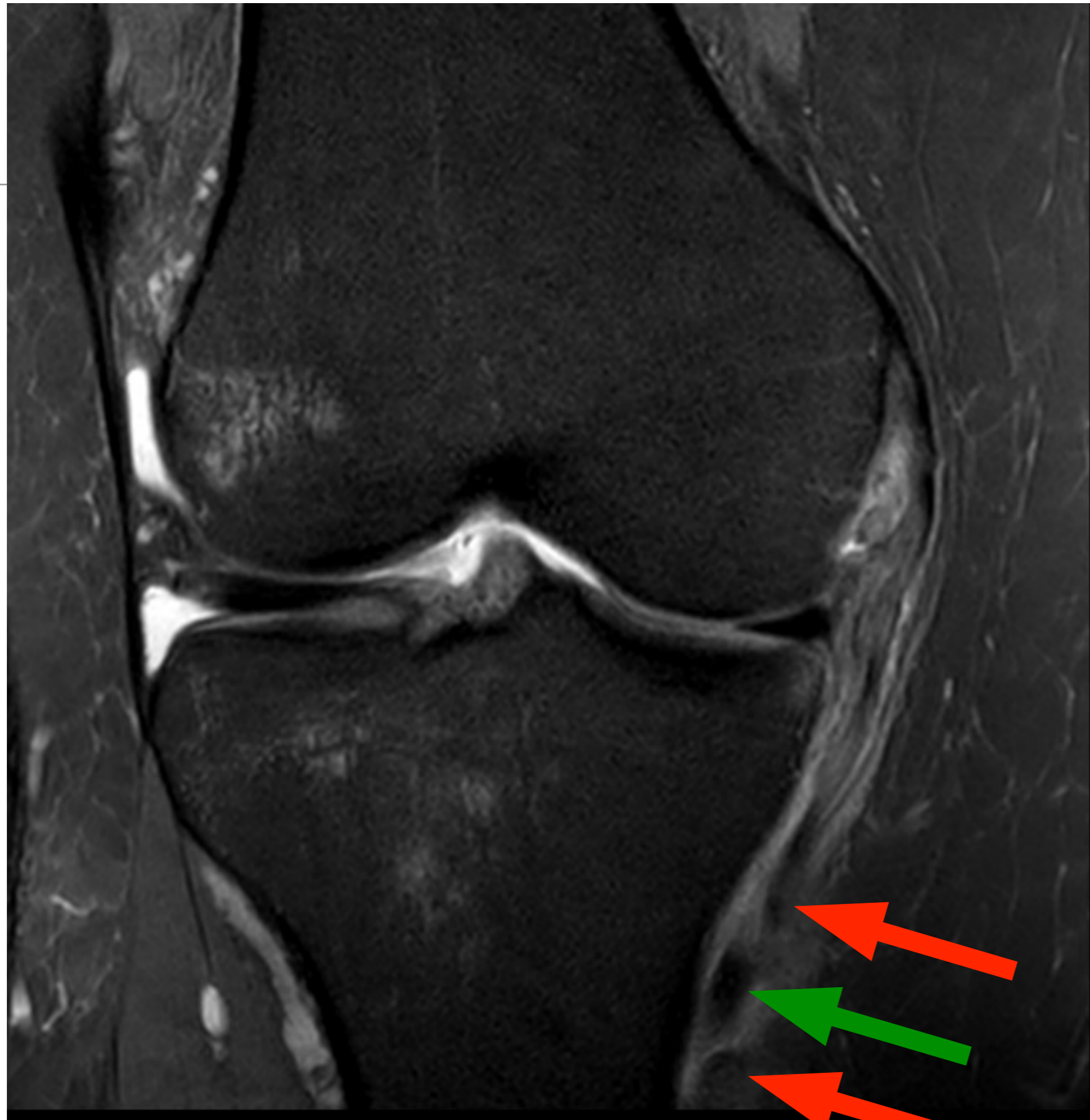

Pas d'effet Stener



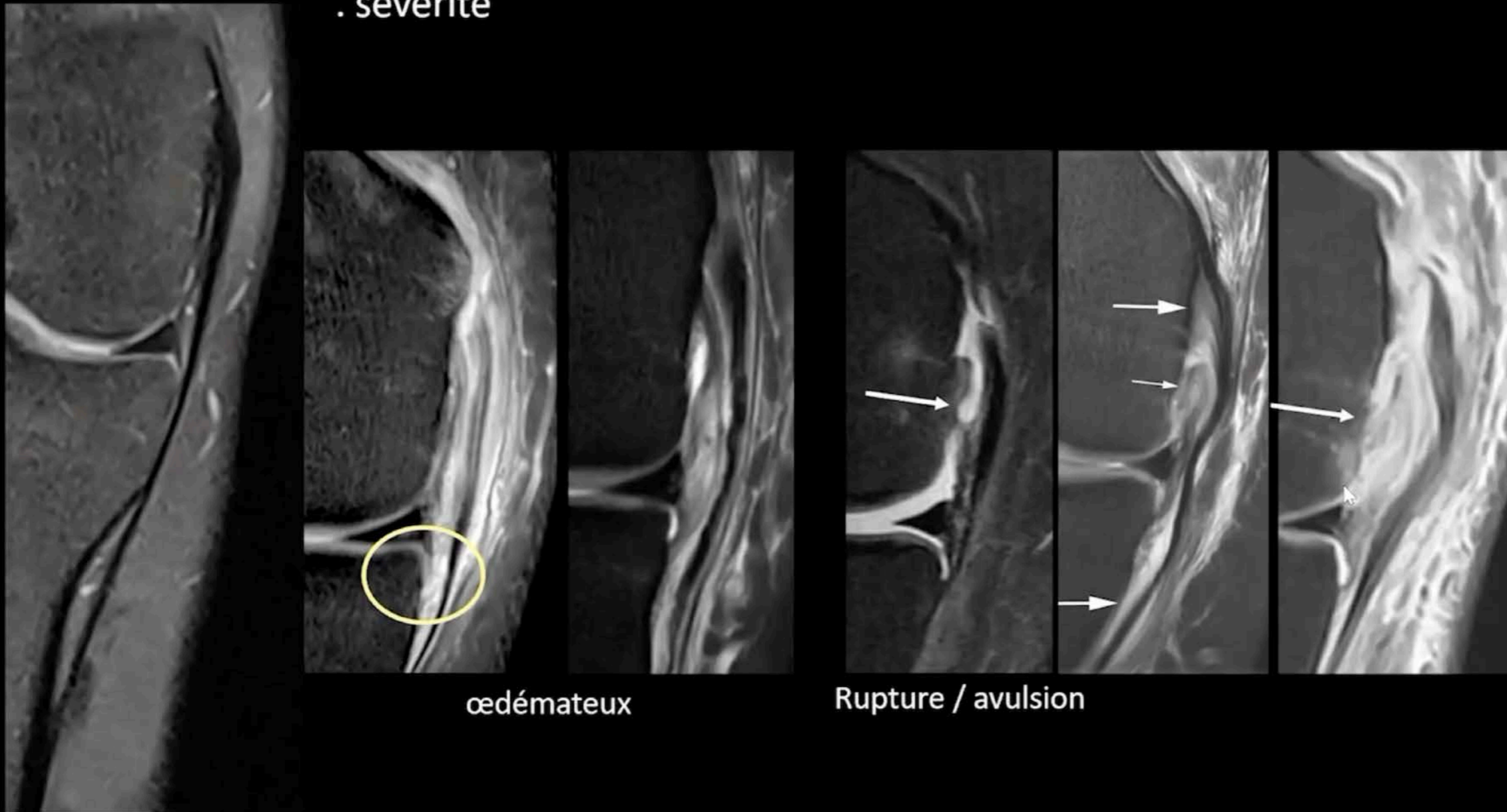






## LCM profond

- . siège: lig méniscofémoral / méniscotibial
- . sévérité



œdémateux

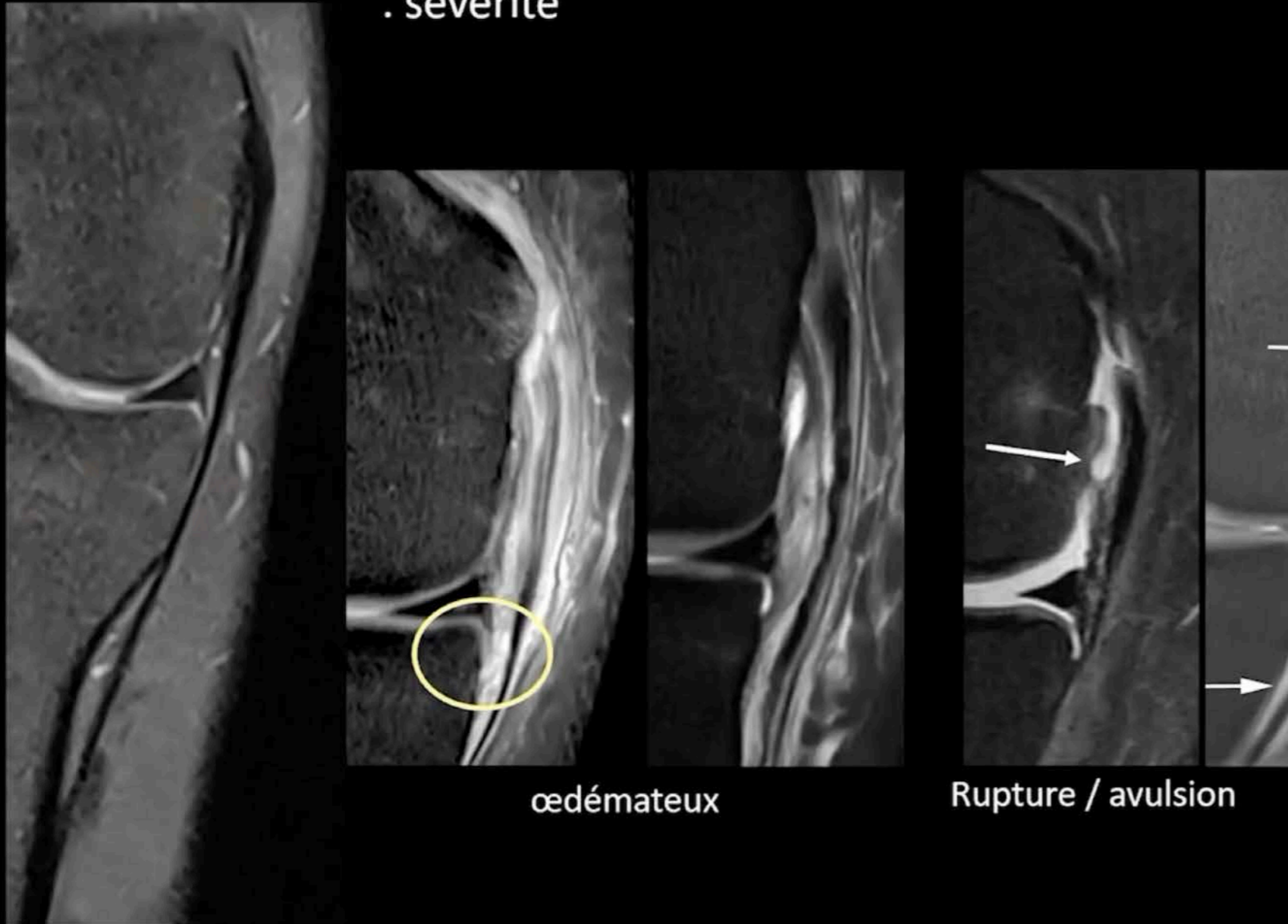
Rupture / avulsion

Risque de Ramp Lésion  
Participation à la stabilité rotationnelle

1. Willinger L et al. High incidence of superficial and deep medial collateral ligament injuries in 'isolated' anterior cruciate ligament ruptures: a long overlooked injury. *Knee Surg Sports Traumatol Arthrosc* 2021; 4 / on line
2. Cavaignac et al. The role of the deep medial collateral ligament in controlling rotational stability of the knee. *Knee Surg Sports Traumatol Arthrosc.* 2015;23(10):3101–7.

## LCM profond

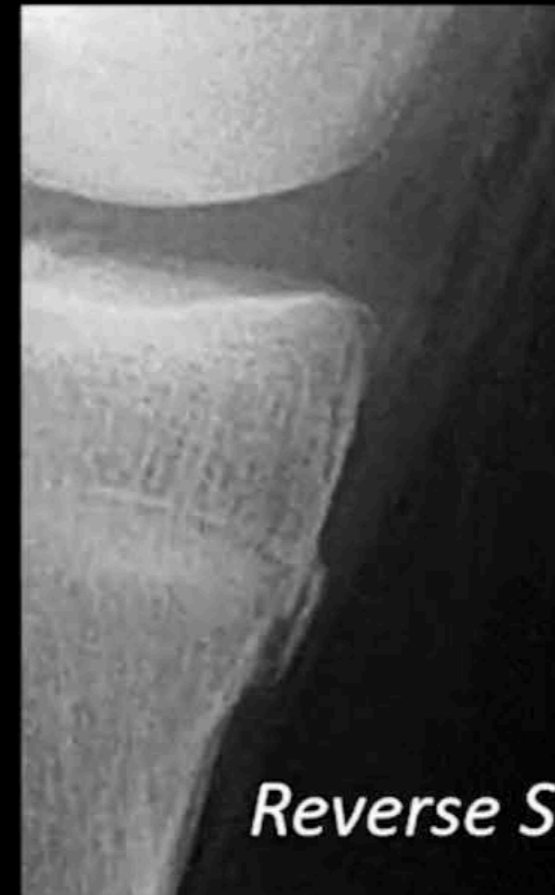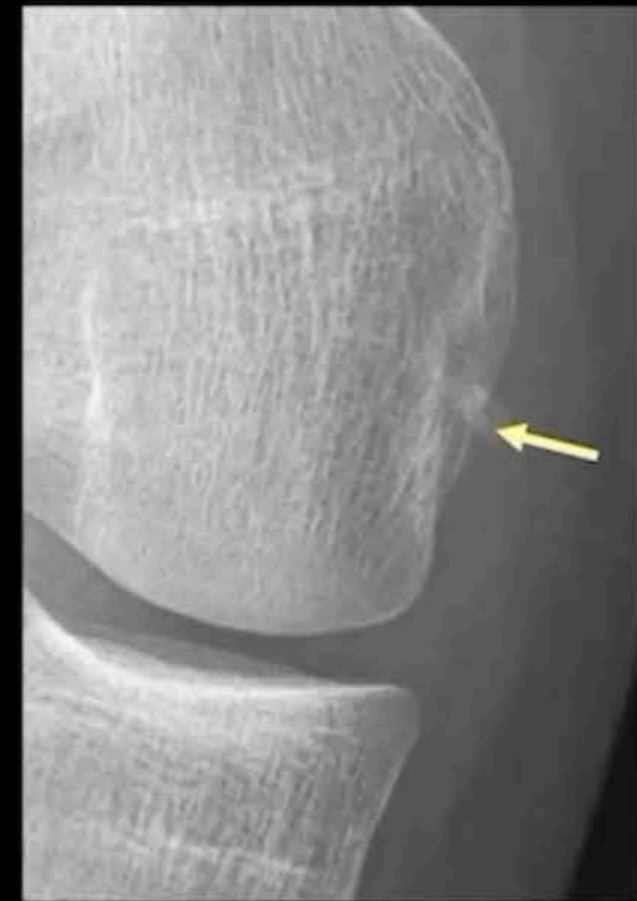- . siège: lig méniscofémoral / méniscotibial
- . sévérité



œdémateux

Rupture / avulsion

## LCM profond

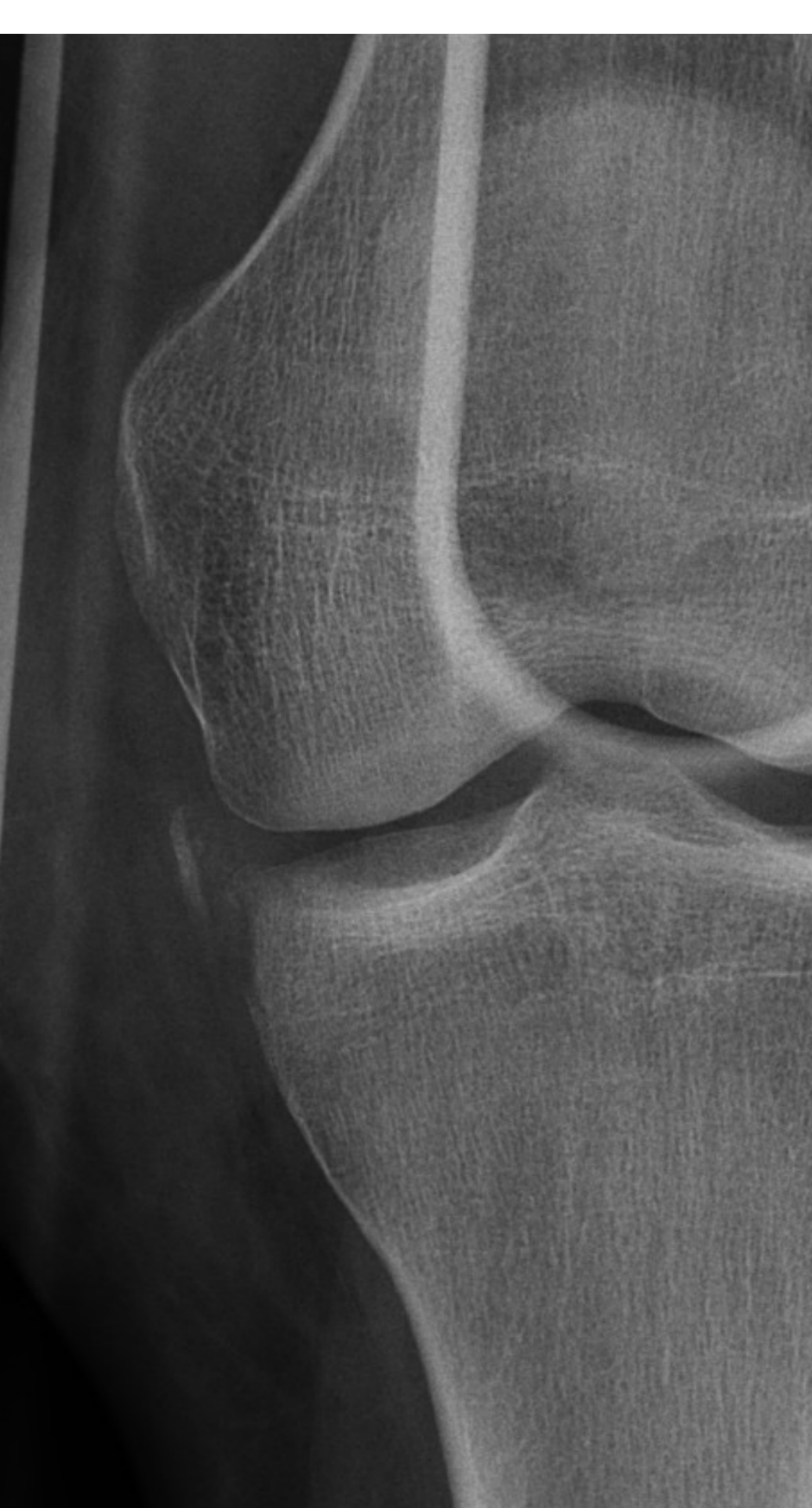


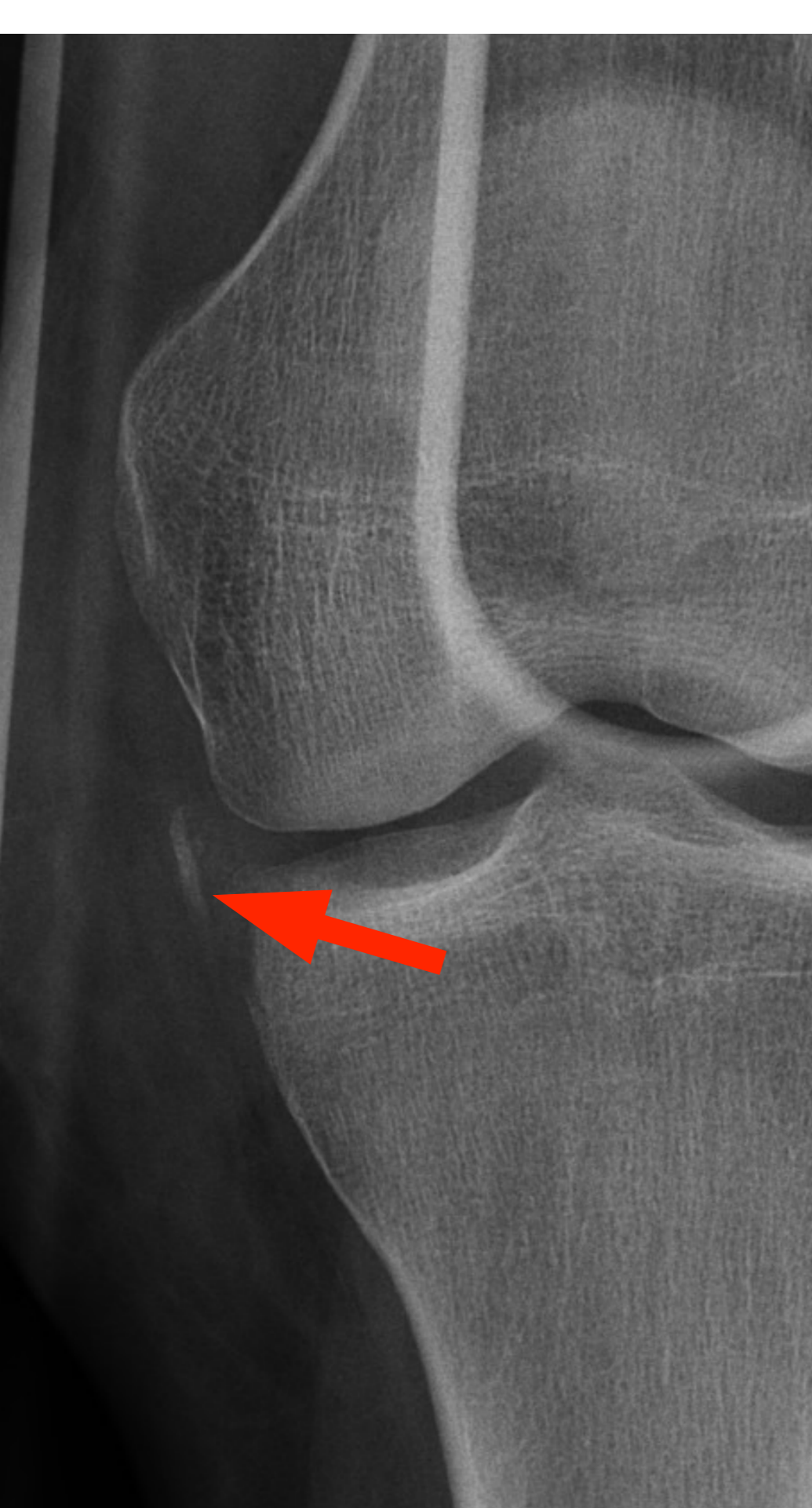*Reverse Segond*

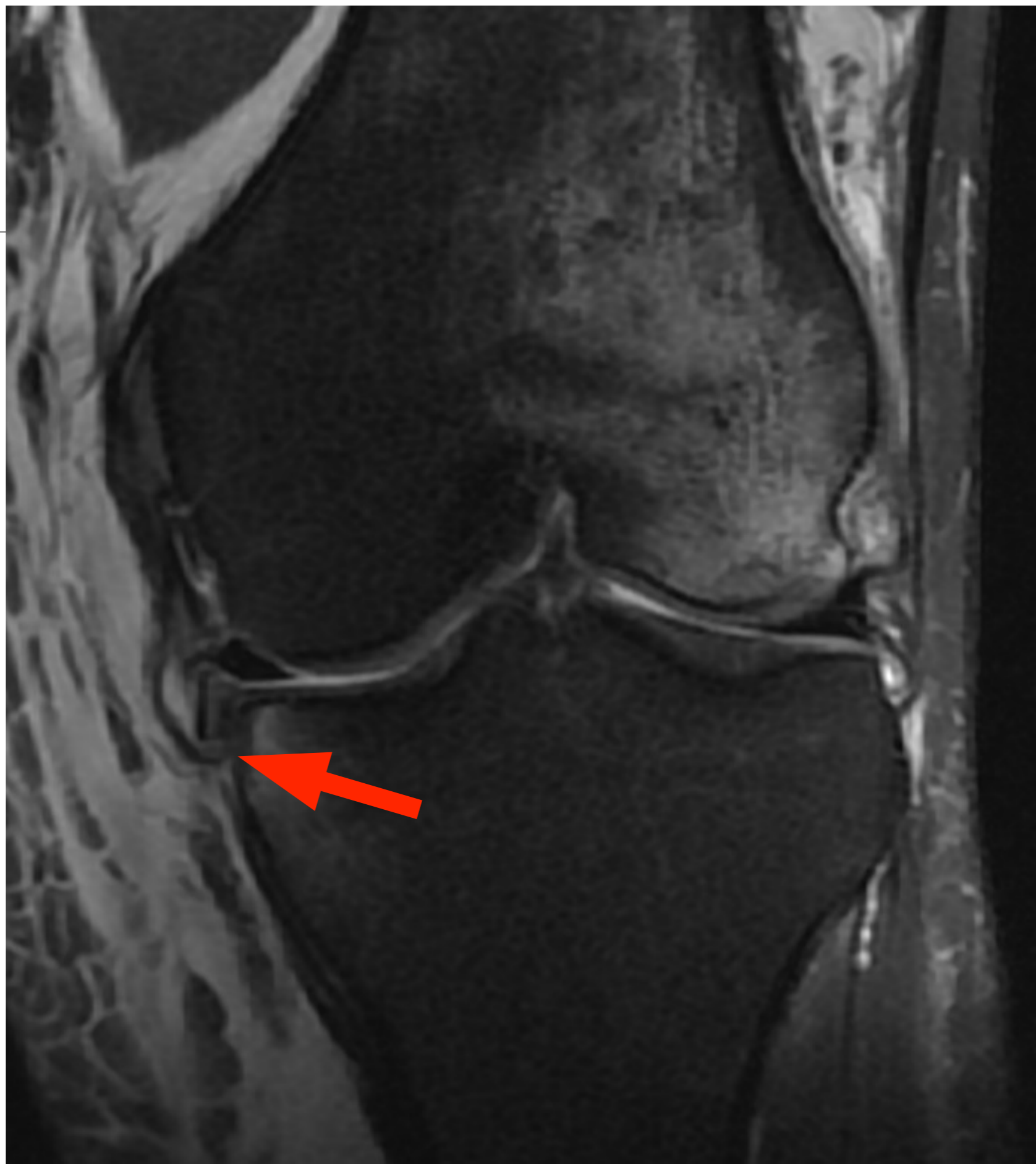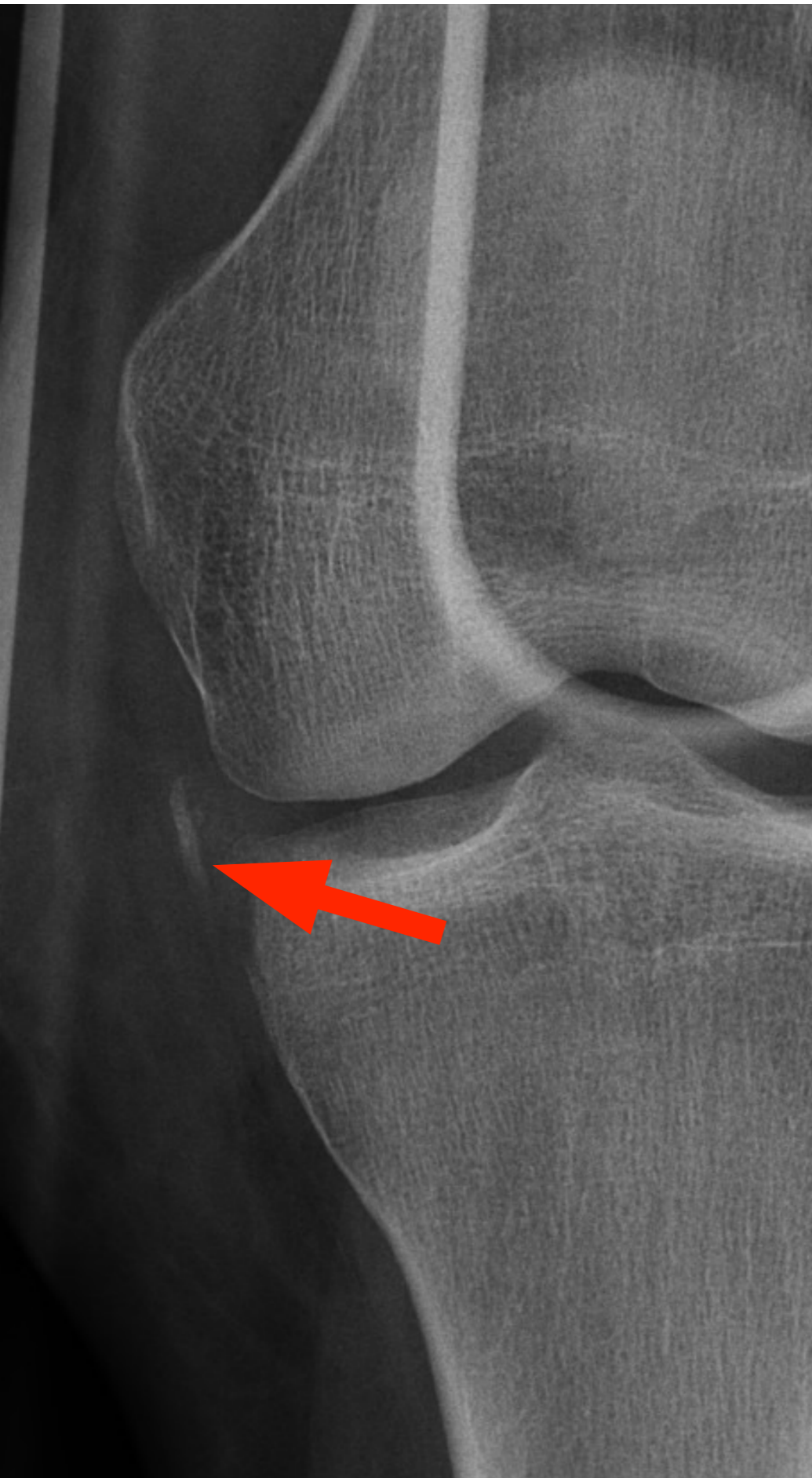Risque de Ramp Lésion  
Participation à la stabilité rotationnelle

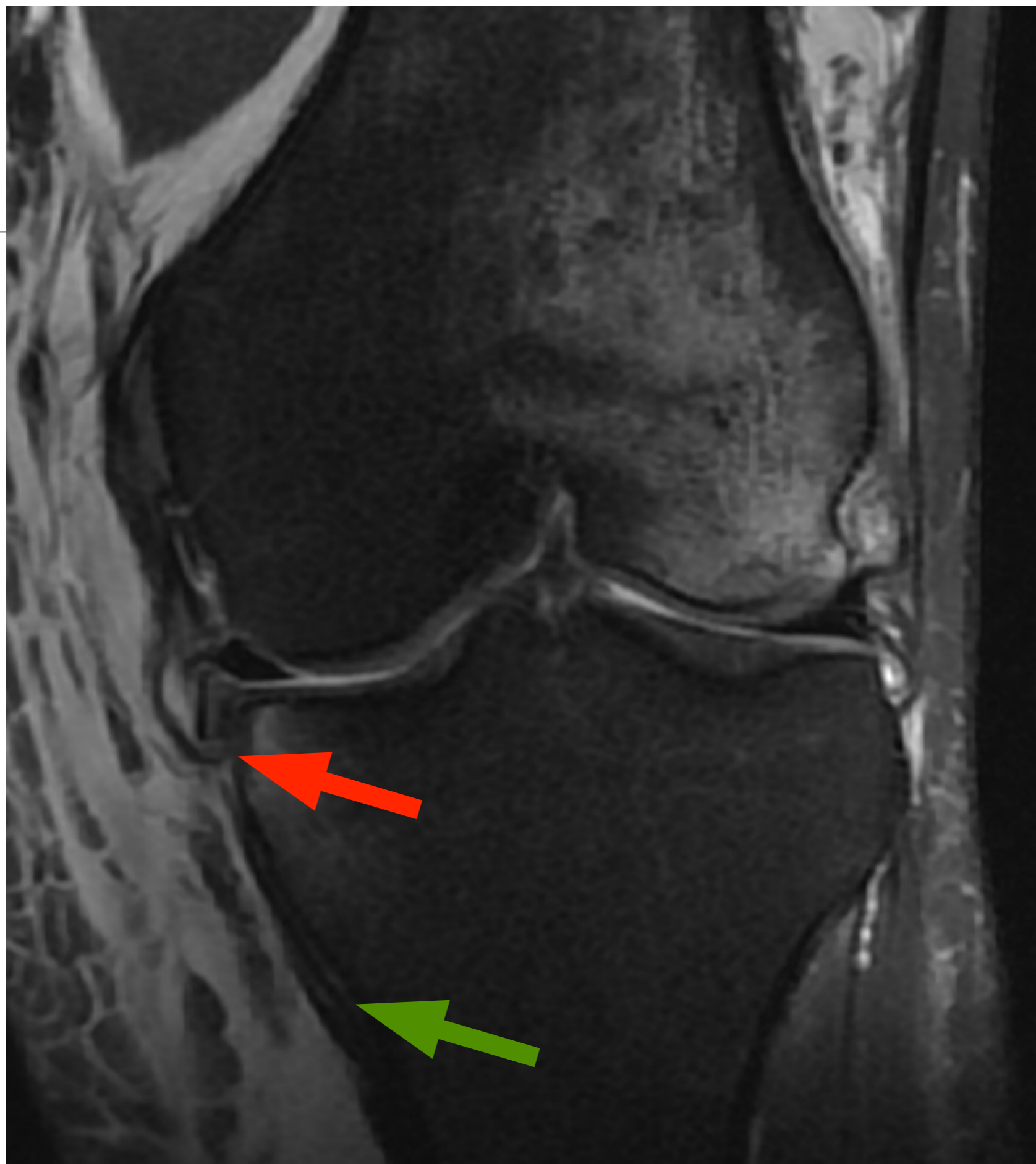
1. Willinger L et al. High incidence of superficial and deep medial collateral ligament injuries in 'isolated' anterior cruciate ligament ruptures: a long overlooked injury. *Knee Surg Sports Traumatol Arthrosc* 2021; 4 / on line
2. Cavaignac et al. The role of the deep medial collateral ligament in controlling rotational stability of the knee. *Knee Surg Sports Traumatol Arthrosc*. 2015;23(10):3101-7.











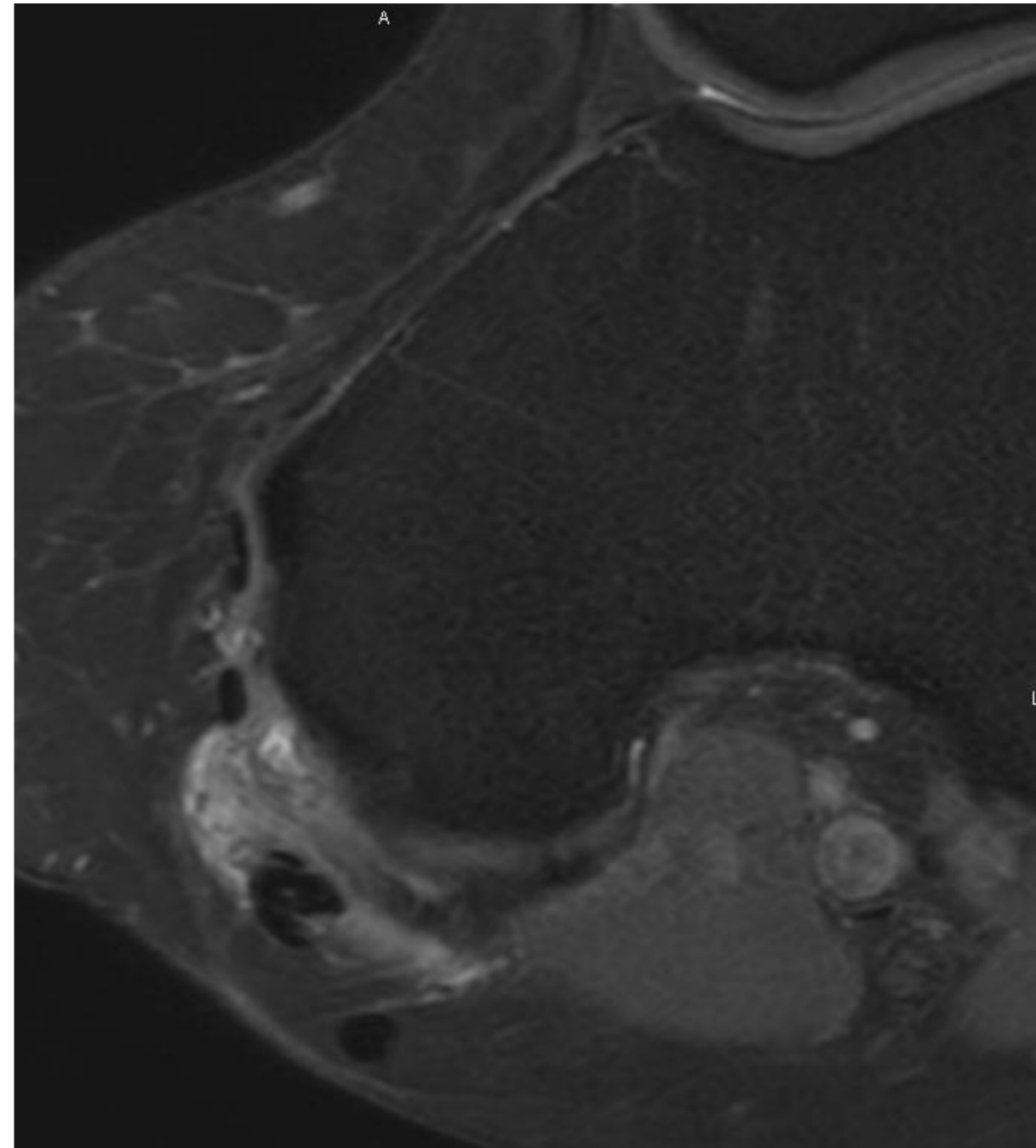
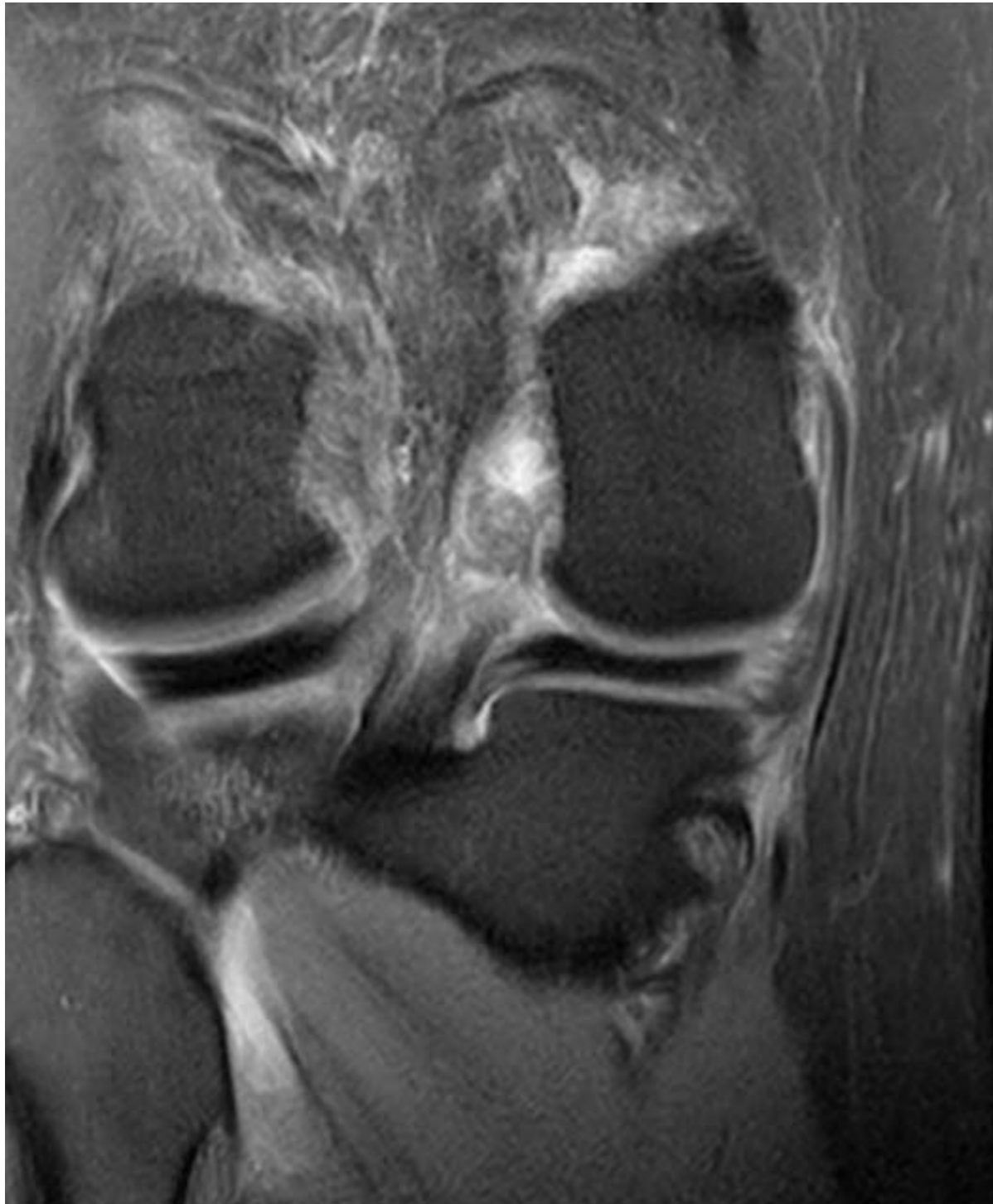## 3. Ligaments et points d'angle

---

- Point d'angle postéro-médial :
  - LOP ligament oblique postérieur
  - Expansions du tendon semi-membraneux
  - Ligament poplité oblique
  - Capsule postéro-médiale
  - Corne postérieure MM

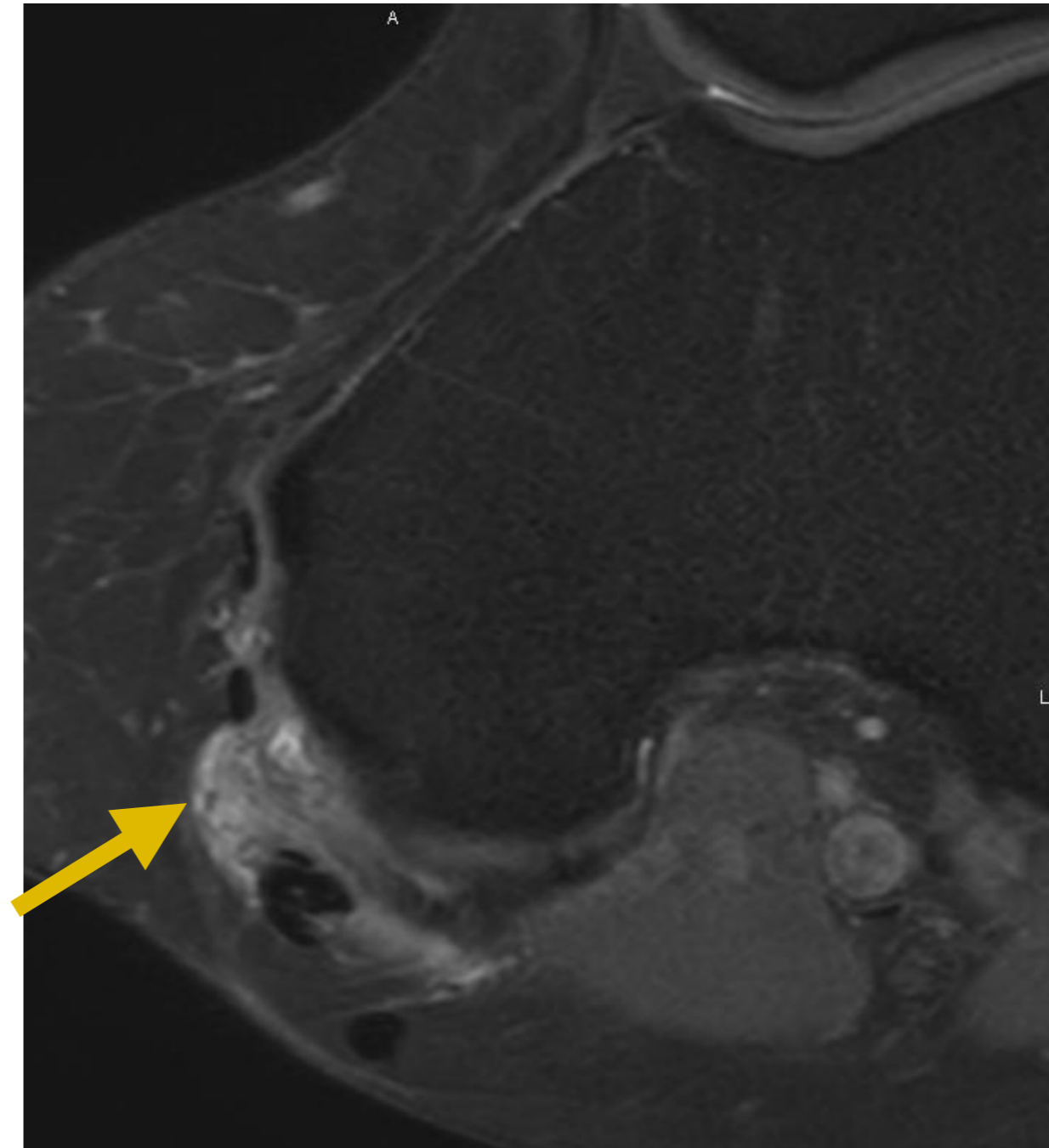
### 3. Ligaments et points d'angle

- Point d'angle postéro-médial



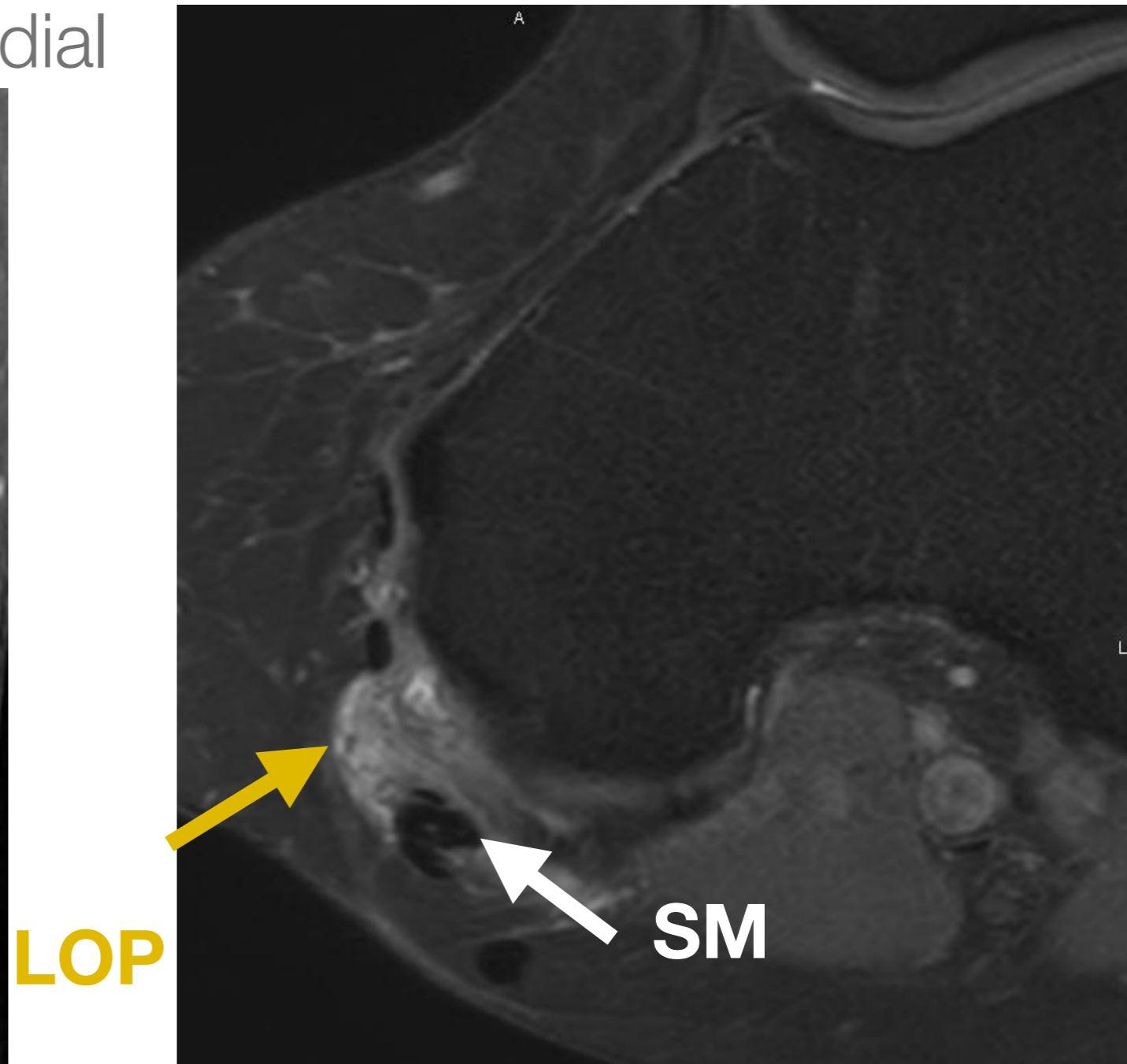
### 3. Ligaments et points d'angle

- Point d'angle postéro-médial



### 3. Ligaments et points d'angle

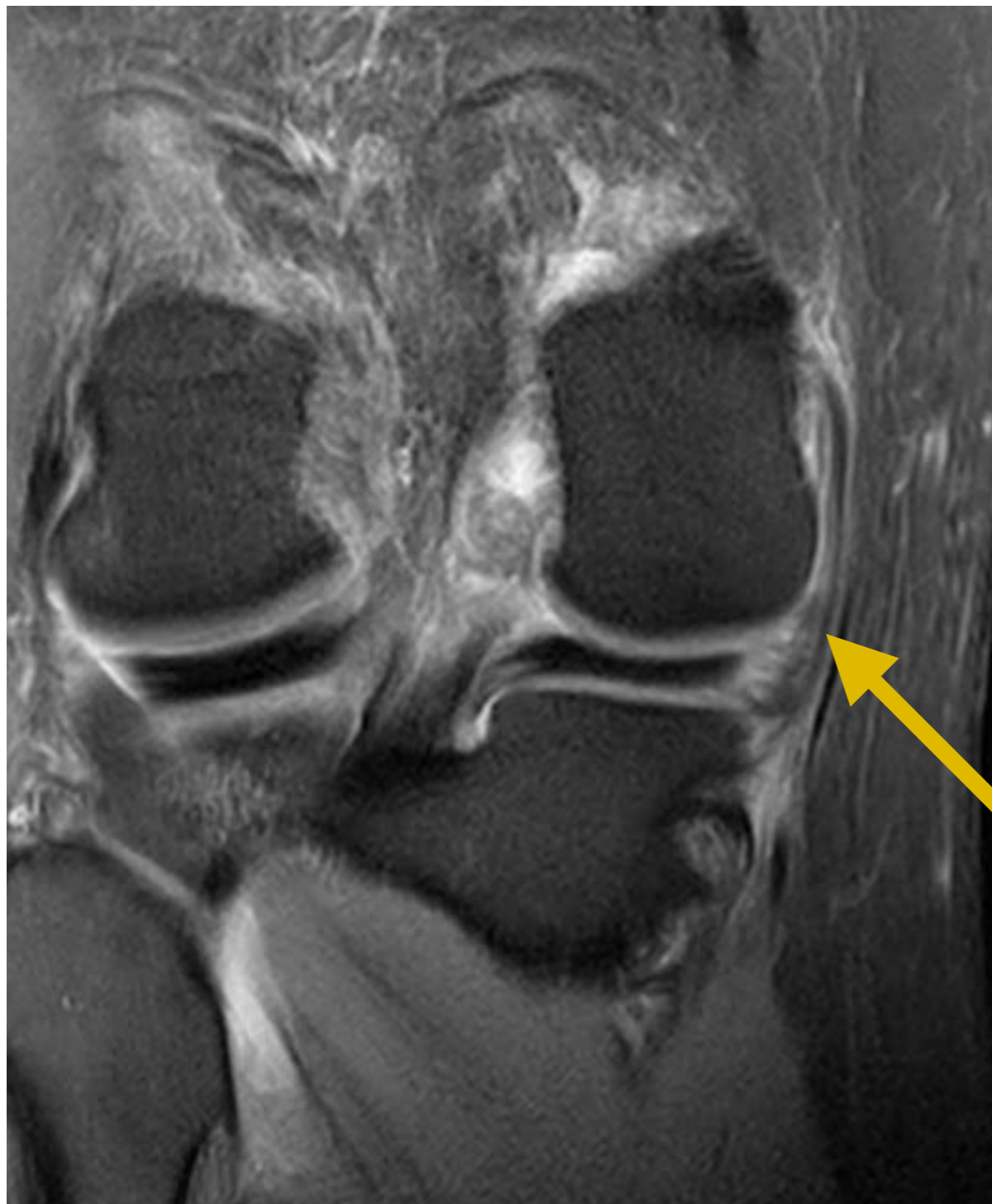- Point d'angle postéro-médial



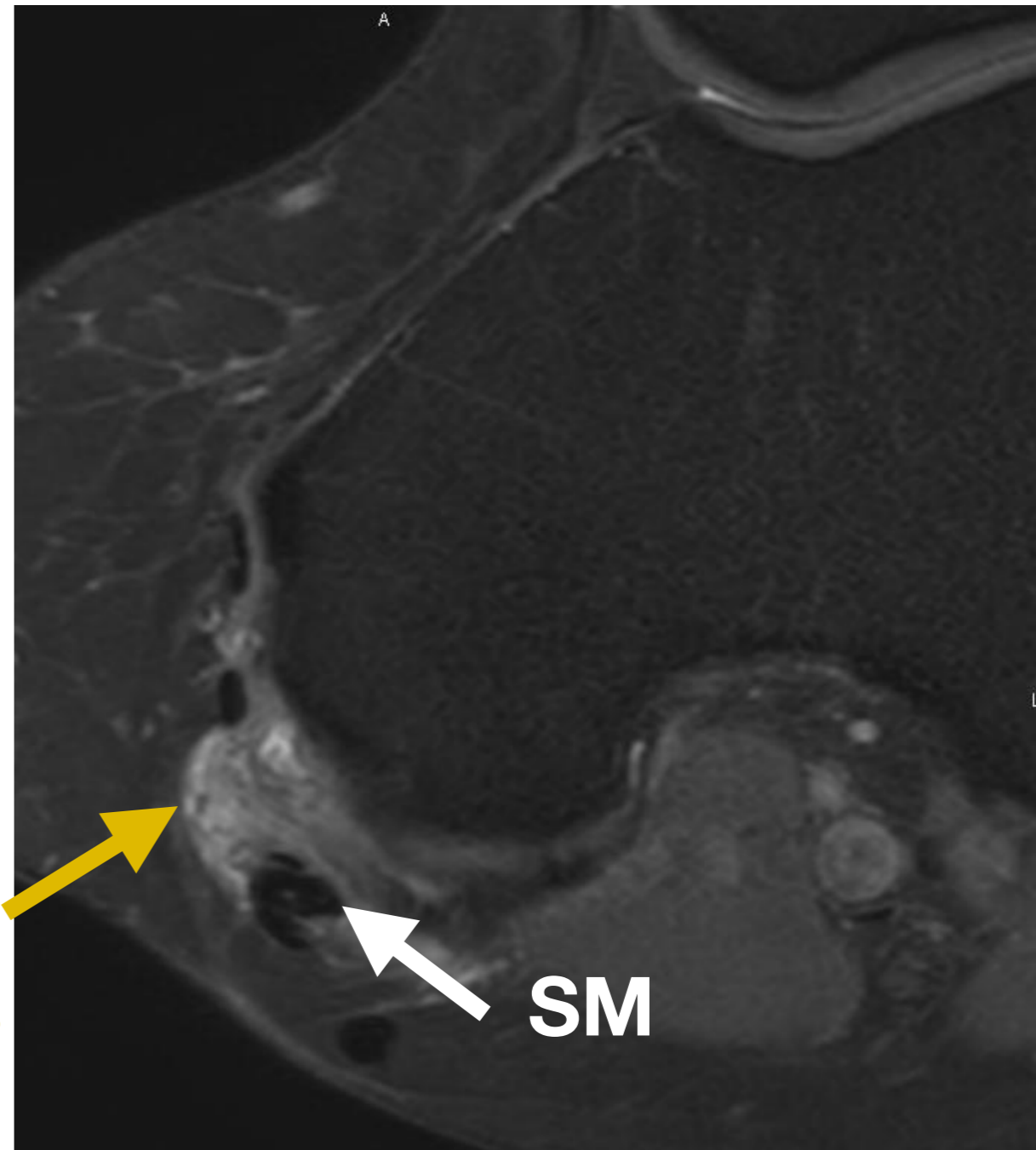


### 3. Ligaments et points d'angle

- Point d'angle postéro-médial

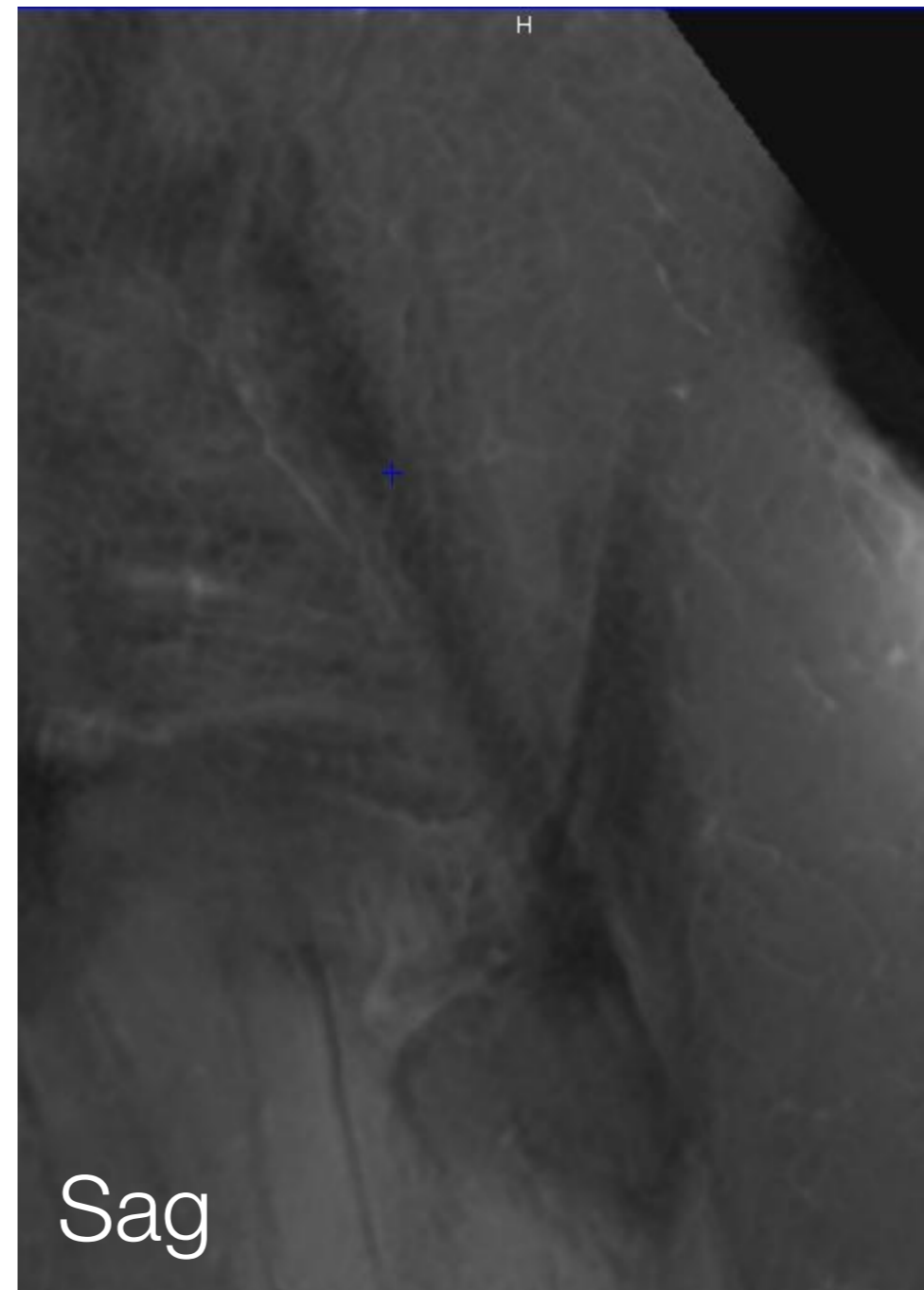
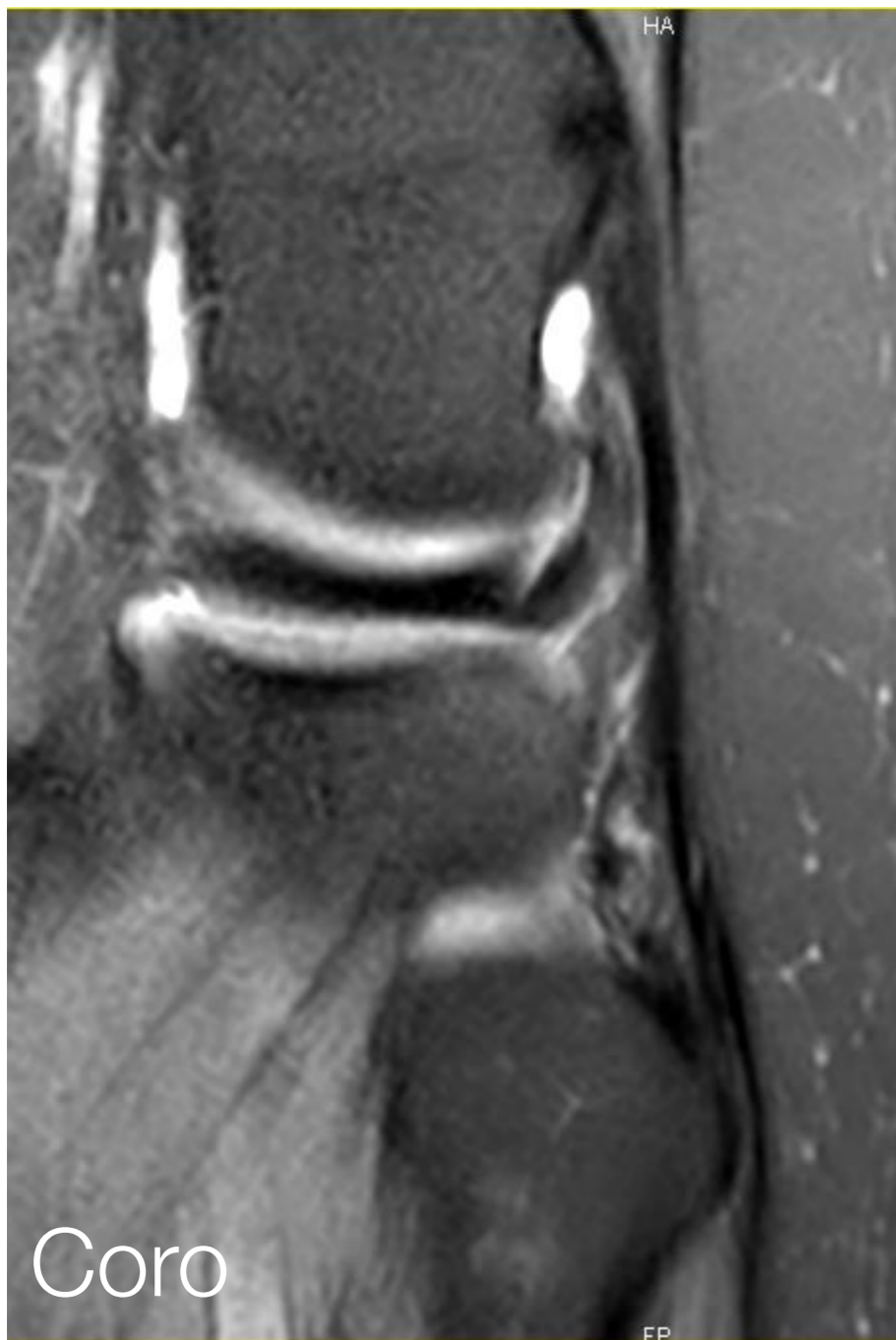


**LOP**


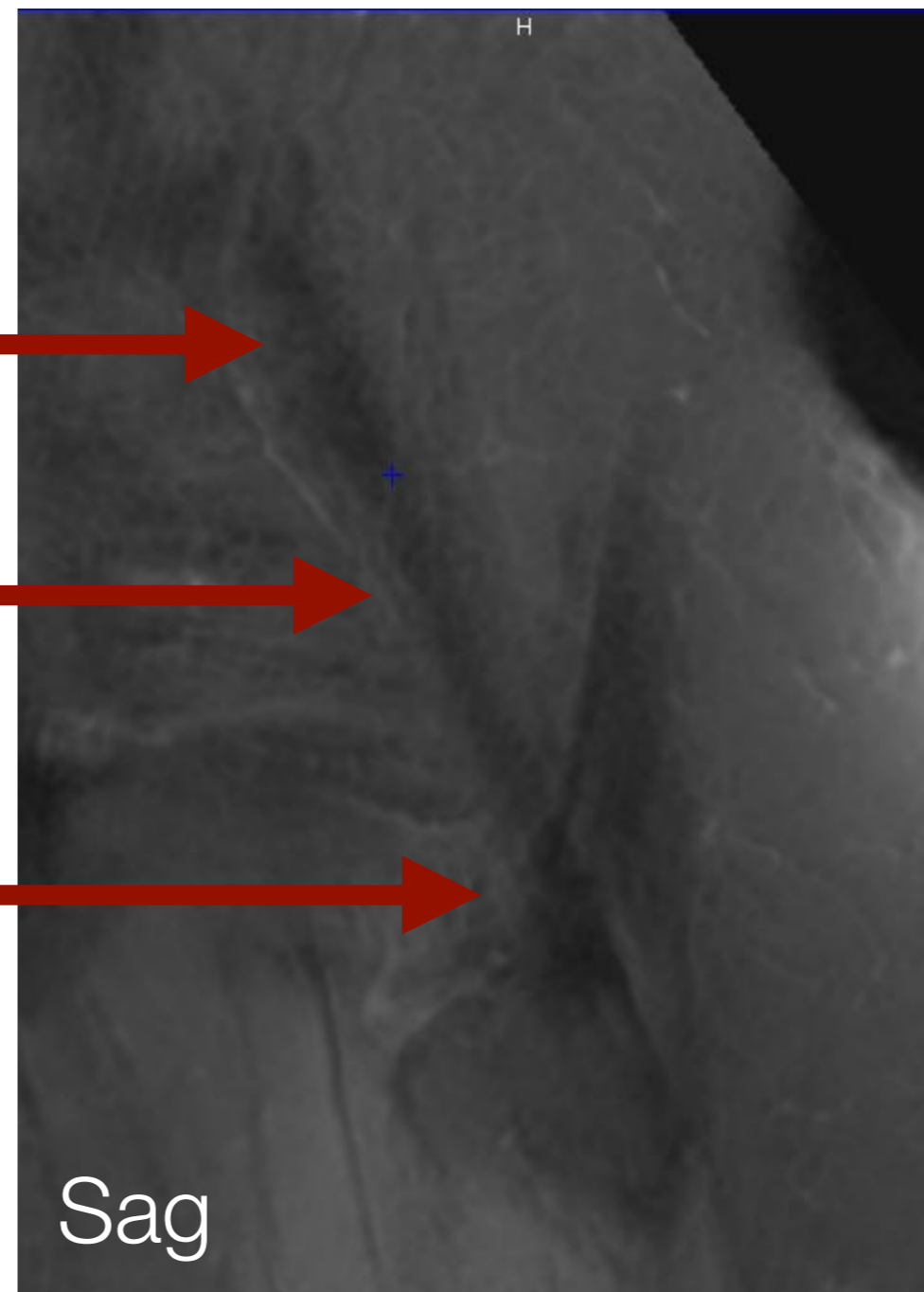
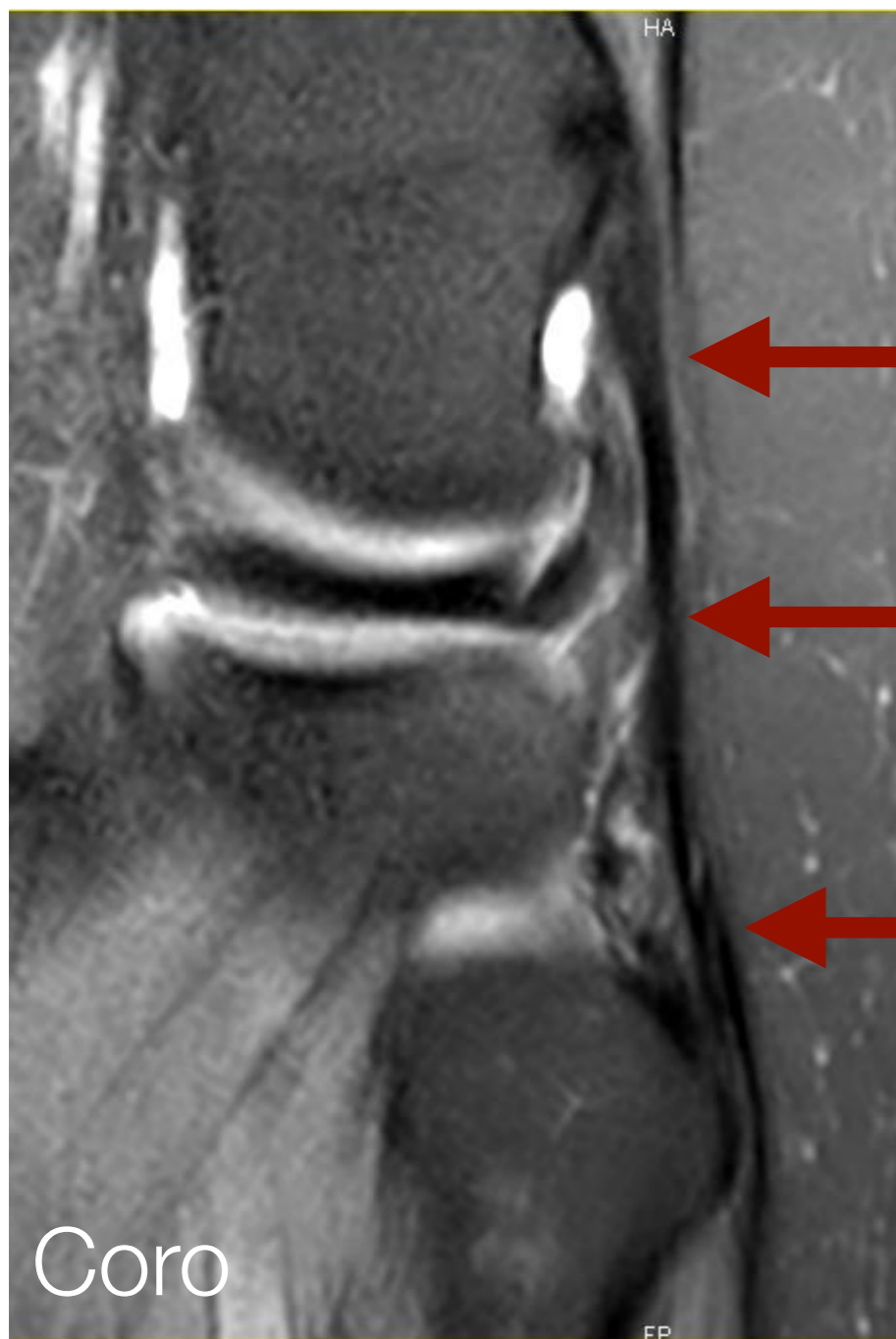


**SM**

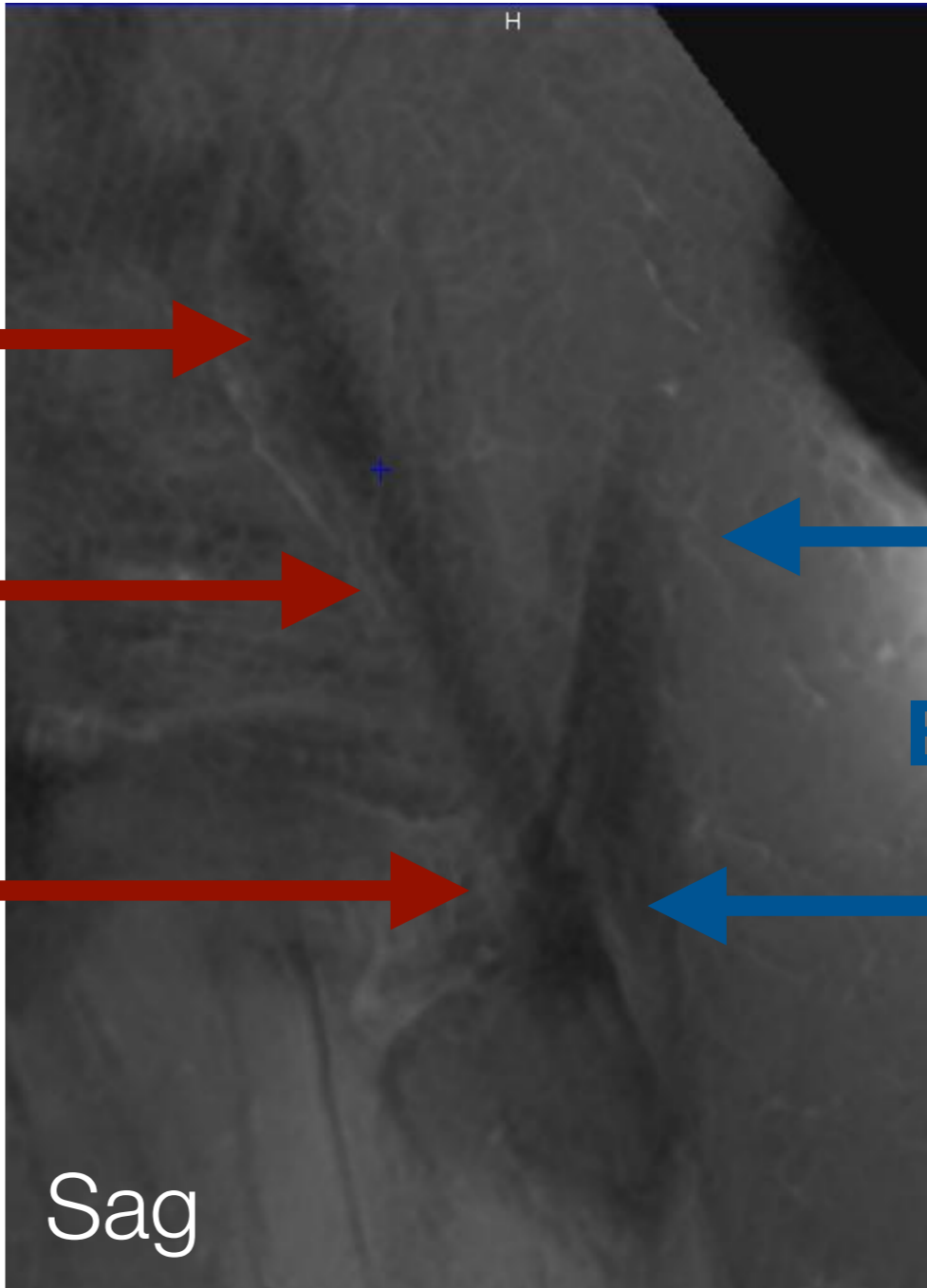
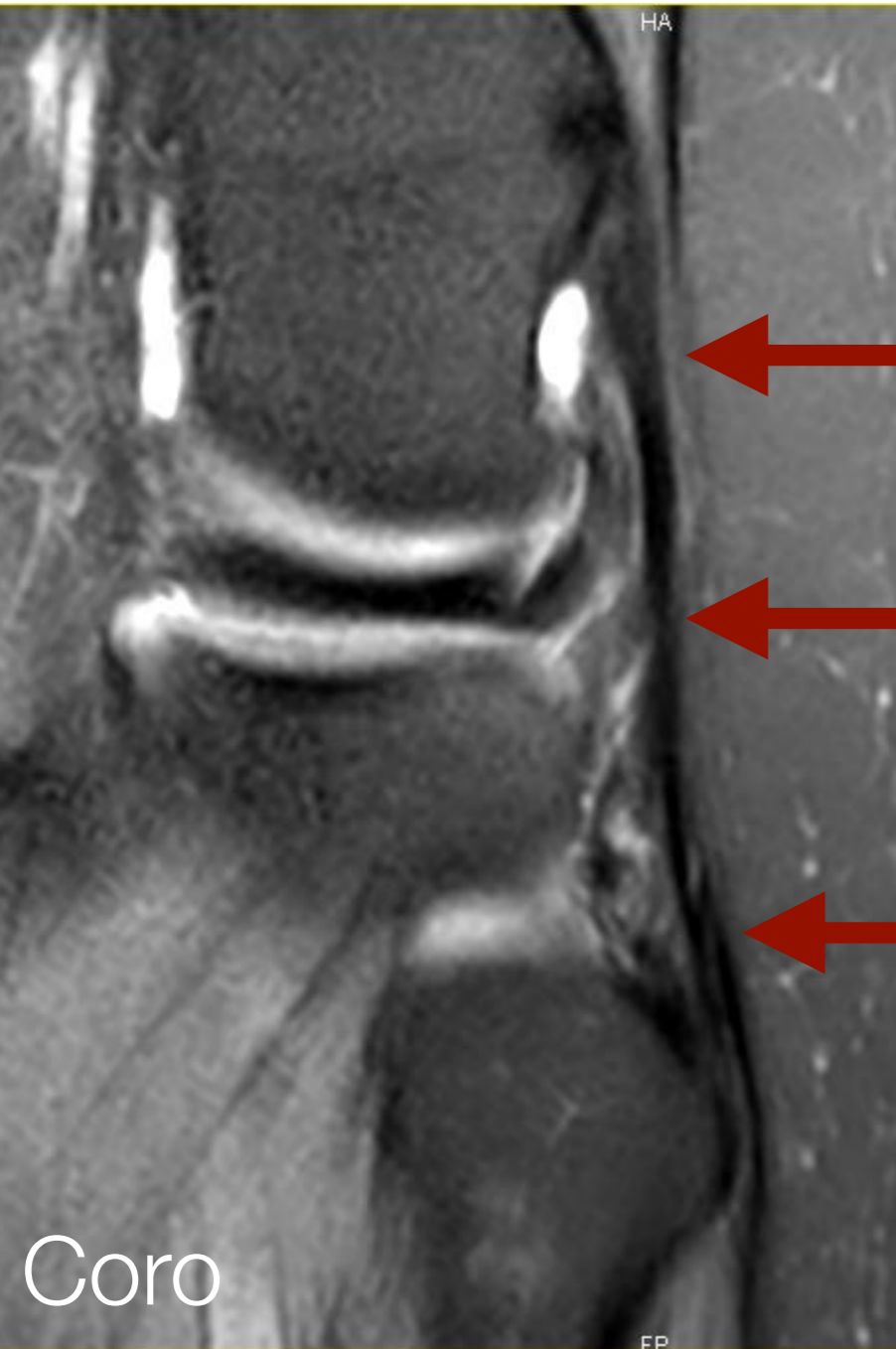
### 3. Ligament Collatéral Latéral LCL



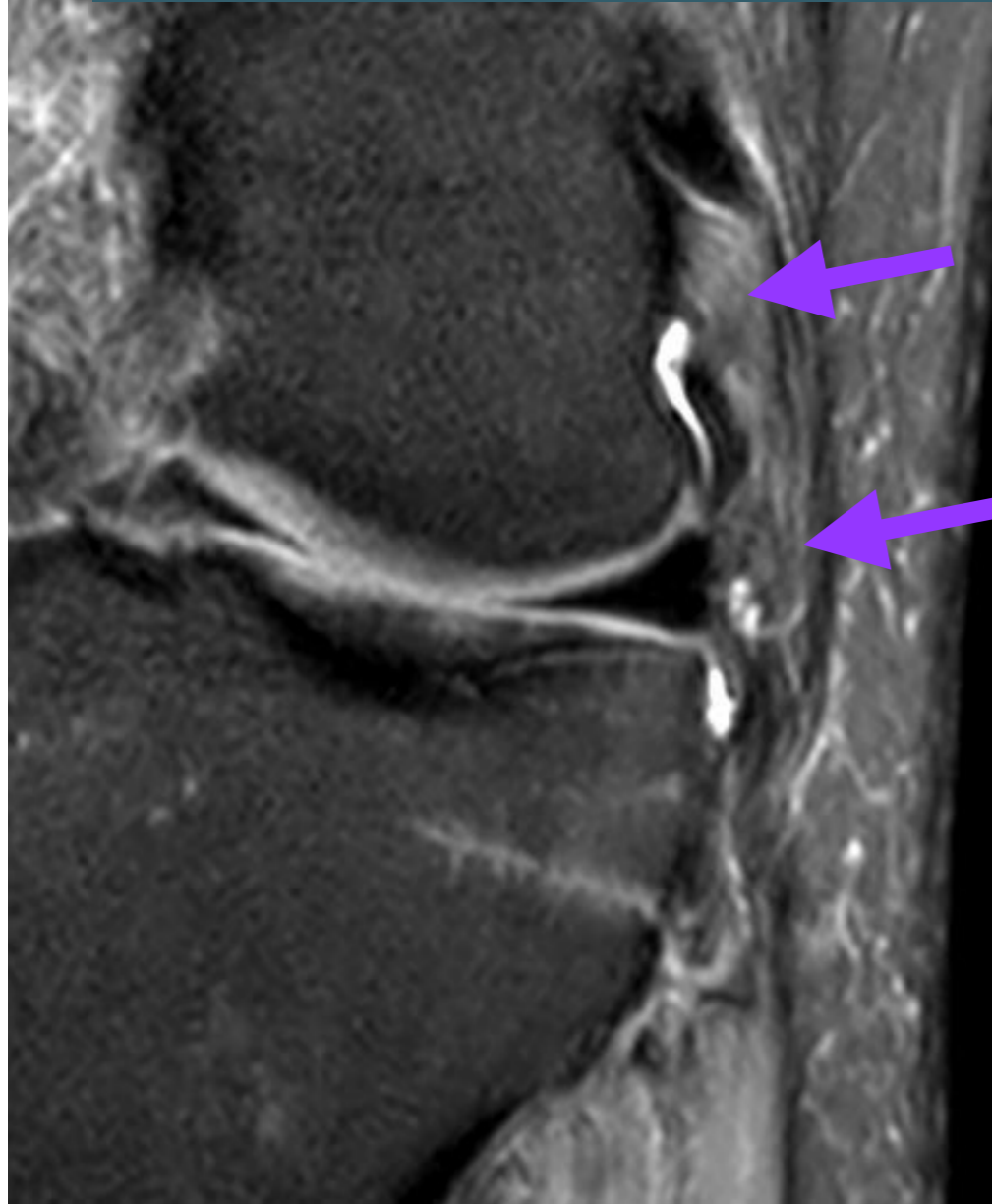
### 3. Ligament Collatéral Latéral LCL



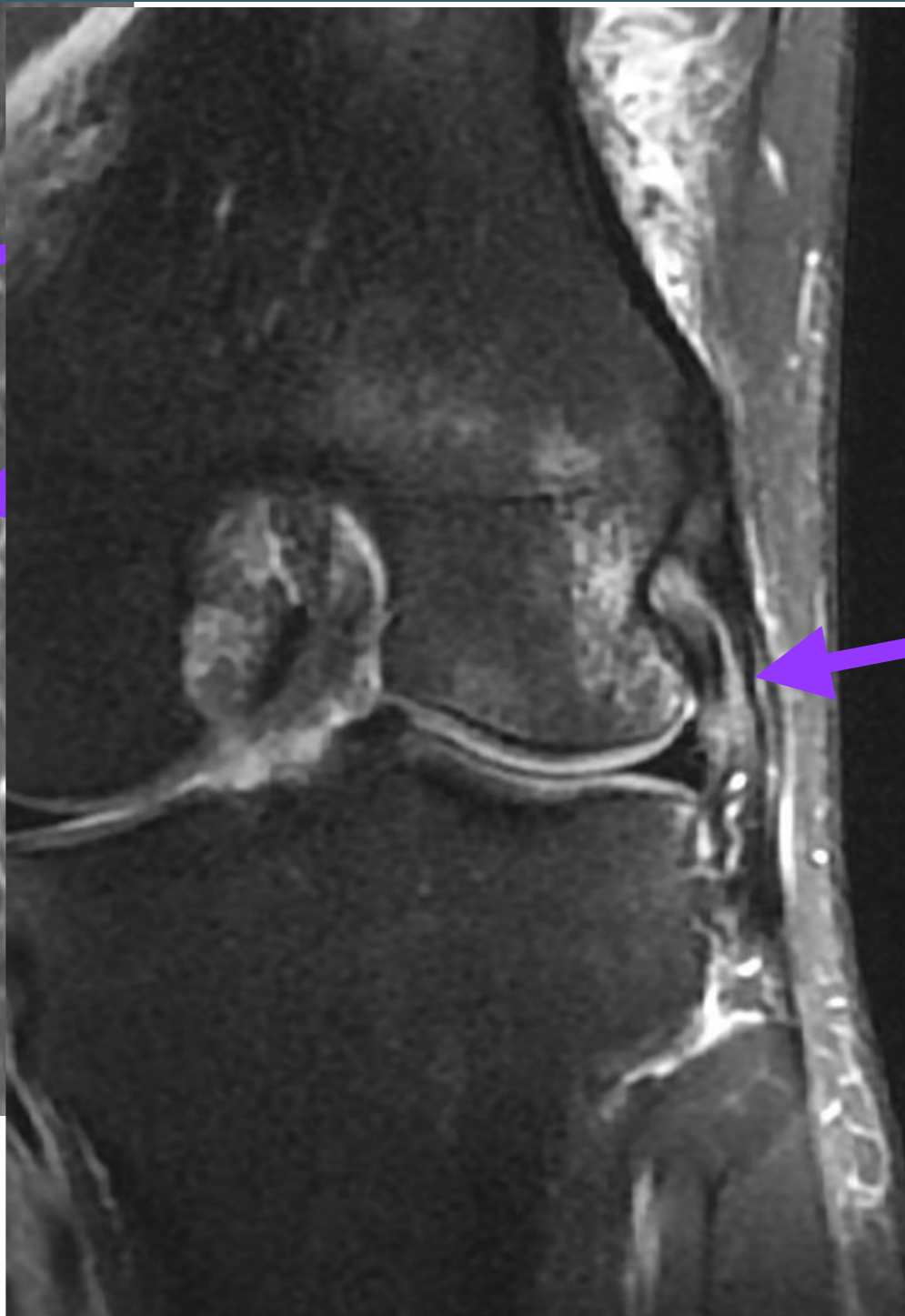
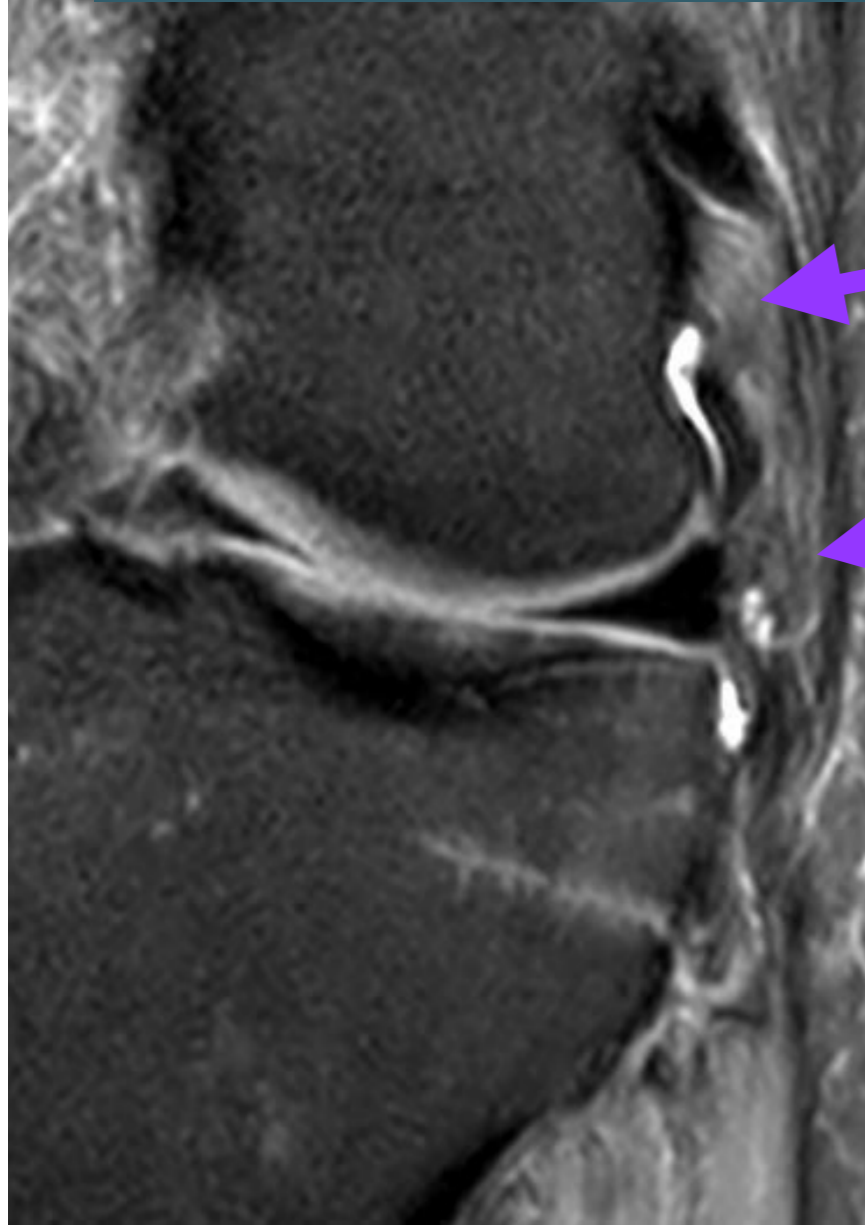
# 3. Ligament Collatéral Latéral LCL



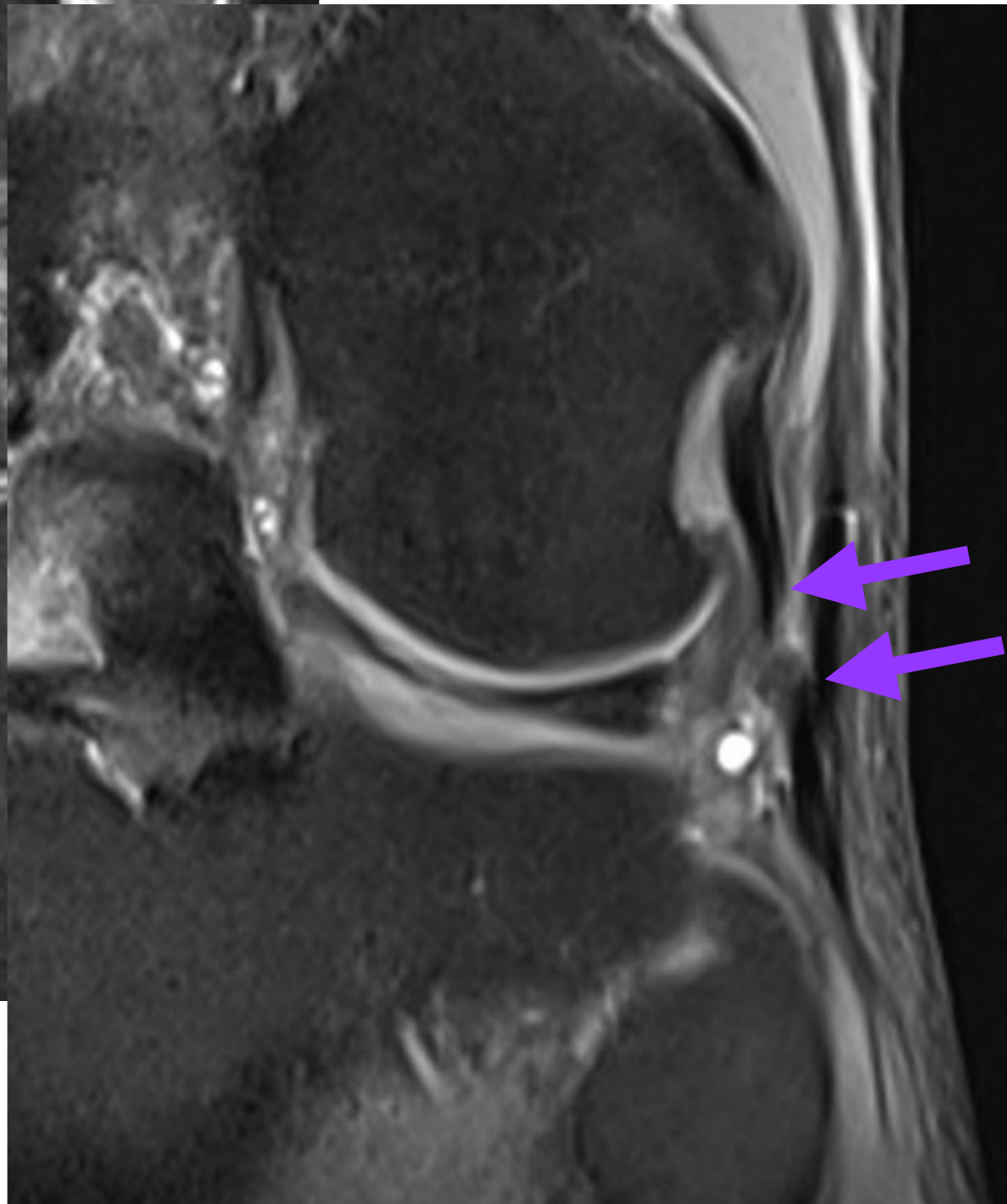
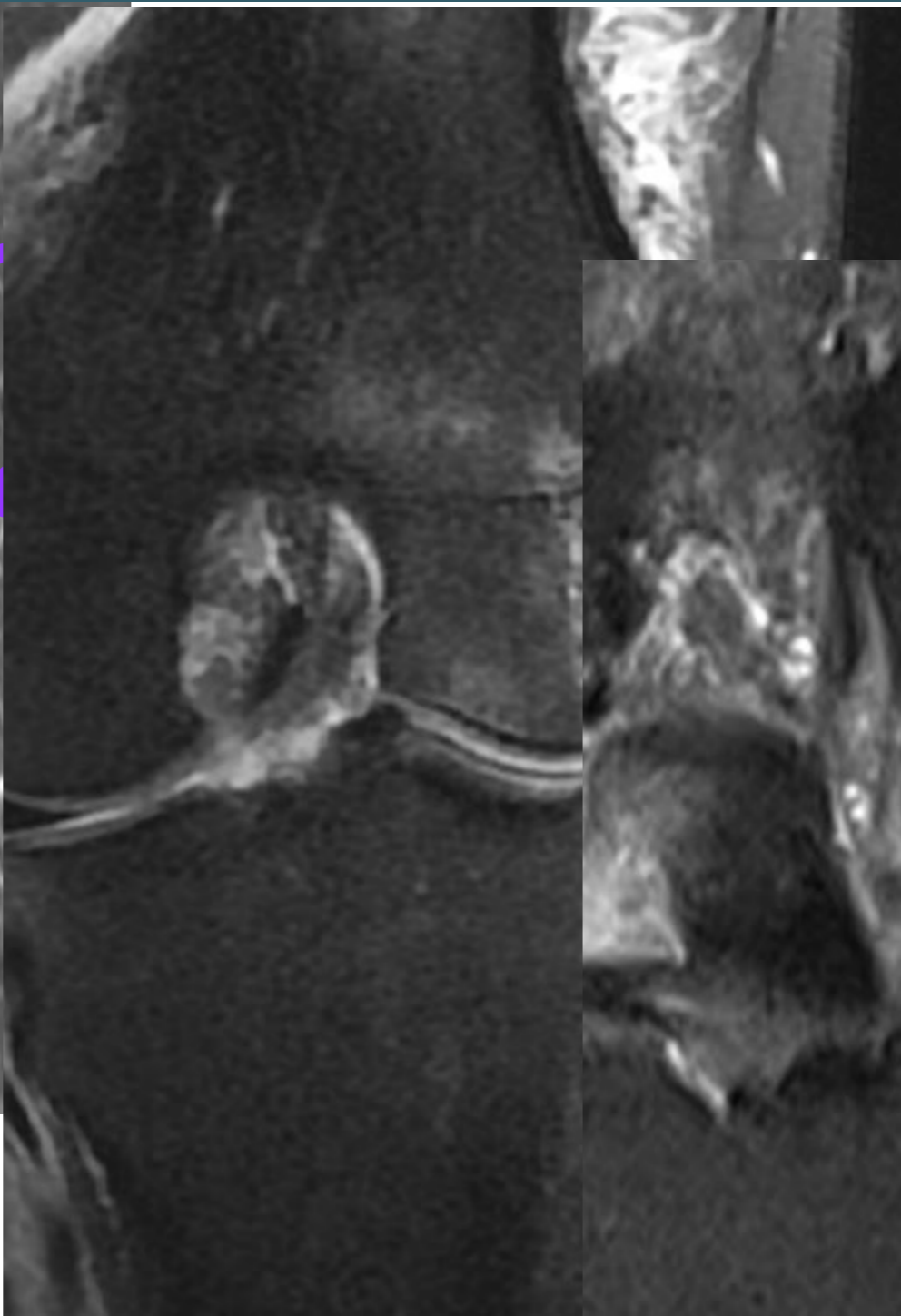
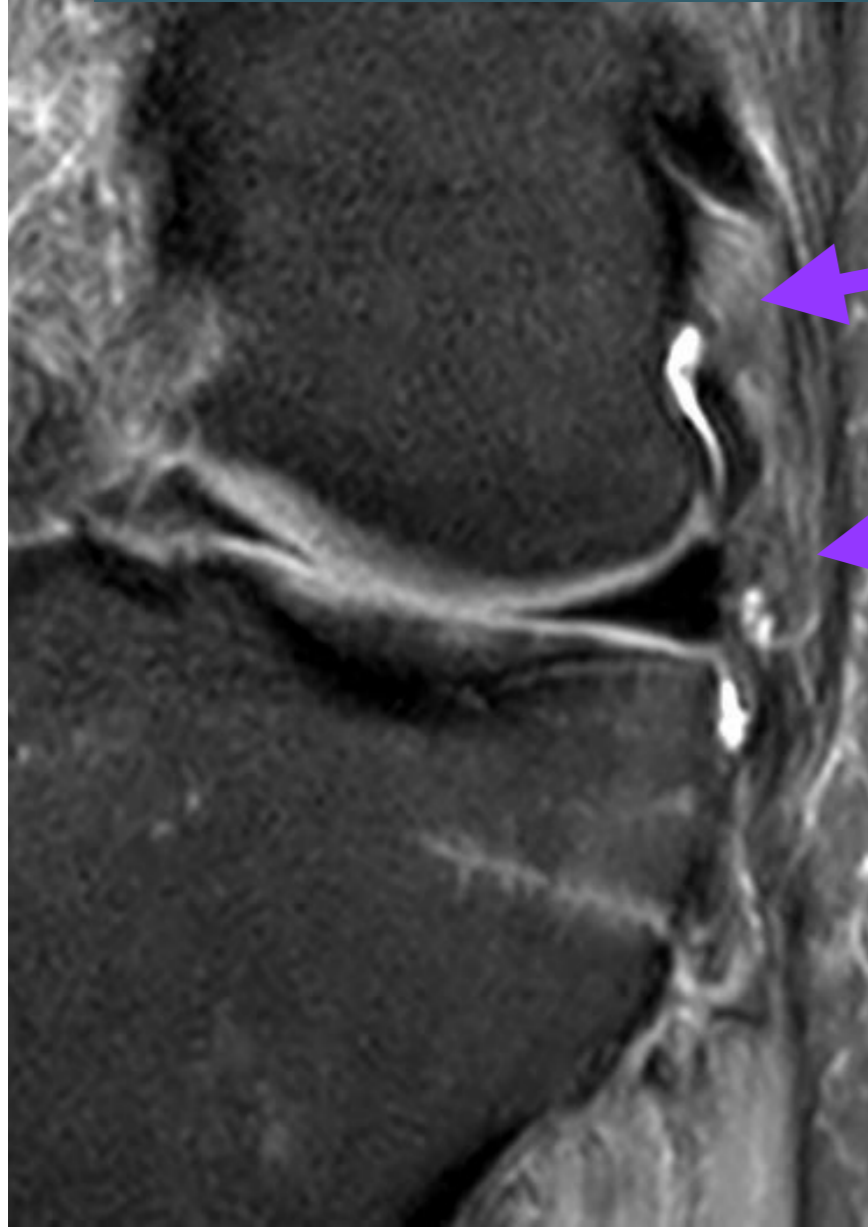
### 3. Ligament Collatéral Latéral LCL



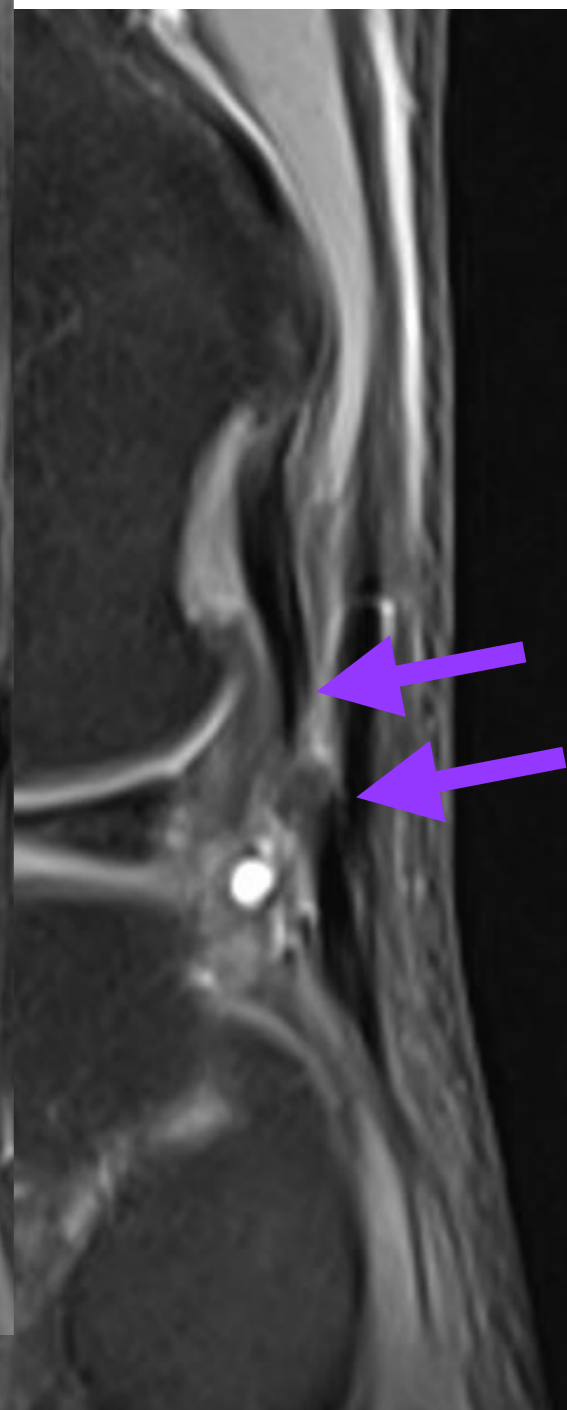
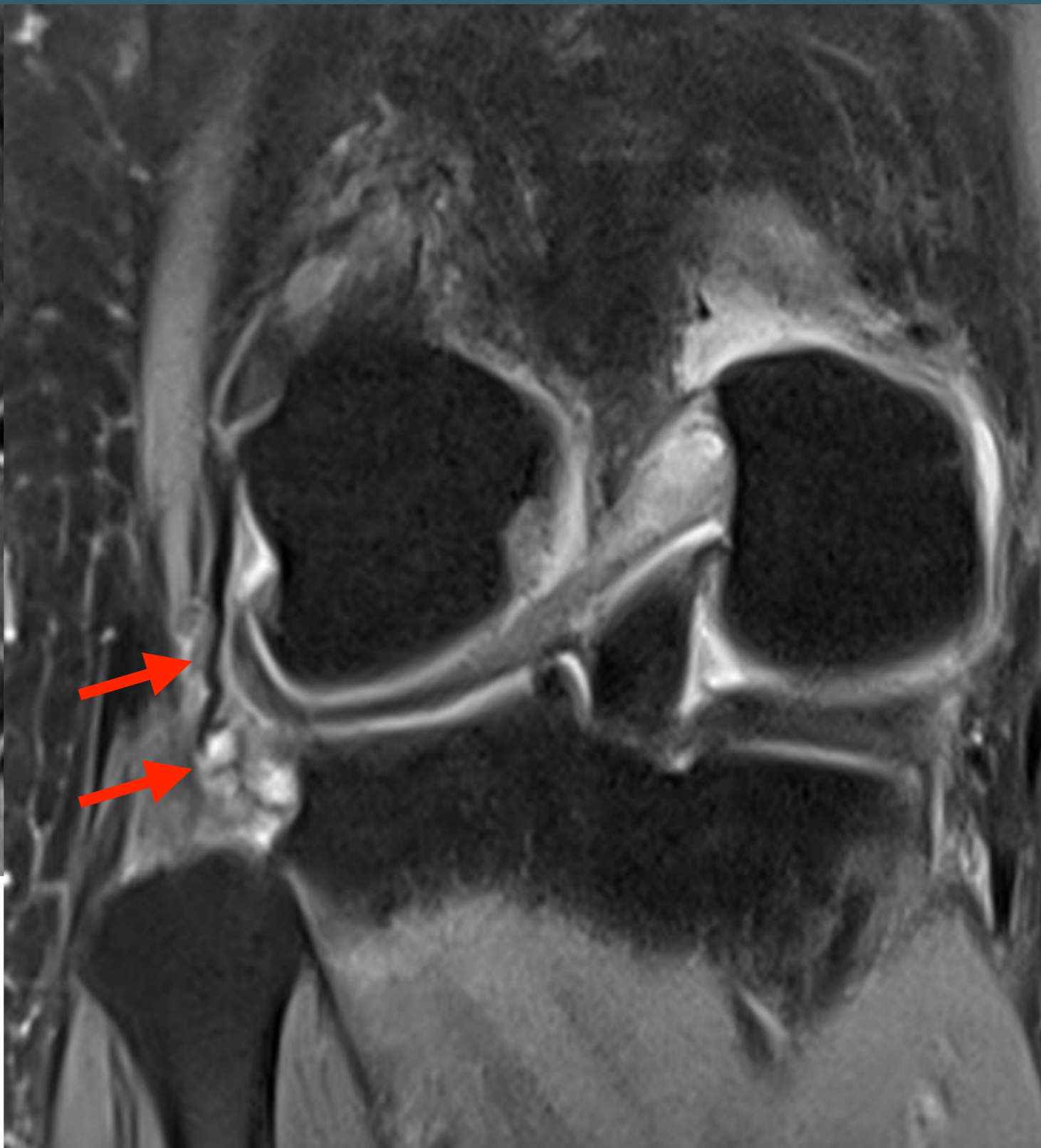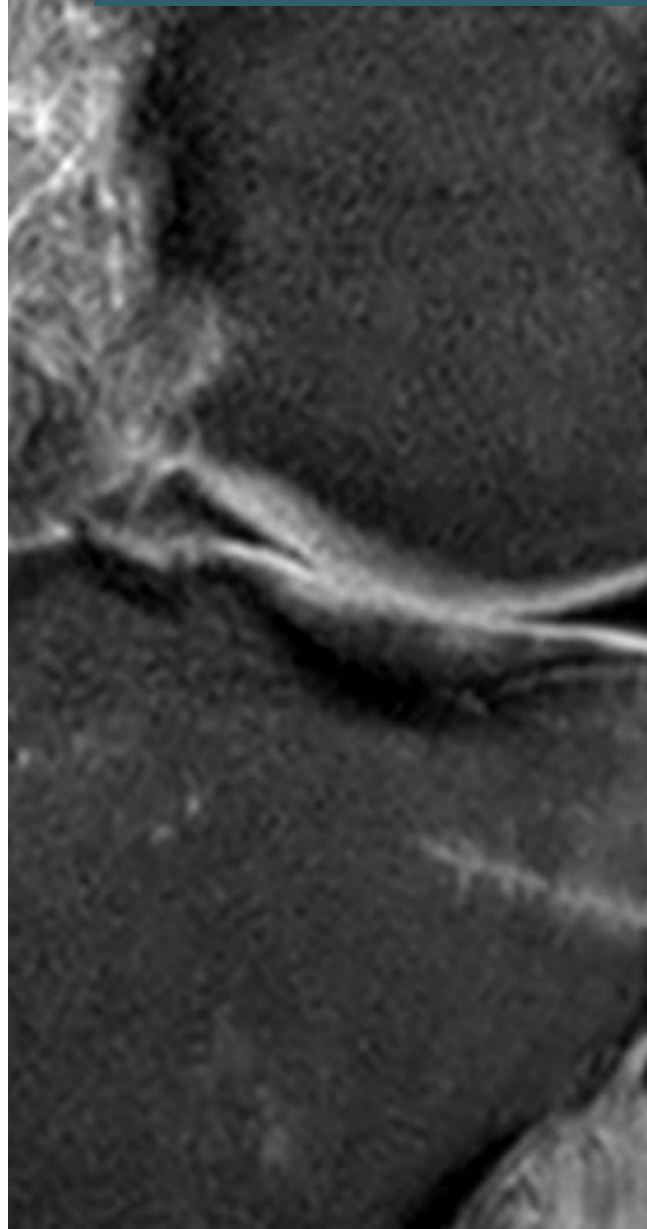
### 3. Ligament Collatéral Latéral LCL



### 3. Ligament Collatéral Latéral LCL

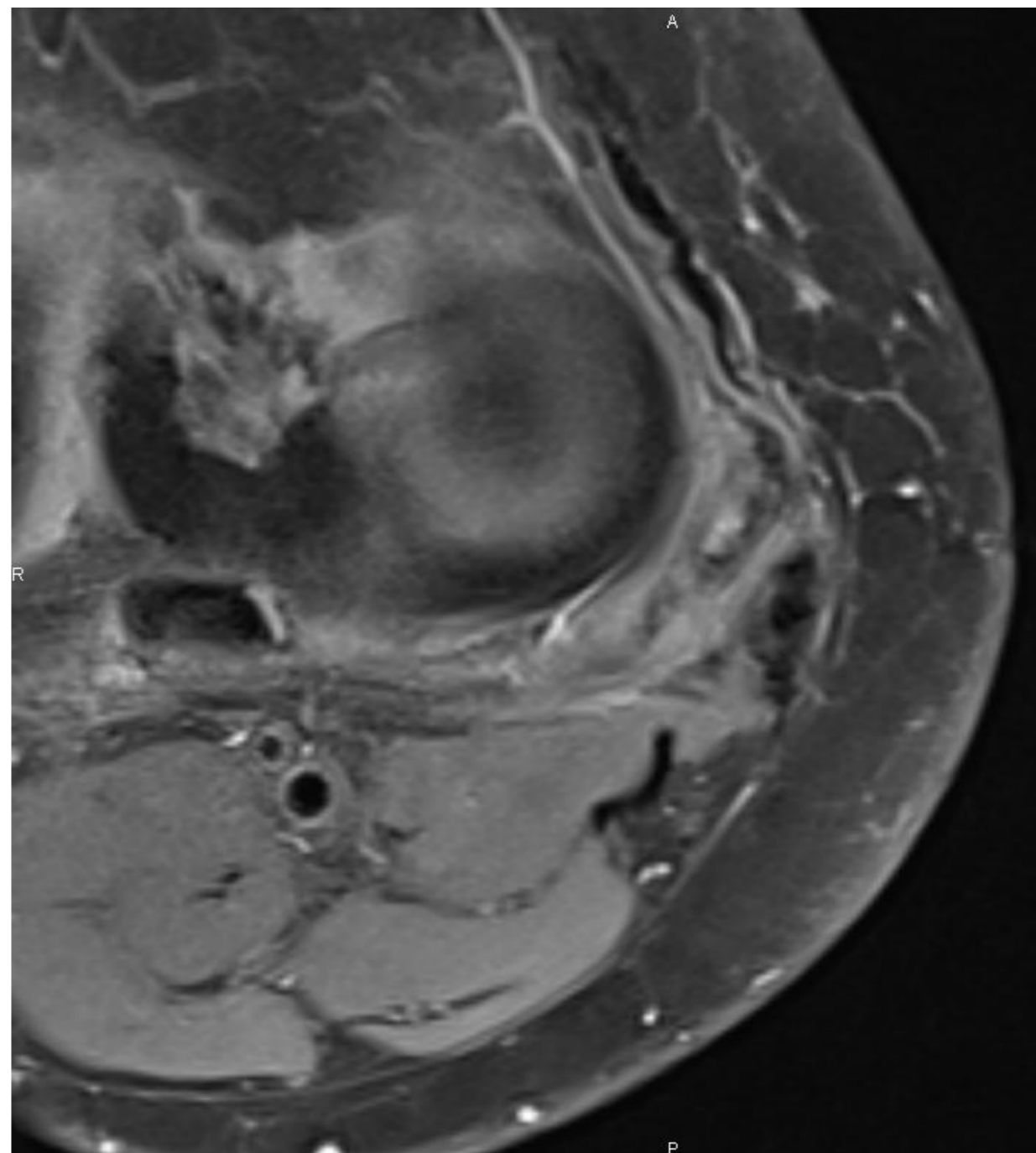
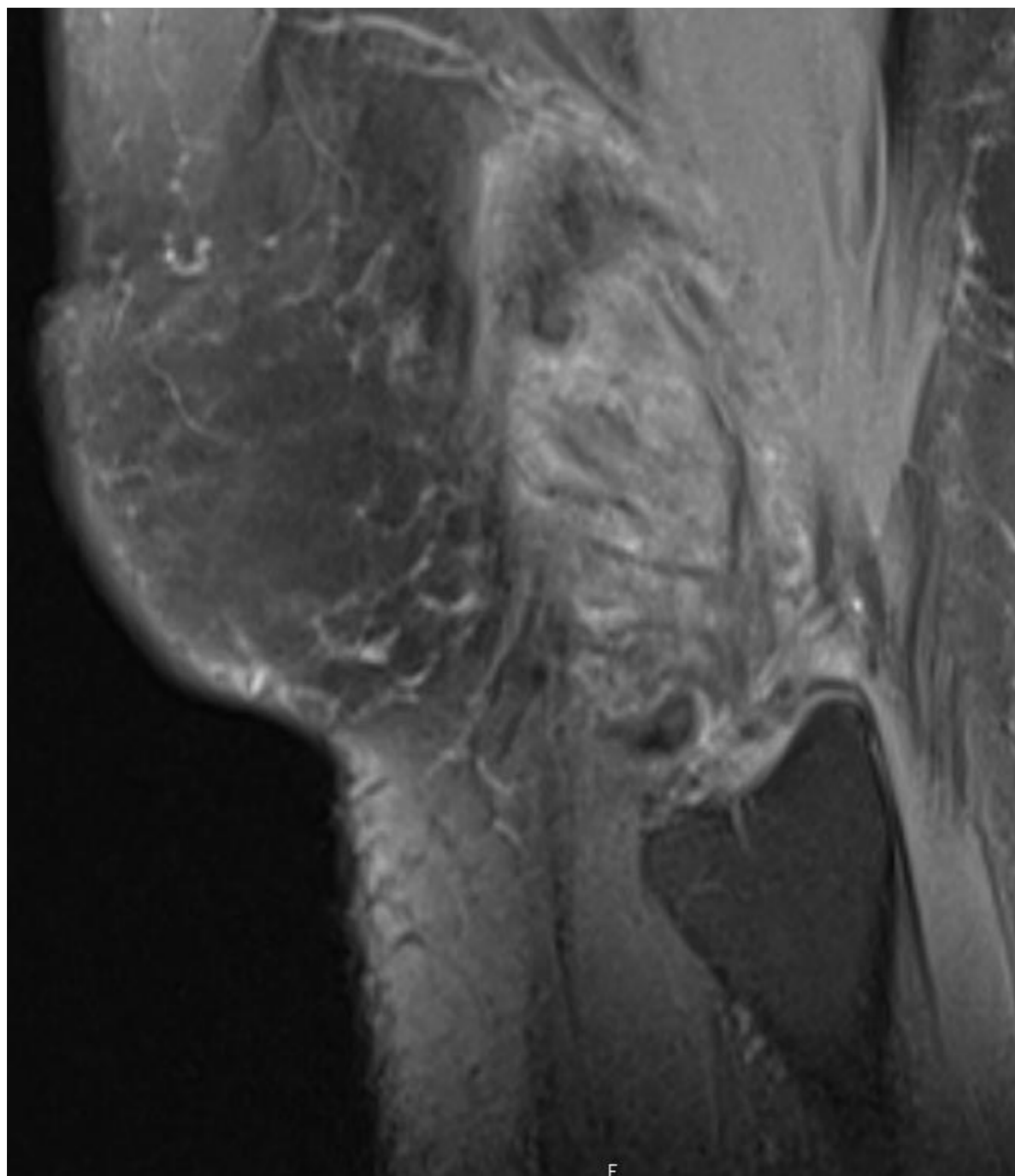


### 3. Ligament Collatéral Latéral LCL

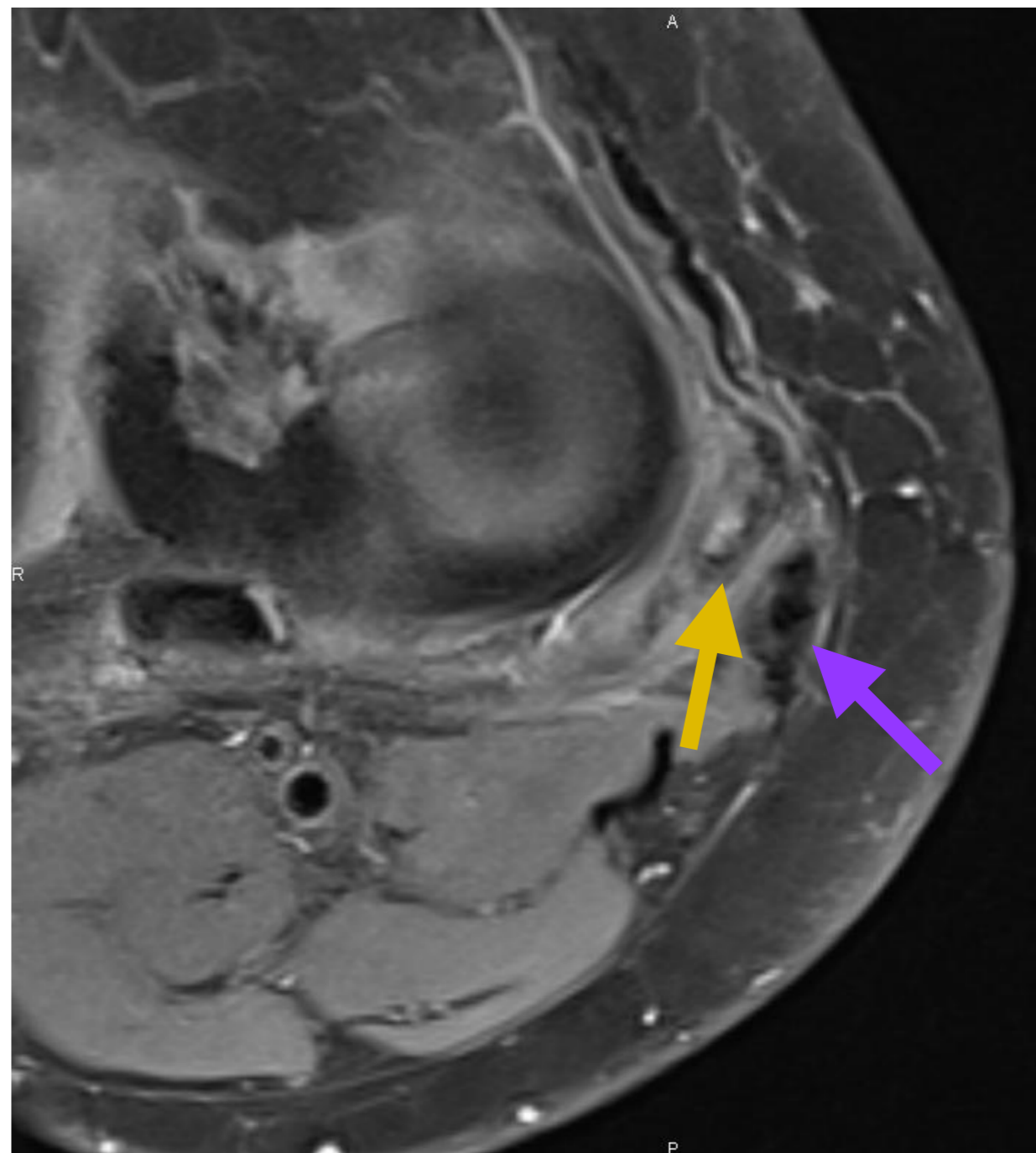
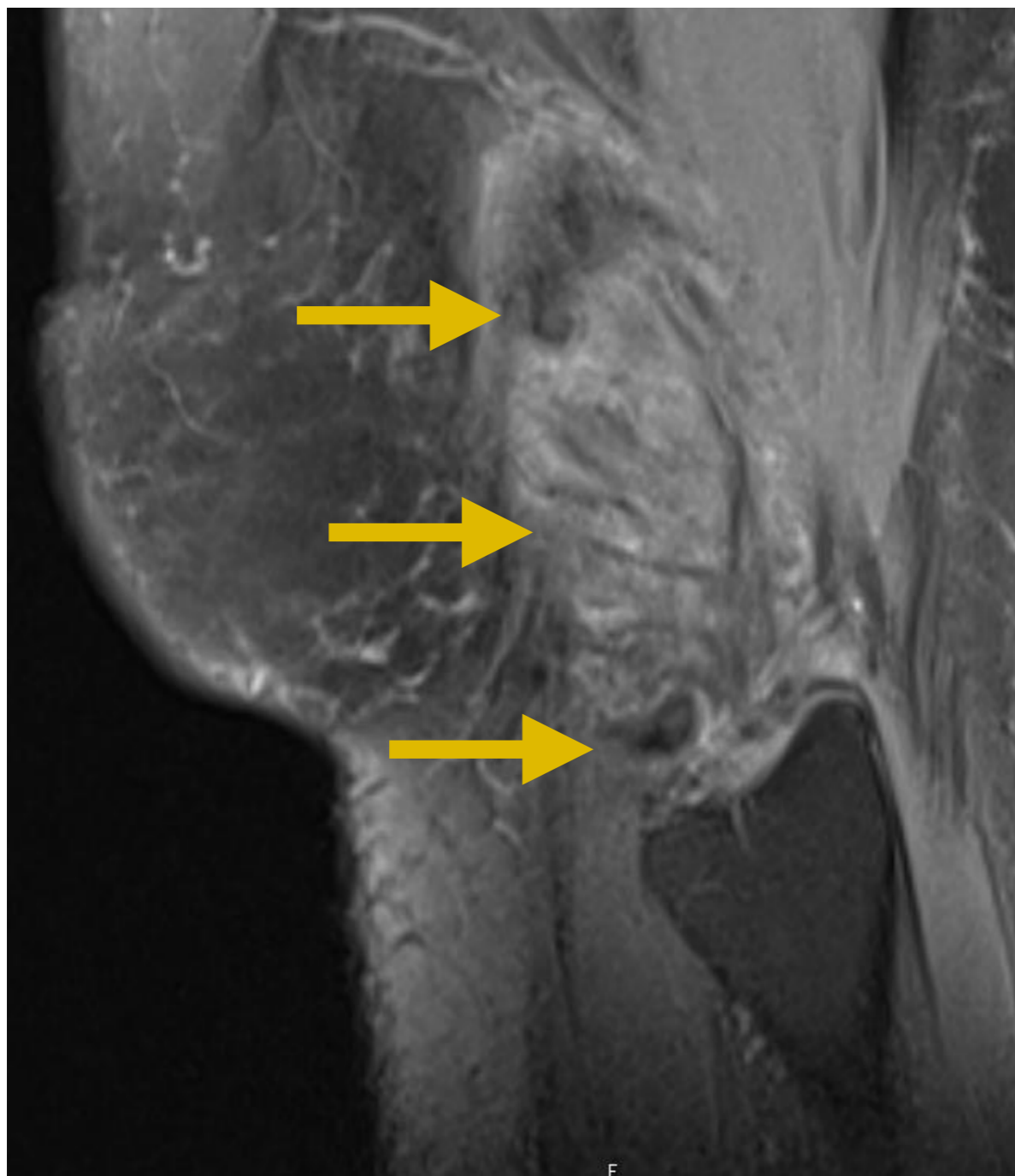




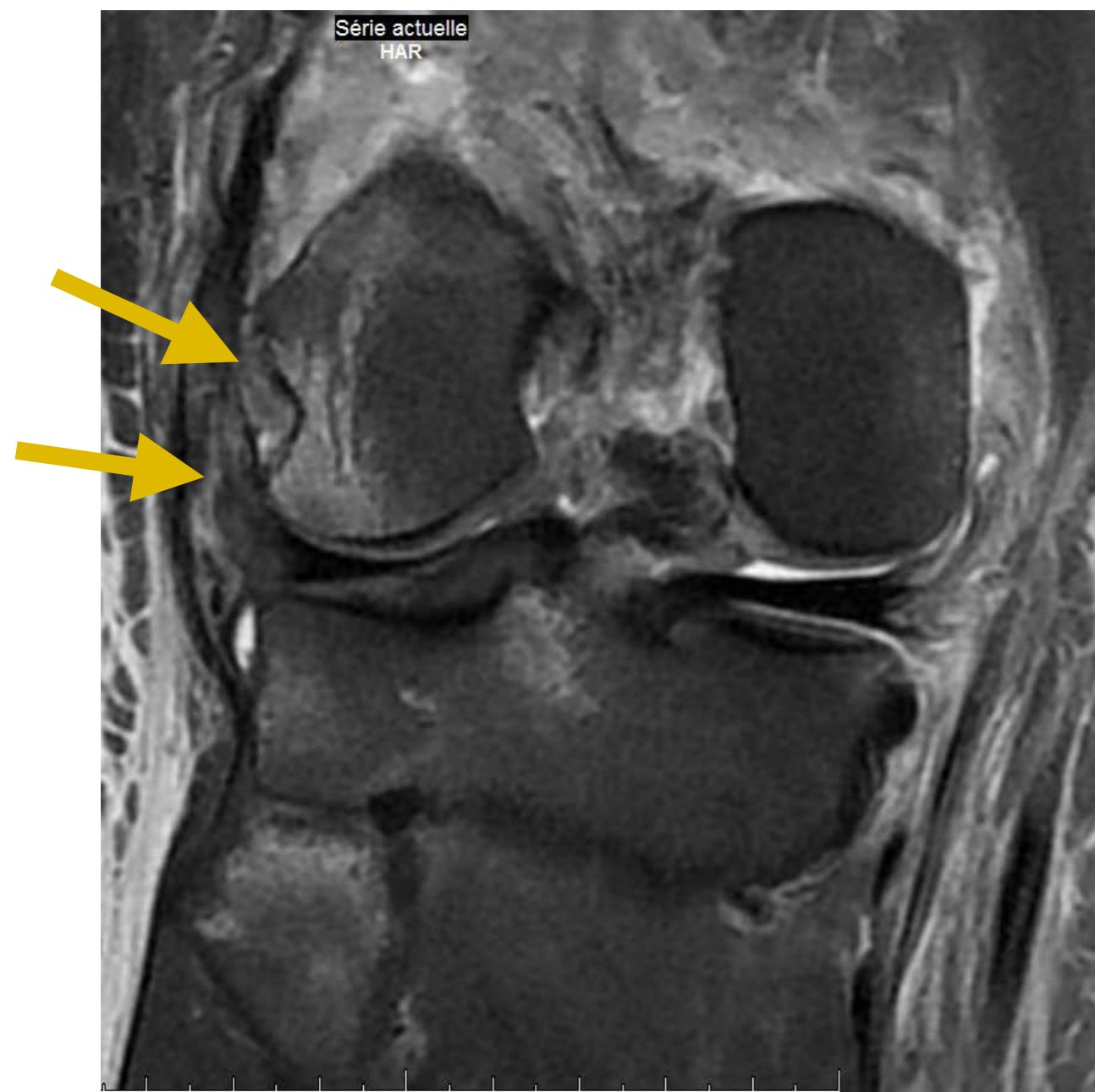
### 3. Ligament Collatéral Latéral LCL



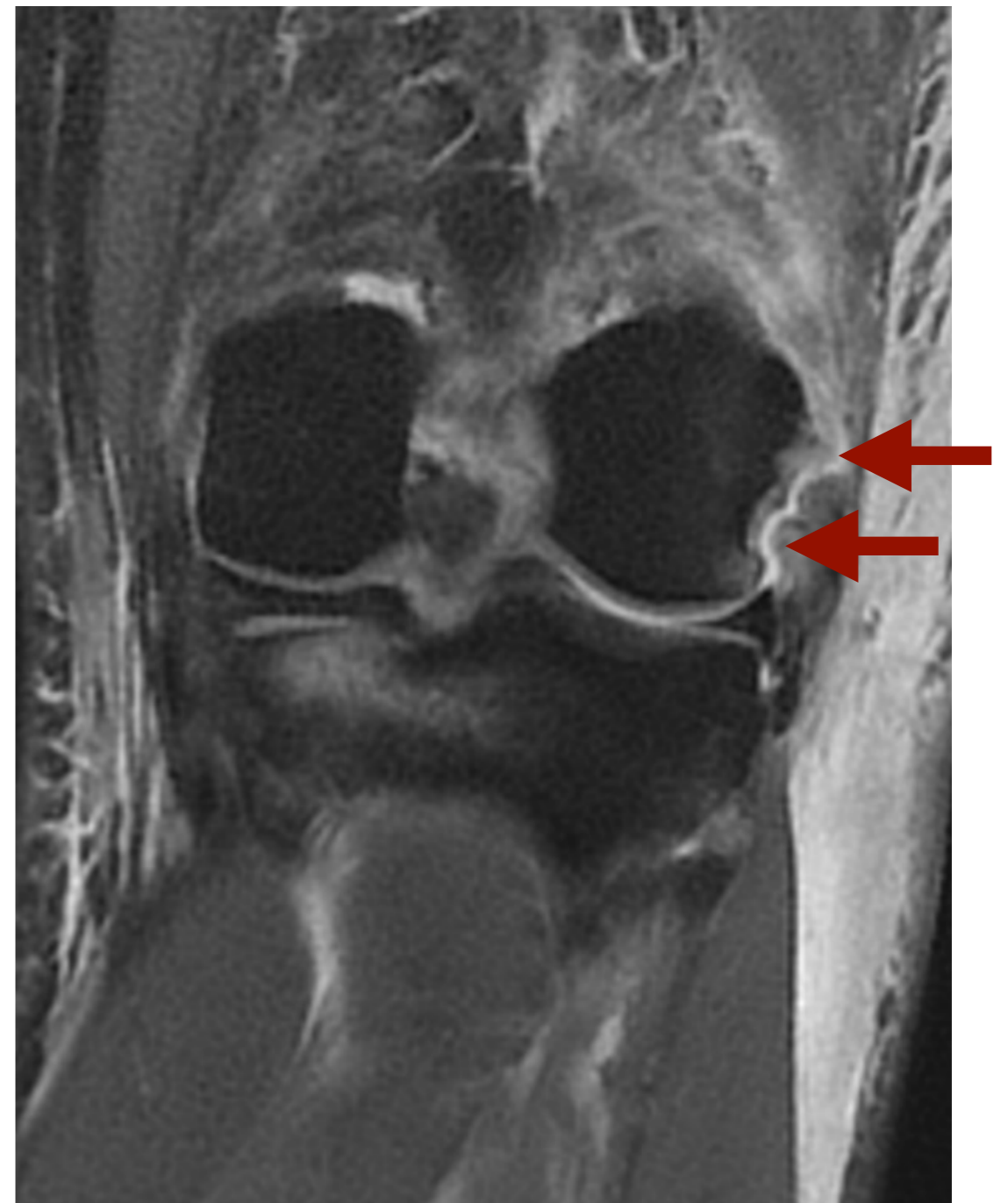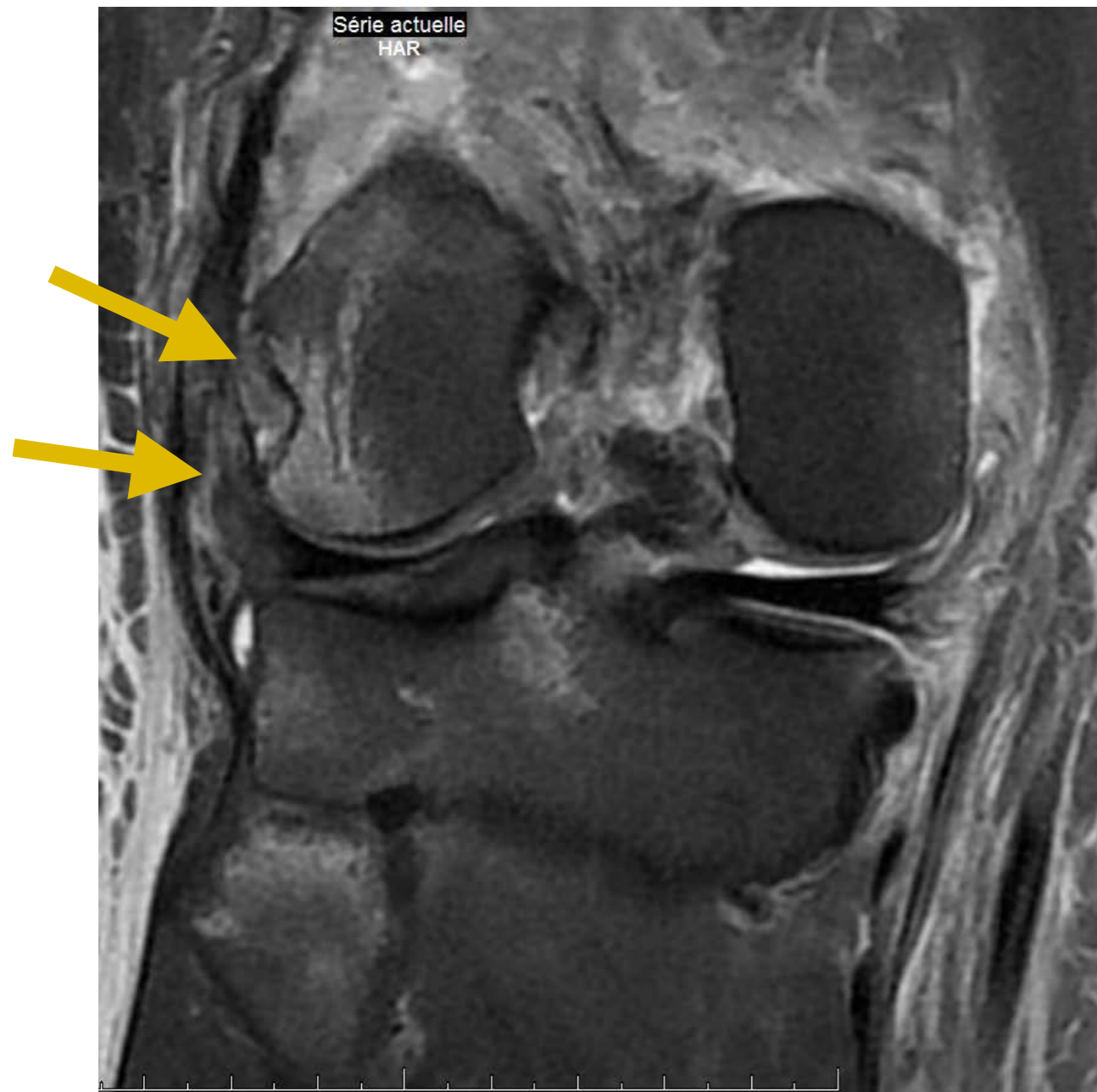
### 3. Ligament Collatéral Latéral LCL



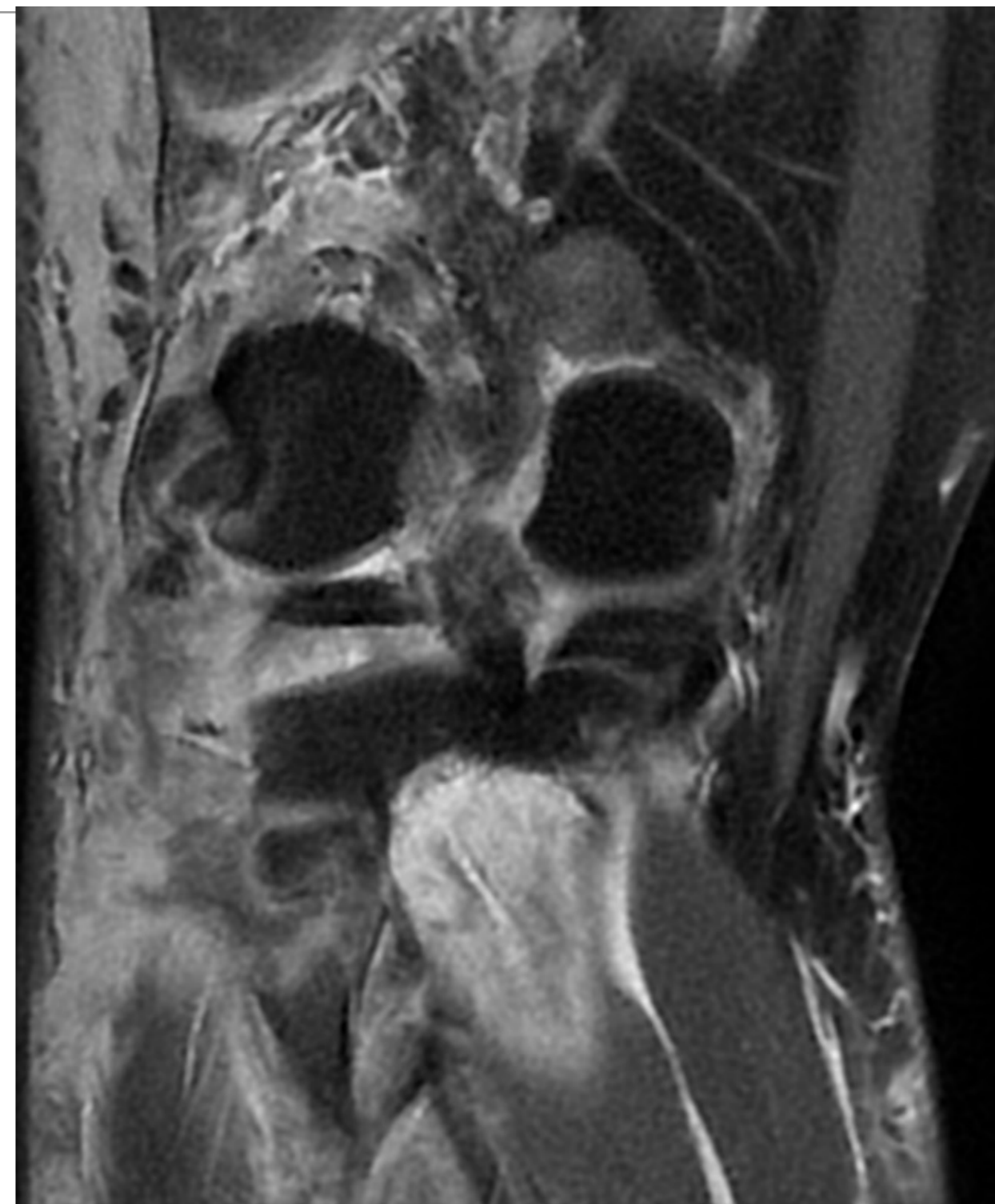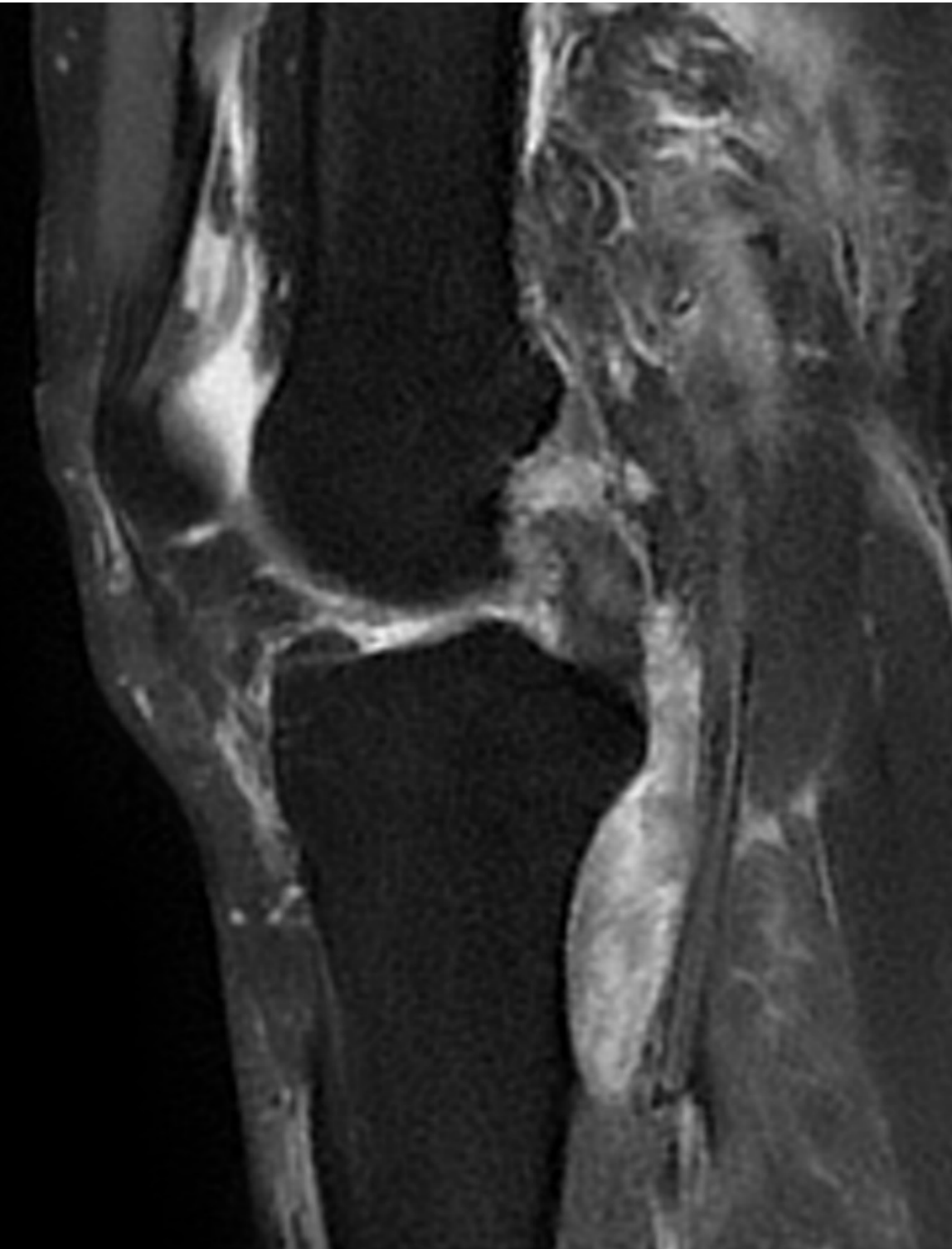
### 3. Autres : Tendon Poplité



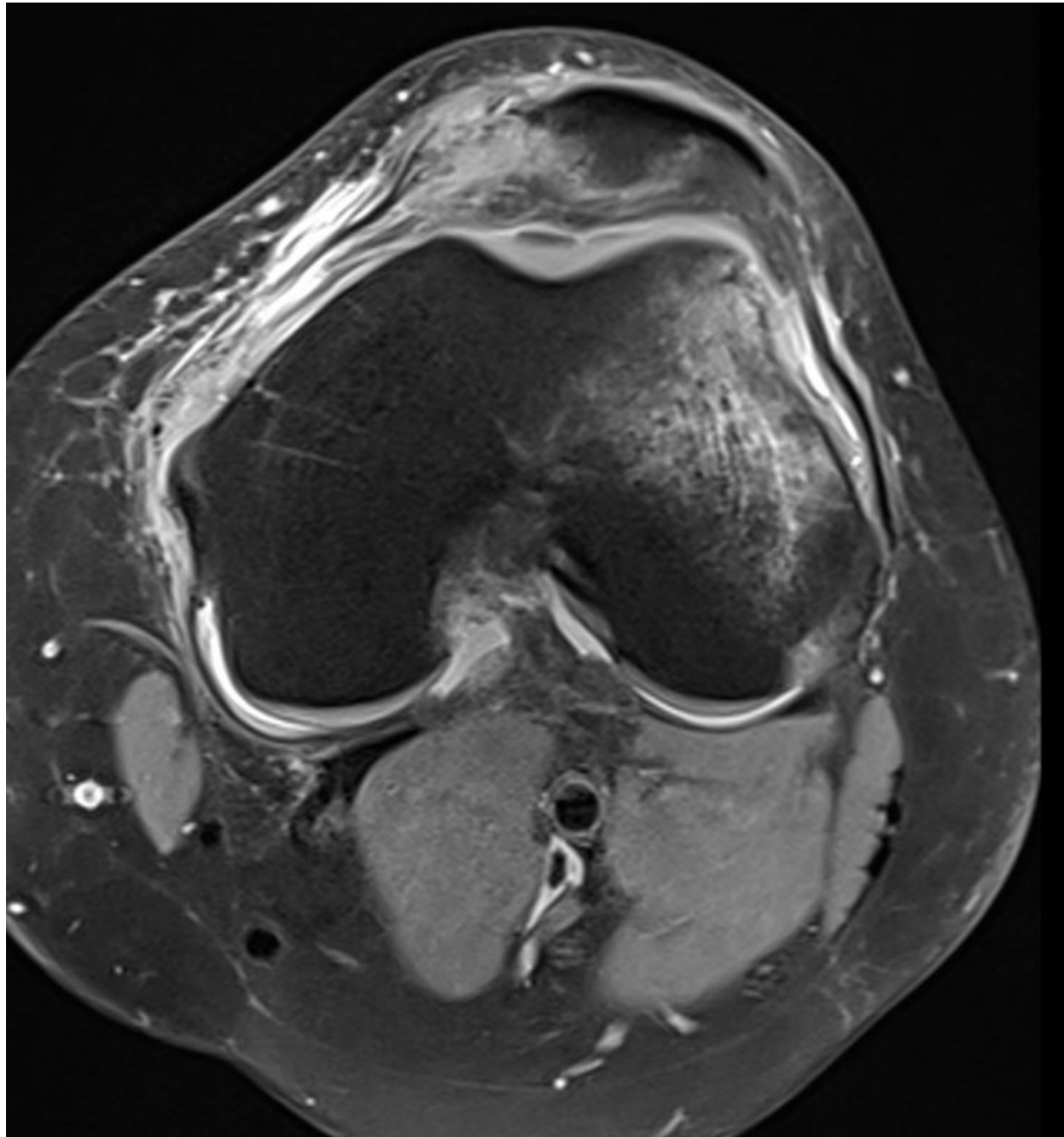
### 3. Autres : Tendon Poplité



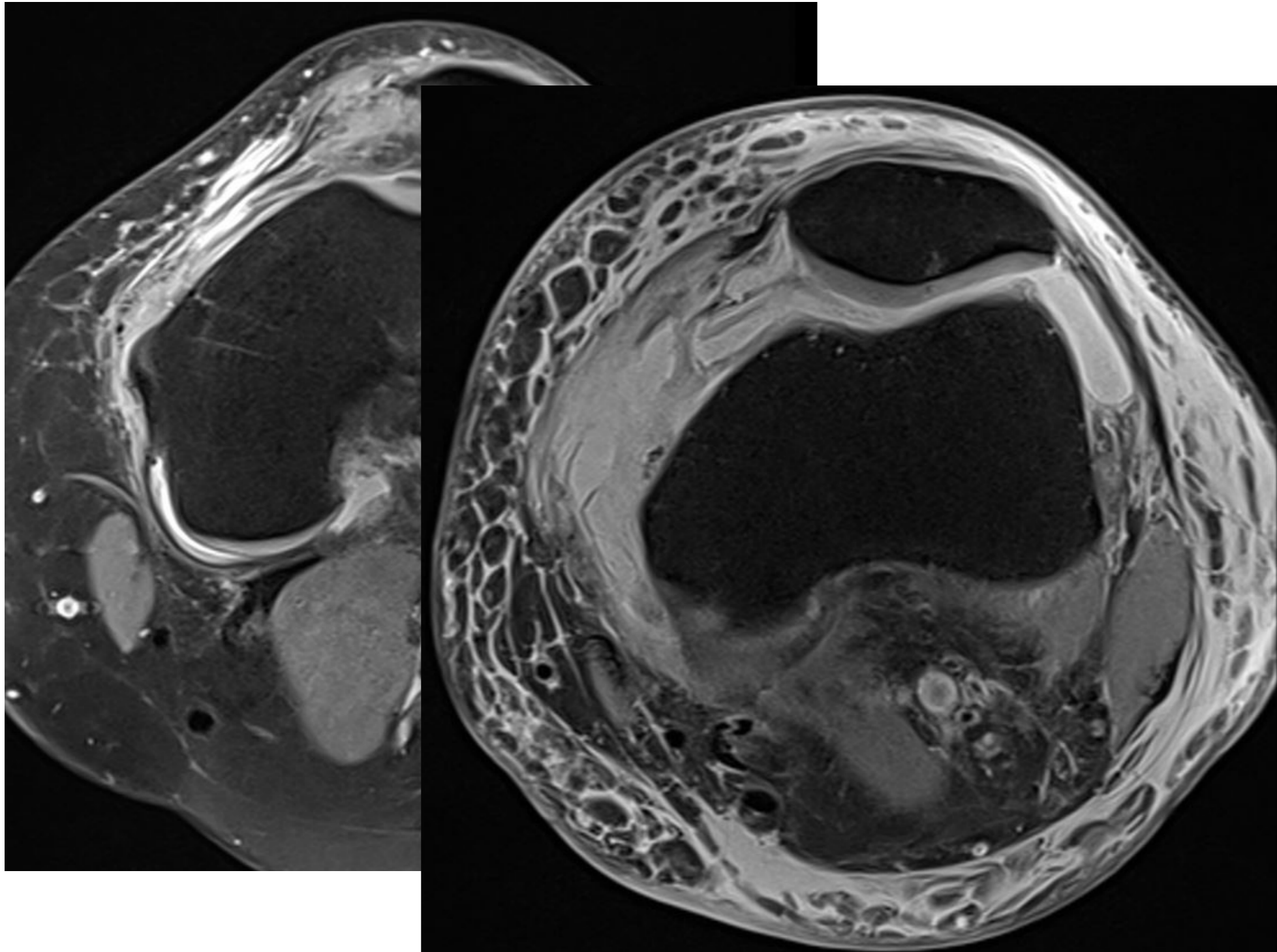
### 3. Tendon Poplité



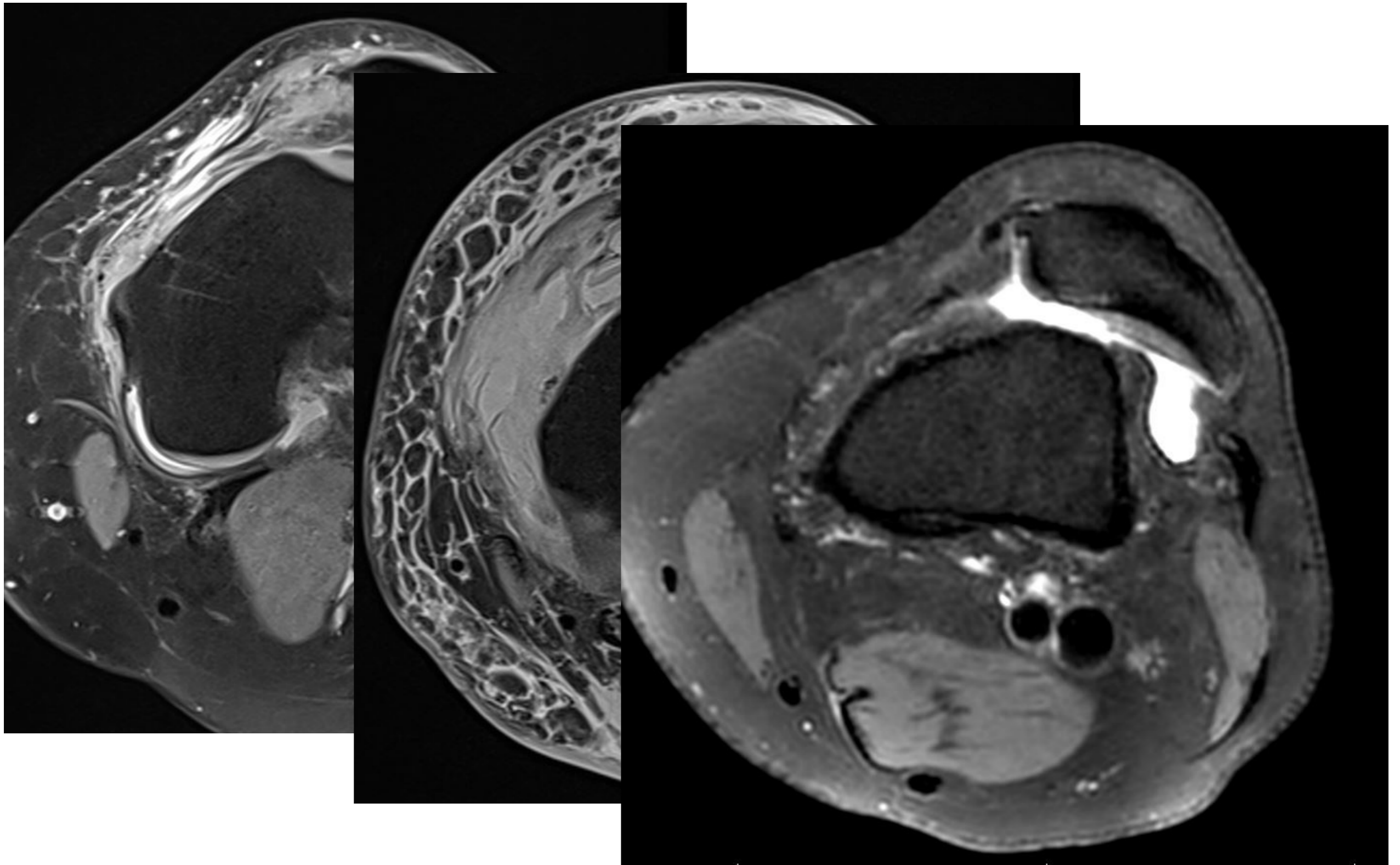
### 3. Ligament fémoro-patellaire médial MPFL



### 3. Ligament fémoro-patellaire médial MPFL

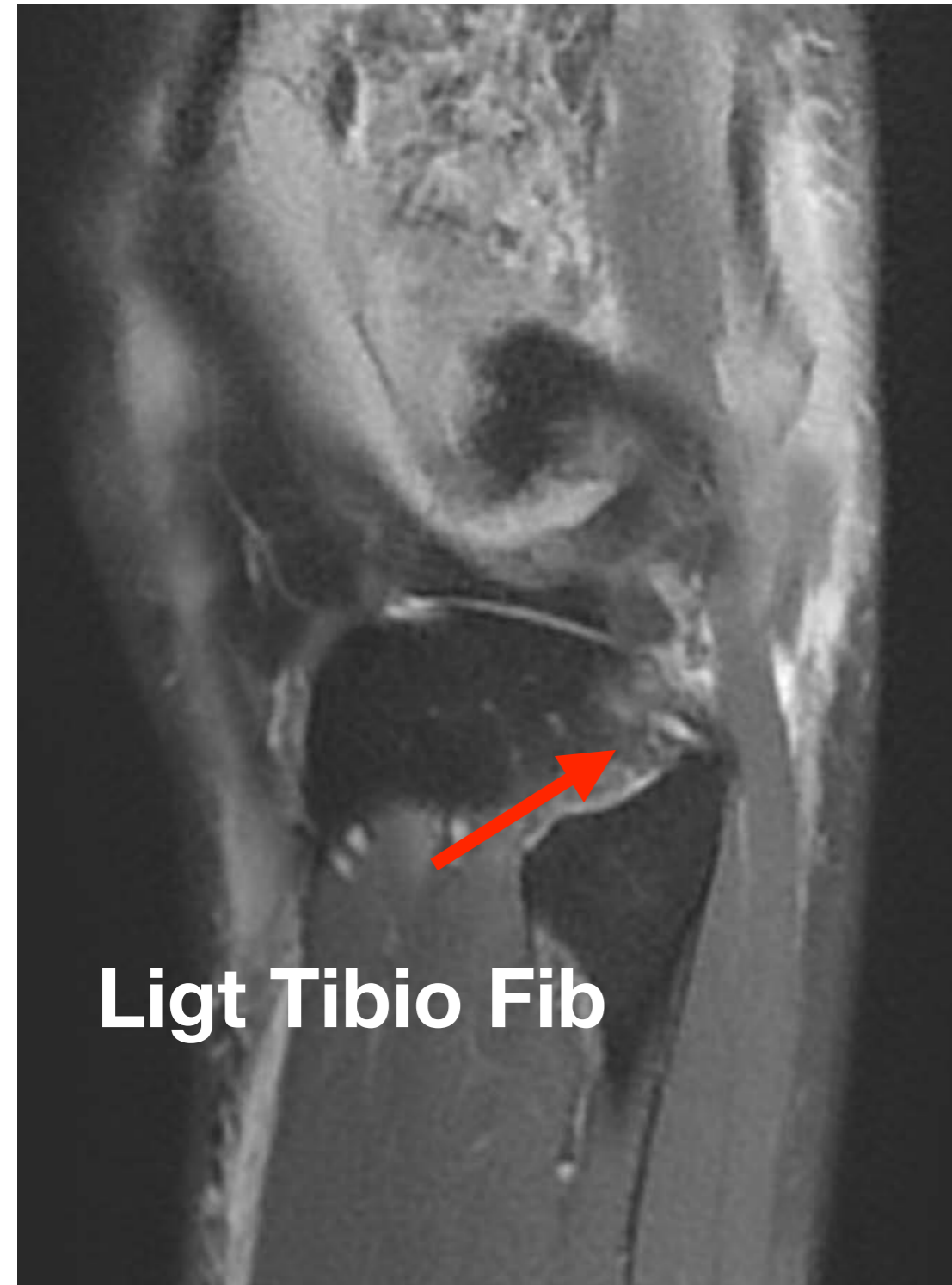


### 3. Ligament fémoro-patellaire médial MPFL

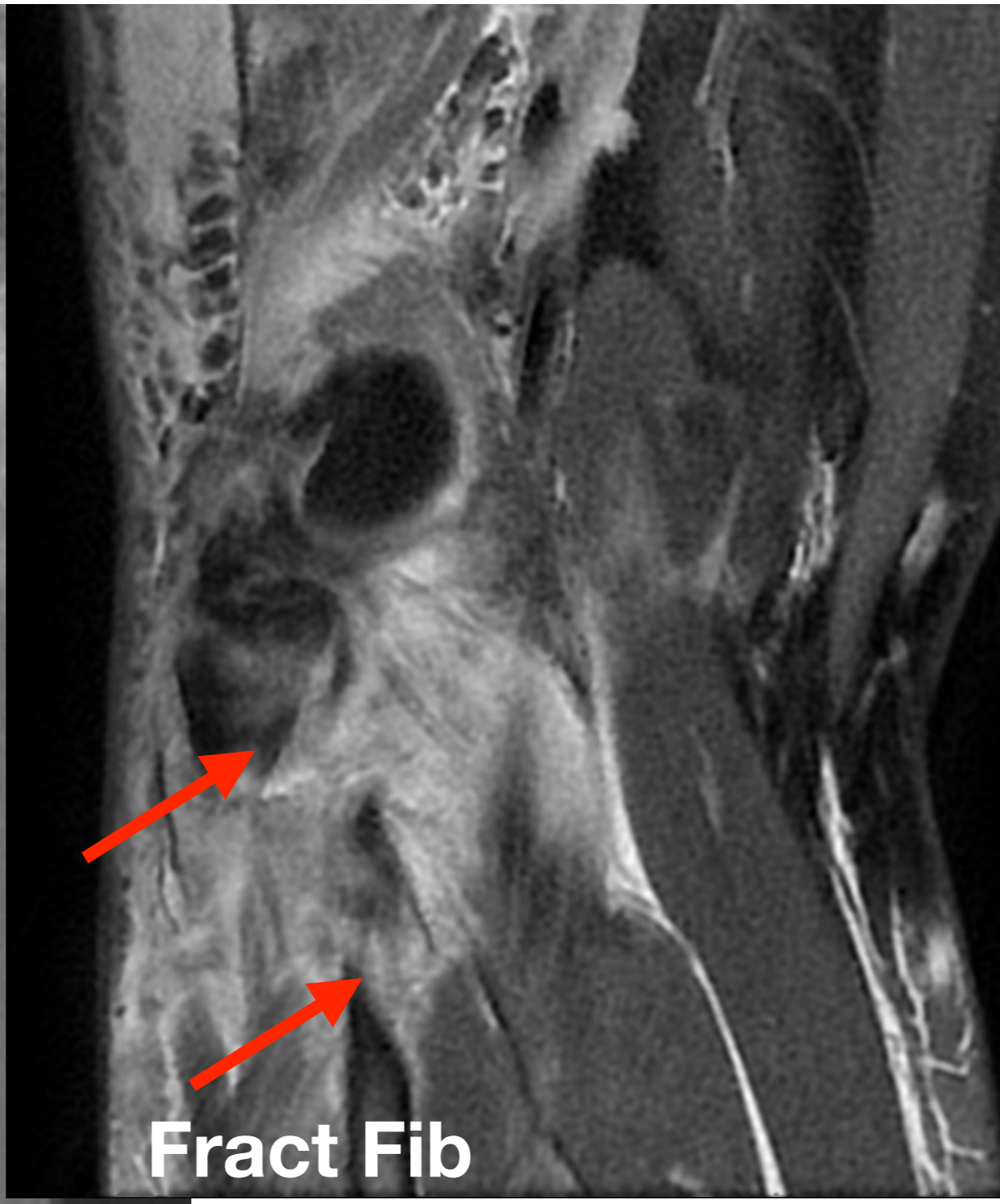
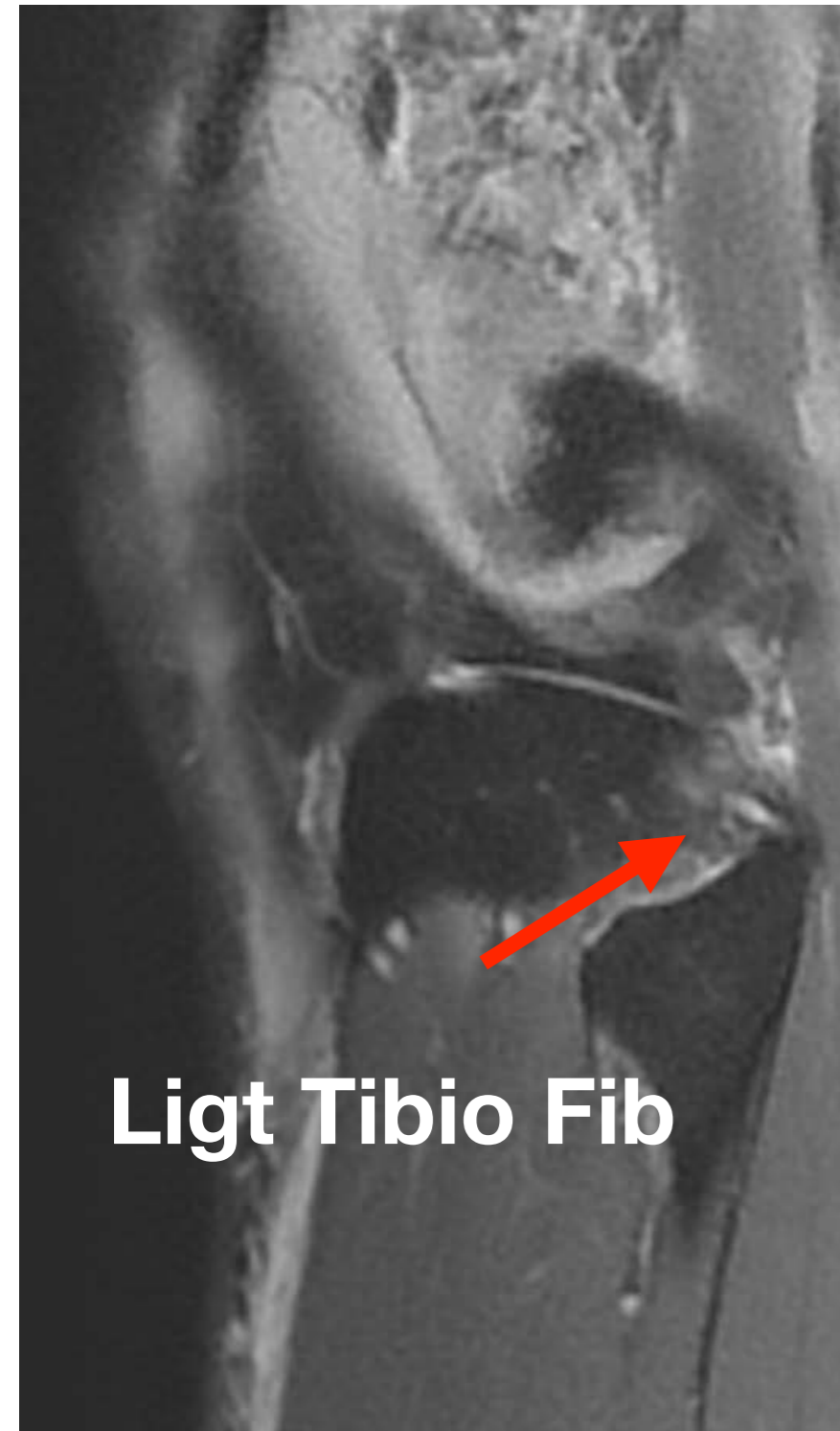



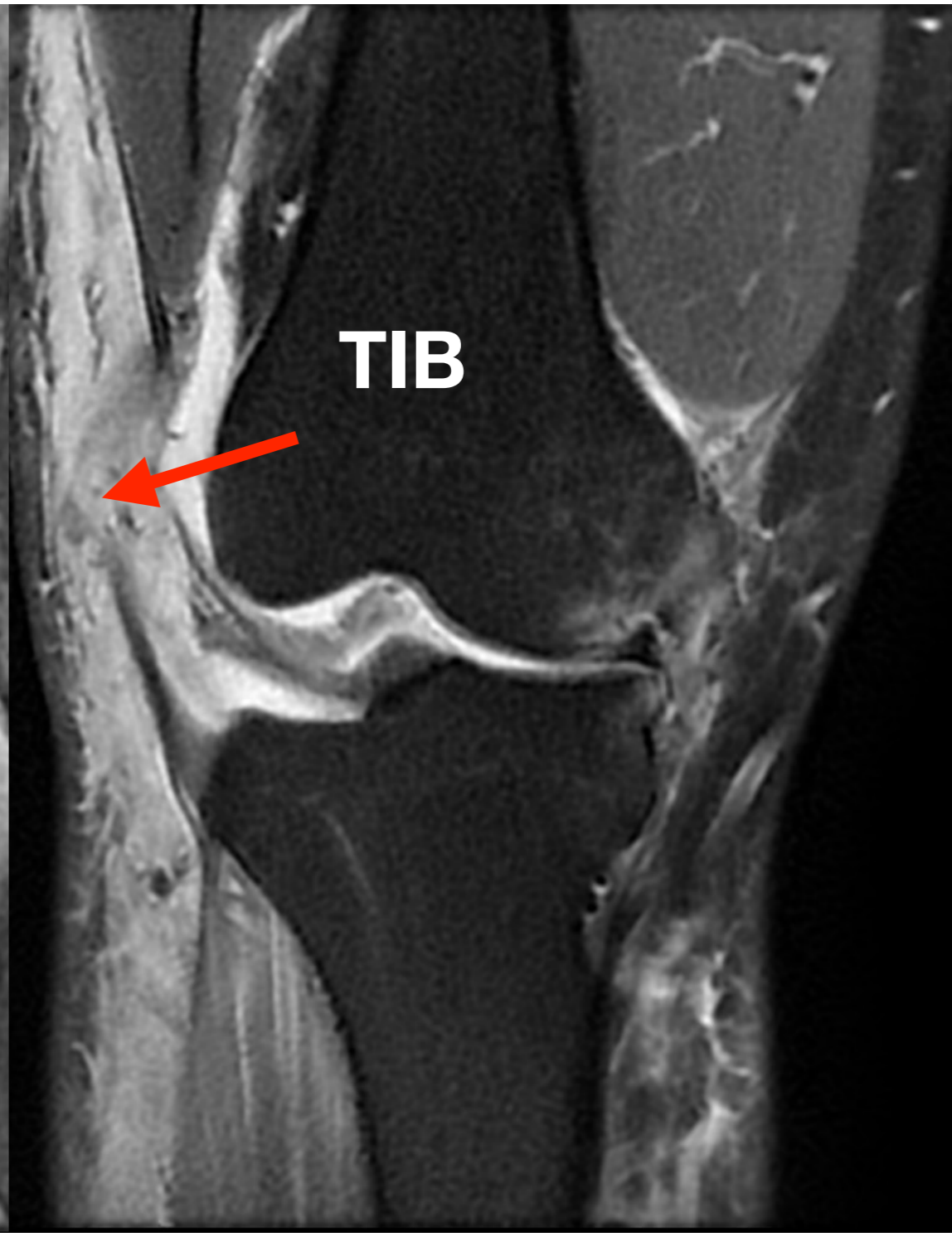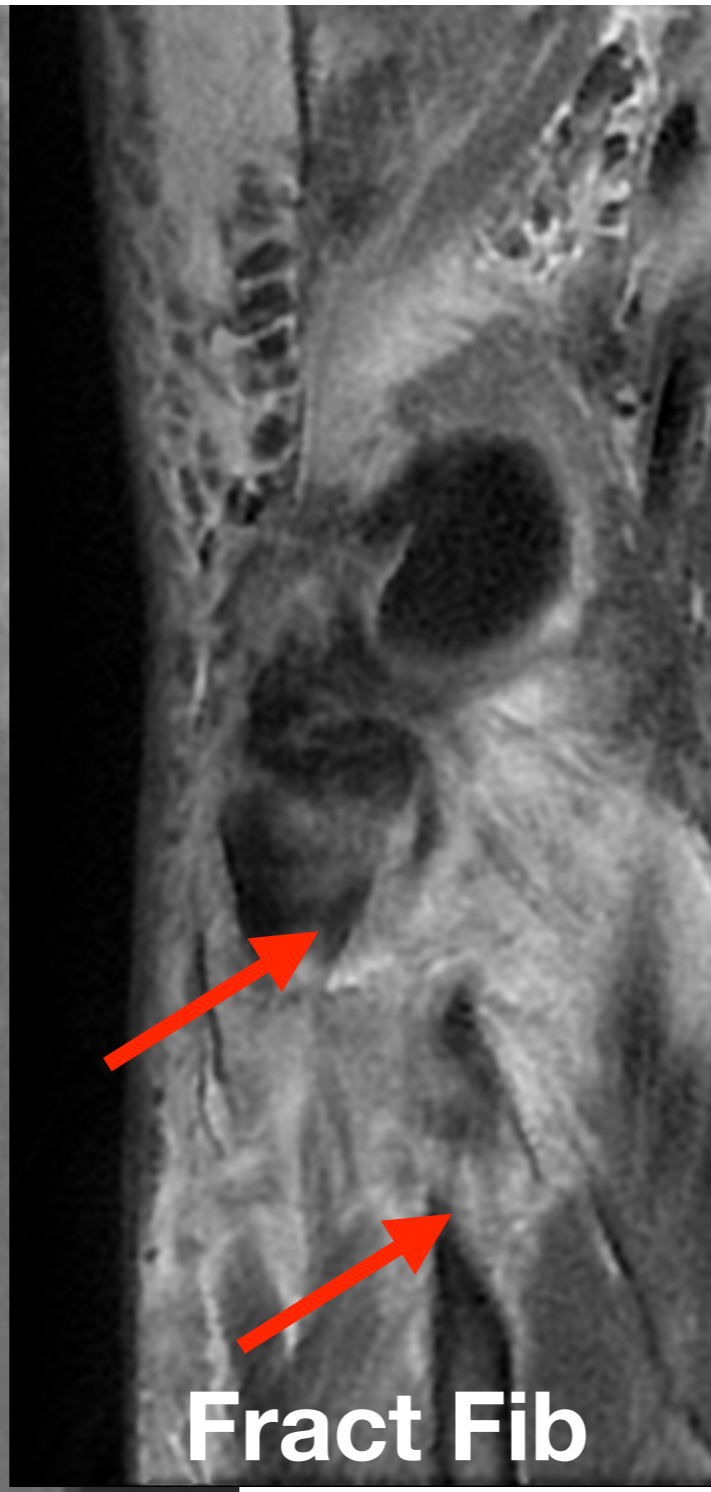
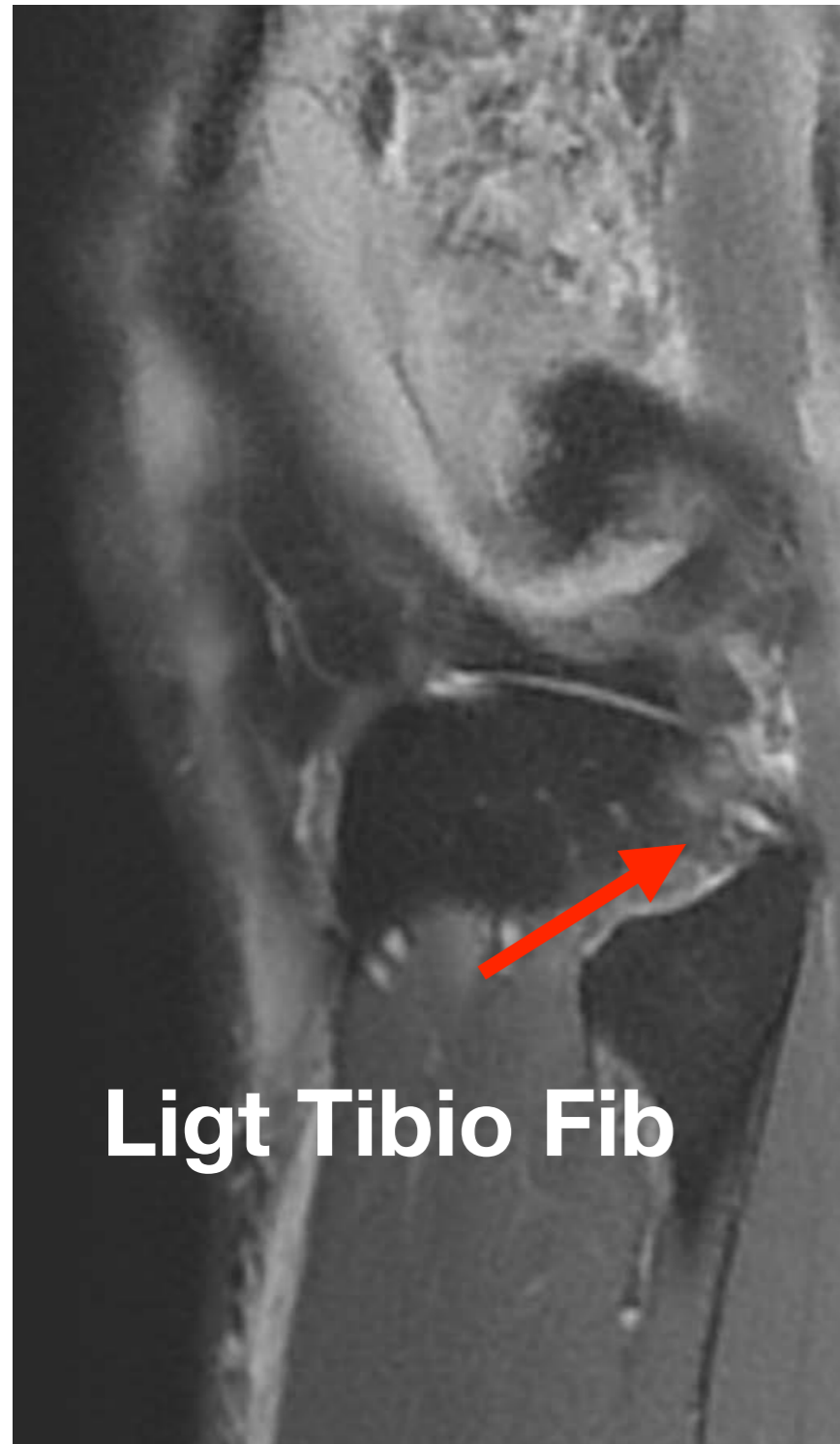## 3. Autres



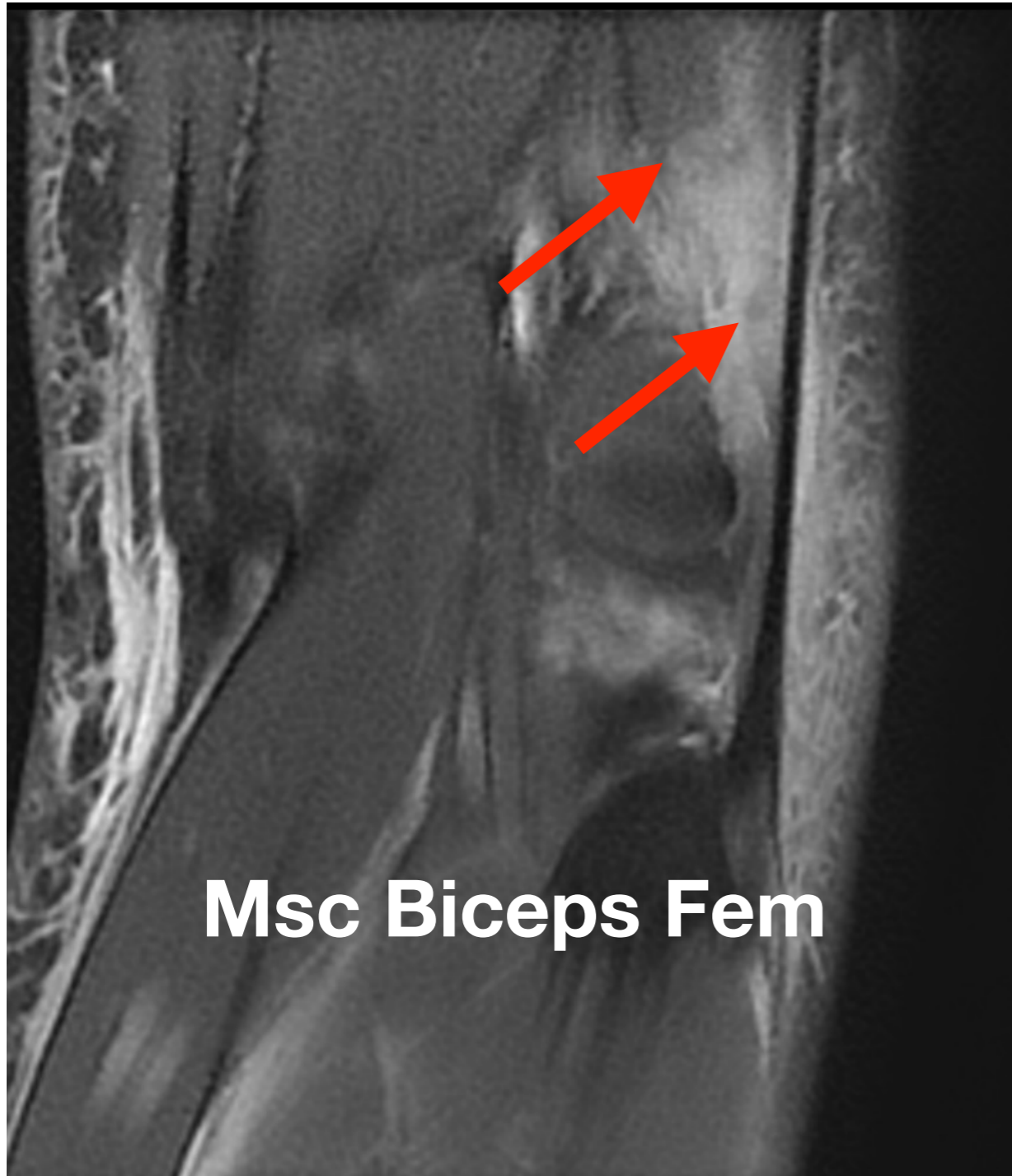
### 3. Autres



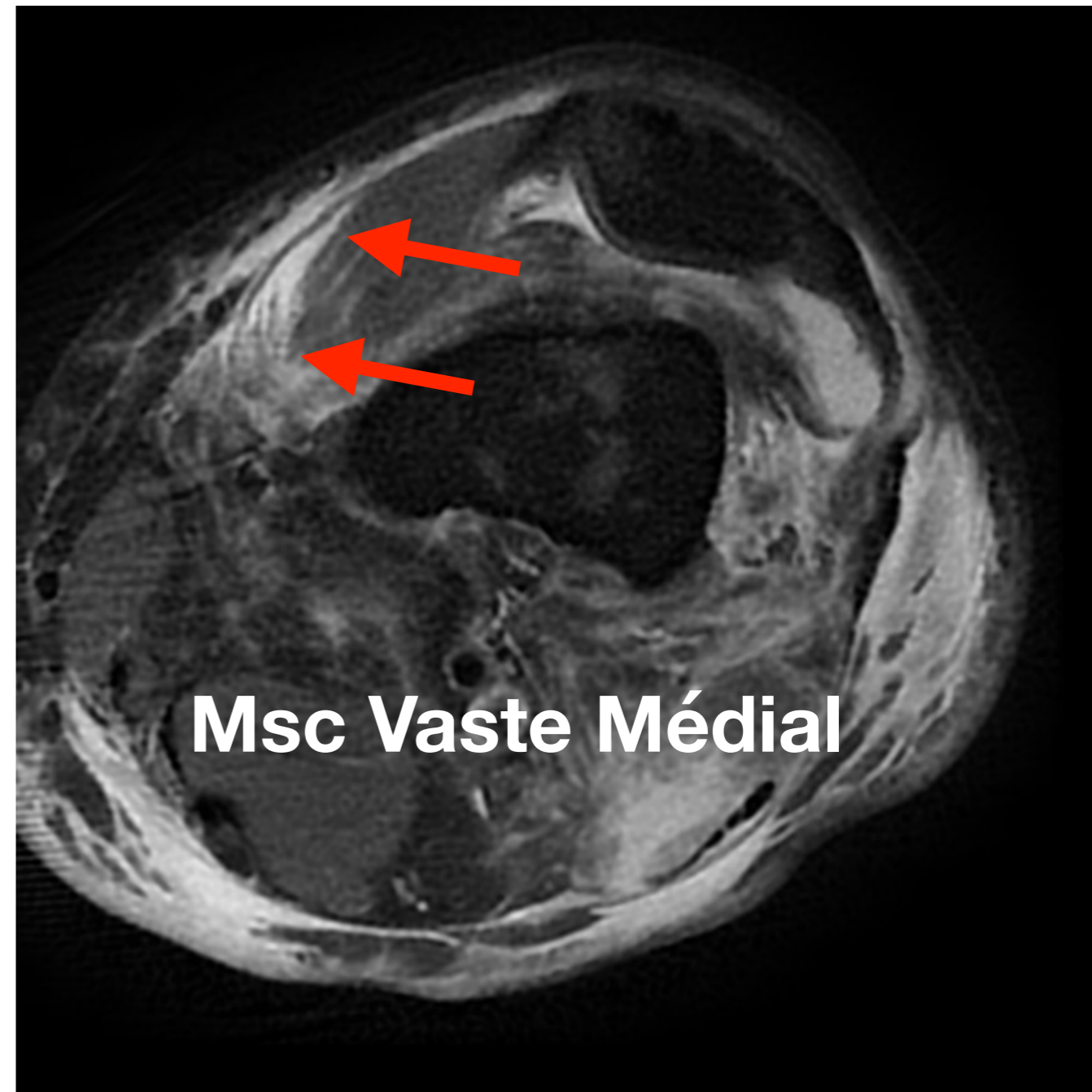
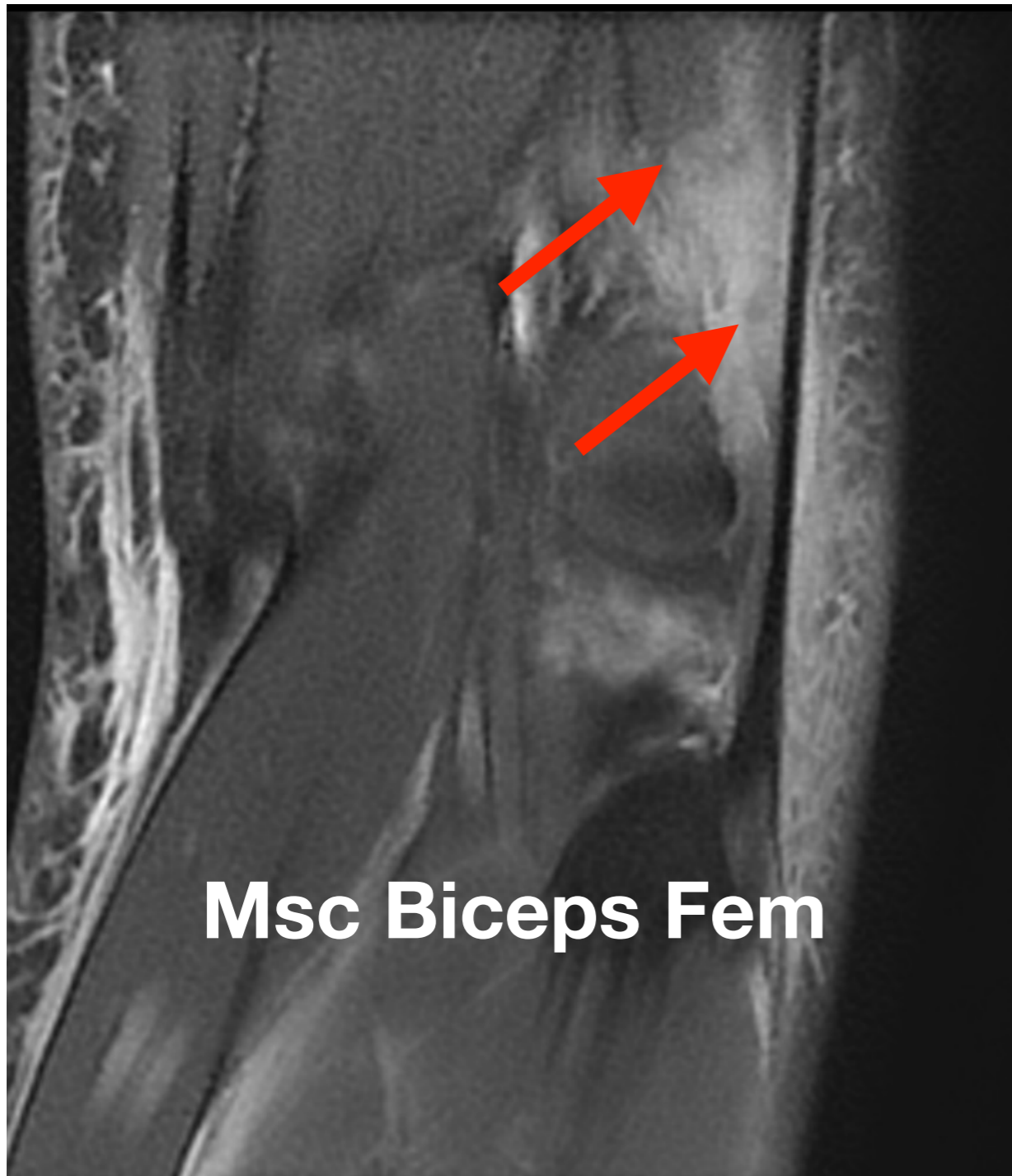
### 3. Autres



### 3. Autres : Muscles



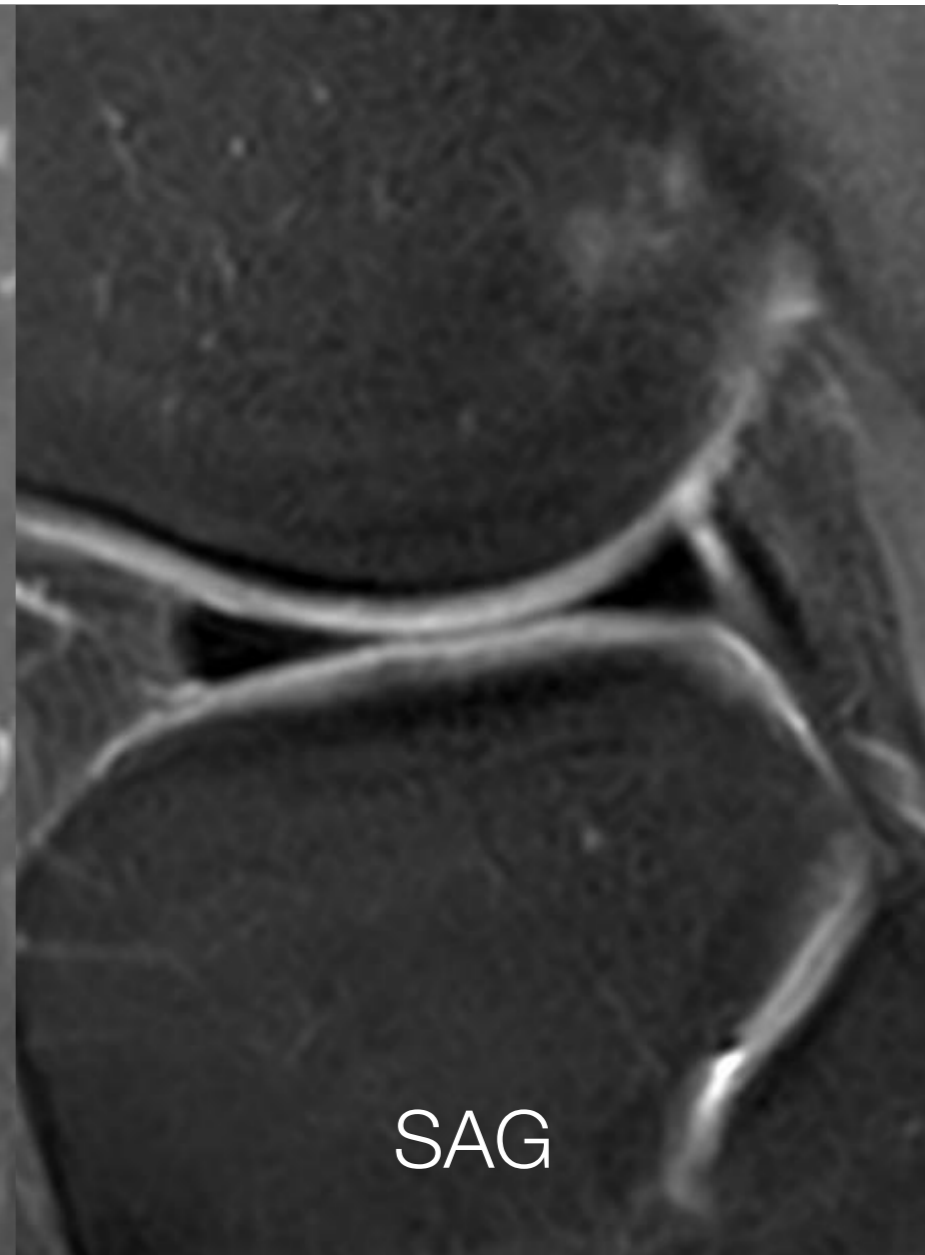
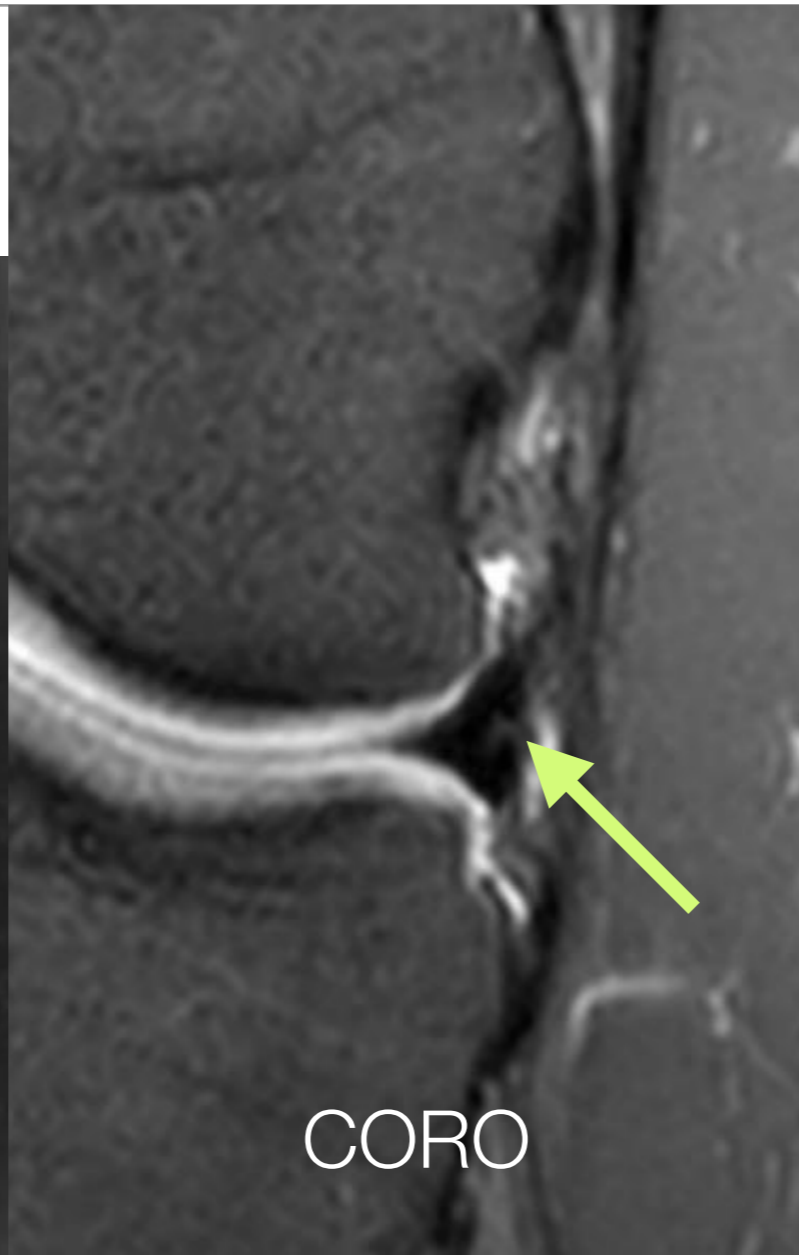
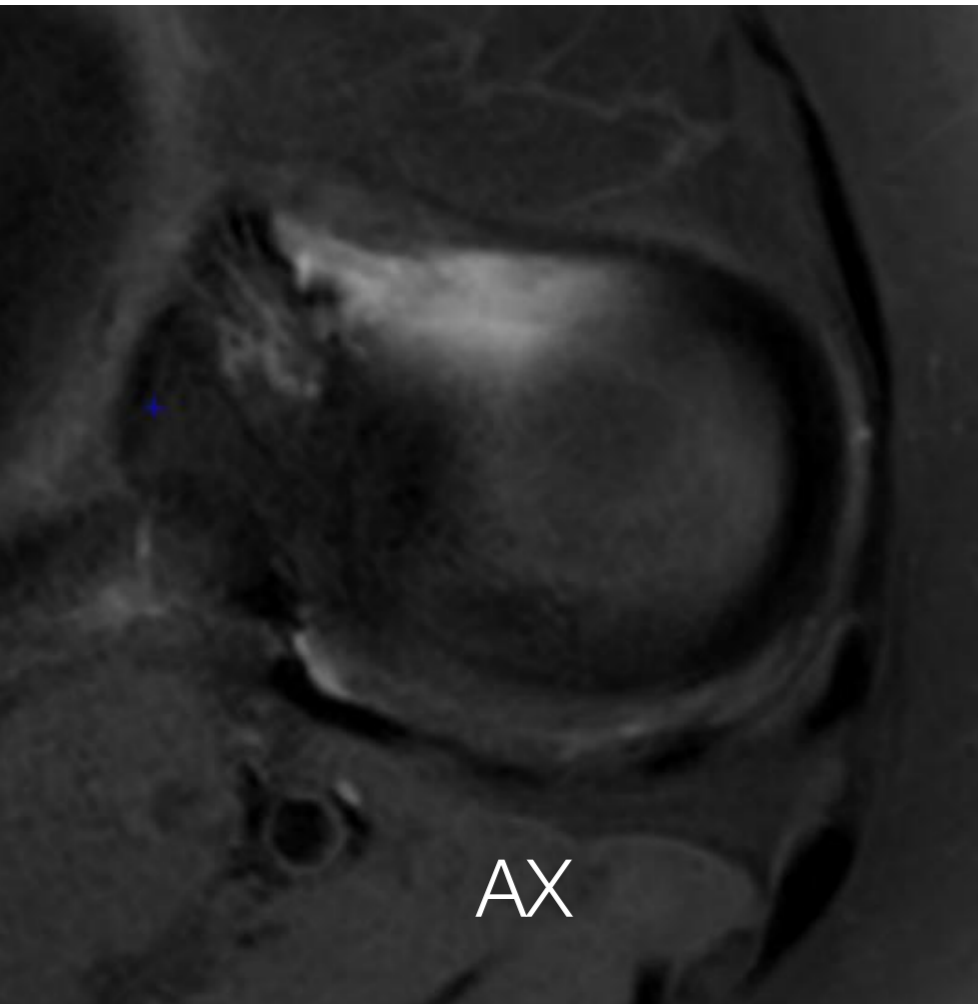
### 3. Autres : Muscles



# 4. Ménisques

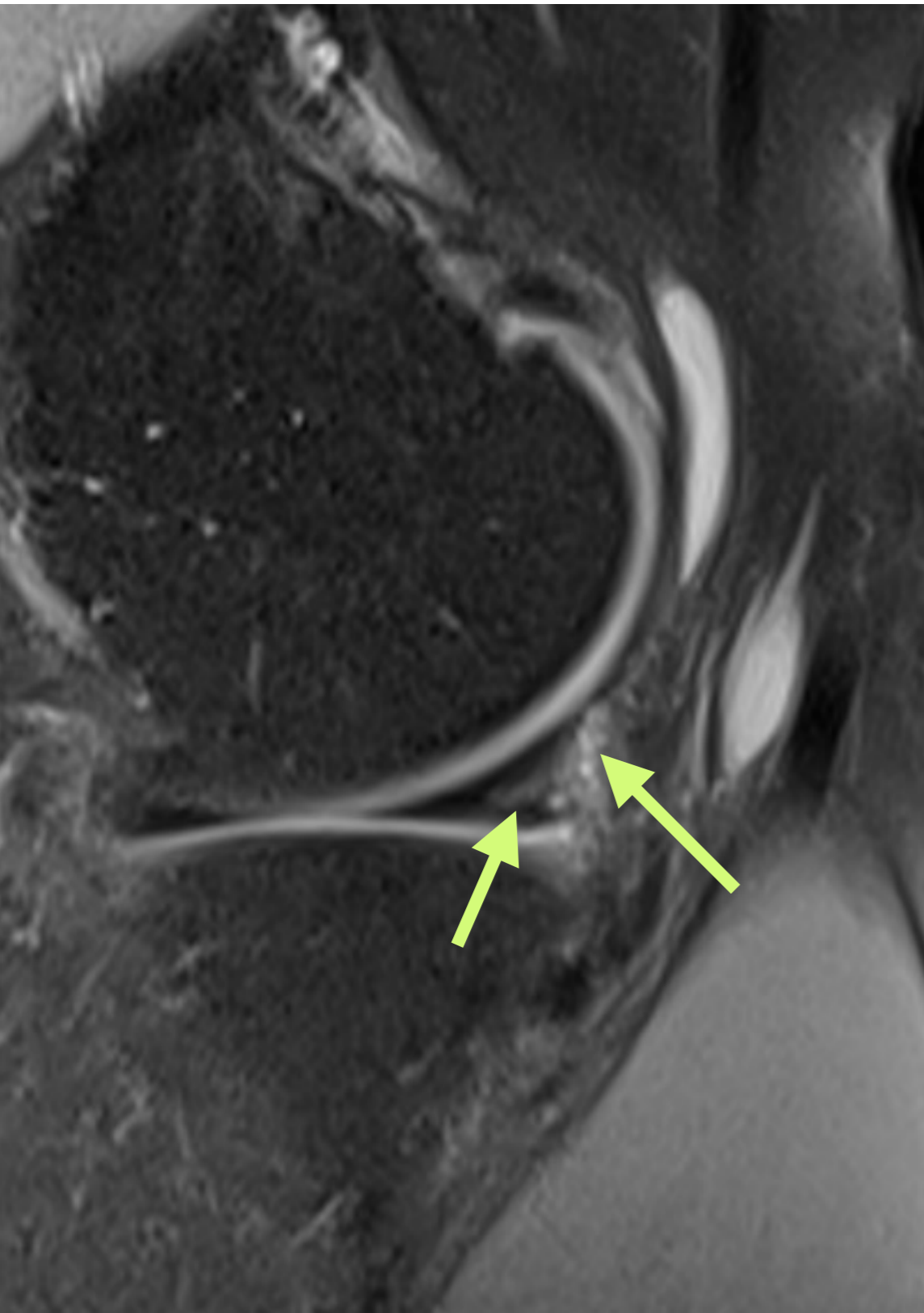
## 4. Ménisques

- Aspect normal



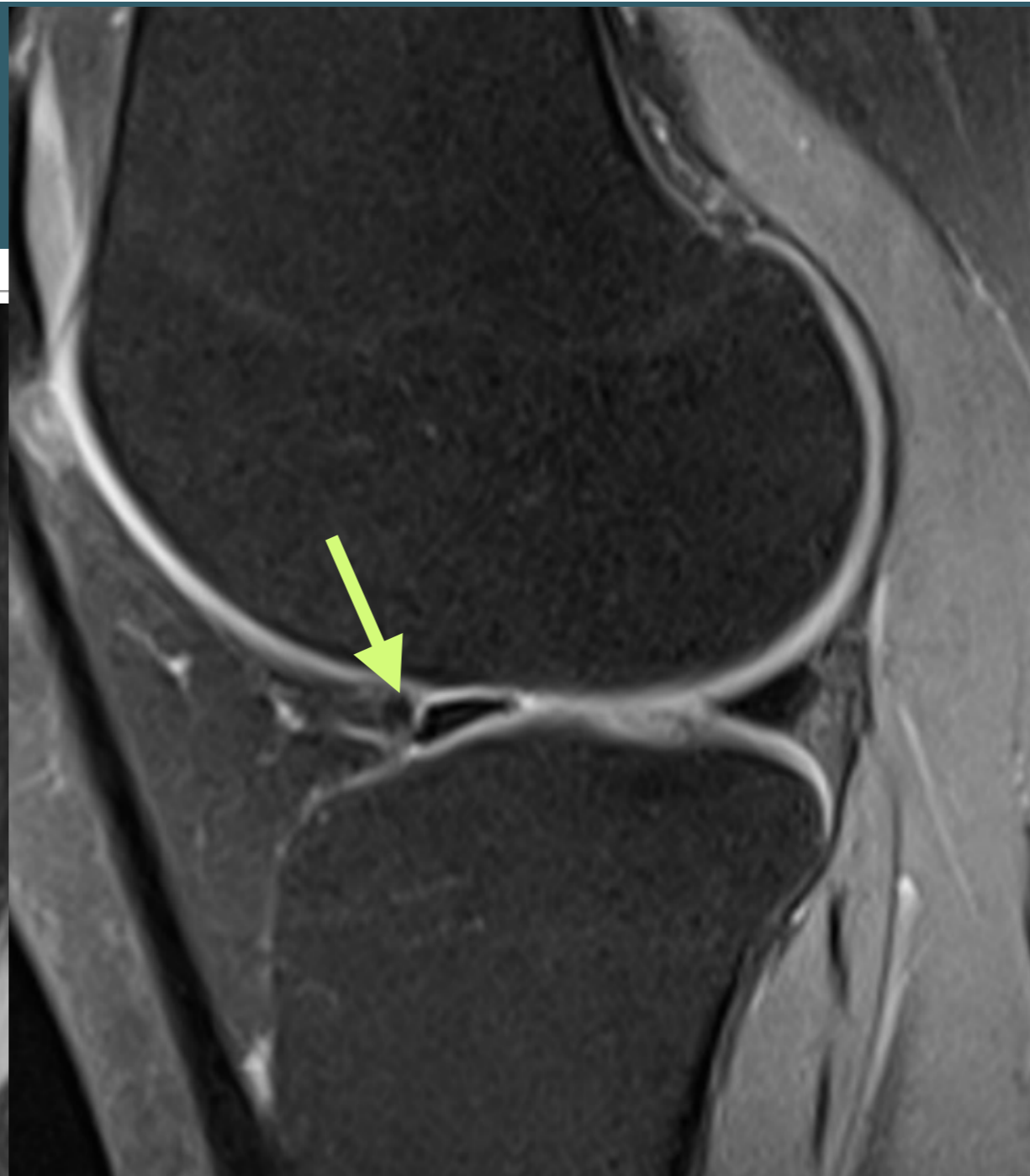
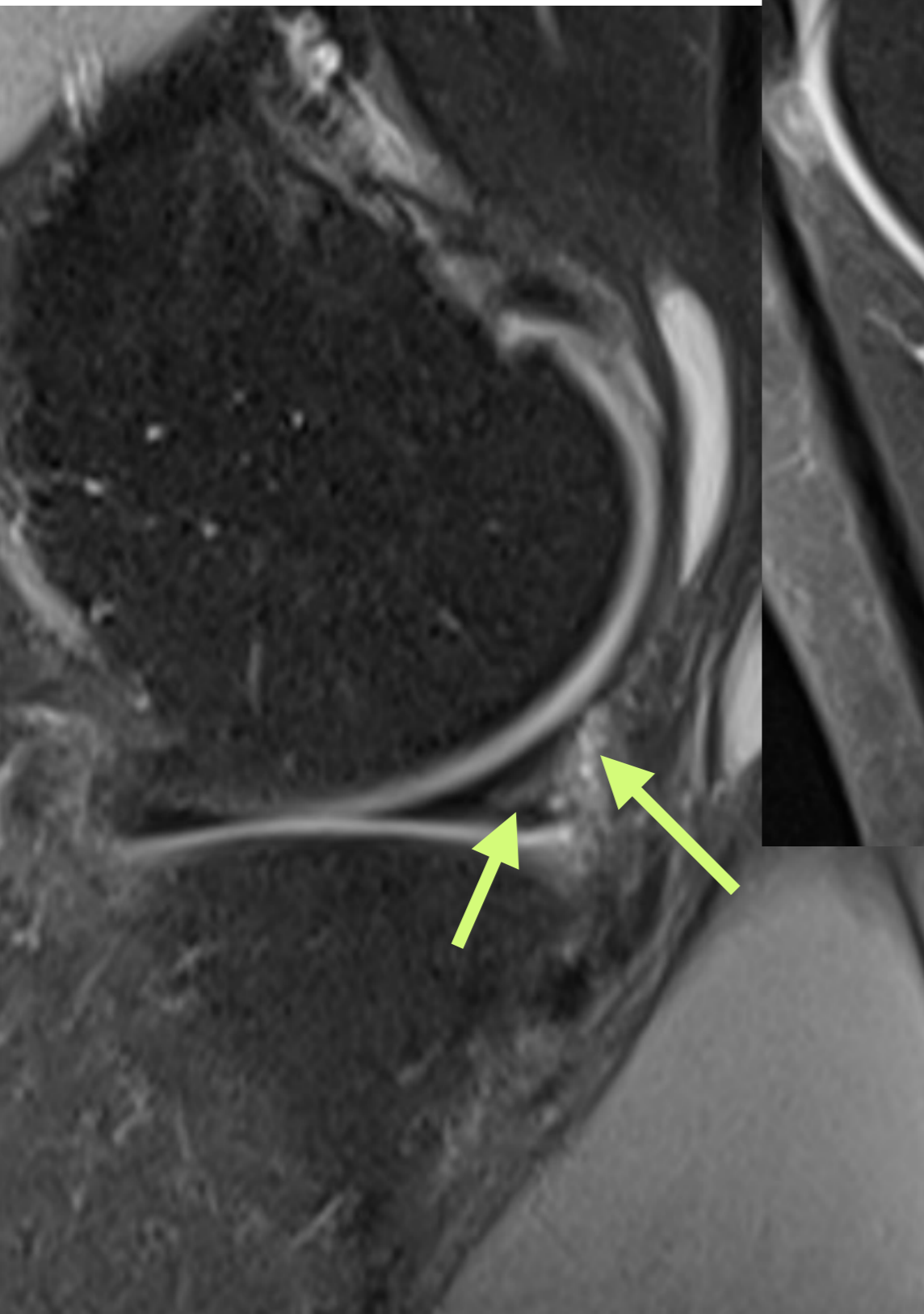
Ménisque latéral

## 4. Ménisques

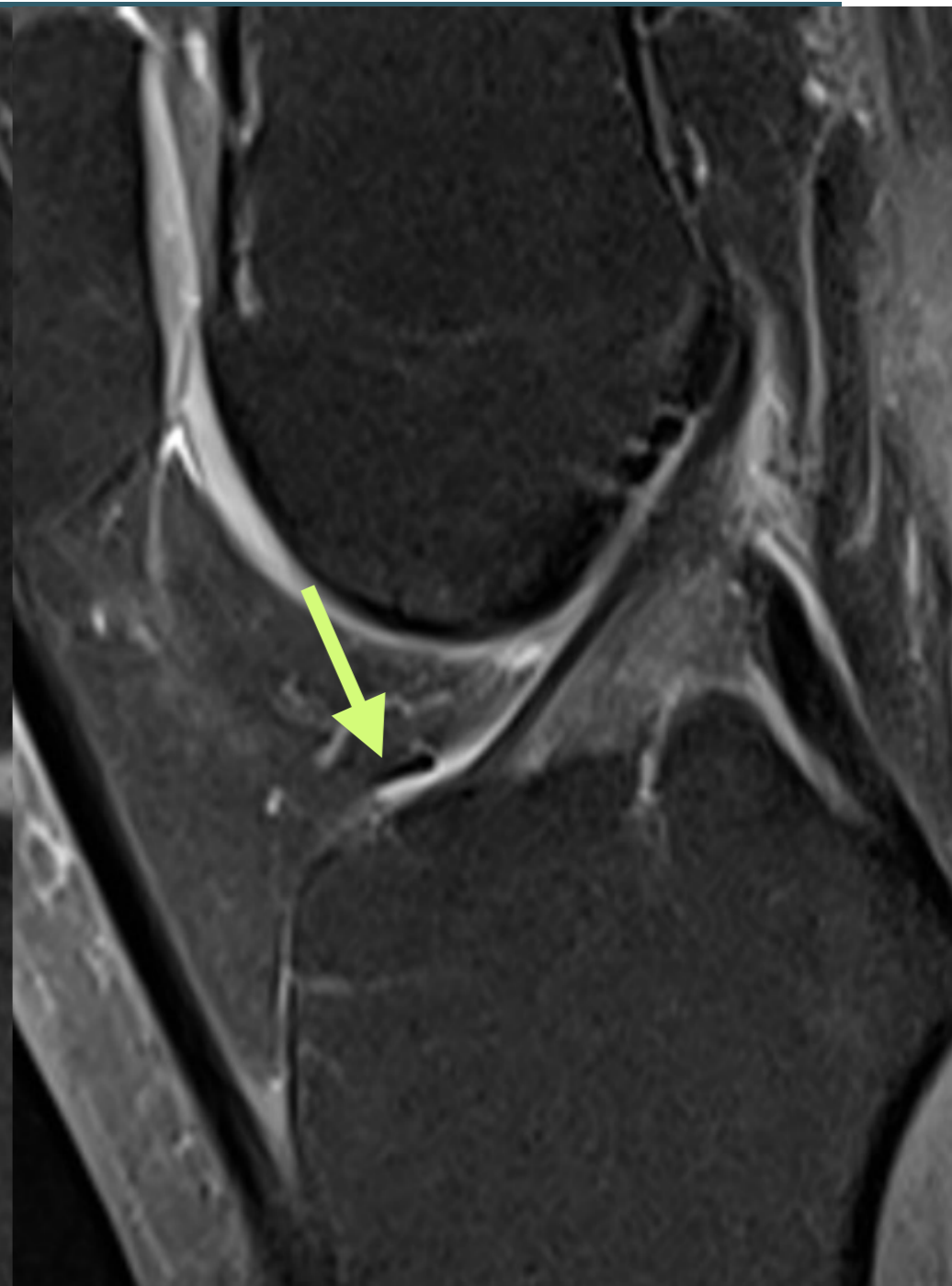
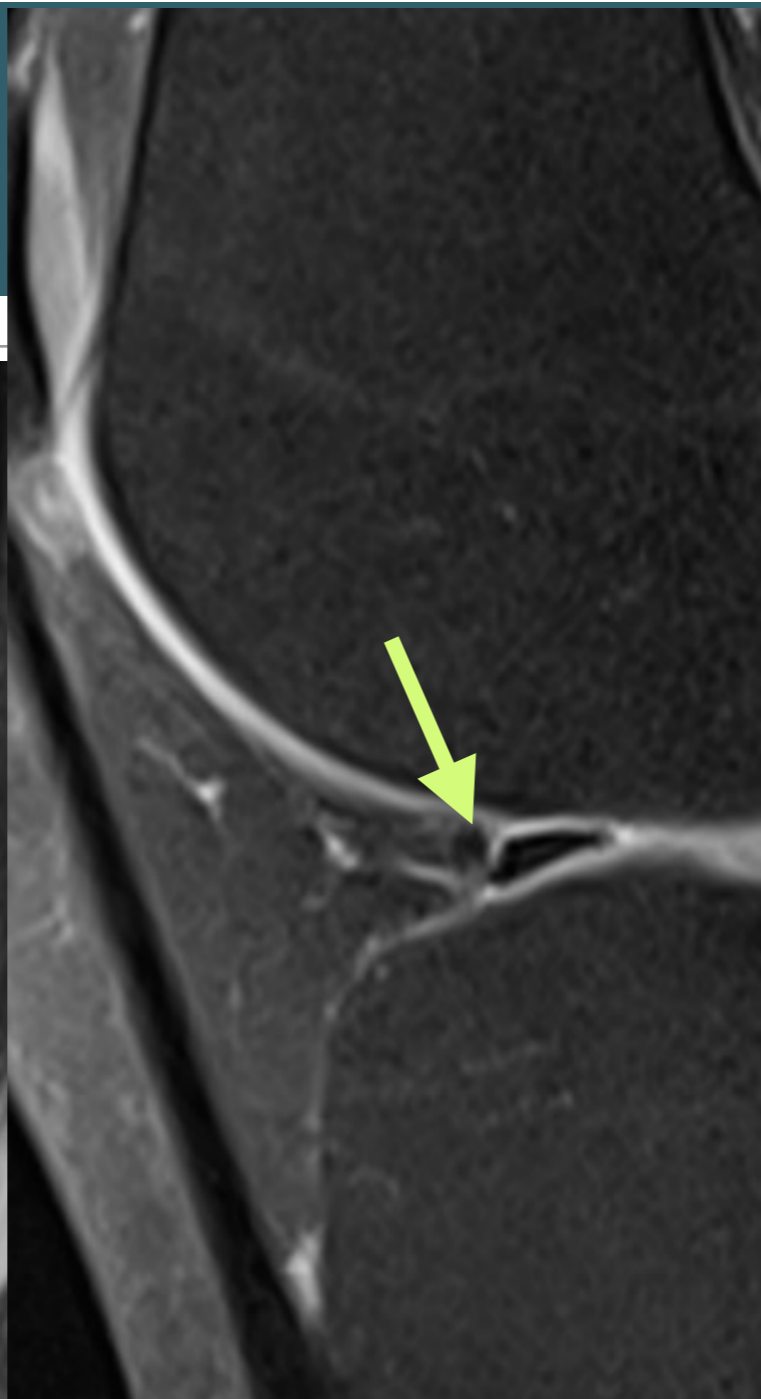
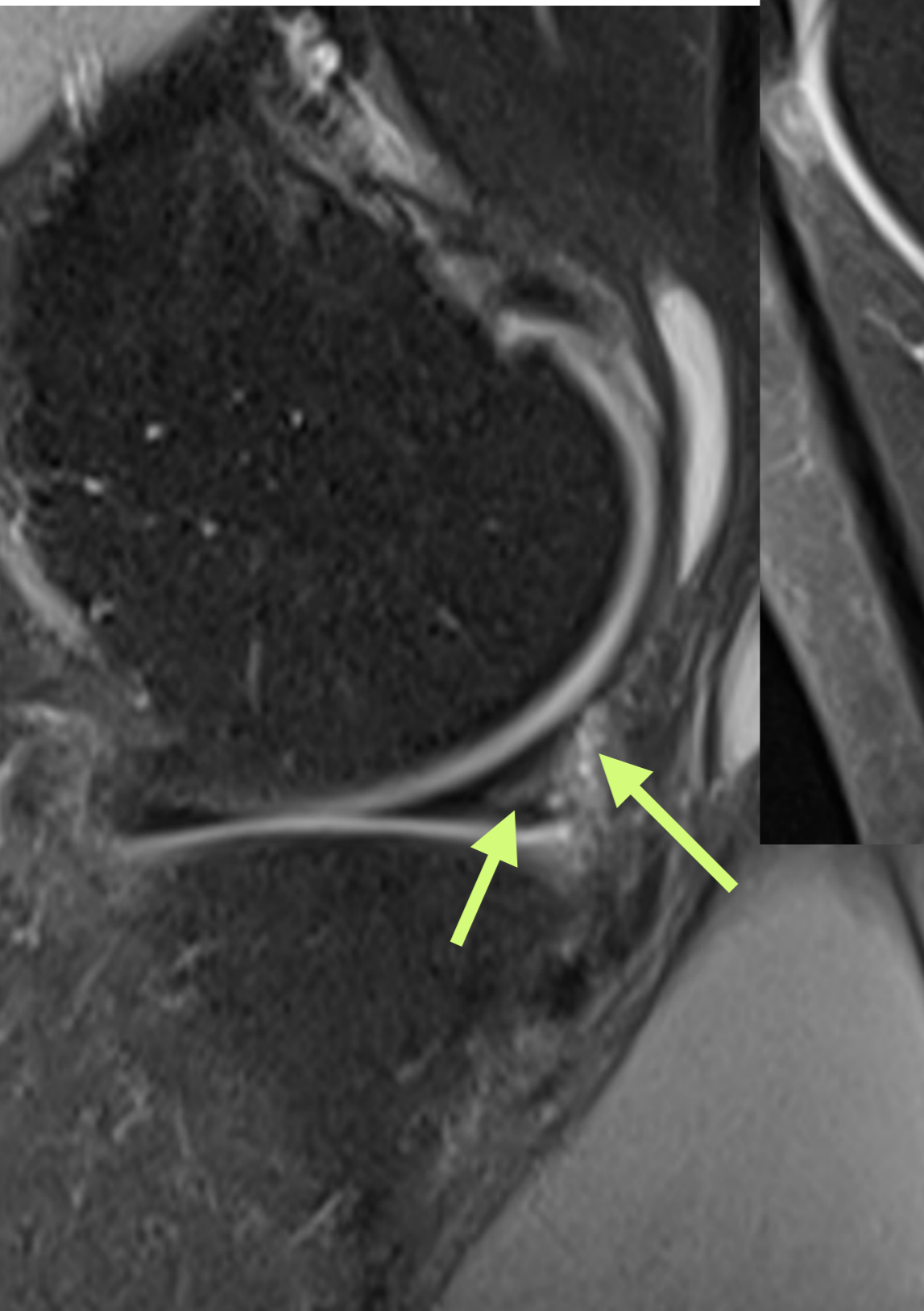




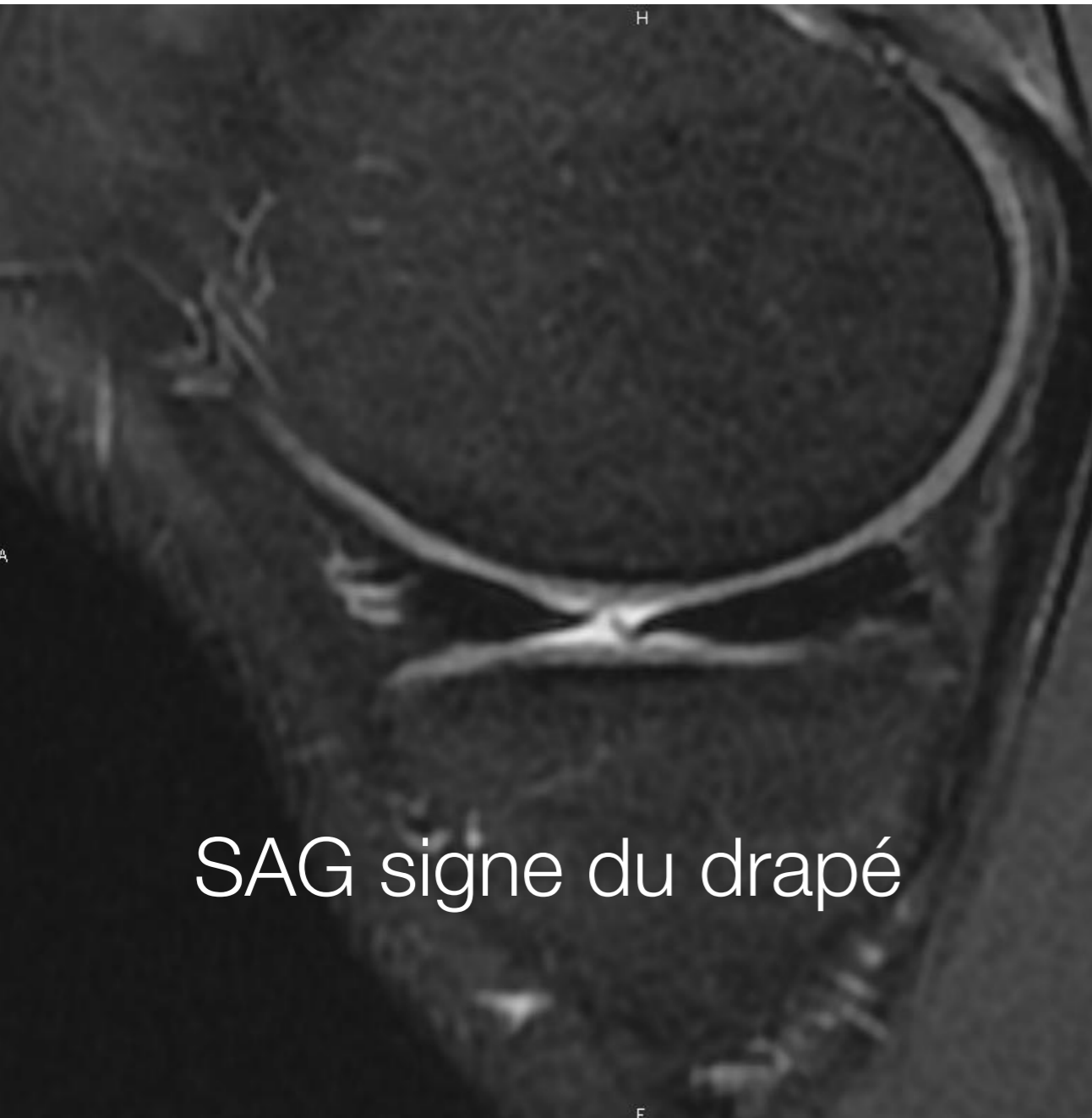
## 4. Ménisques



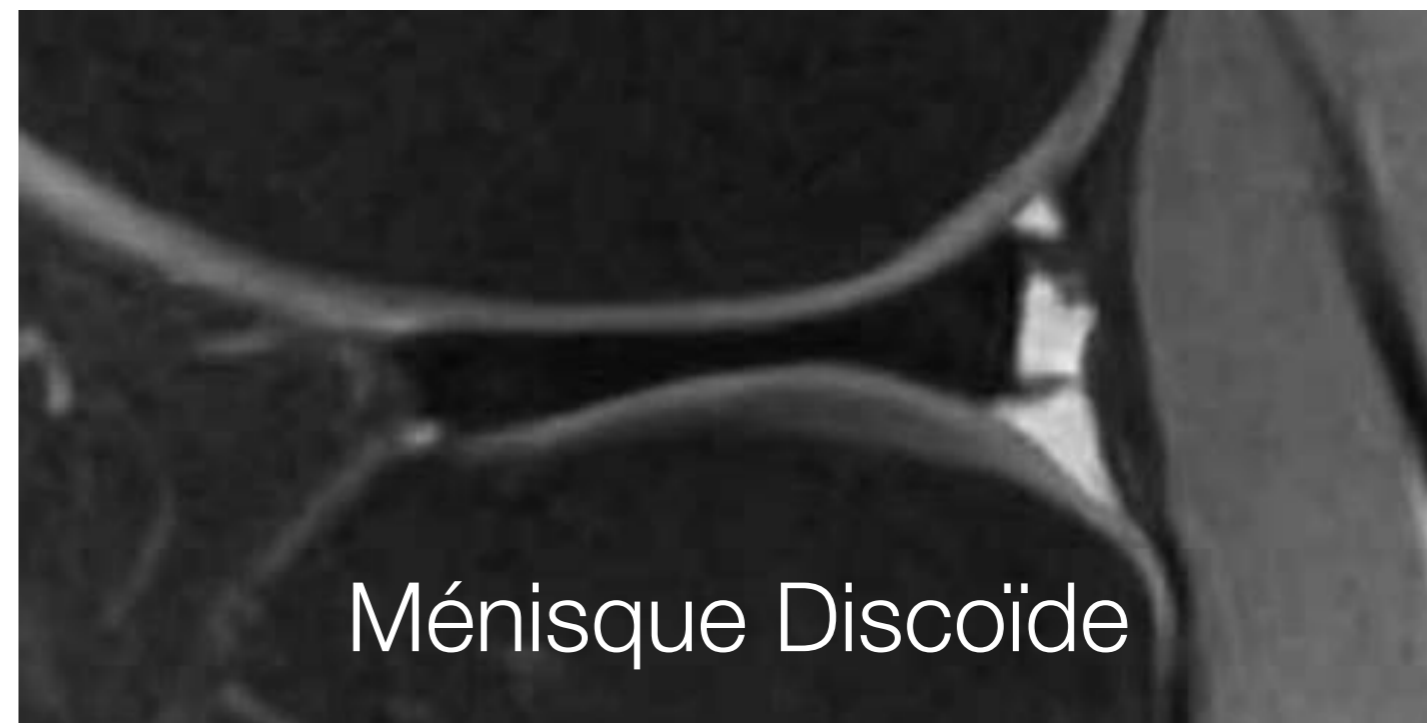
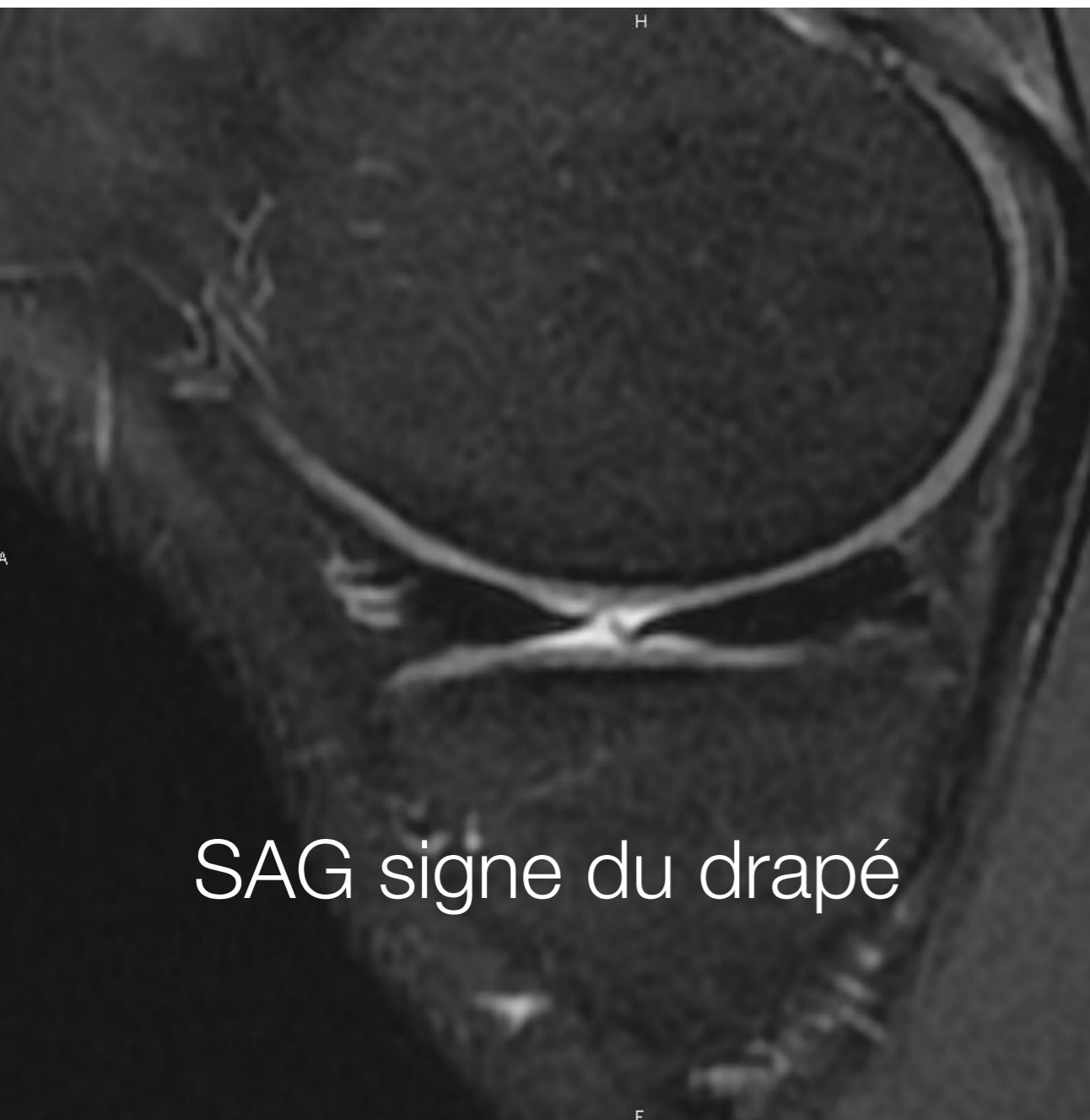
## 4. Ménisques



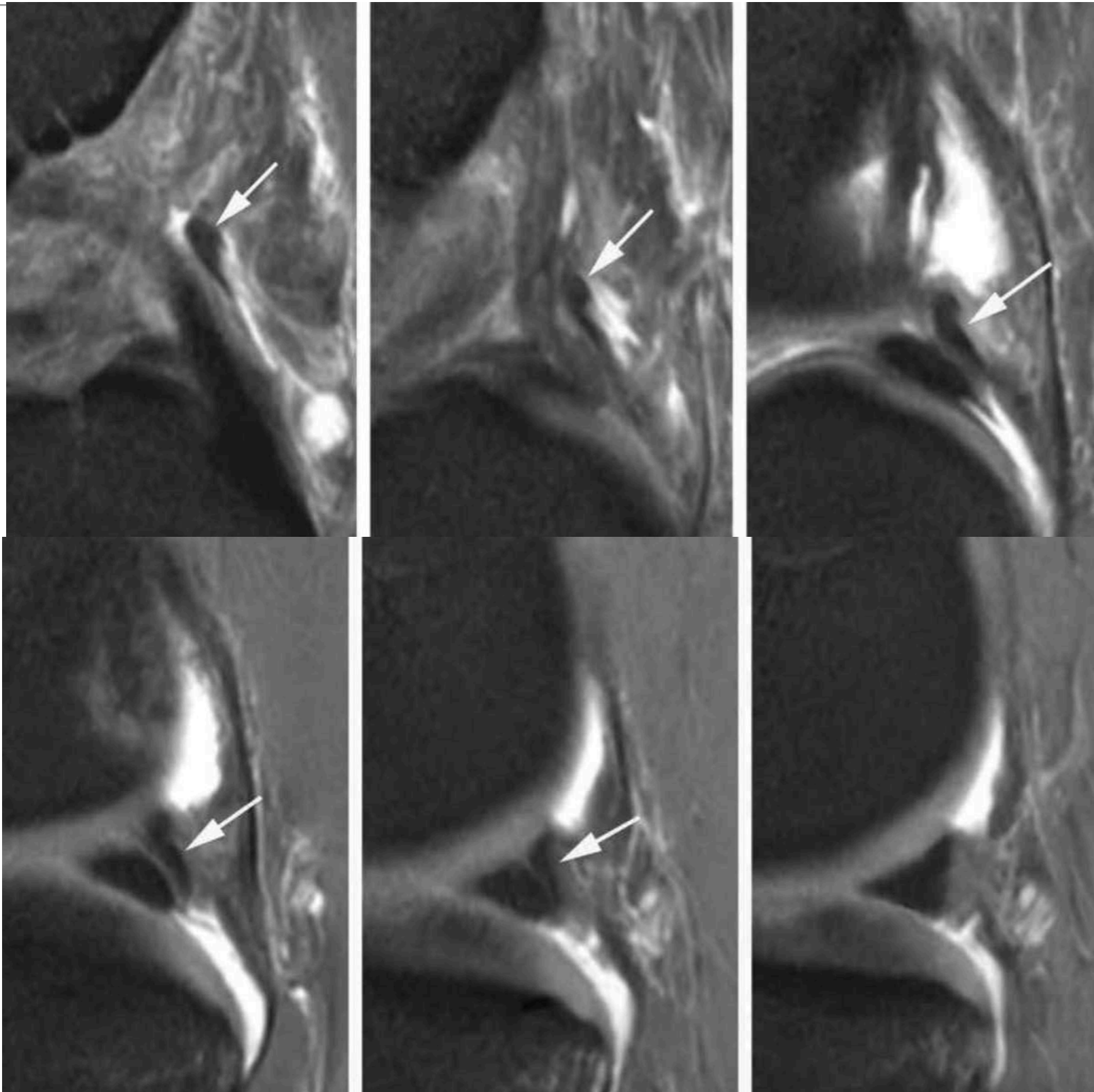
# 4. Ménisques



## 4. Ménisques



## 4. Ménisques

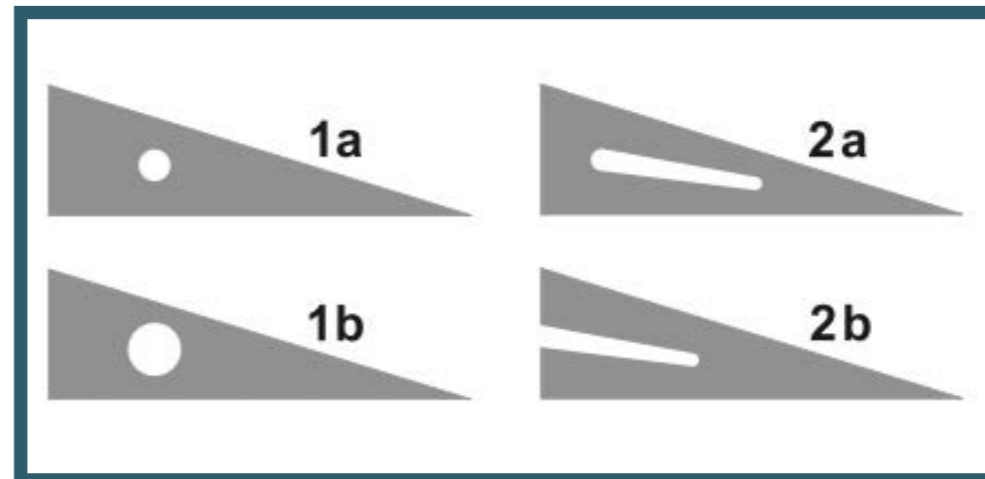


Ligt ménisco-fémoral  
postéro-latéral

Humphrey  
Wrisberg

# 4. Ménisques Fissures

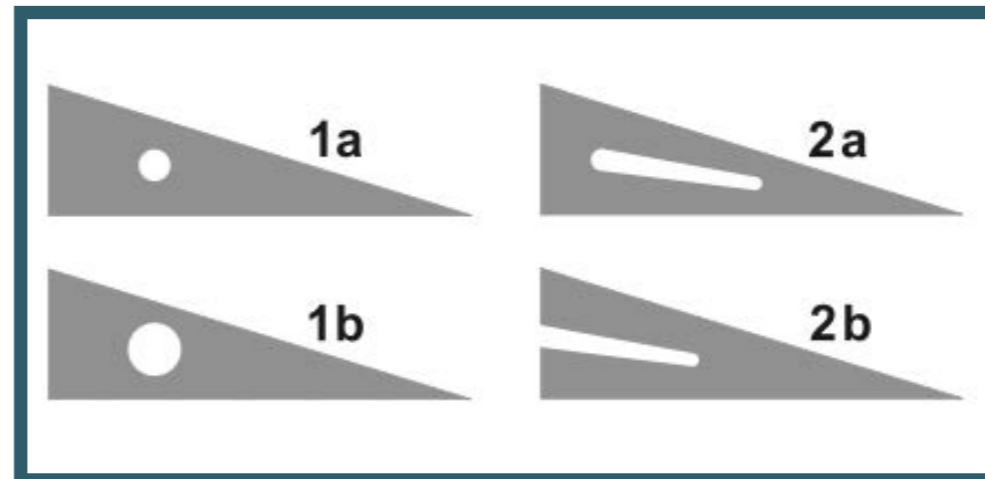
**Grade 1 et 2**  
Méniscopathie non fissuraire



# 4. Ménisques Fissures

## Grade 1 et 2

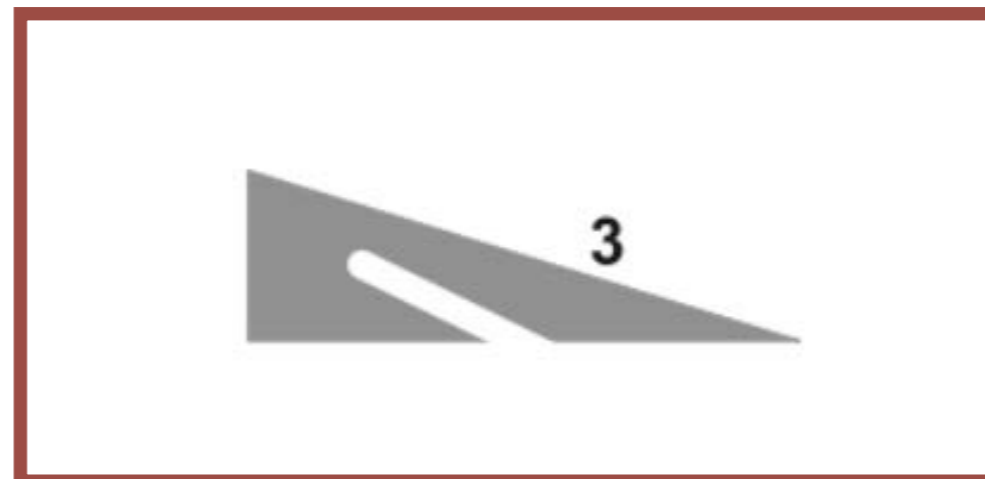
Méniscopathie non fissuraire



## Grade 3

Méniscopathie fissuraire

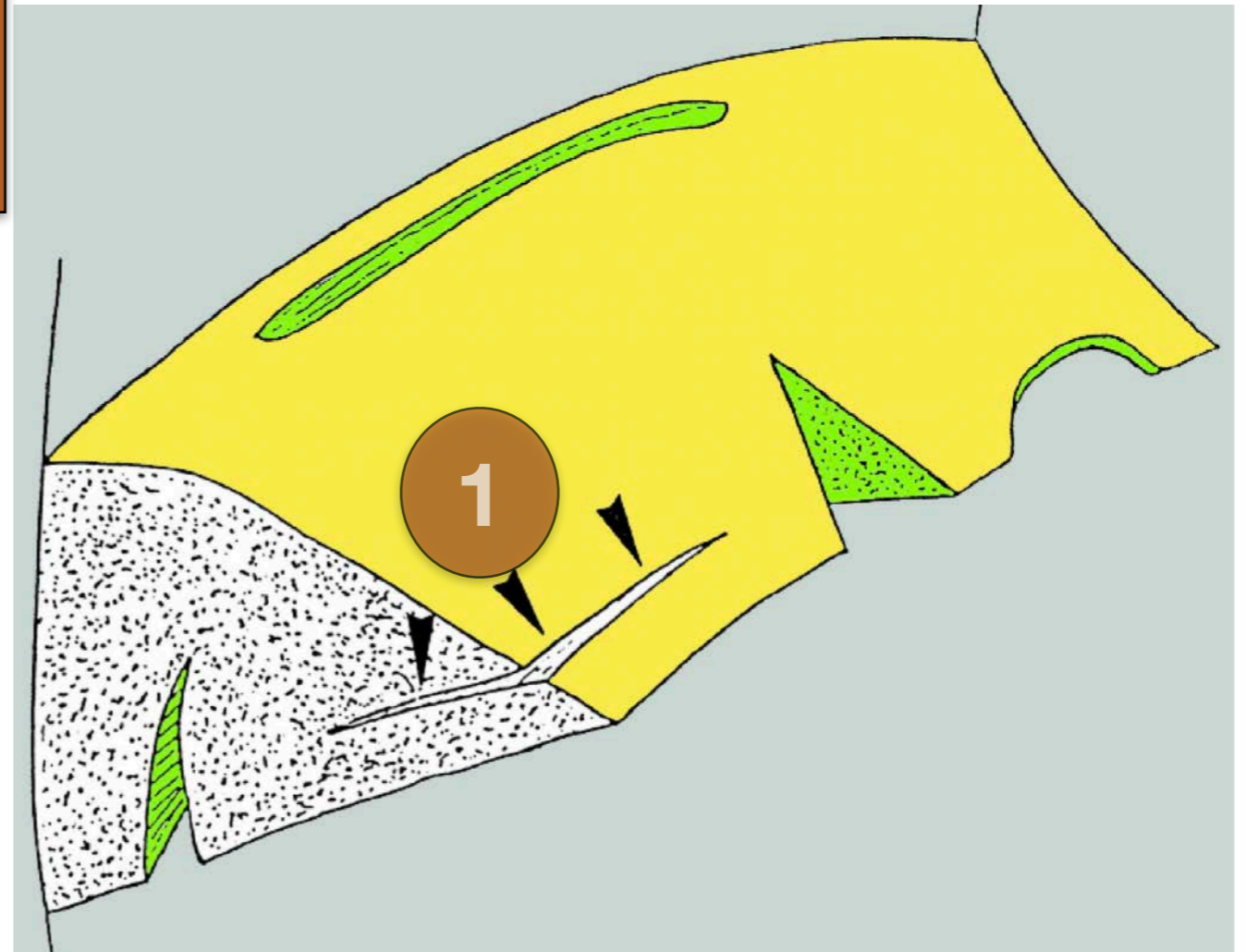
HYPER DP sur au moins 2 coupes



# 4. Ménisques Fissures

AXIALE

1 Longitudinale



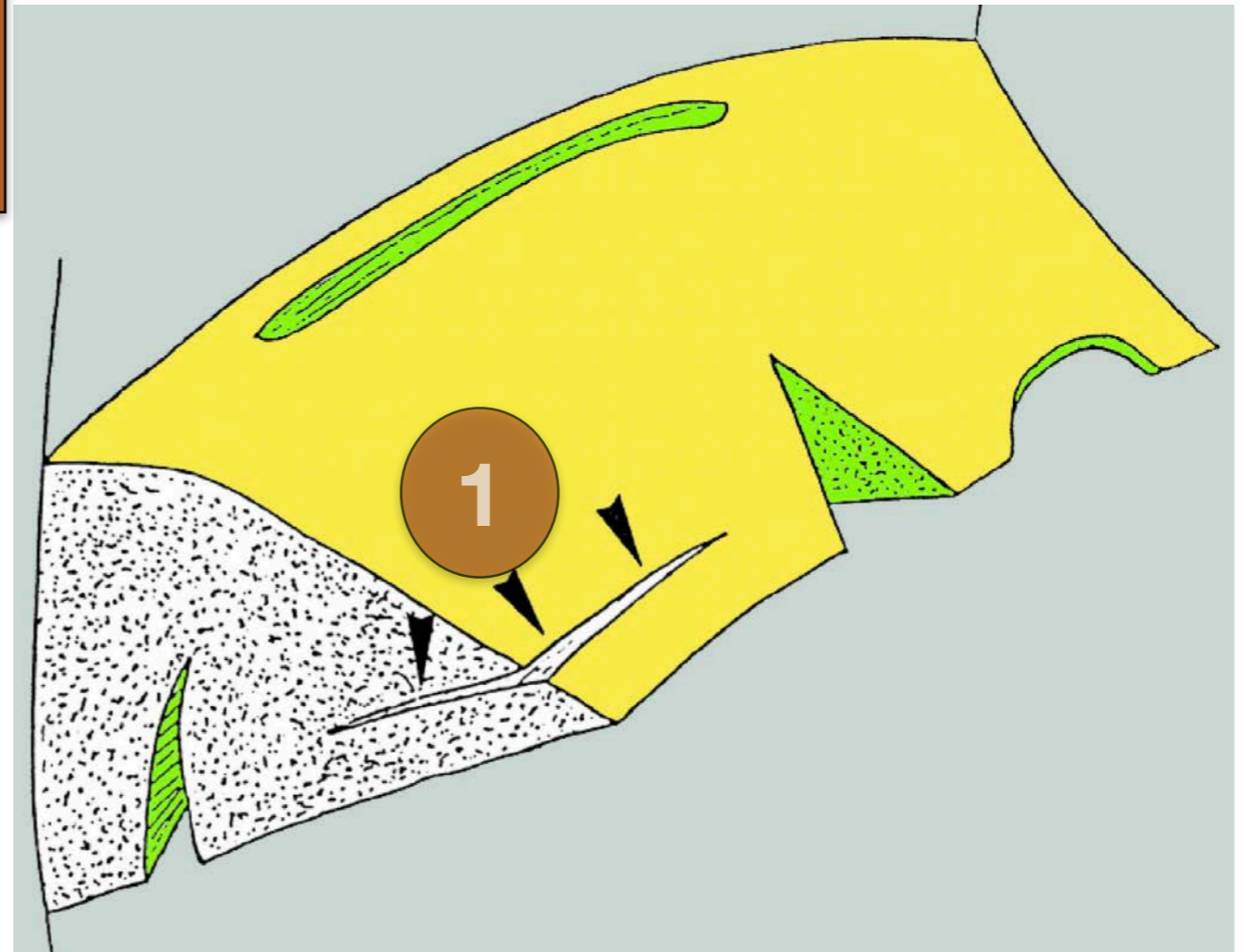


# 4. Ménisques Fissures

AXIALE

1 Longitudinale

VERTICALE



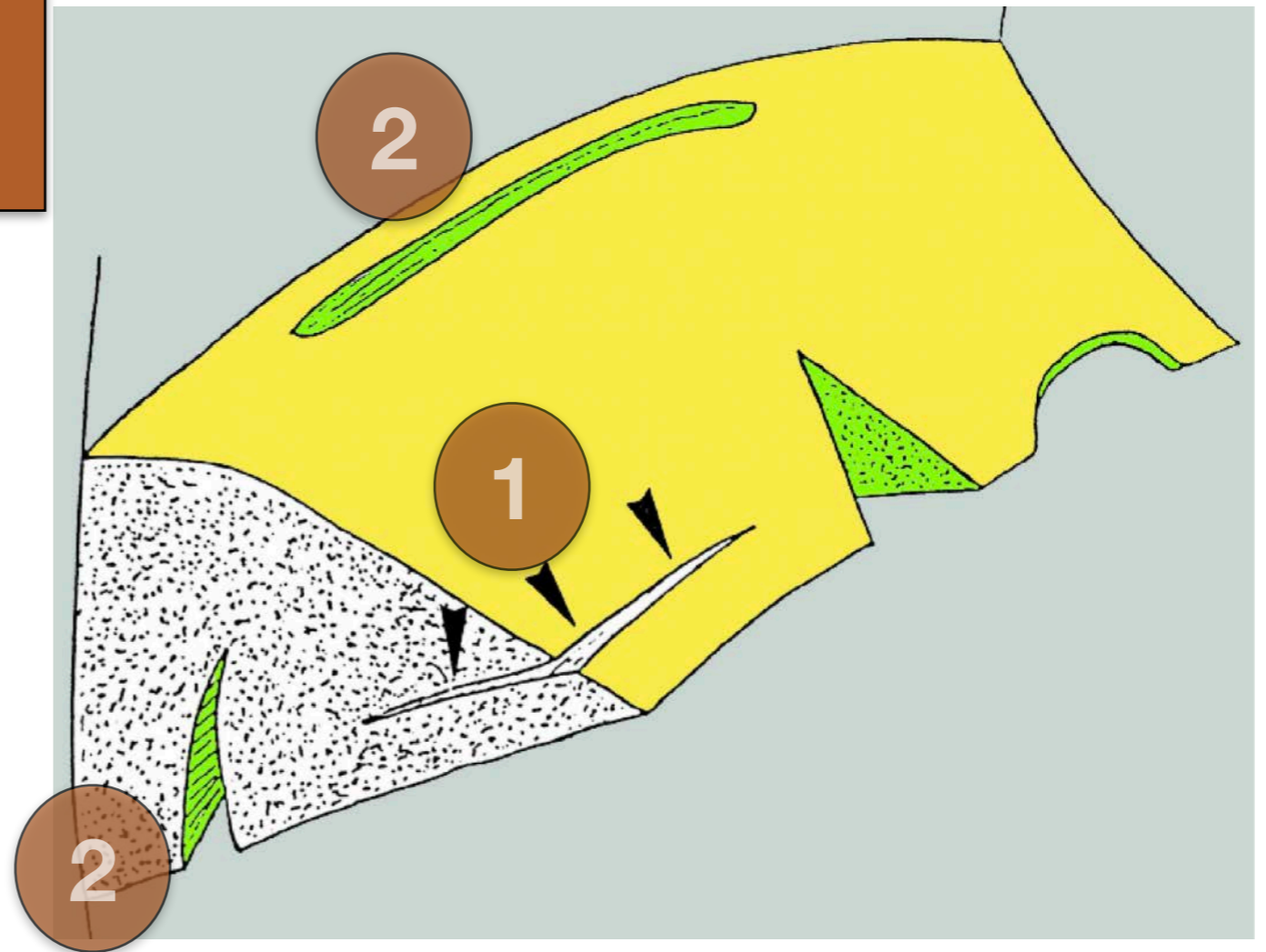
# 4. Ménisques Fissures

AXIALE

1 Longitudinale

VERTICALE

2 Longitudinale



# 4. Ménisques Fissures

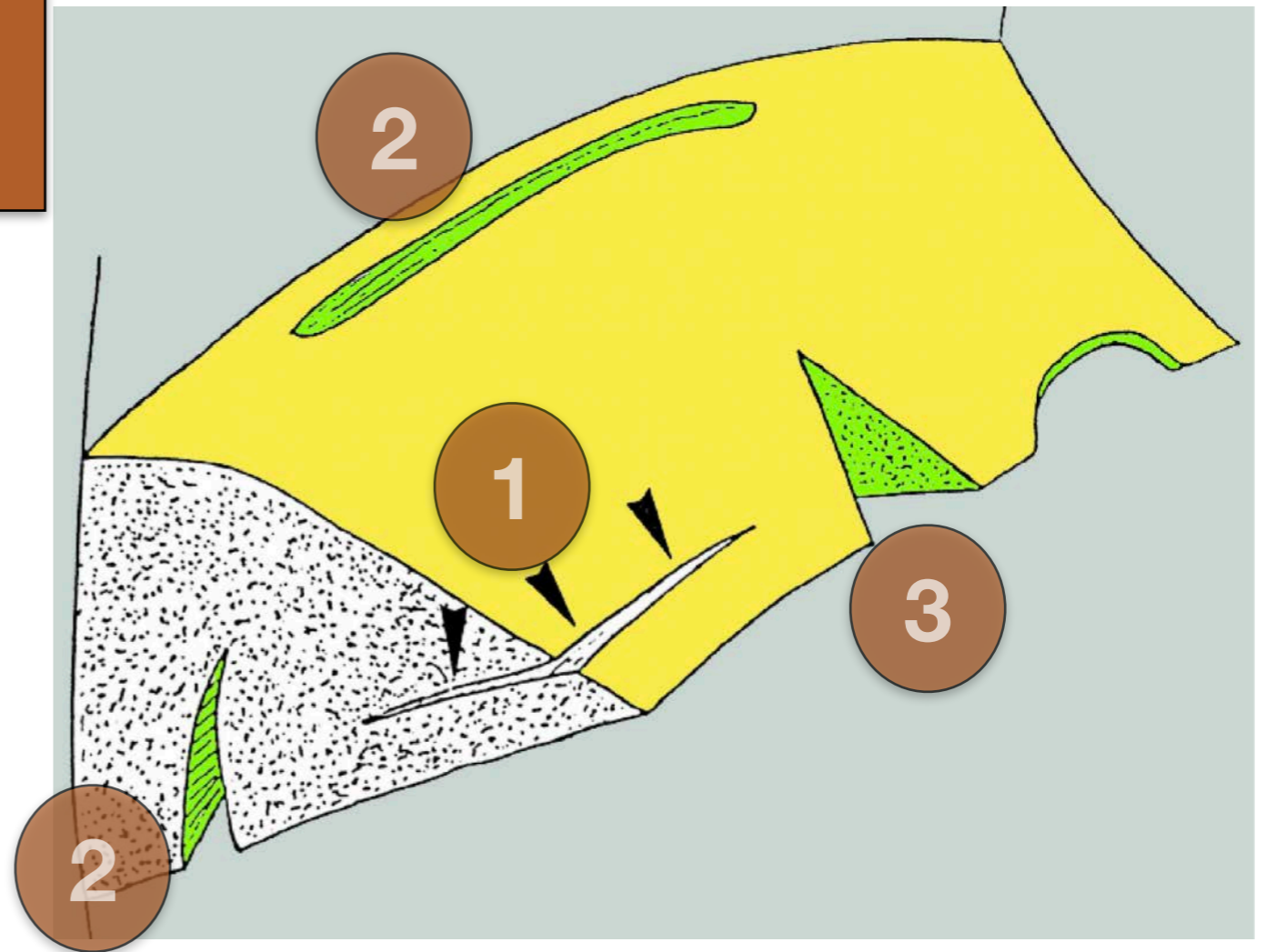
AXIALE

1 Longitudinale

VERTICALE

2 Longitudinale

3 Radiaire



# 4. Ménisques Fissures

AXIALE

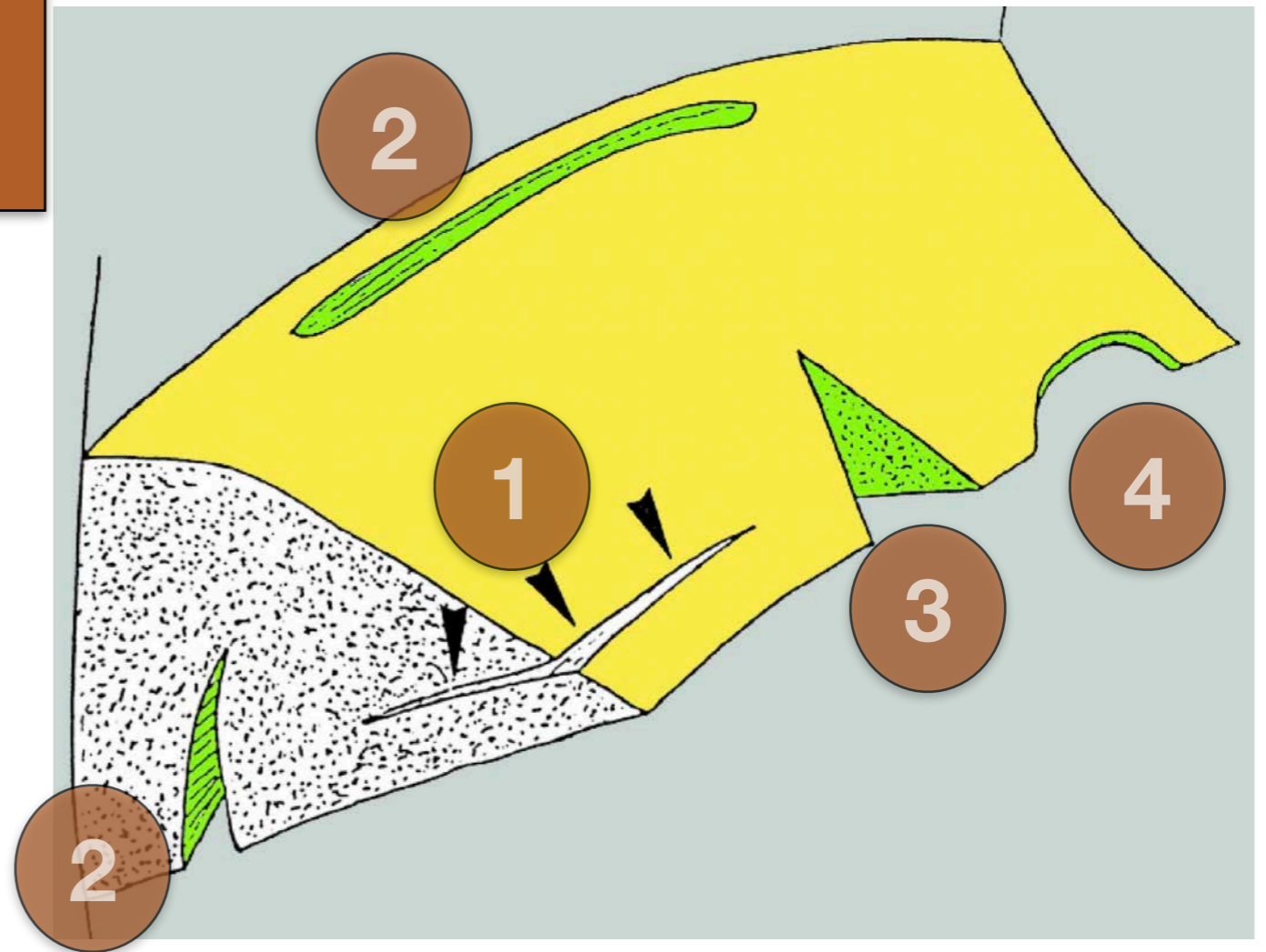
1 Longitudinale

VERTICALE

2 Longitudinale

3 Radiaire

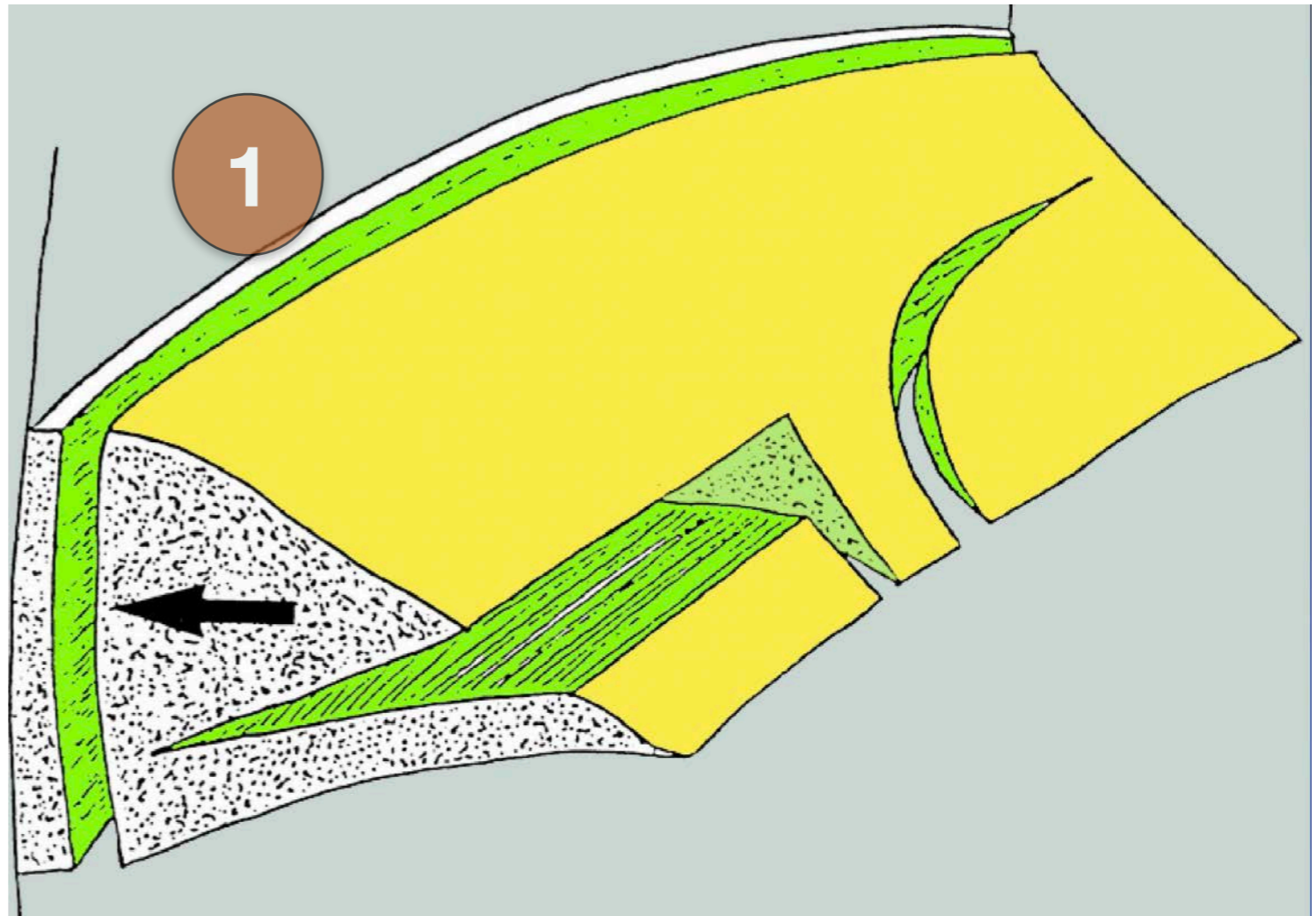
PERTE DE  
SUBSTANCE



# 4. Ménisques Fissures

VERTICALE

Profondeur :  
Partielle  
Transfixiante

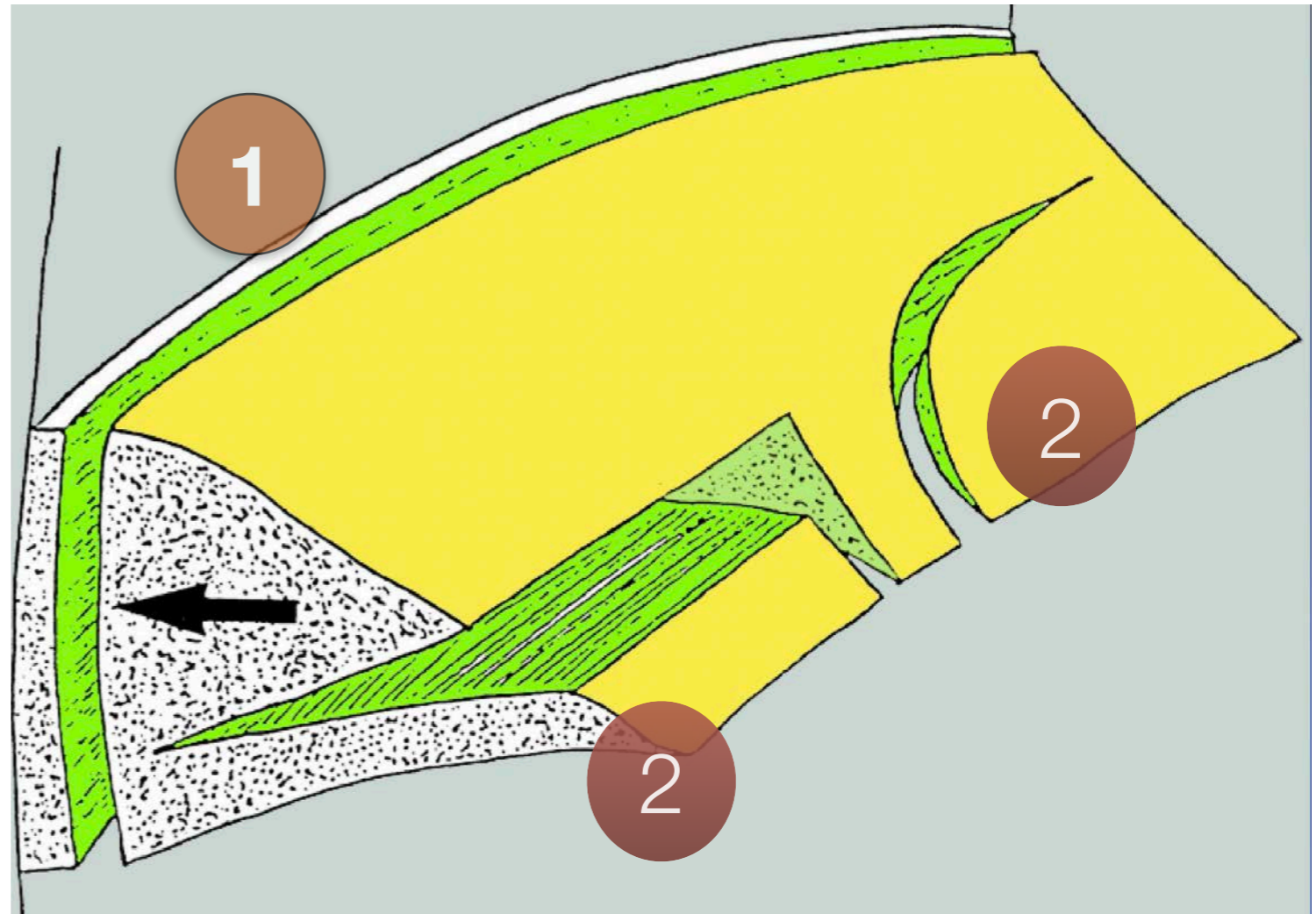


# 4. Ménisques Fissures

VERTICALE

Profondeur :  
Partielle  
Transfixiante

MIXTES



# 4. Ménisques Fissures

## Encadré 24.1 Liste des lésions méniscales et des migrations possibles de fragments méniscaux

### Type de lésion méniscale

- Fissures verticales
  - Fissures longitudinales
  - Désinsertions capsuloméniscales
  - Fissures radiaires
  - Fissures obliques (« en bec-de-perroquet »)
- Fissures horizontales
- Fissures complexes
- Contusions méniscales

### Topographie de la lésion

- Corne postérieure, tiers moyen, corne antérieure, frein
- Tiers central, intermédiaire ou périphérique (vascularisé)
- Profondeur : partielle ou complète (transfixiante)

### Migration de fragments méniscaux

- Anse de seau
- Fragment retourné (*mégacorne, double corne, etc.*)
- Lambeau méniscal
- Fragment libre

### Lésion méniscale stable/instable

#### Qualité du ménisque adjacent

- Normal
- Dégénératif : hypersignal intraméniscal ou global, irrégularités des berges

#### Lésions associées

- Kyste intra/périméniscal
- Rupture du LCA
- Fracture sous chondrale
- Arthrose fémorotibiale, etc.

#### Variantes méniscales

- Ménisque discoïde
- Ménisque hypermobile
- Ossicule méniscal

## Encadré 24.3 Lésions méniscales stables ou instables

### Lésions méniscales instables

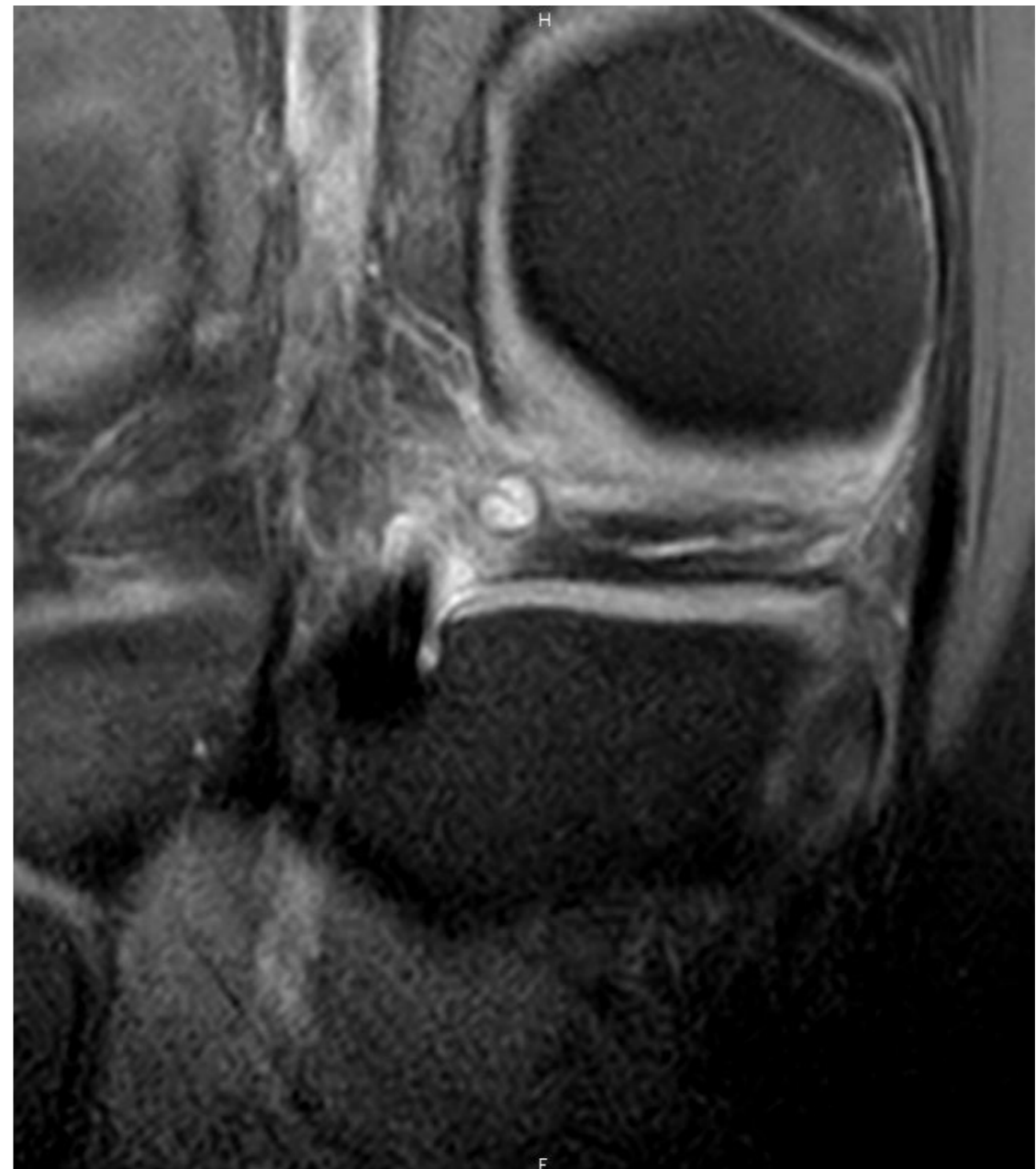
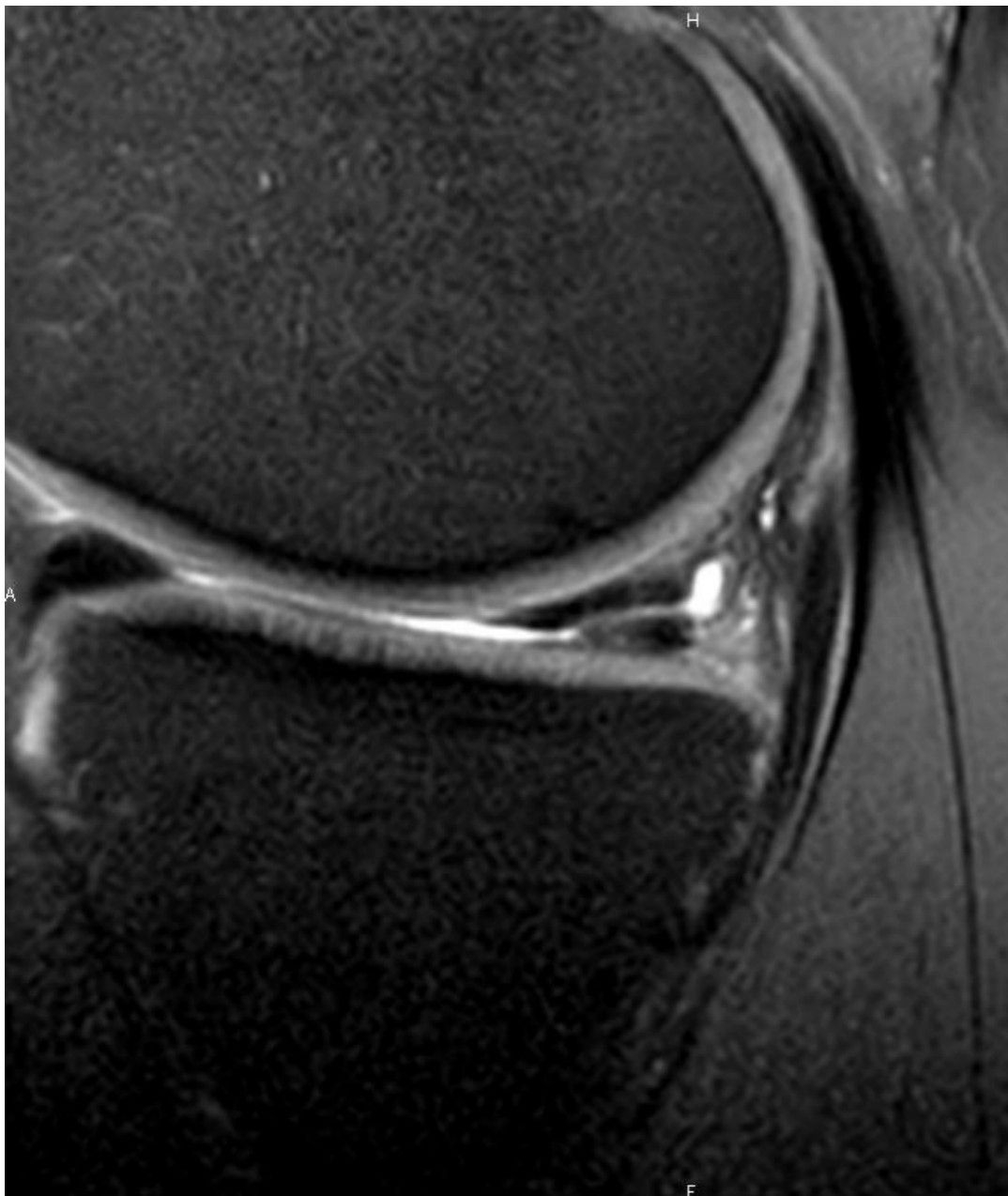
- Fissure verticale complète de plus de 10 mm de longueur
- Désinsertion capsuloméniscale de plus de 10 mm de longueur
- Fissure complexe
- Fissure en hypersignal T2 de type liquidien (passage de liquide témoignant de l'écartement des berges)
- Fissure (quel qu'en soit le type) avec fragment méniscal déplacé
- Lésion d'un frein méniscal postérieur
- Lésion de l'attache méniscotibiale ou méniscofémorale

### Lésions méniscales stables

- Anomalie isolée des contours méniscaux
- Fissure radiaire isolée et de petite taille
- Fissure horizontale
- Fissure verticale partielle (moins de la moitié de la hauteur méniscale)
- Fissure verticale complète de moins de 5–10 mm de longueur
- Désinsertion capsuloméniscale de moins de 5–10 mm de longueur

# 4. Ménisques

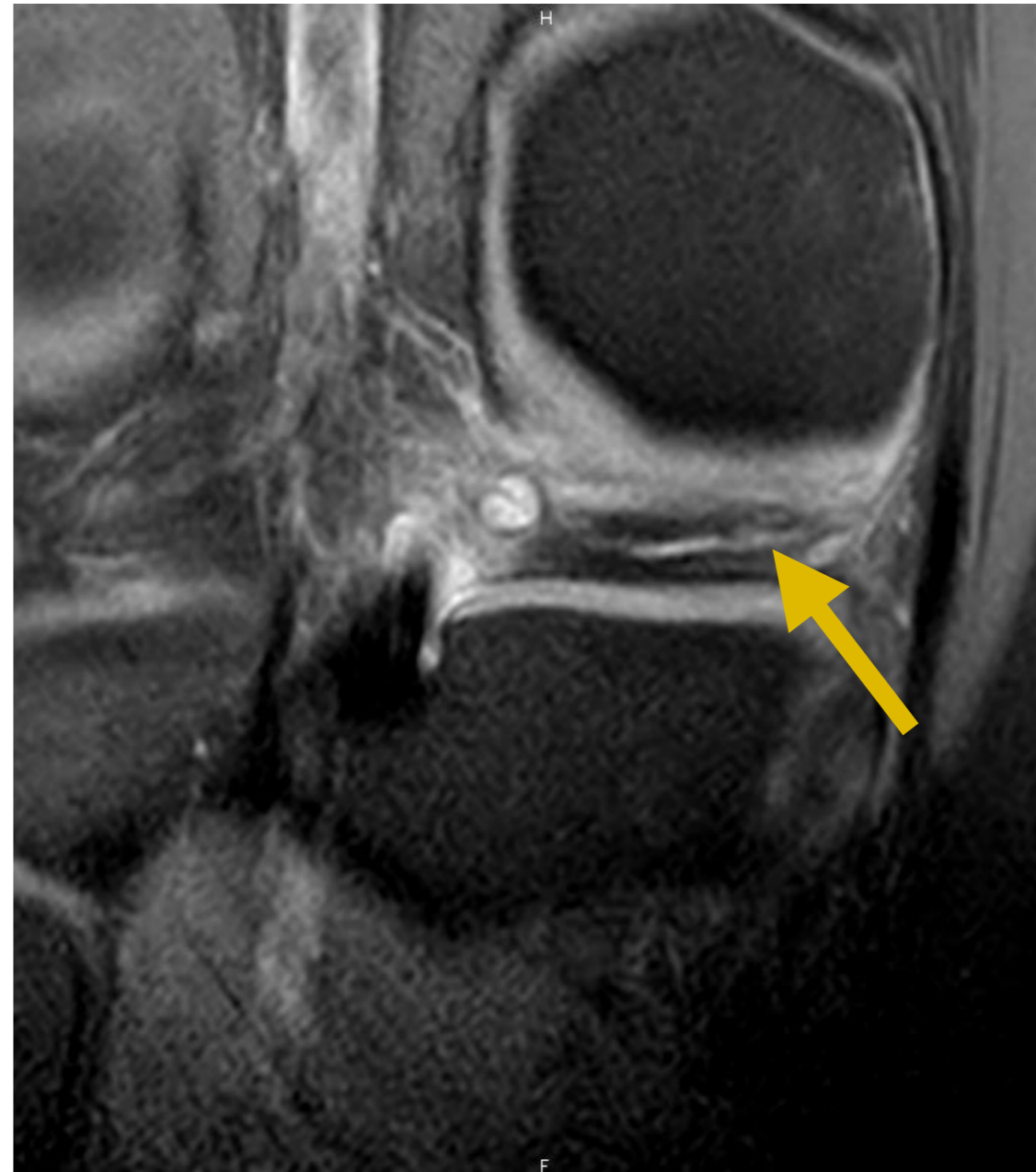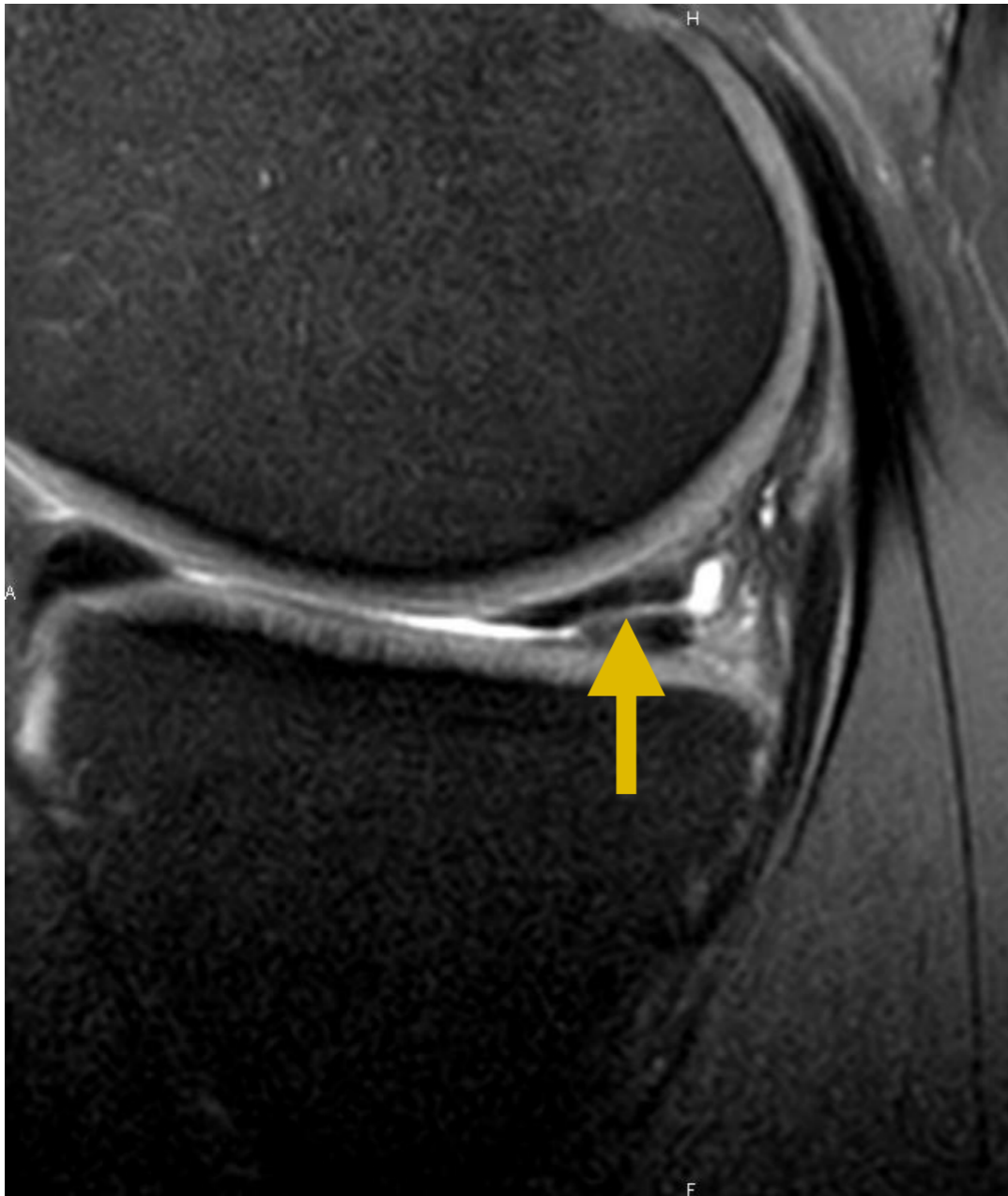
- Fissure : axiale





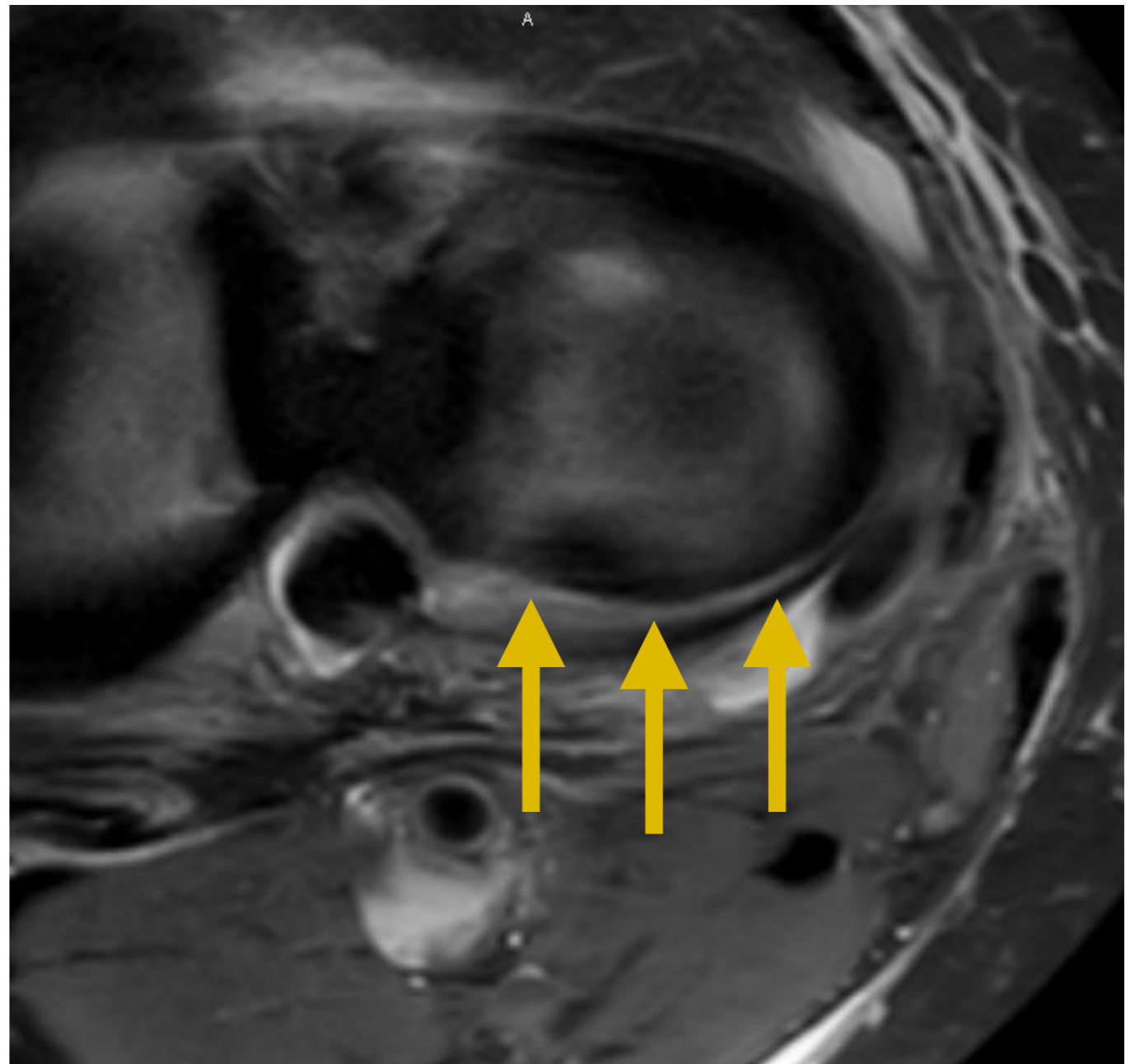
# 4. Ménisques

- Fissure : axiale



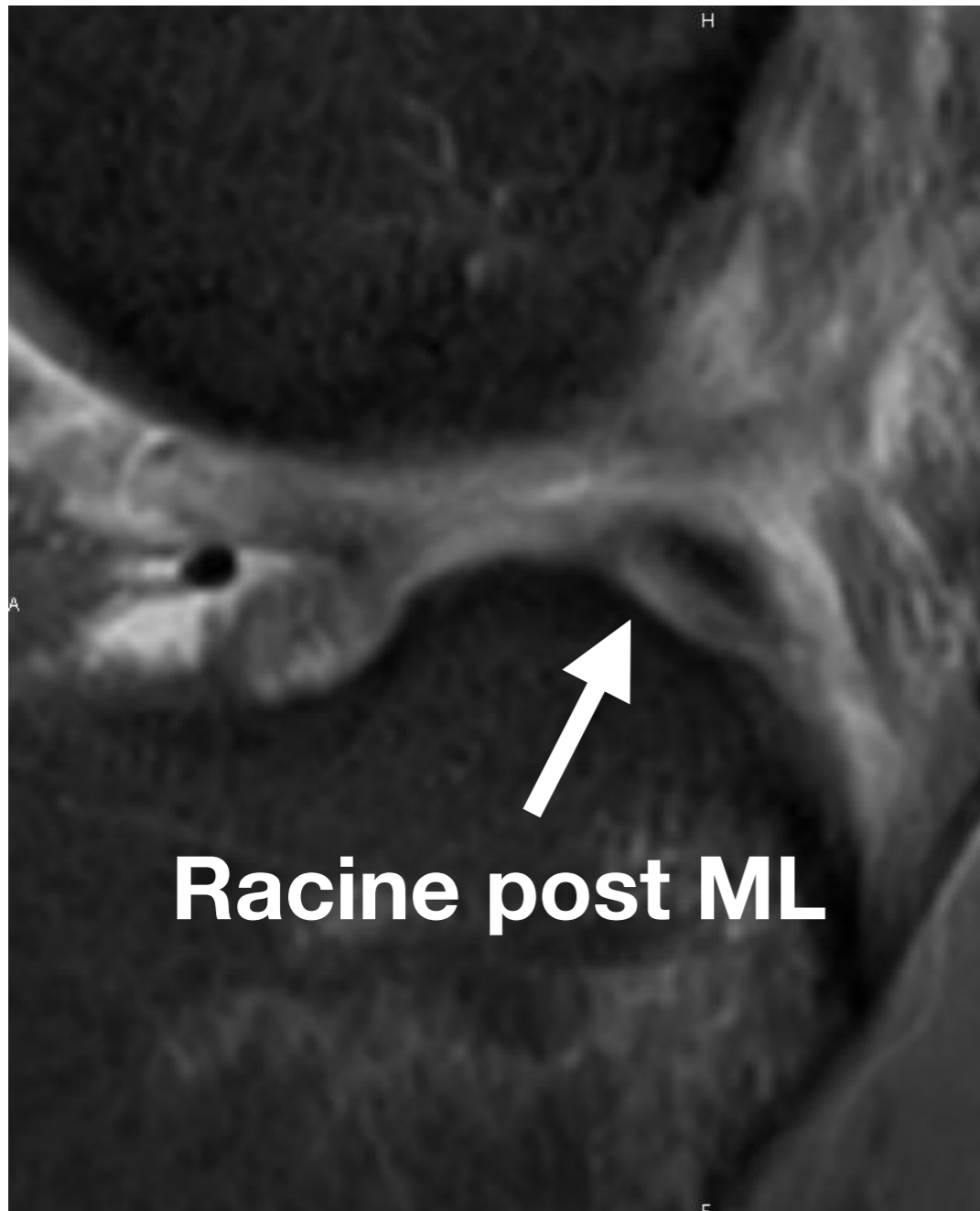
## 4. Ménisques

- Fissure verticale longitudinale
- Dépasse la moitié de la corne postérieure du ML = fissure
- **ZIP sign associé au LCA +++**



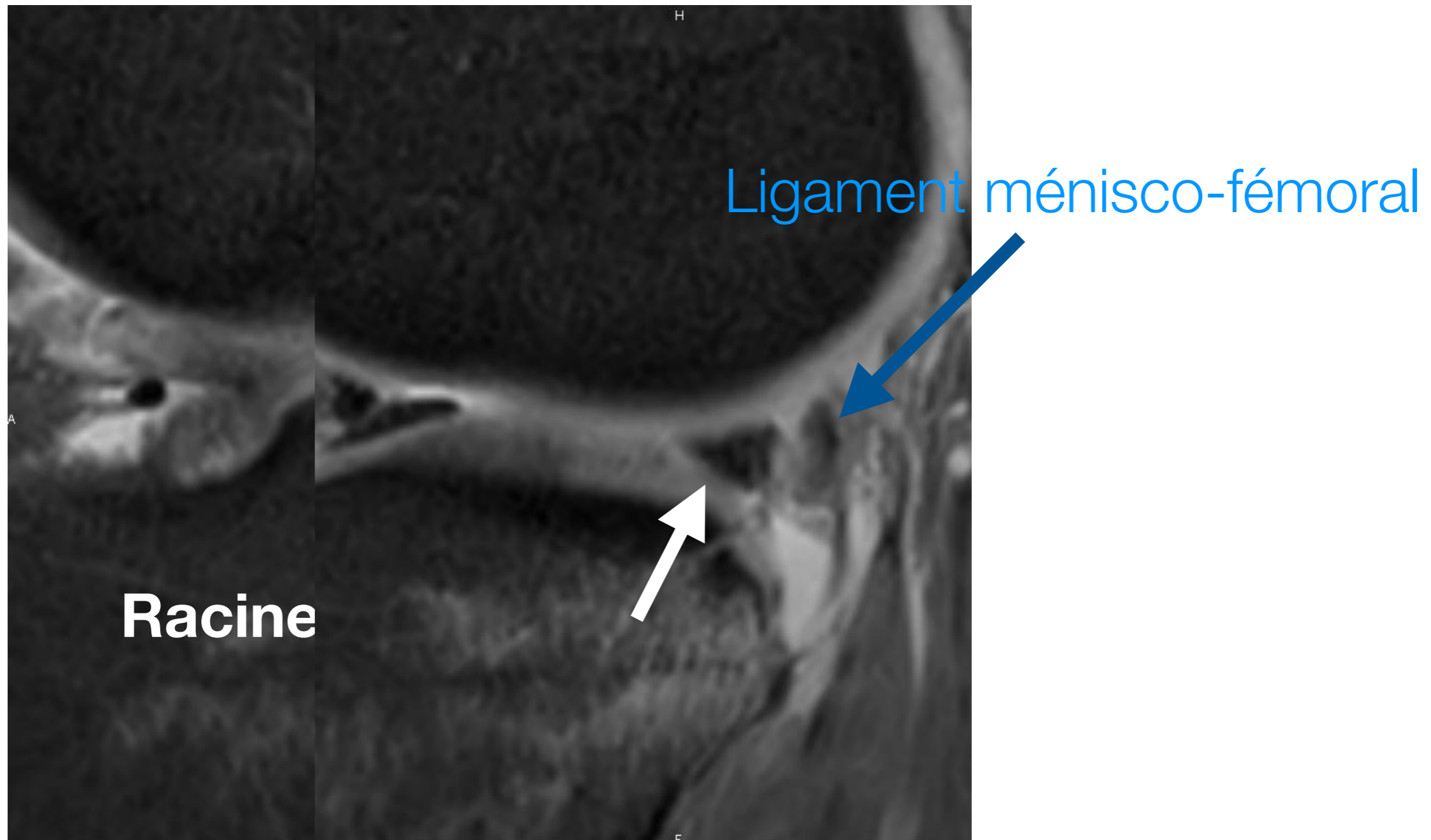
## 4. Ménisques

- Fissures : verticale longitudinale



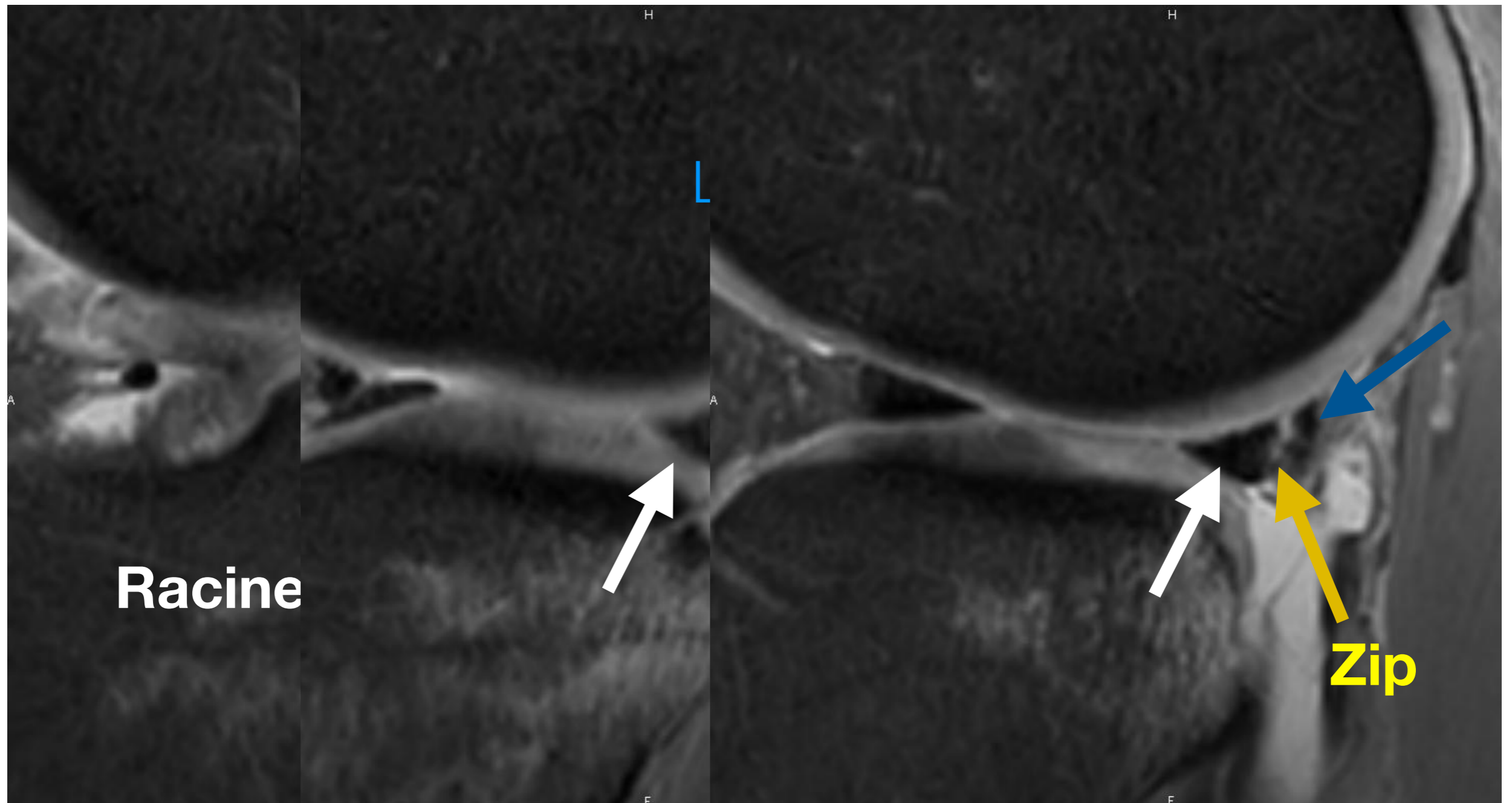
## 4. Ménisques

- Fissures : verticale longitudinale



# 4. Ménisques

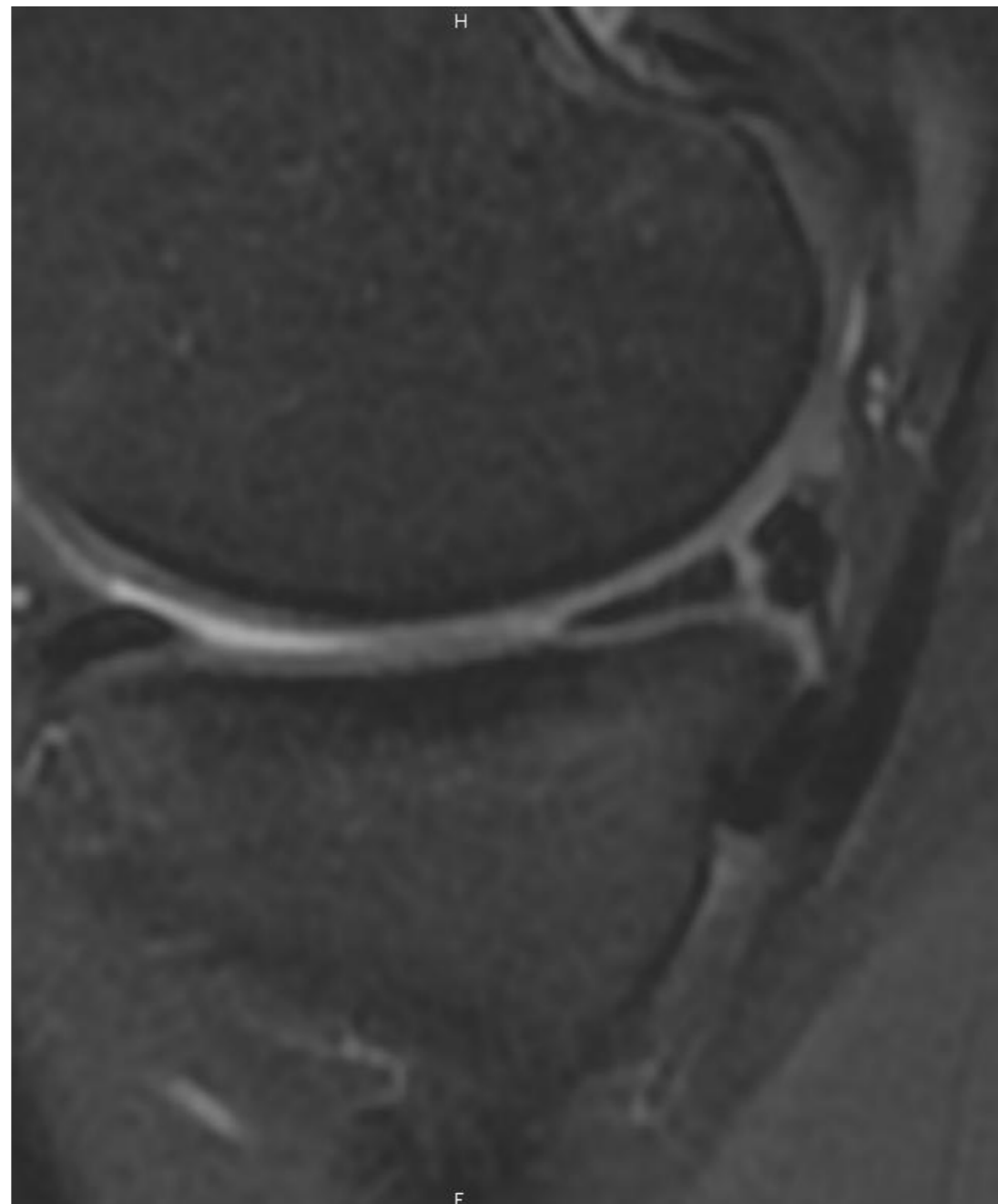
- Fissures : verticale longitudinale



## 4. Ménisques

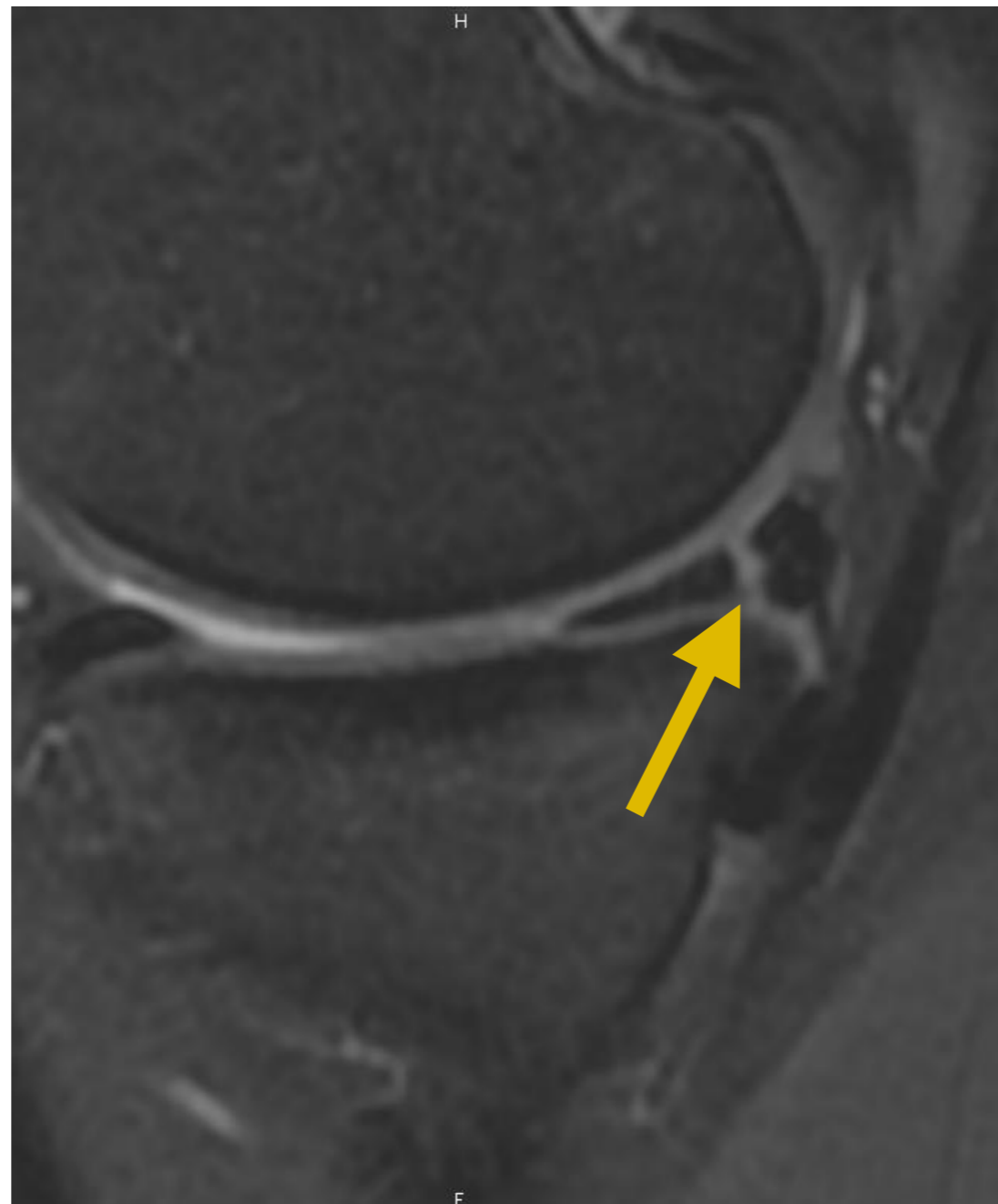
---

- Fissure verticale transfixiante CPMM



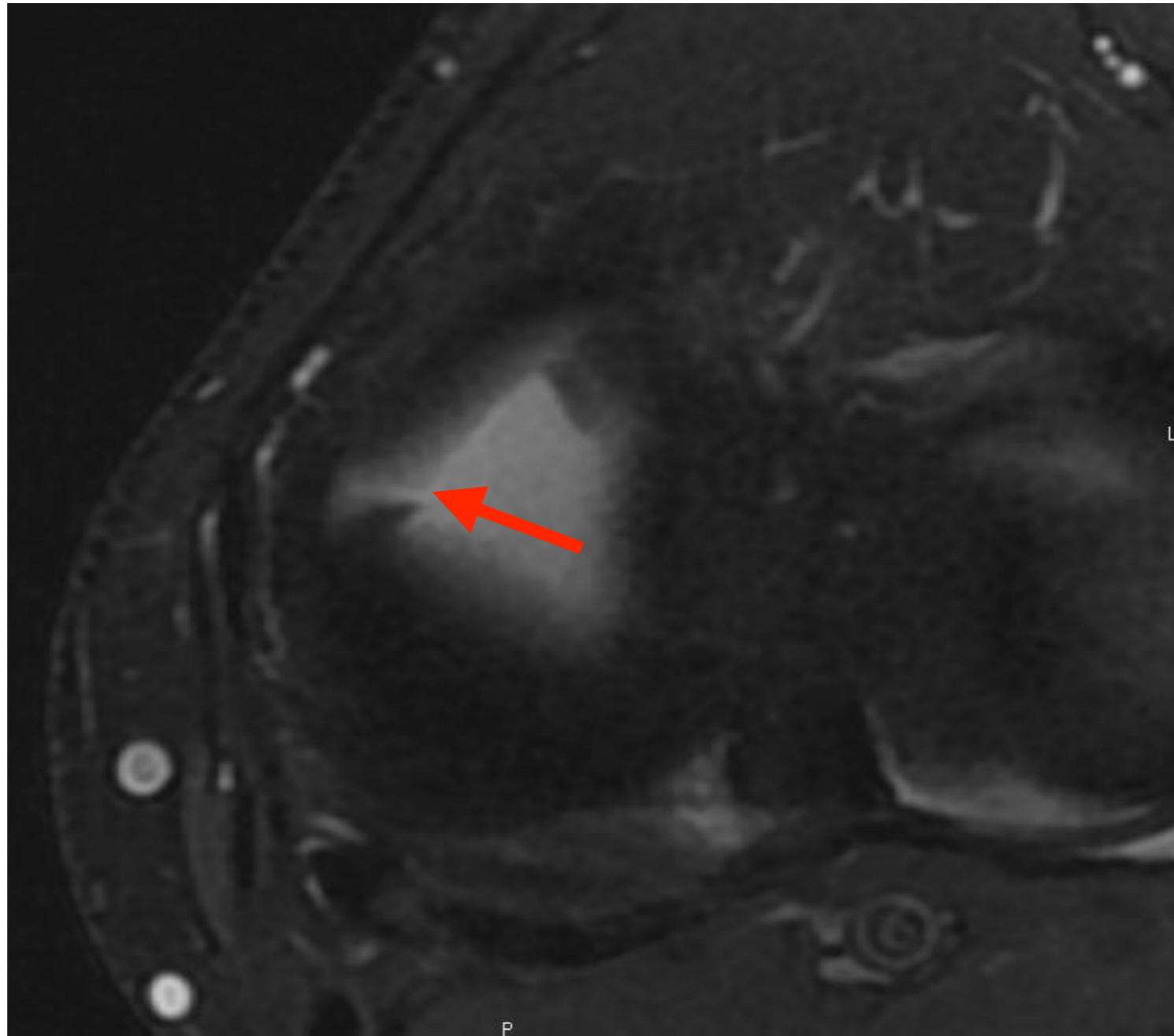
# 4. Ménisques

- Fissure verticale transfixiante CPMM



## 4. Ménisques

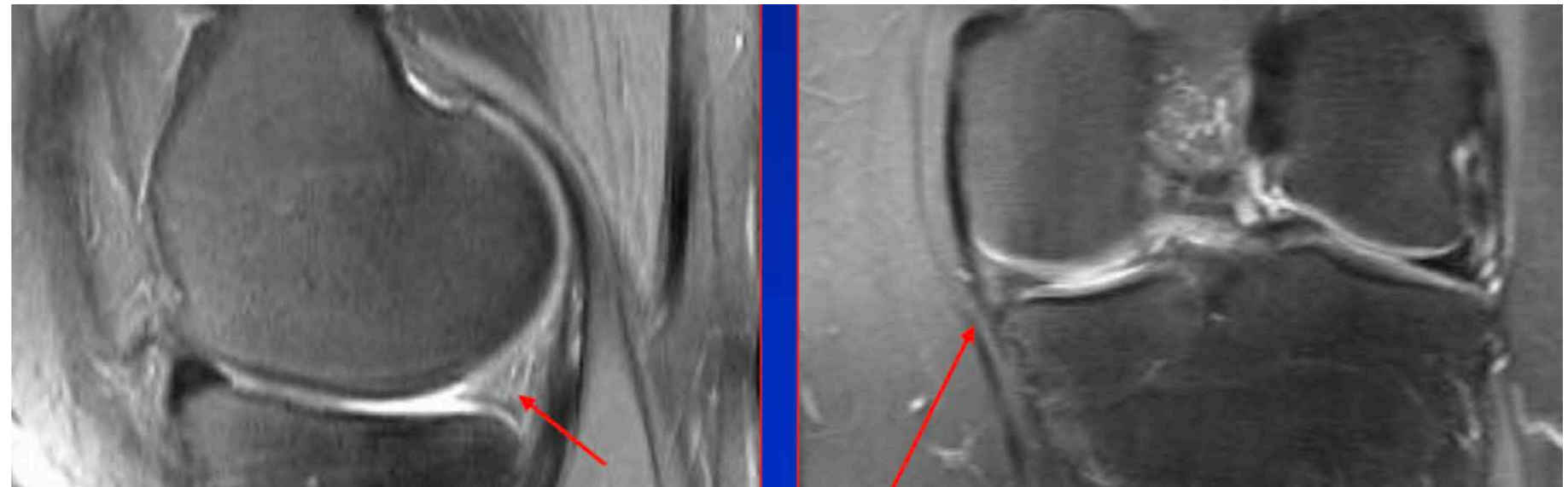
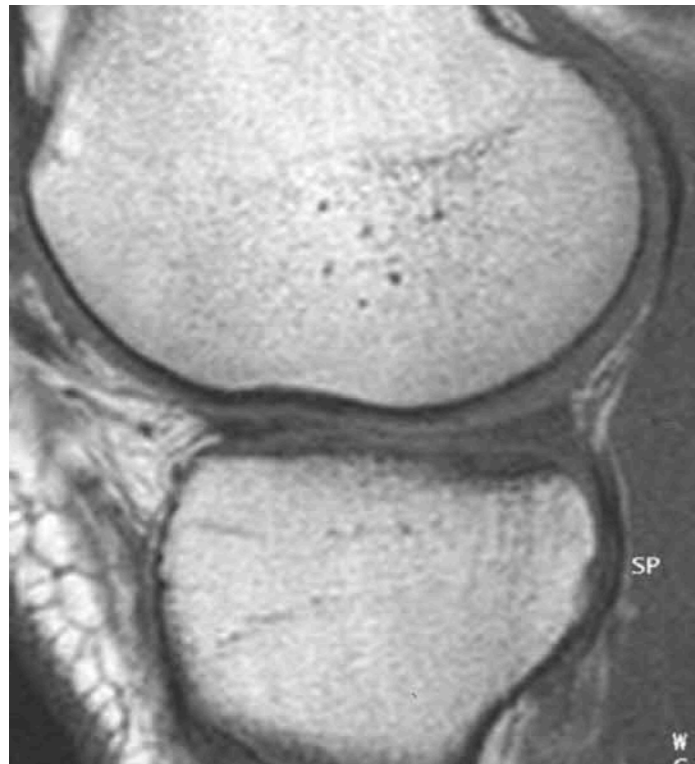- Fissure verticale radiaire

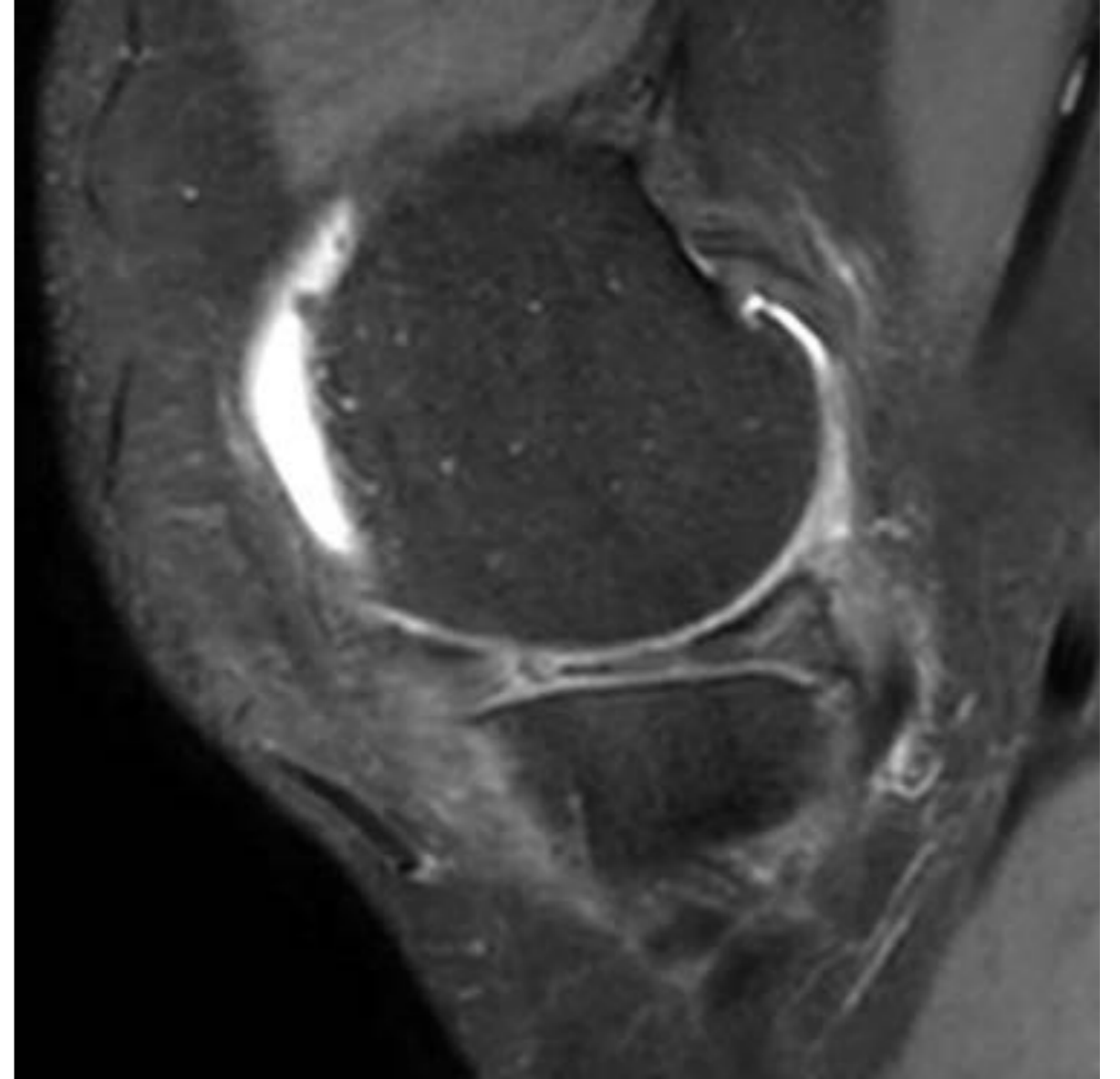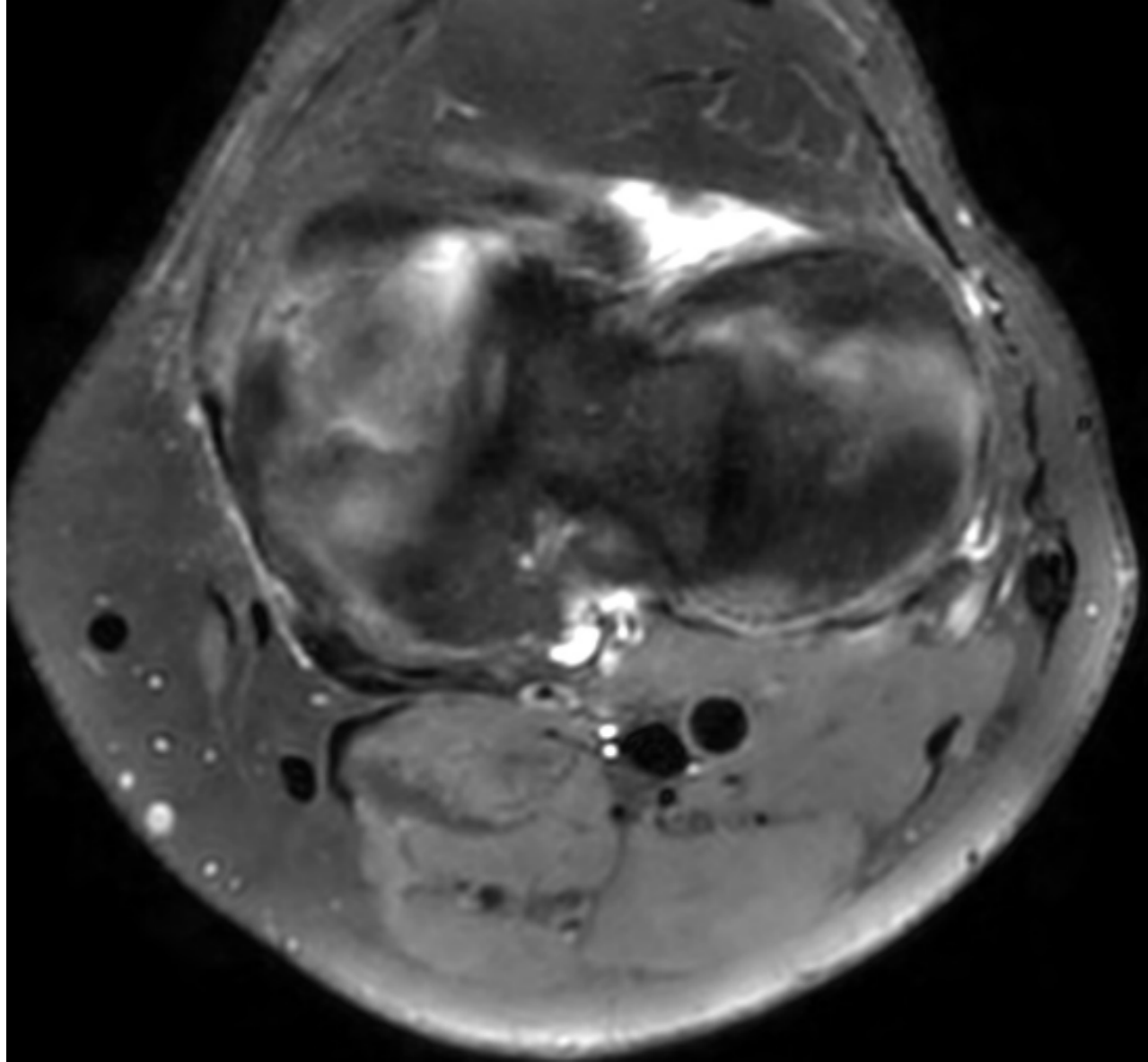


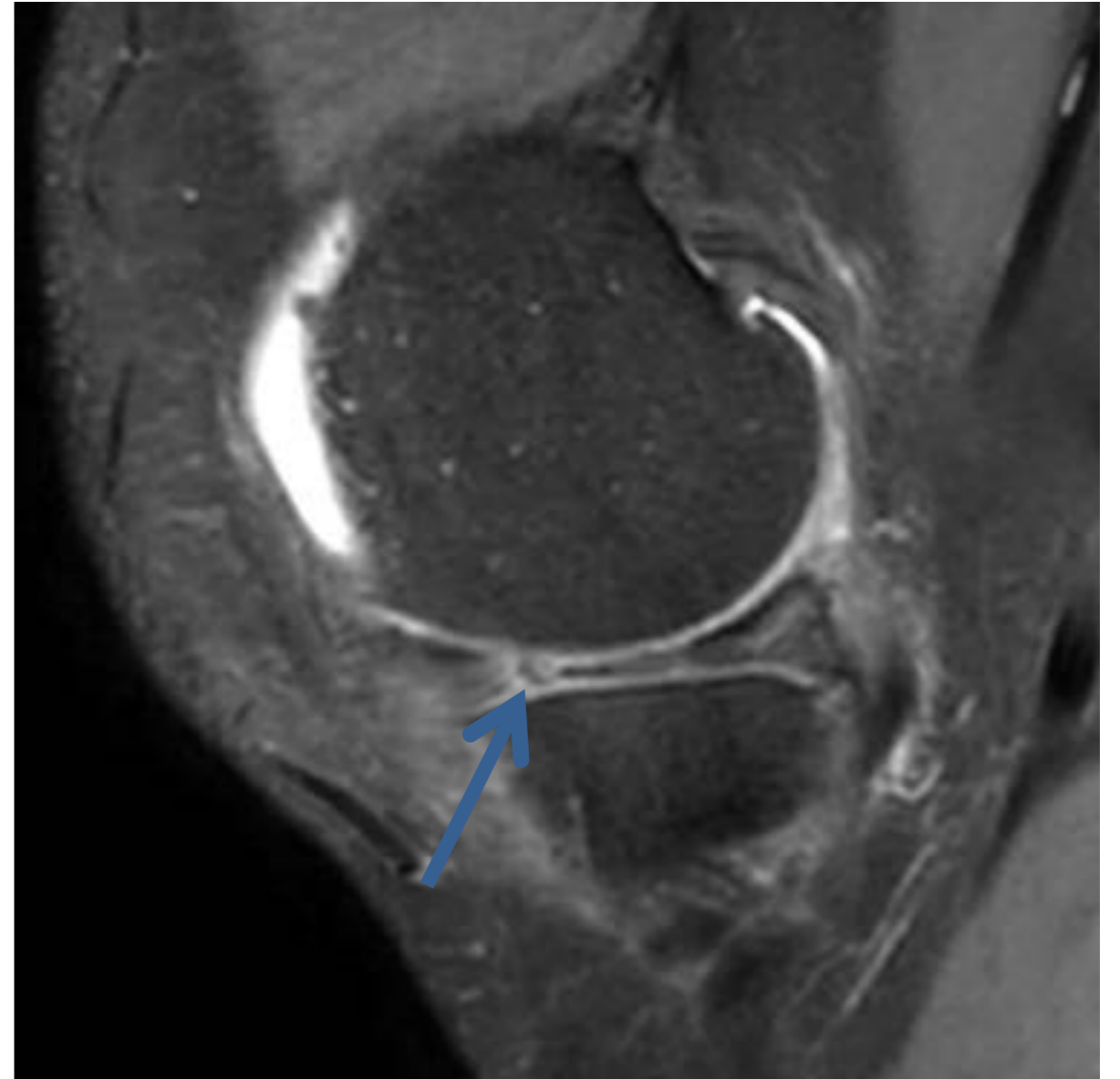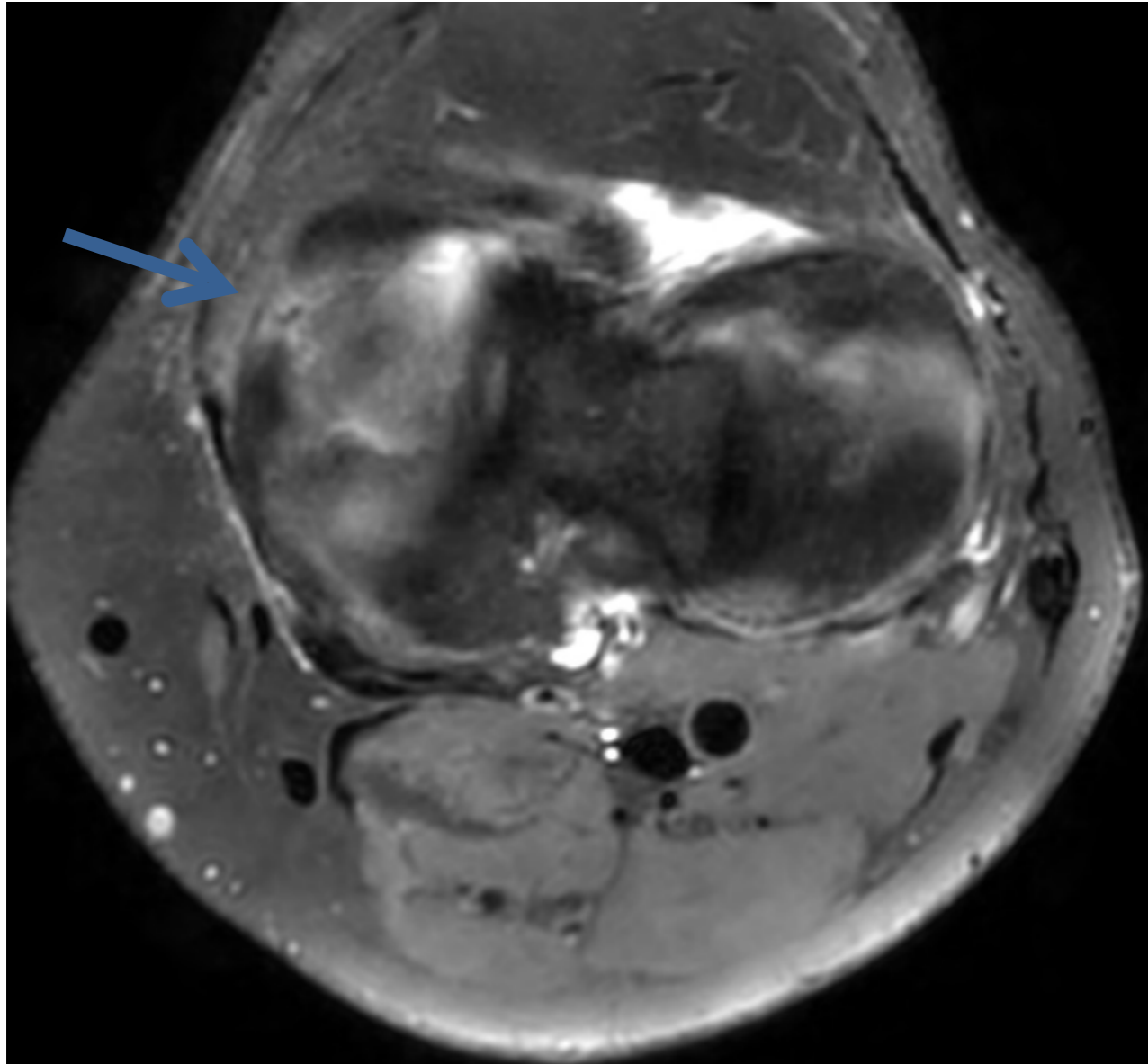


# 4. Ménisques

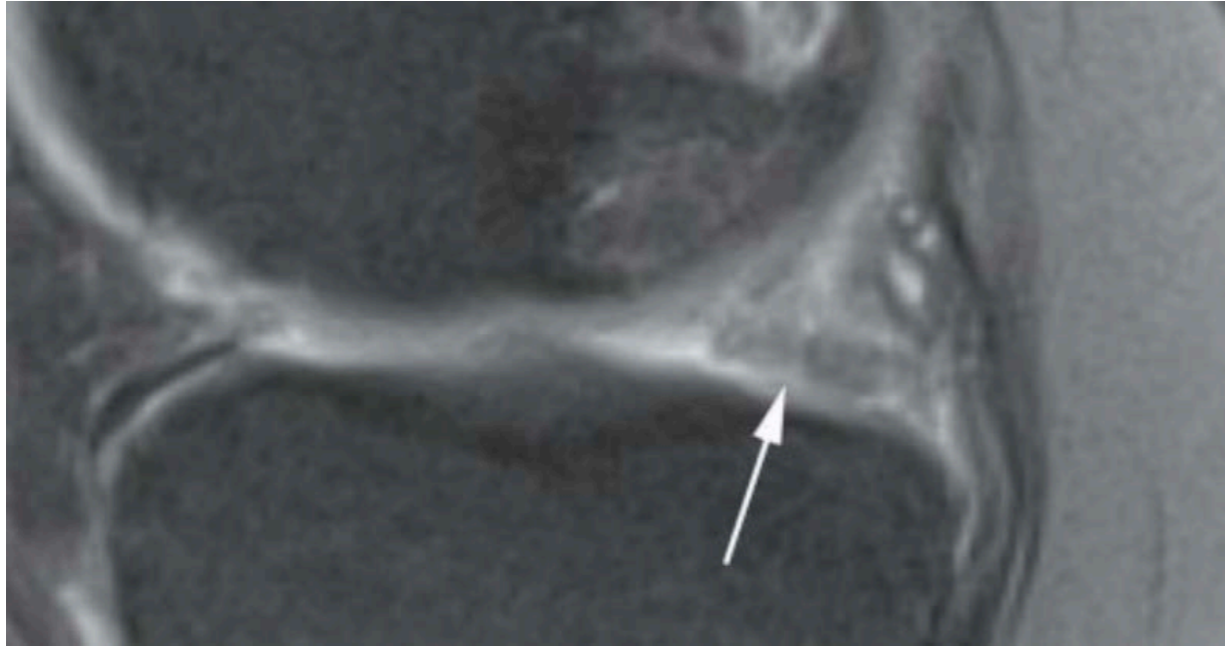
- Ménisque fantôme : Volume partiel ?

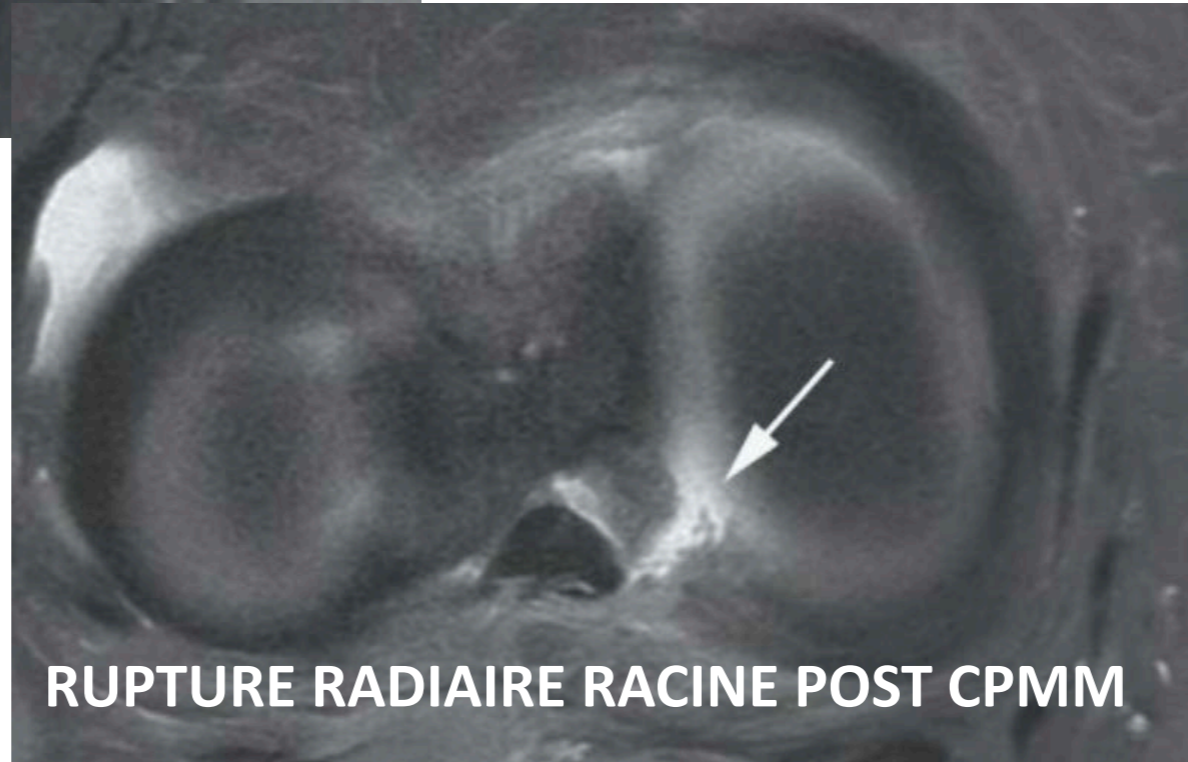
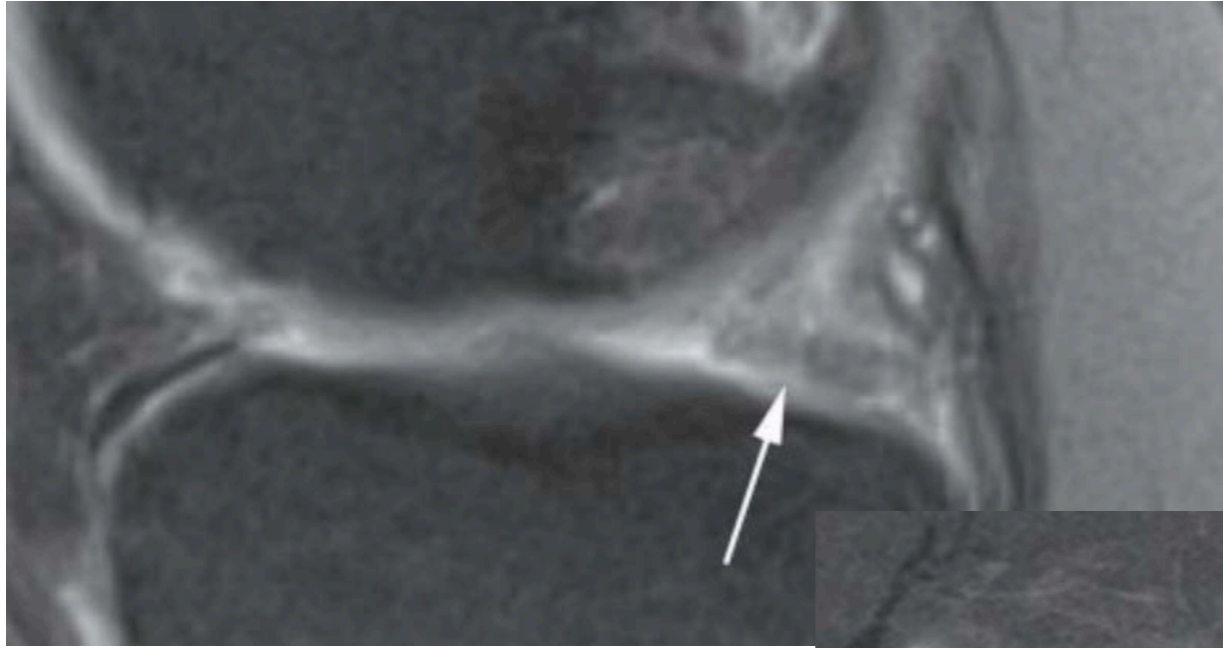




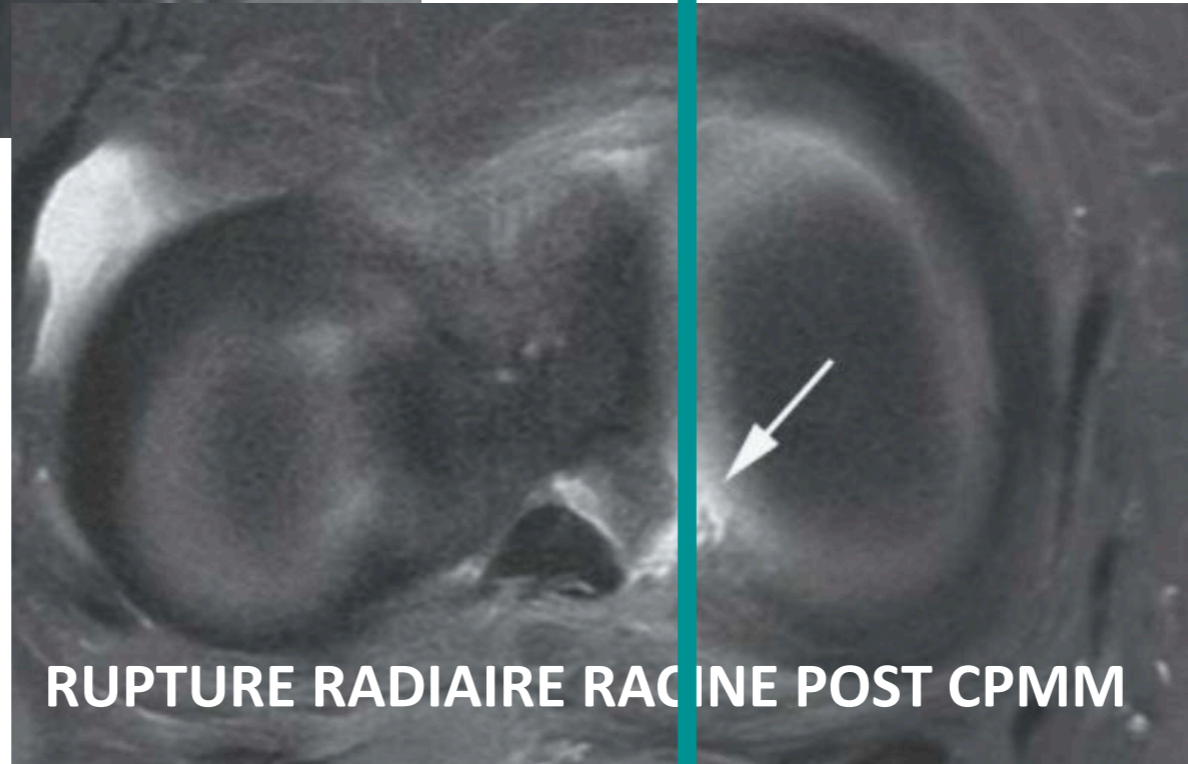
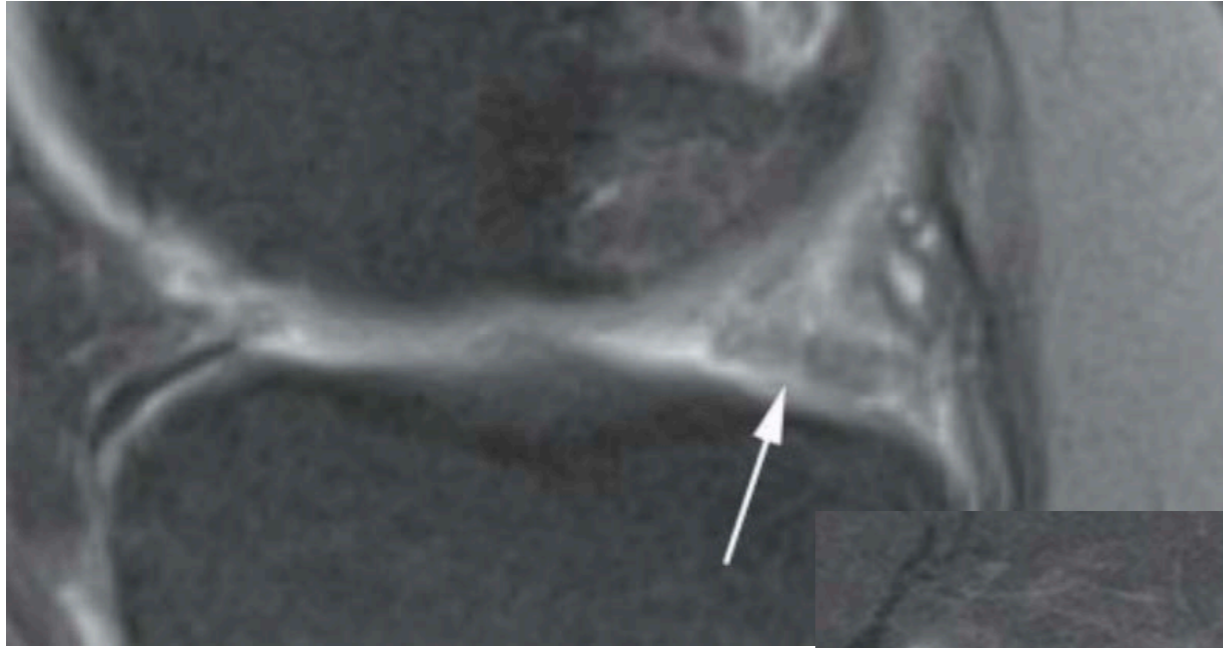


**Rupture radiaire du segment moyen du ménisque médial**

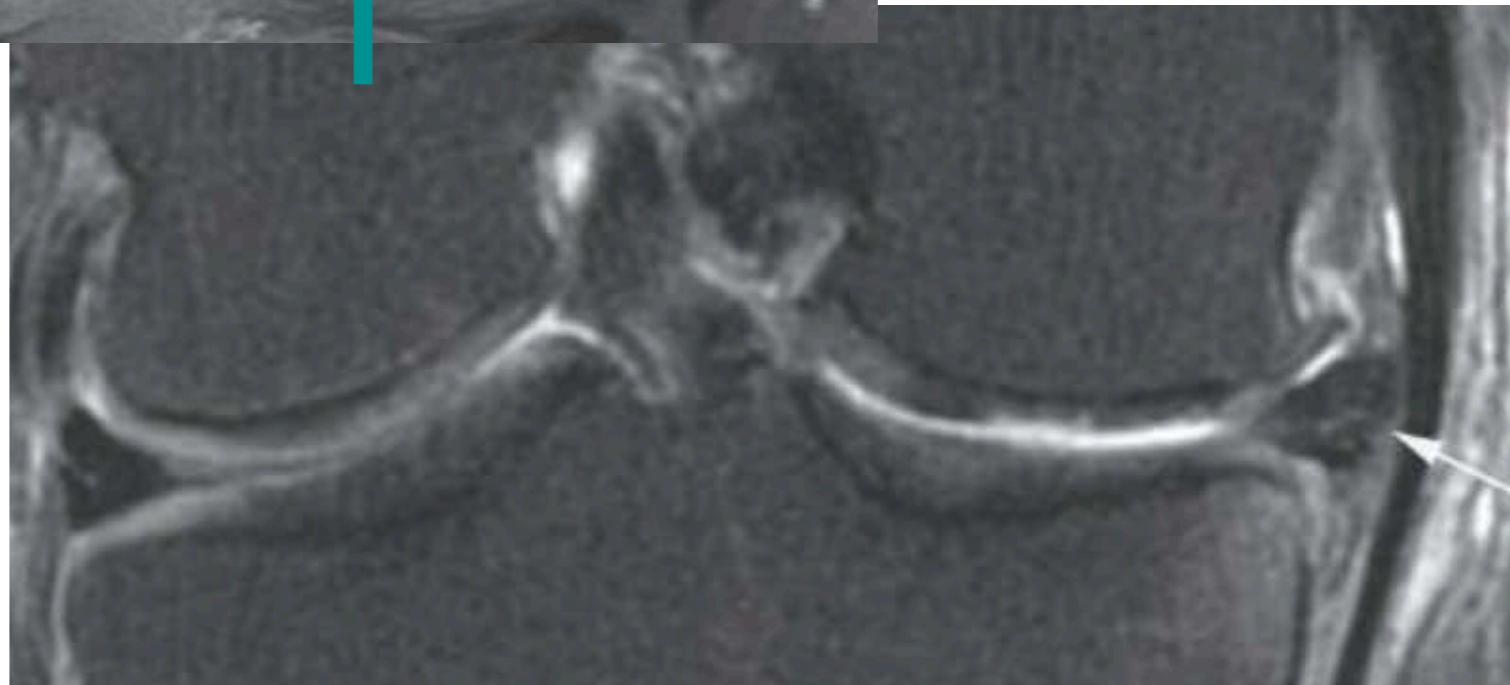
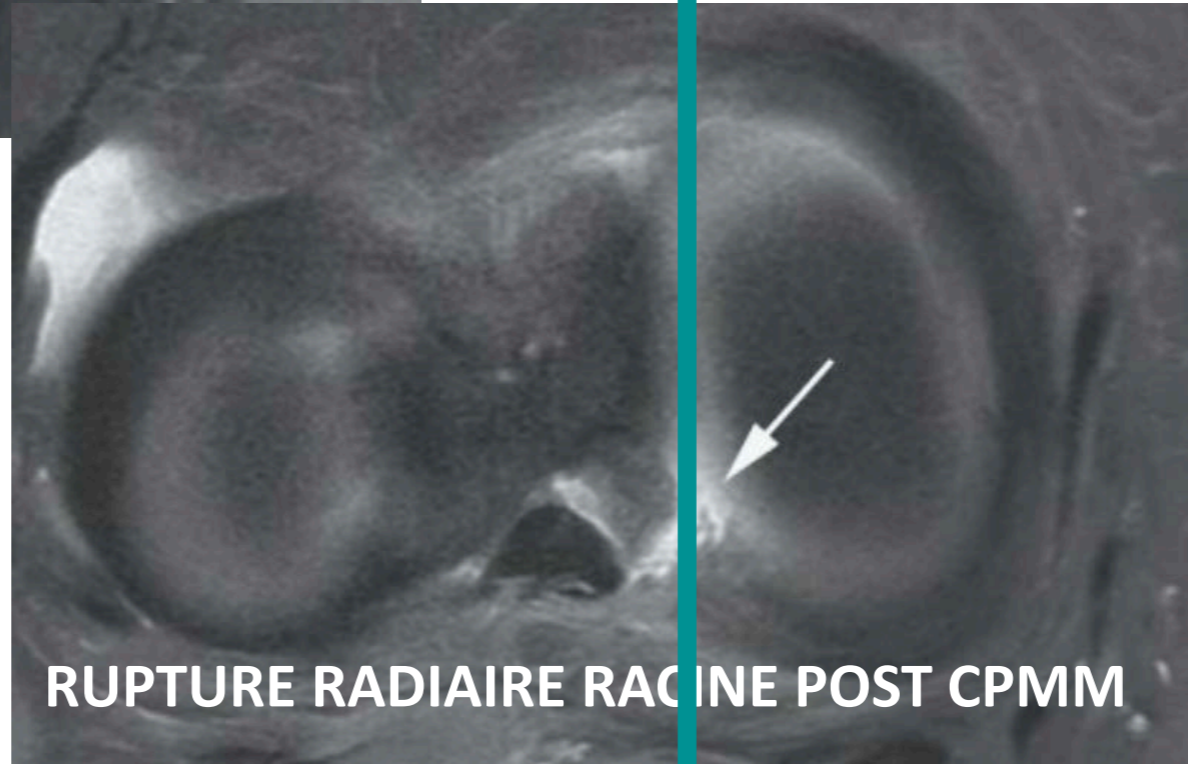
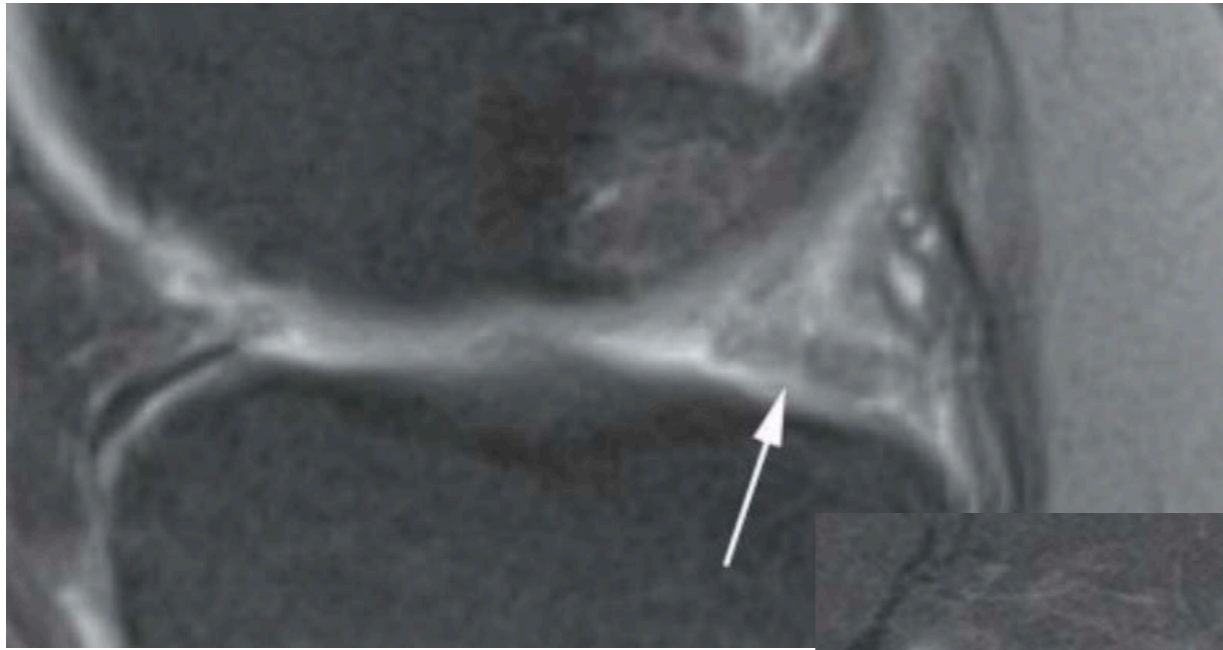




**RUPTURE RADIAIRE RACINE POST CPMM**

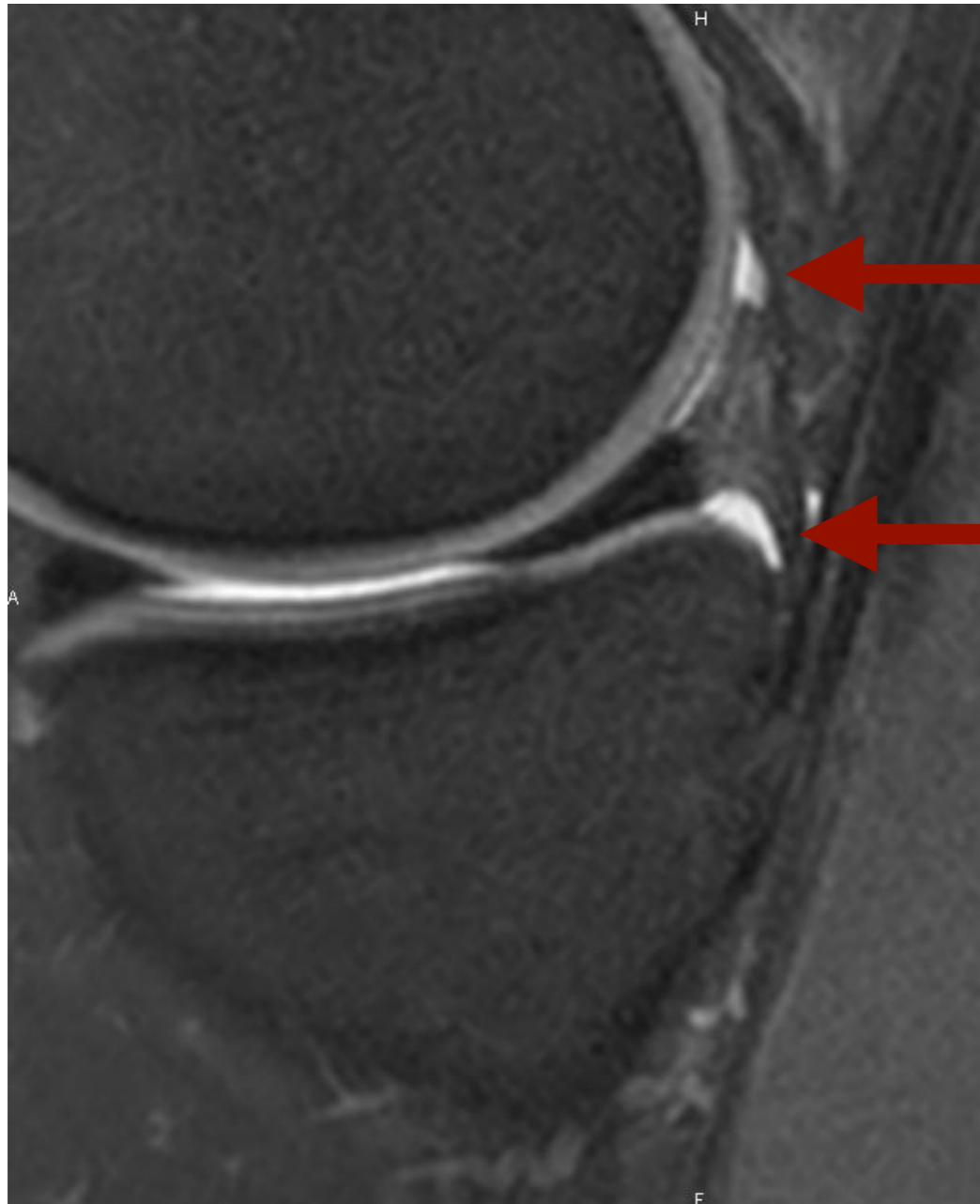


**RUPTURE RADIAIRE RACINE POST CPMM**



## 4. Désinsertion Capsulo Méniscale : Ramp Lesion

- Fissure verticale périphérique

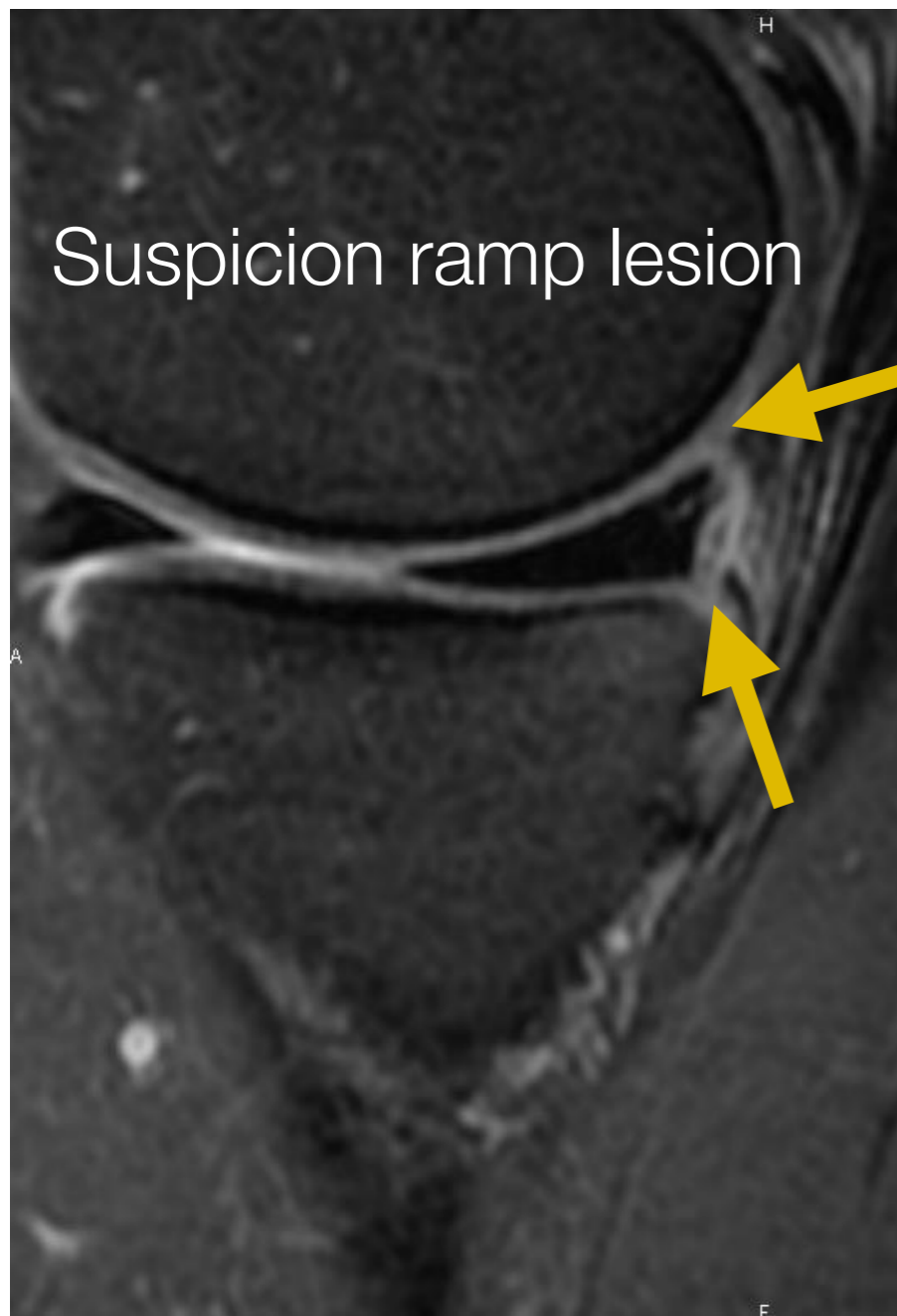


Attache ménisco-fémorale

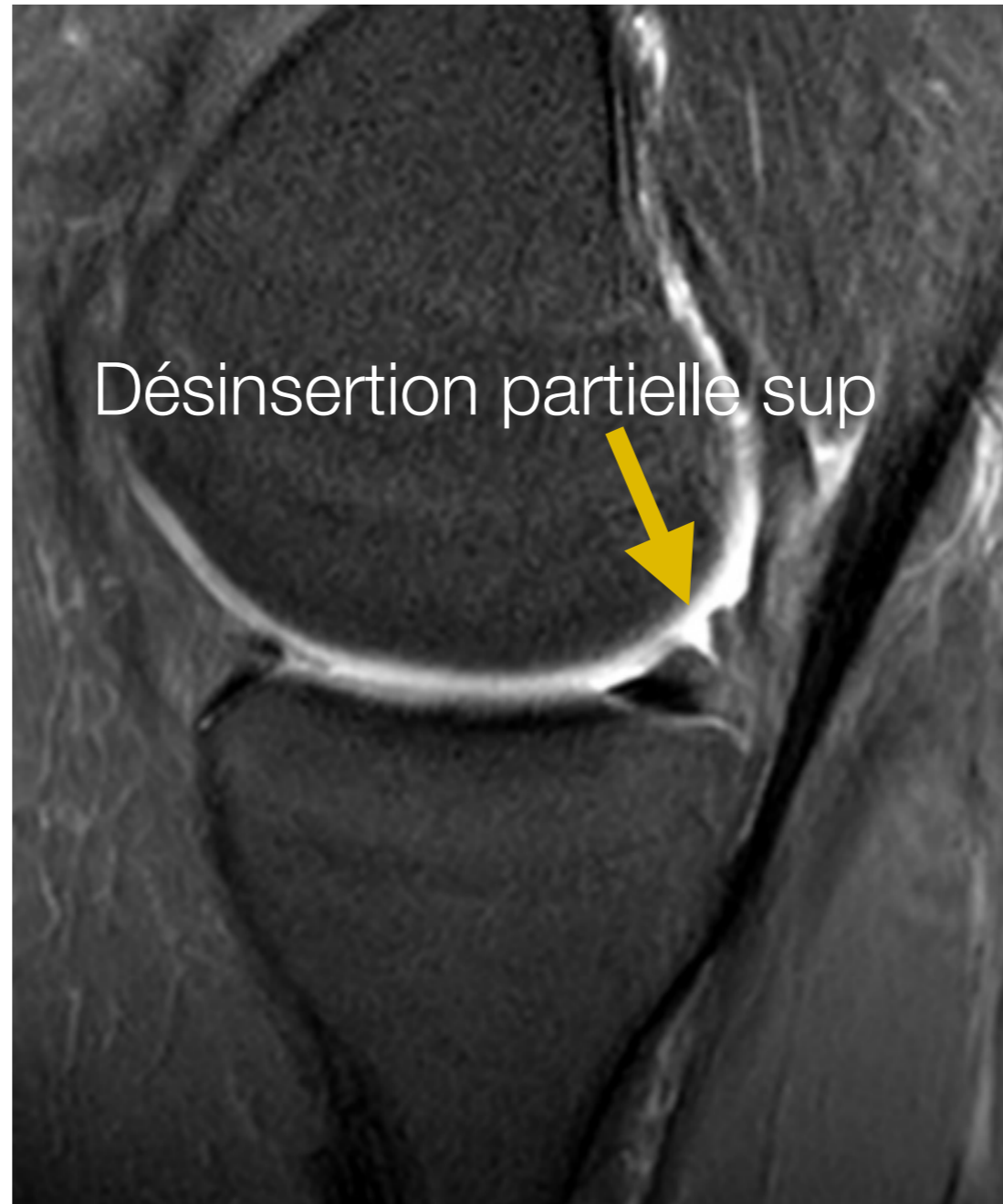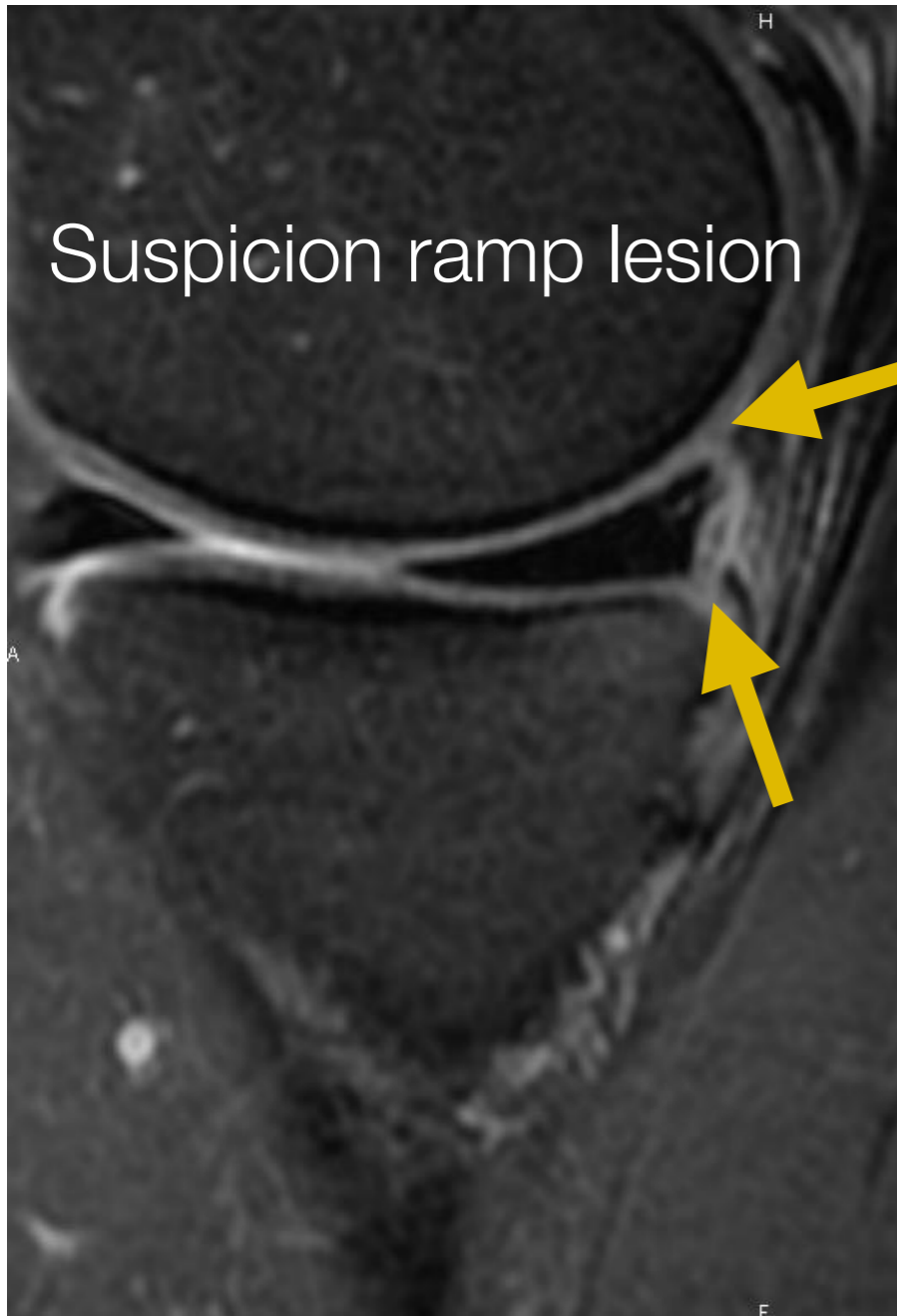
Ligament ménisco-tibial



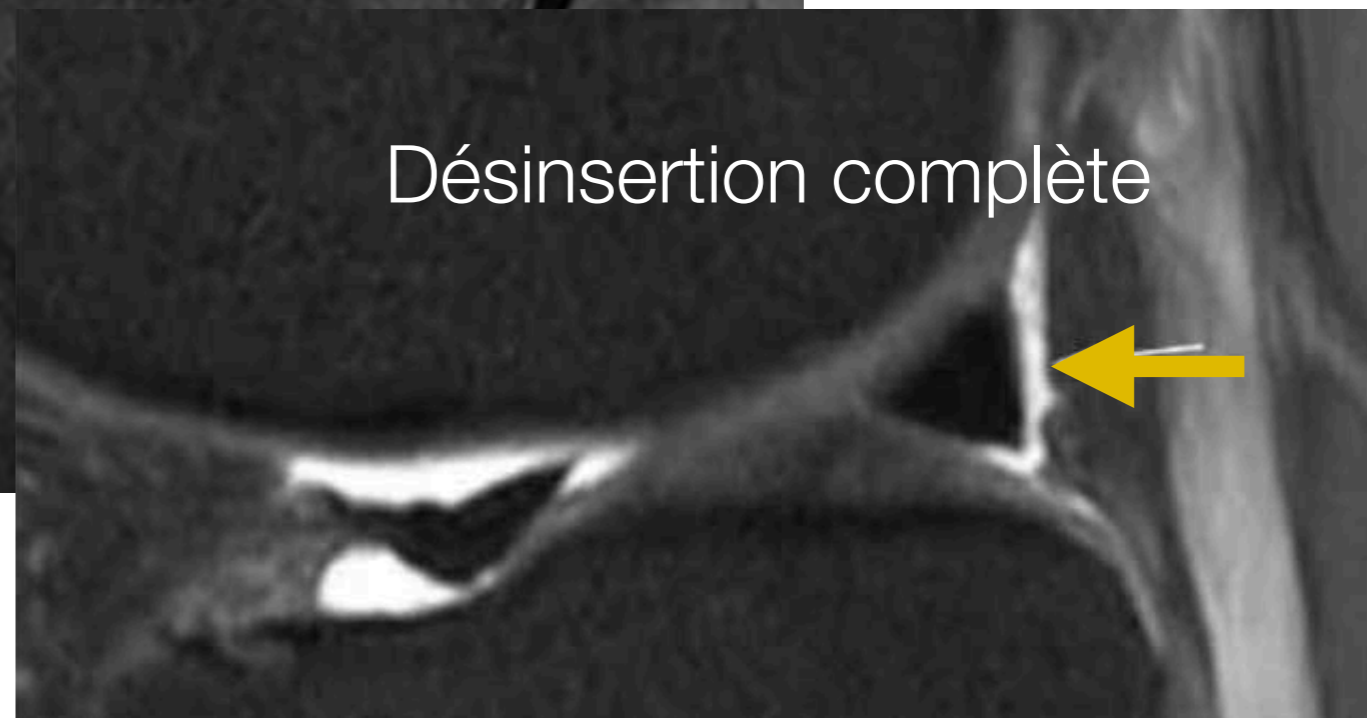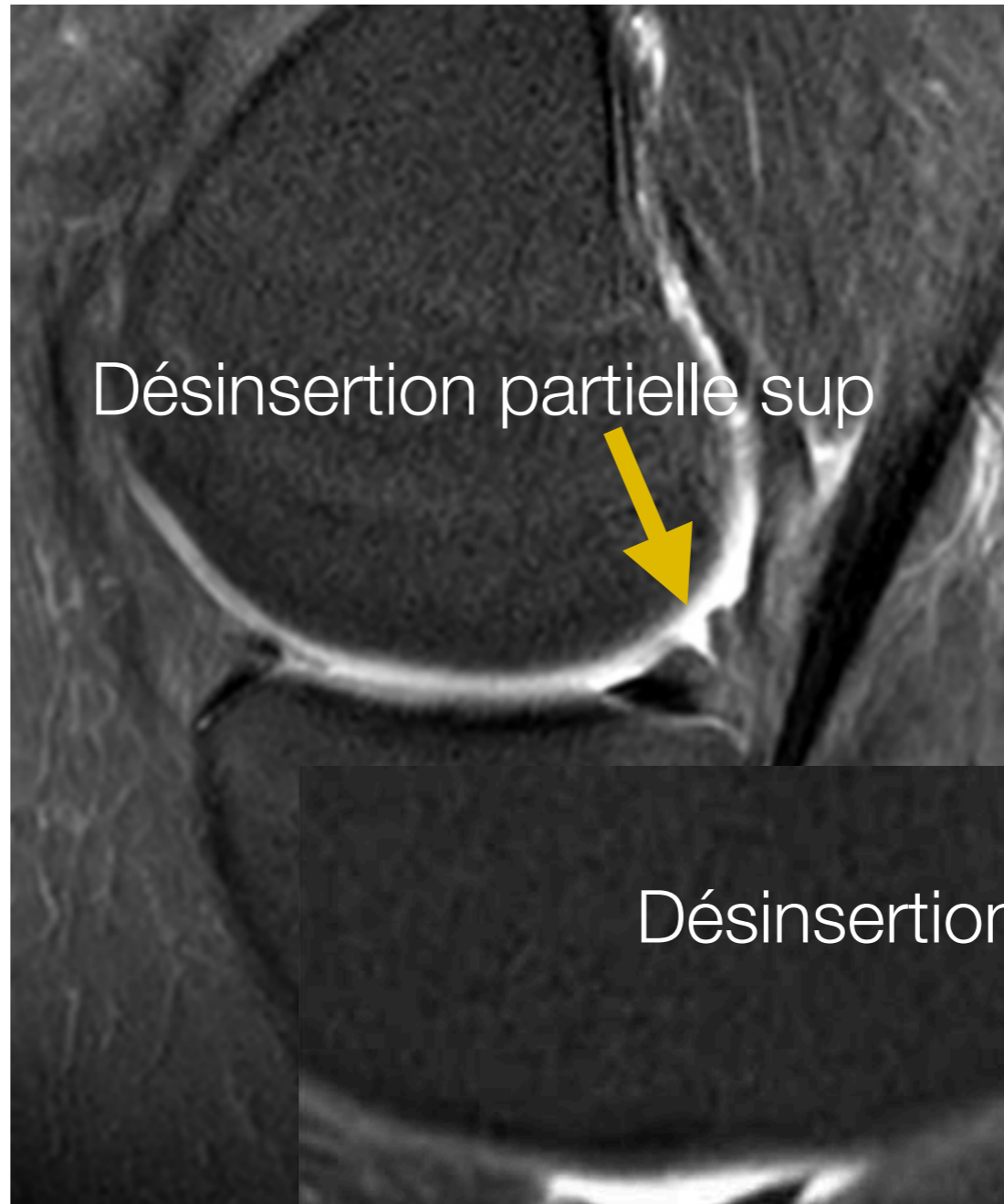
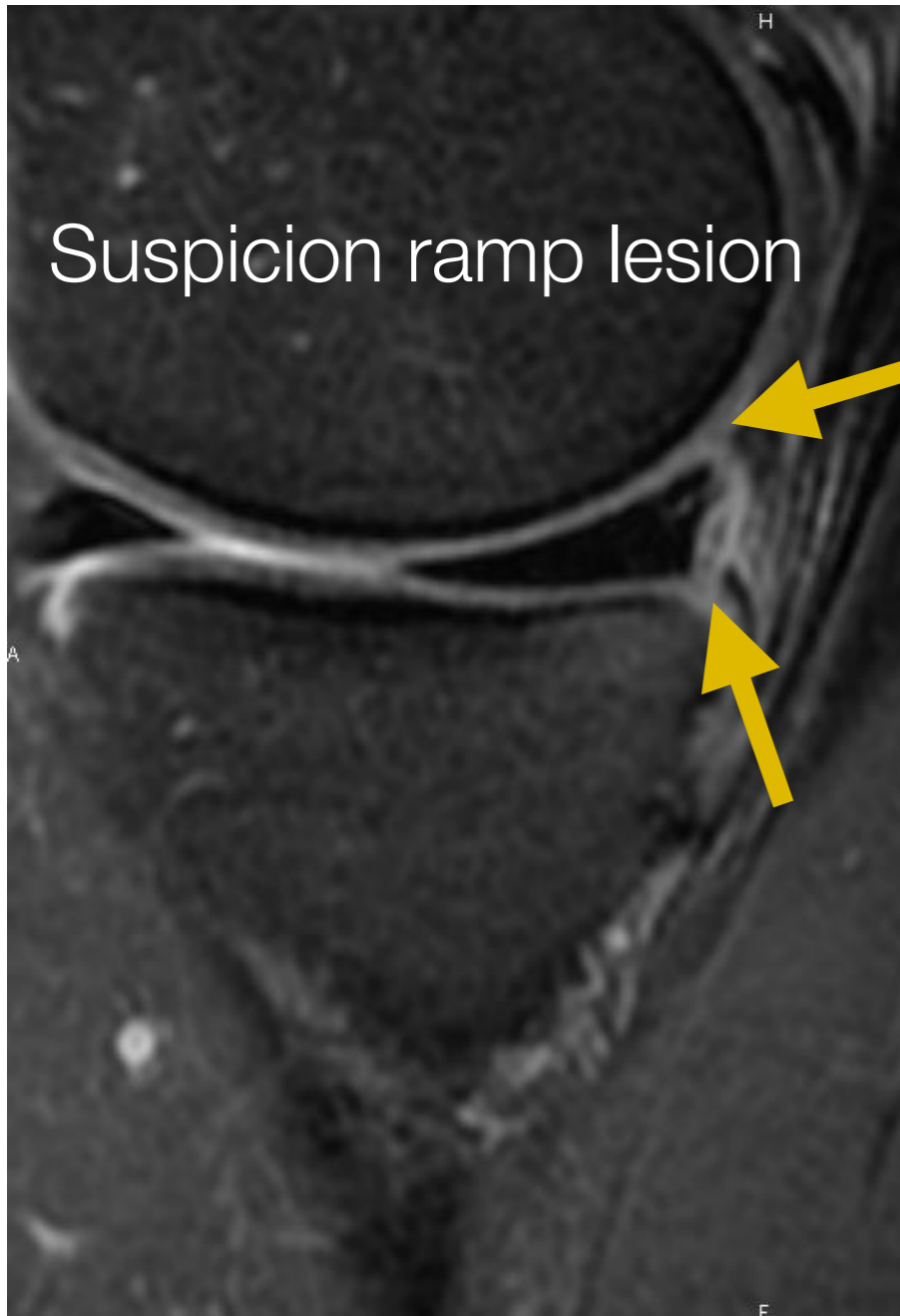
# 4. Ménisques

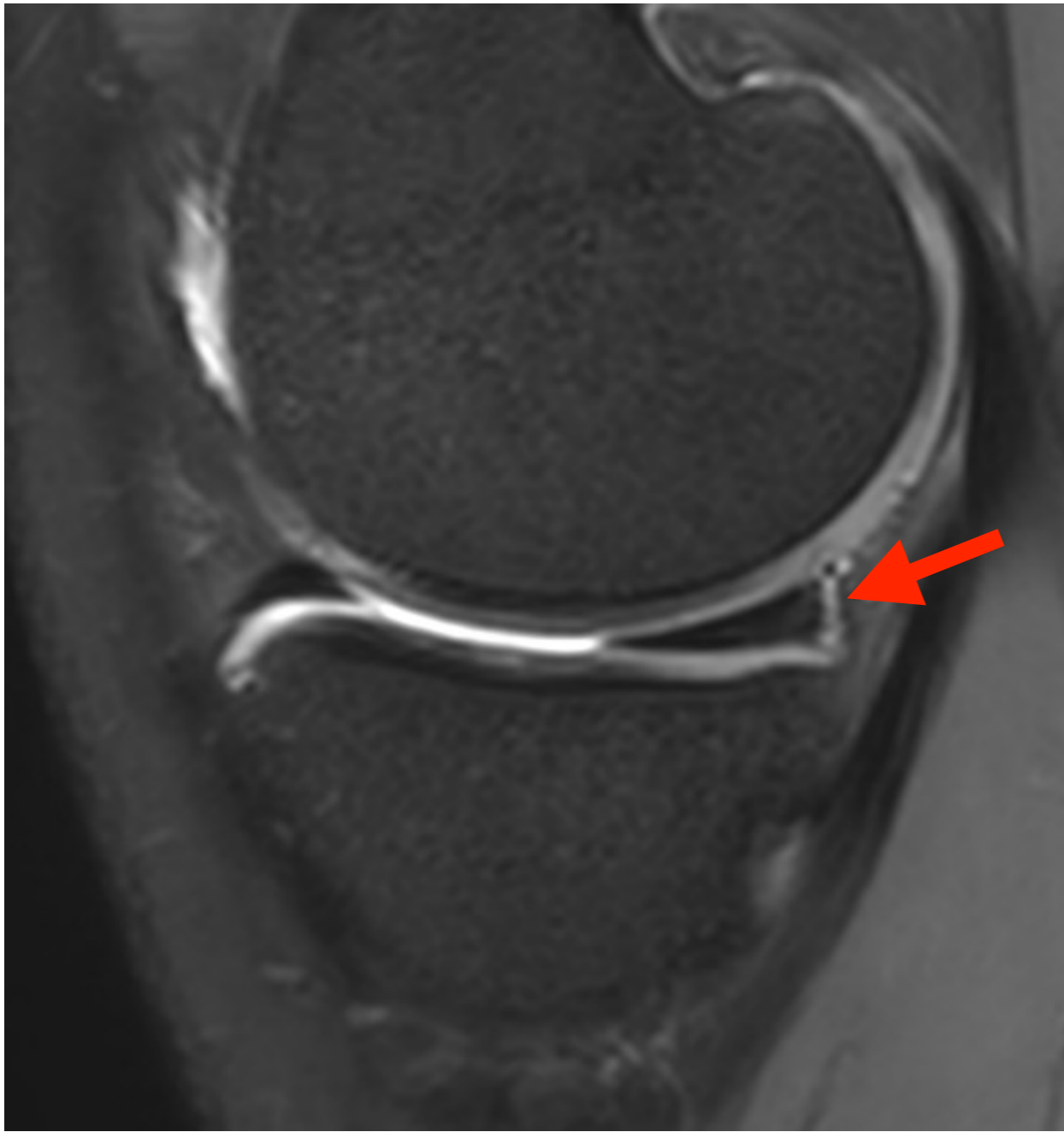

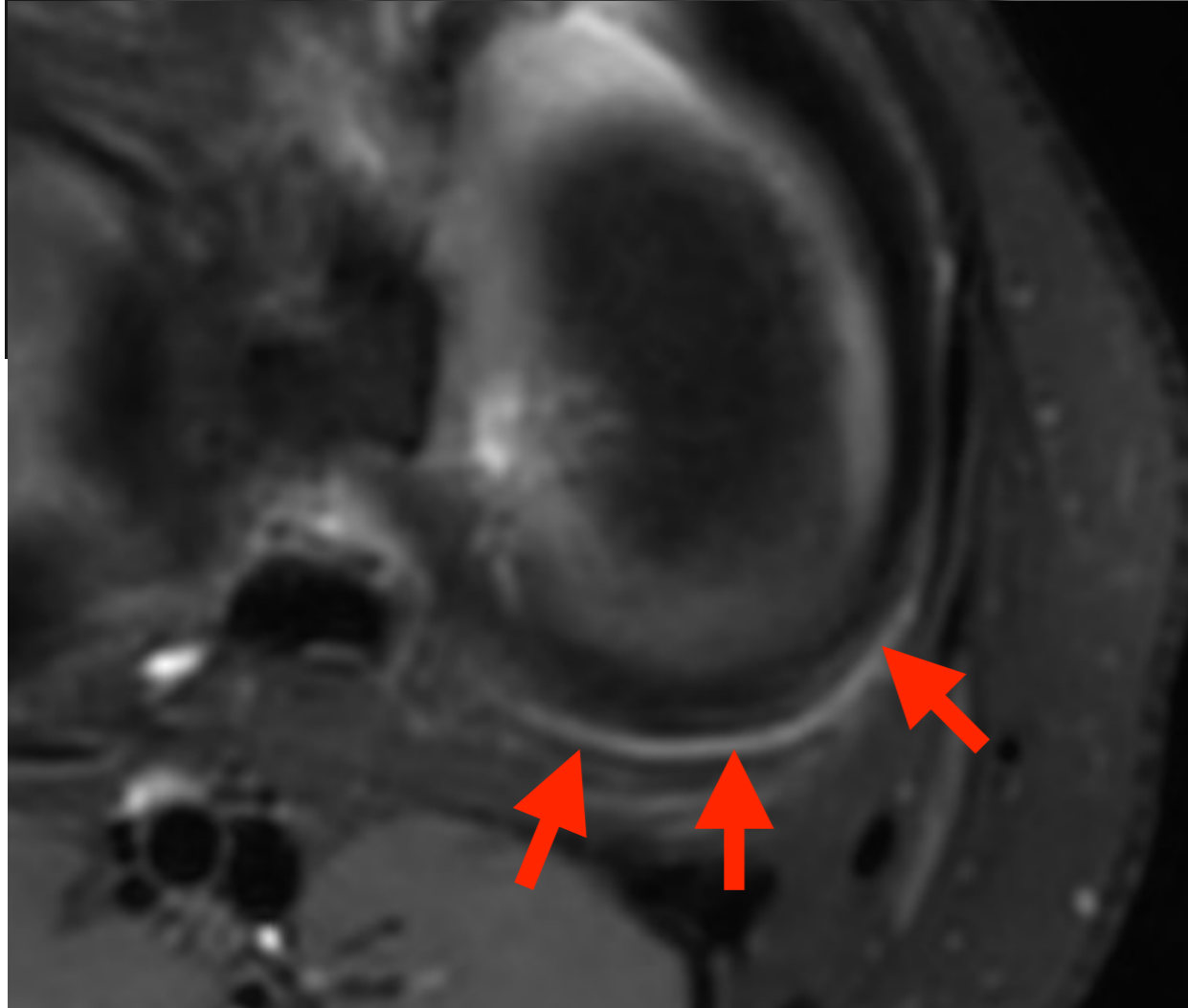
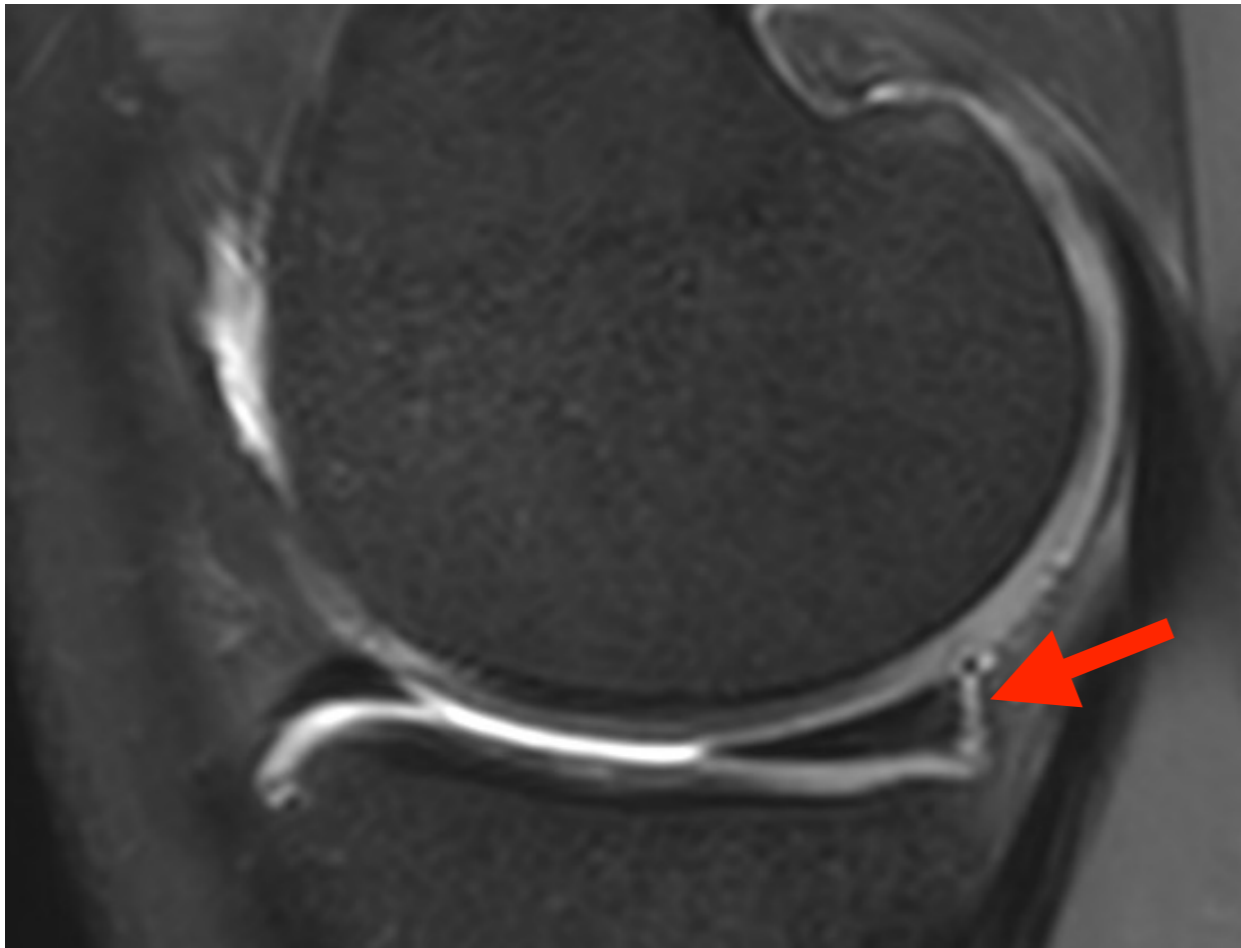
# 4. Ménisques

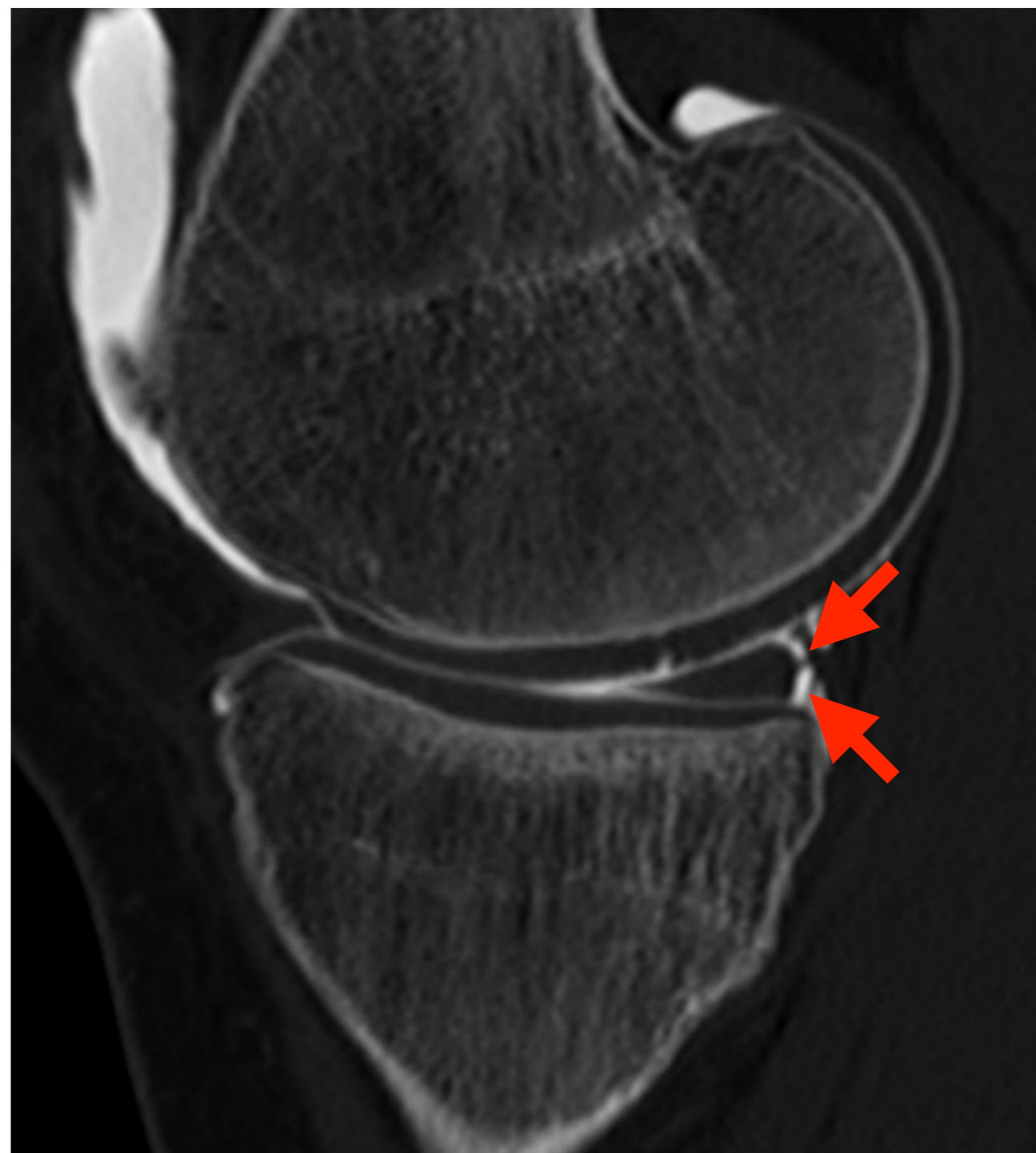
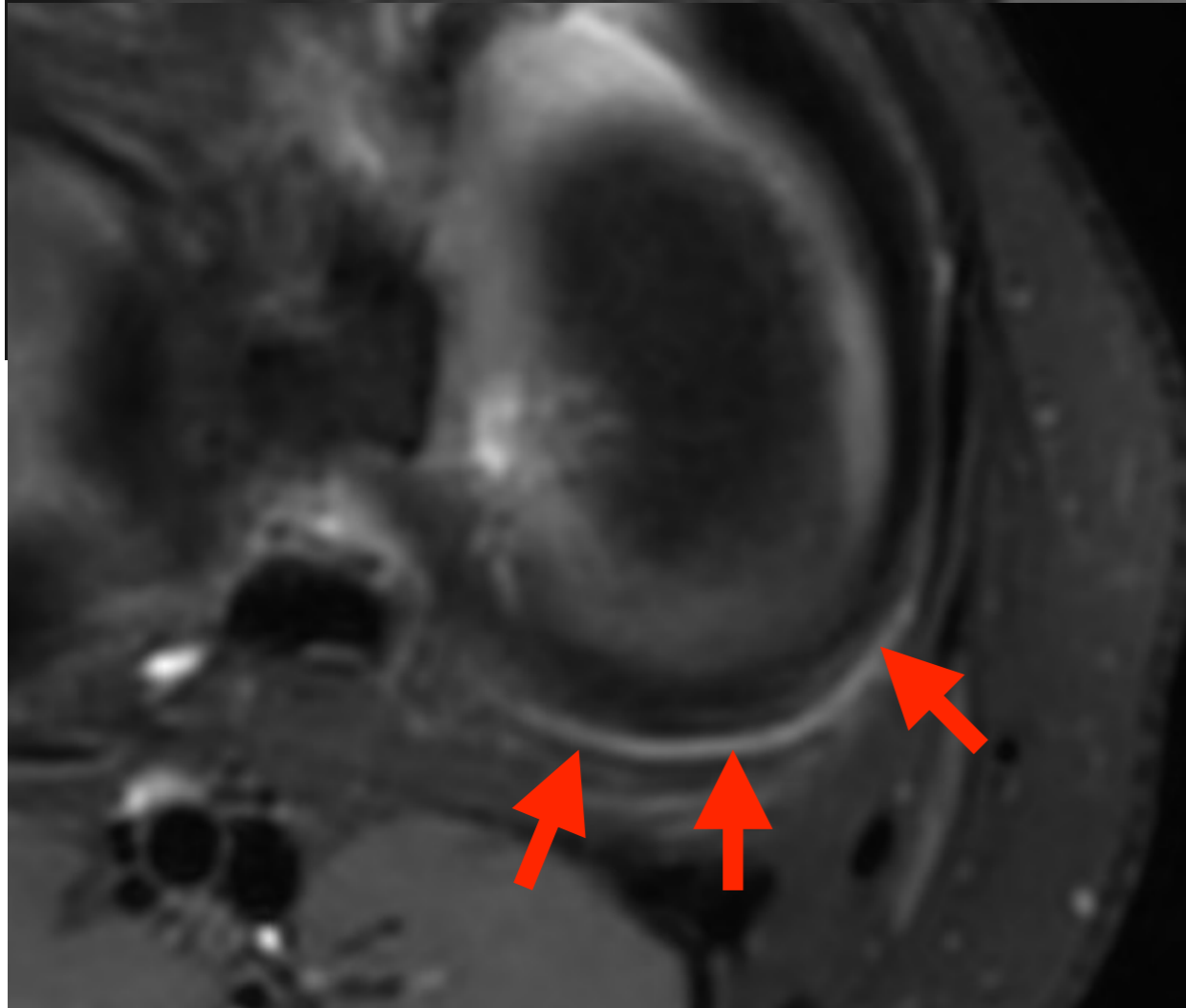
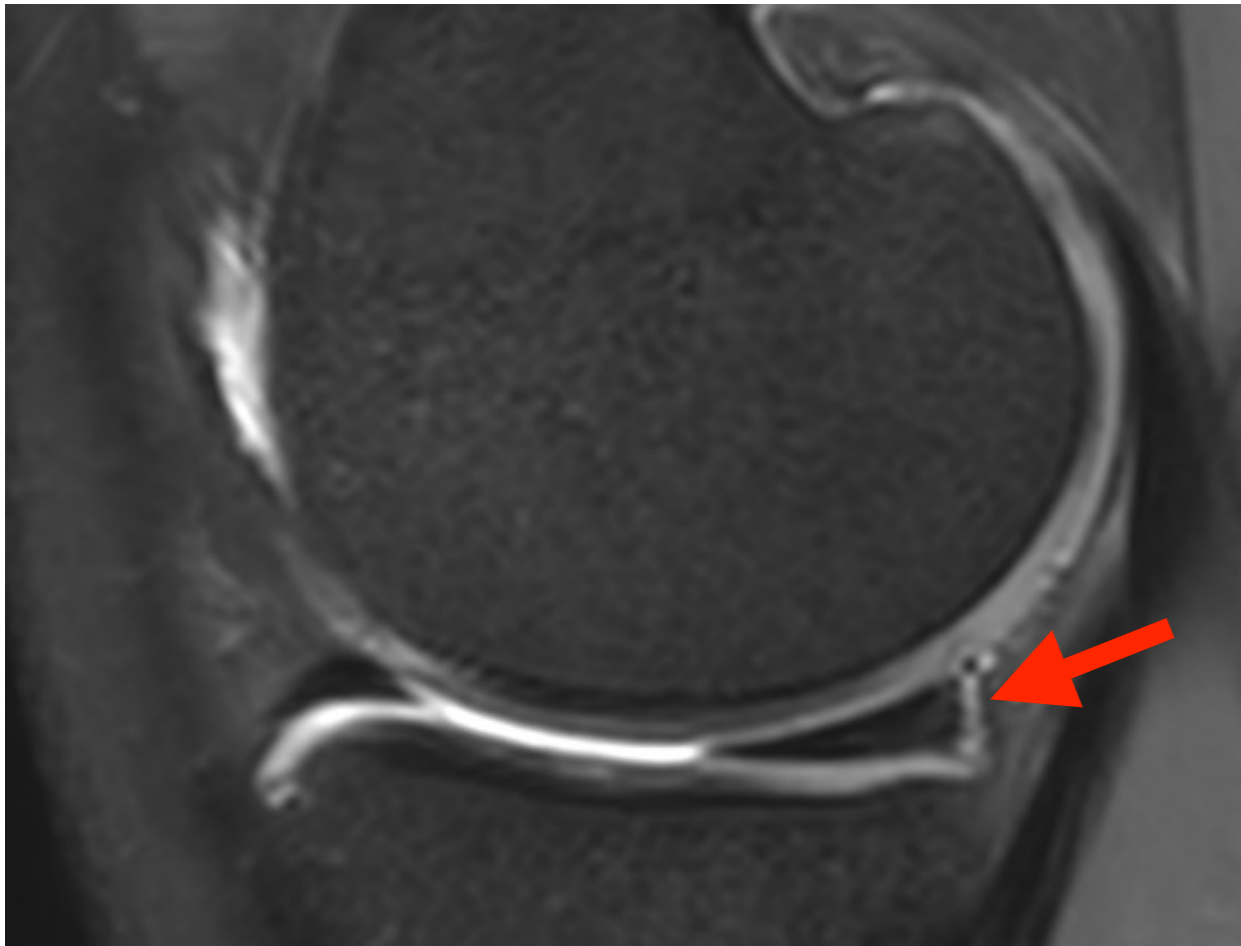


# 4. Ménisques





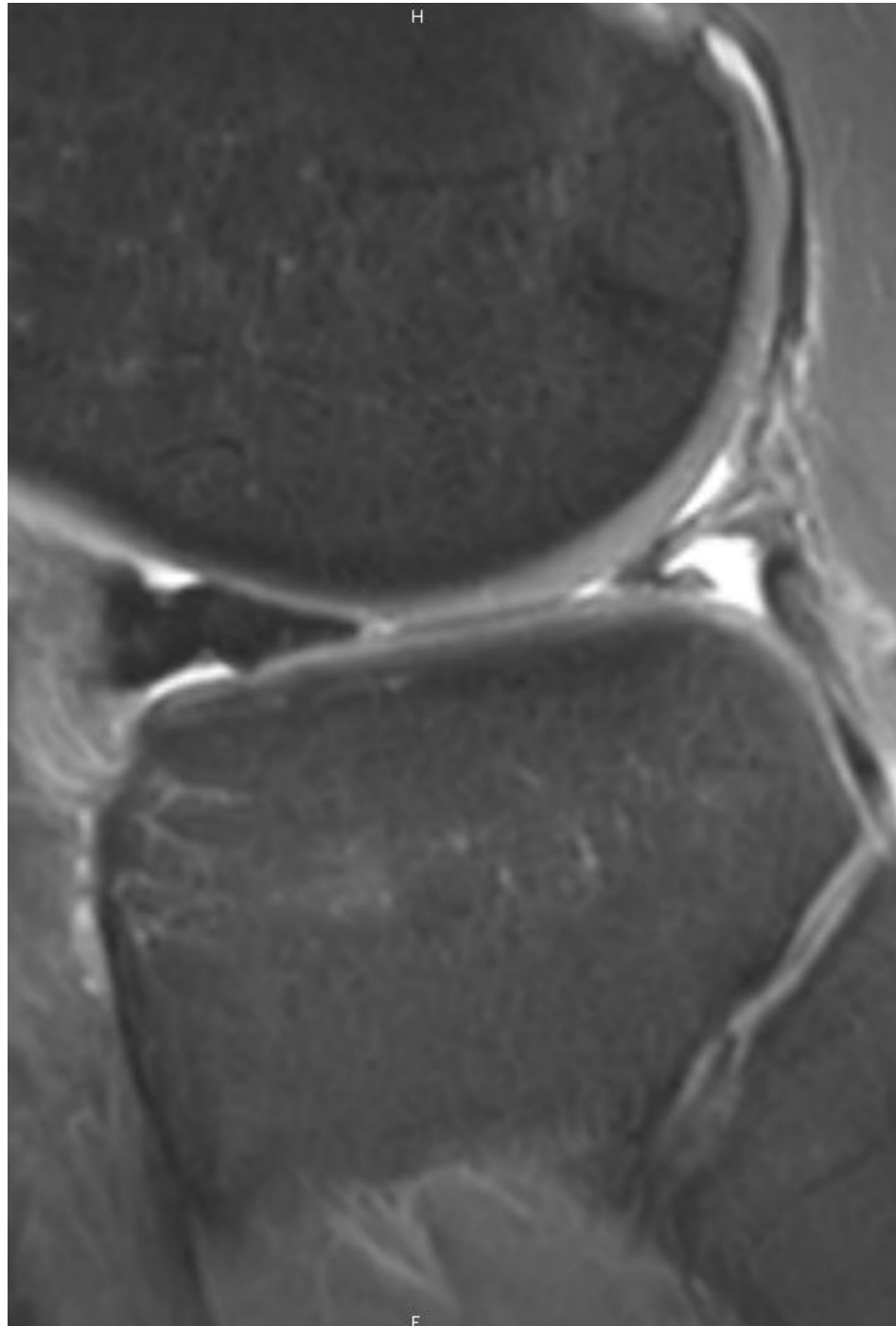




## 4. Ménisque Anse de seau

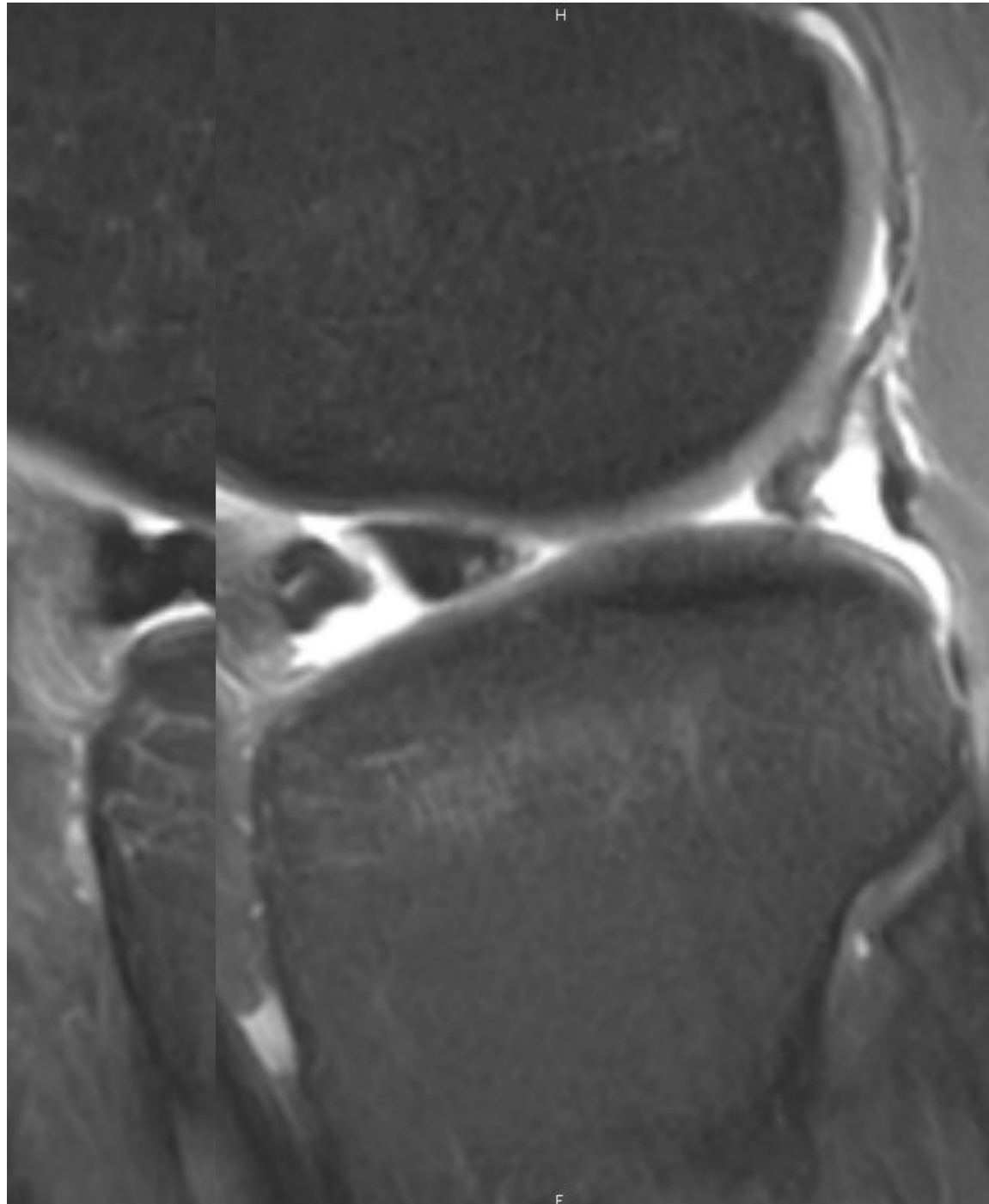
---

- Double corne antérieure



## 4. Ménisque Anse de seau

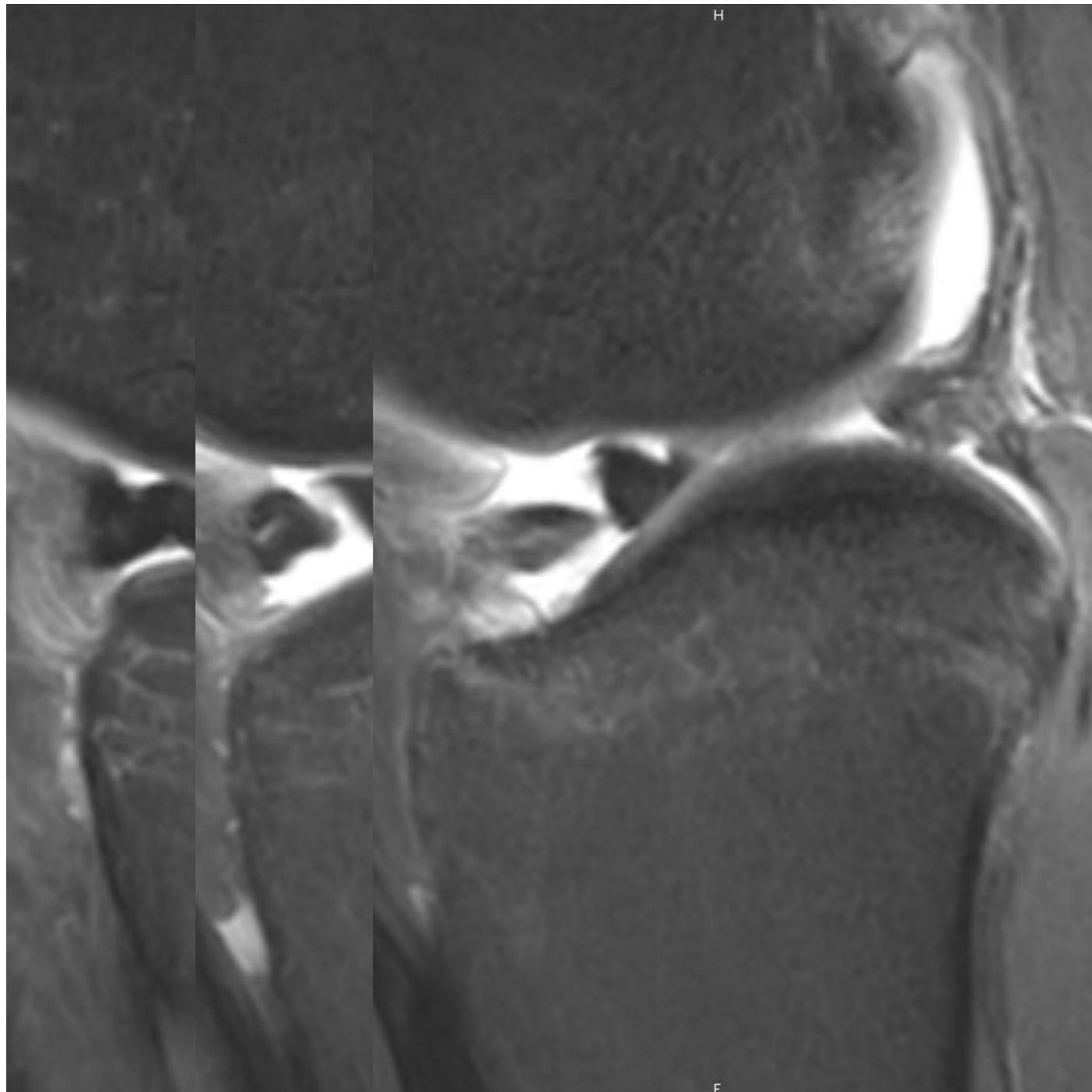
- Double corne antérieure





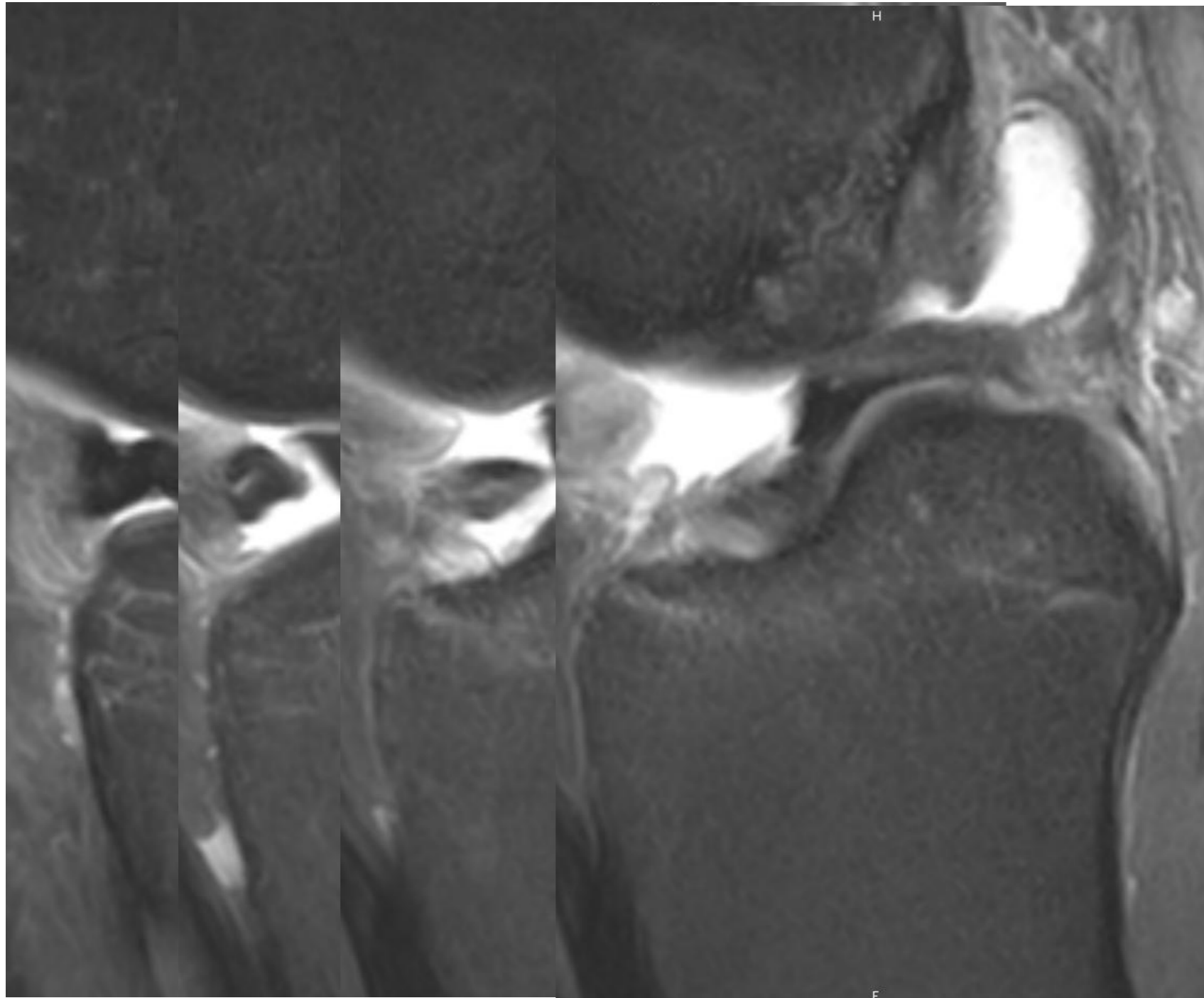
## 4. Ménisque Anse de seau

- Double corne antérieure



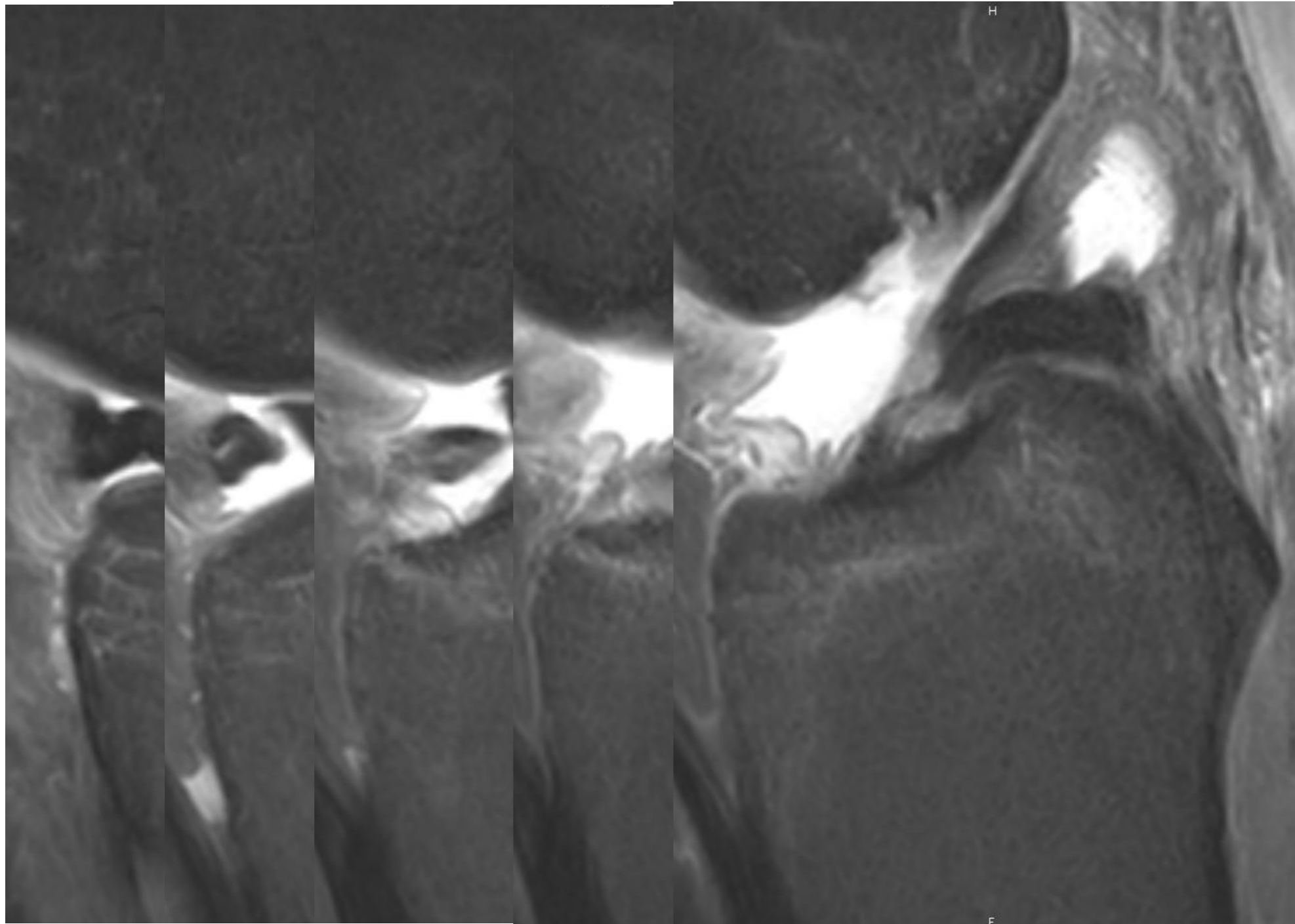
## 4. Ménisque Anse de seau

- Double corne antérieure



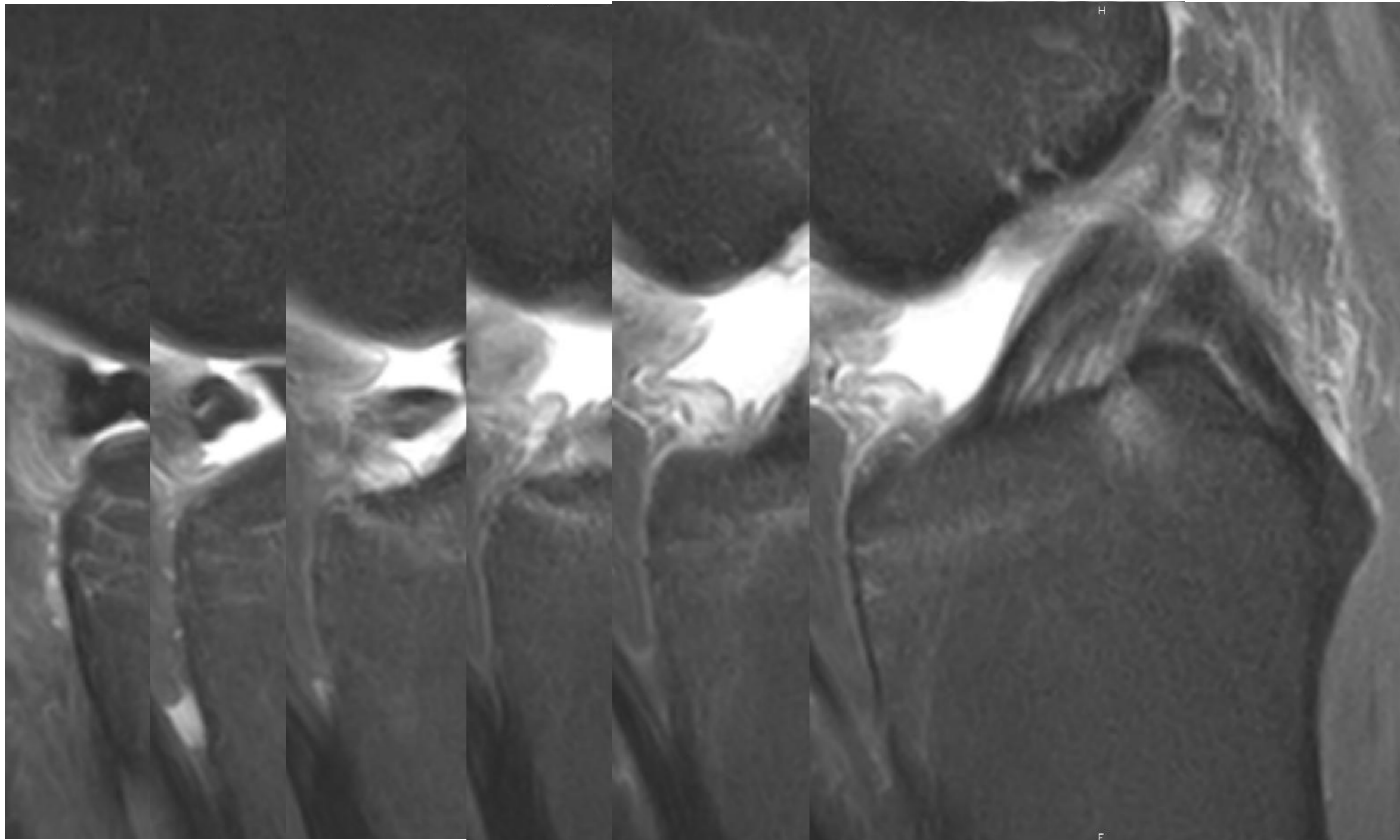
## 4. Ménisque Anse de seau

- Double corne antérieure



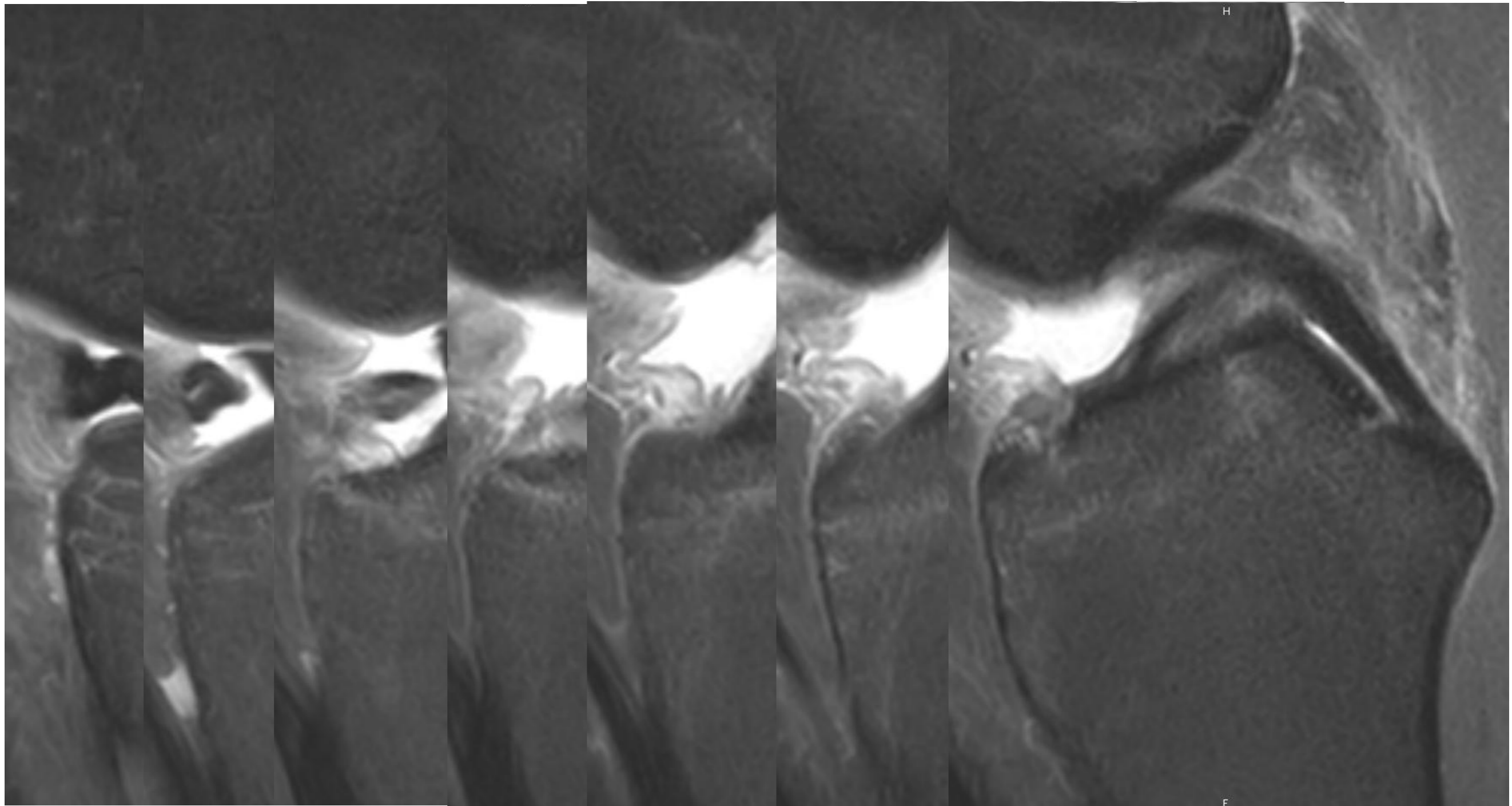
## 4. Ménisque Anse de seau

- Double corne antérieure



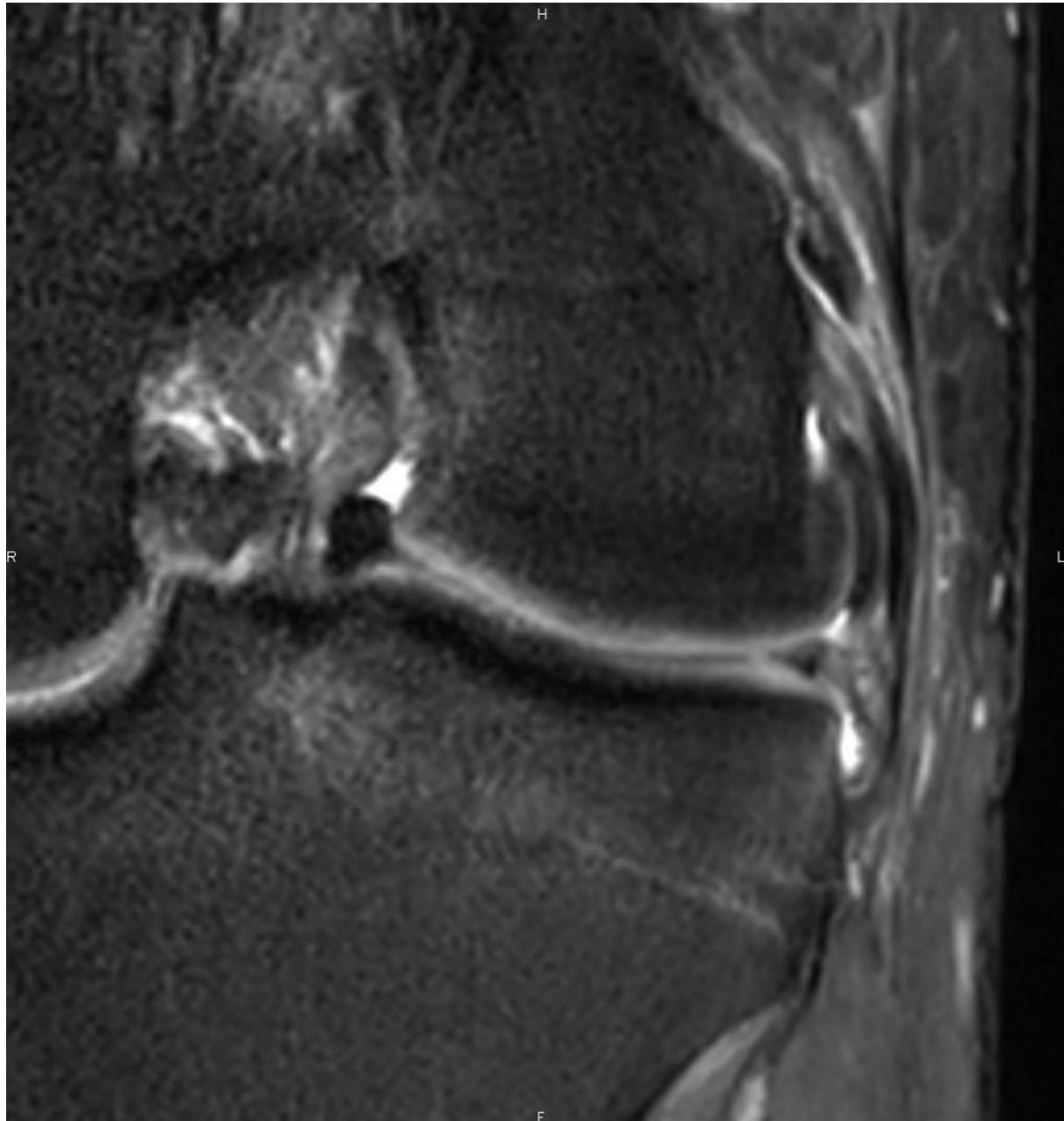
## 4. Ménisque Anse de seau

- Double corne antérieure



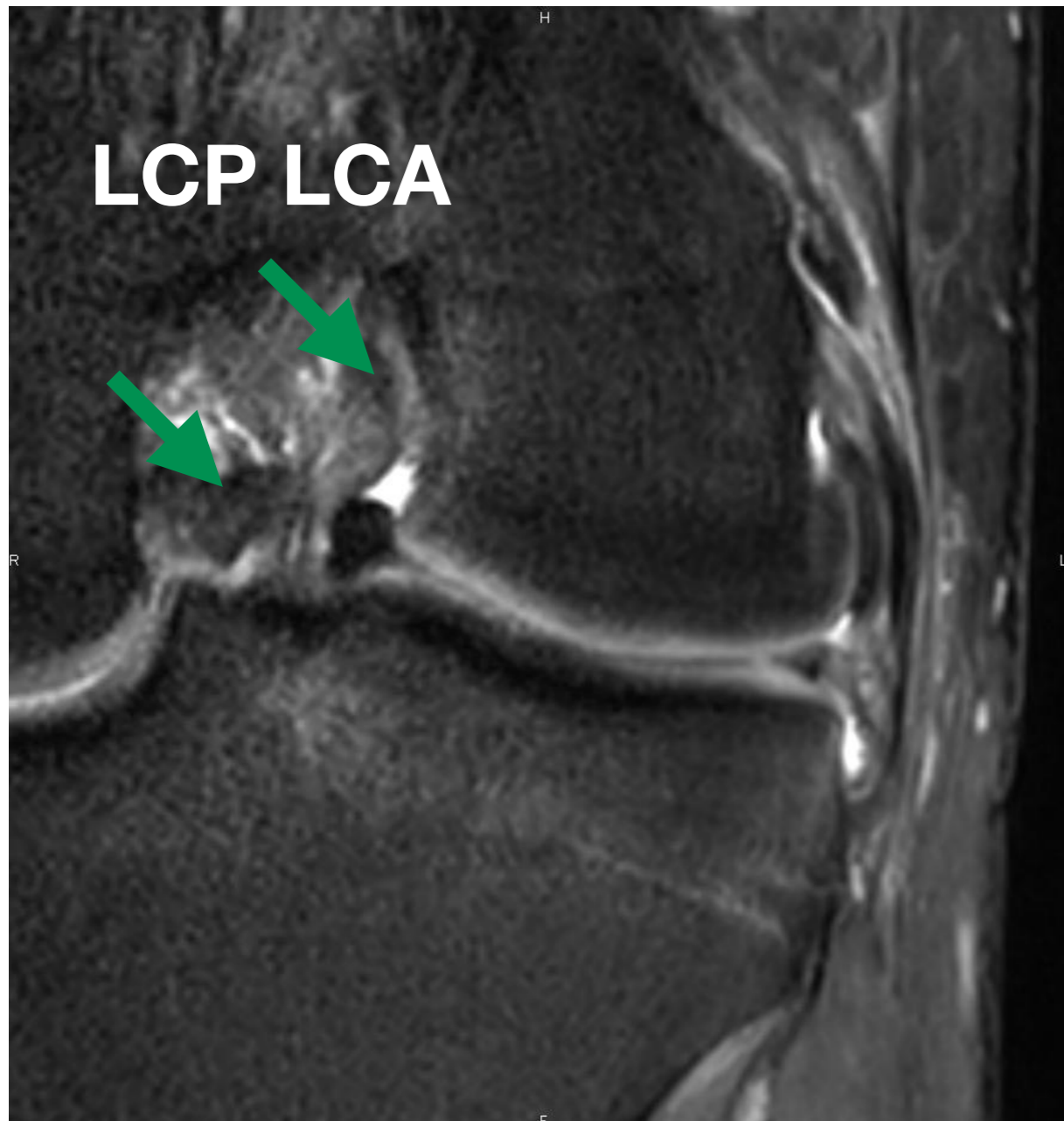
## 4. Ménisque Anse de seau

- Trio de l'échancrure



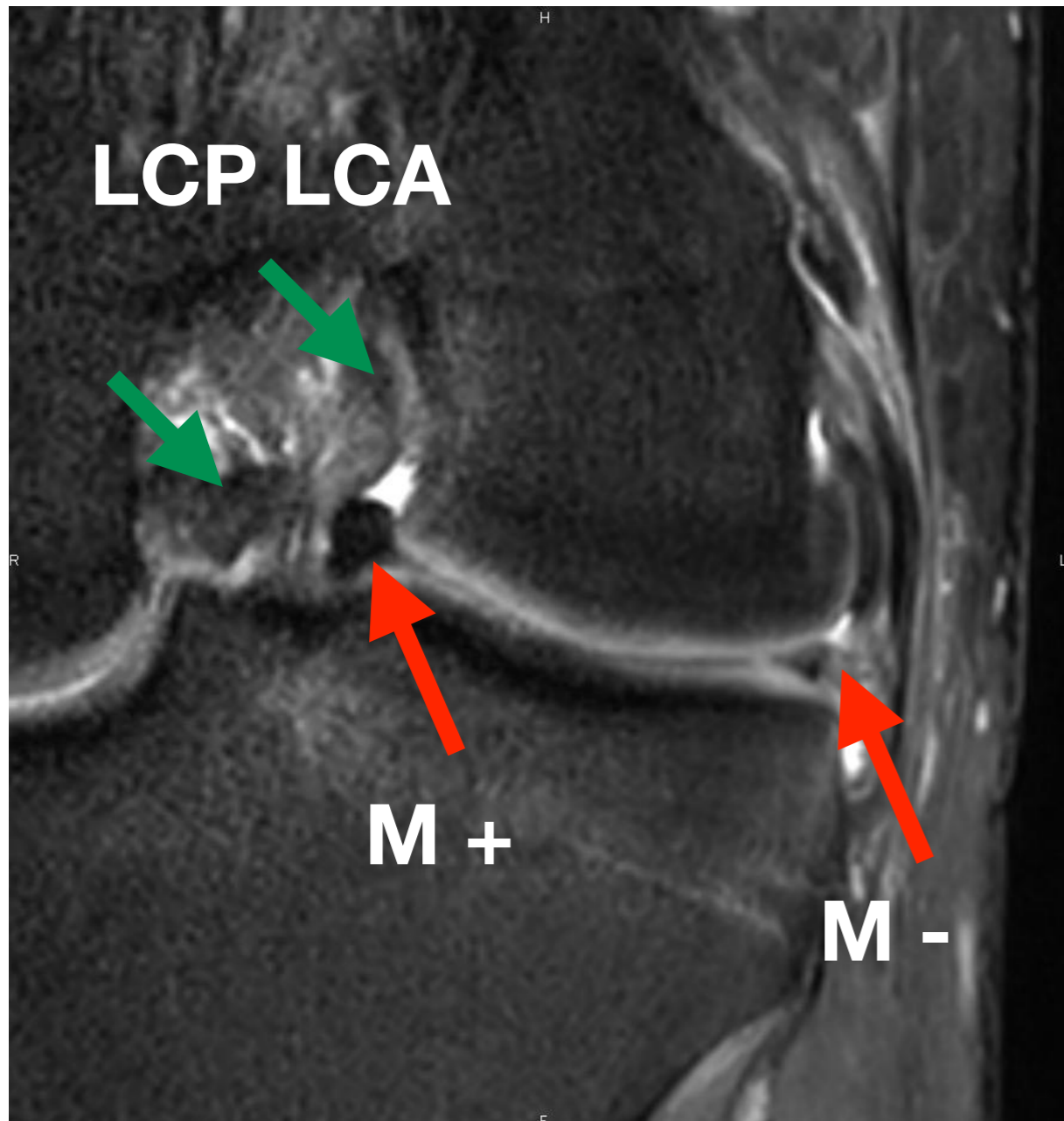
## 4. Ménisque Anse de seau

- Trio de l'échancrure



## 4. Ménisque Anse de seau

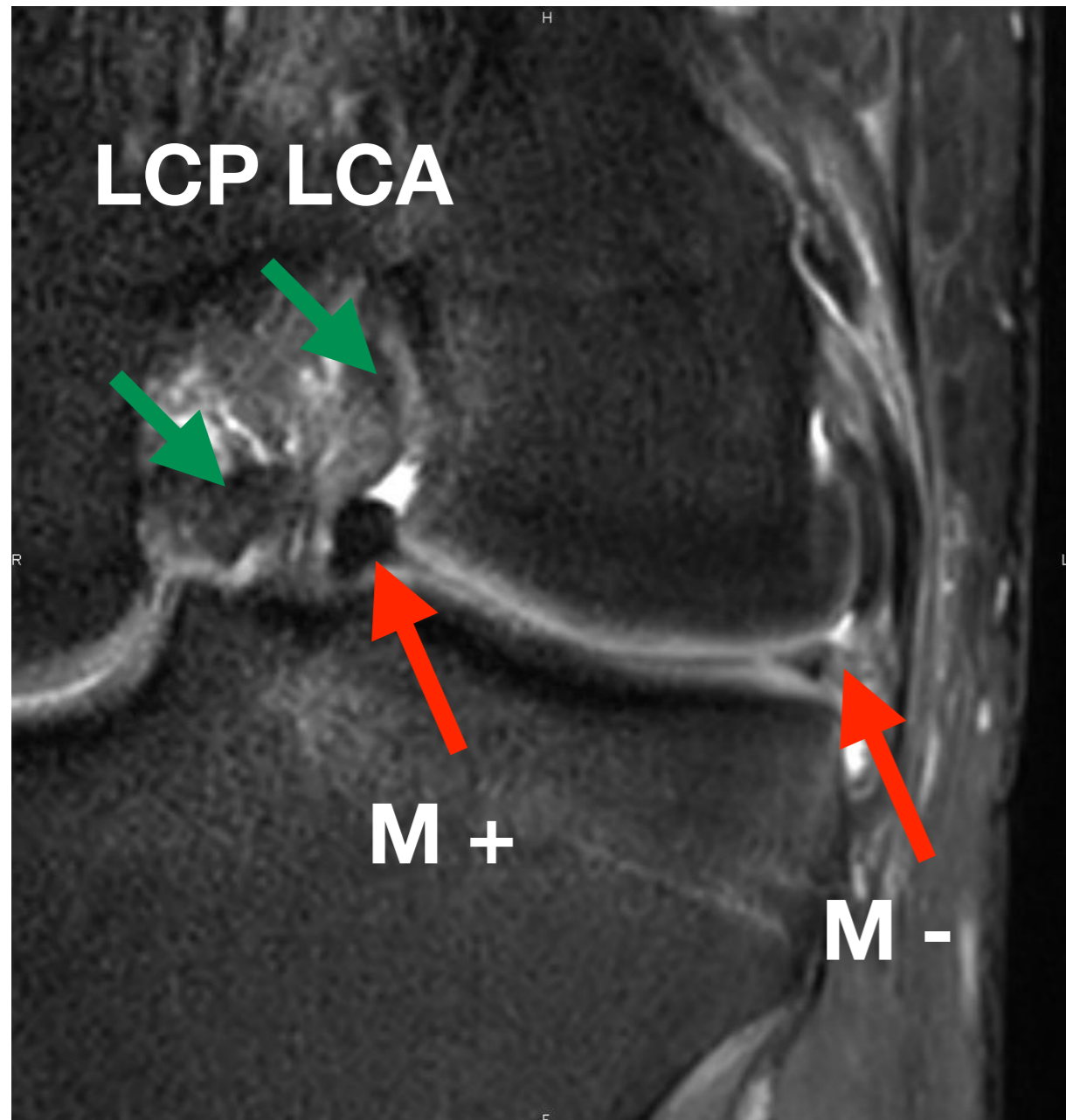
- Trio de l'échancrure



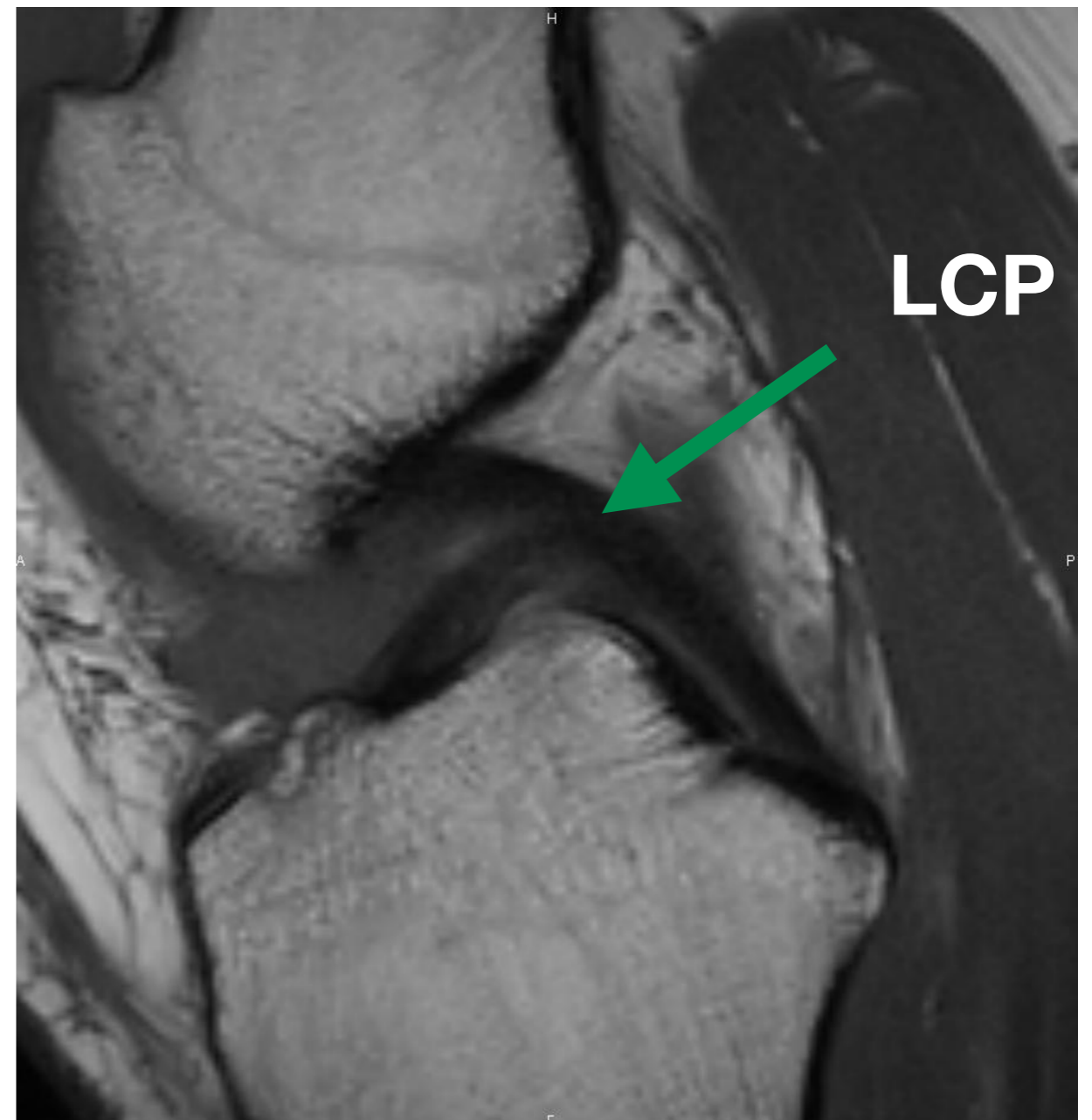


## 4. Ménisque Anse de seau

- Trio de l'échancrure

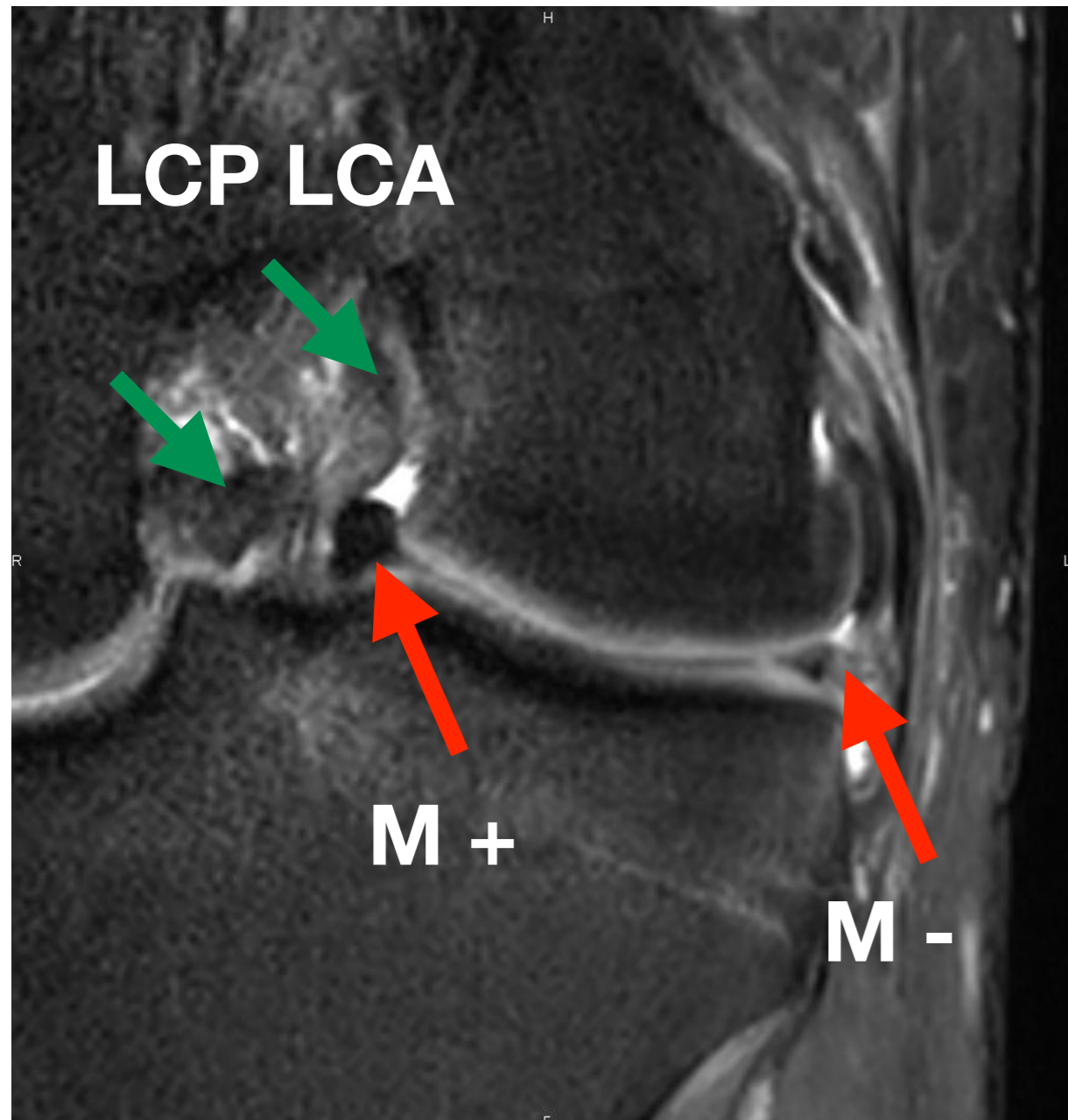


- Double LCP

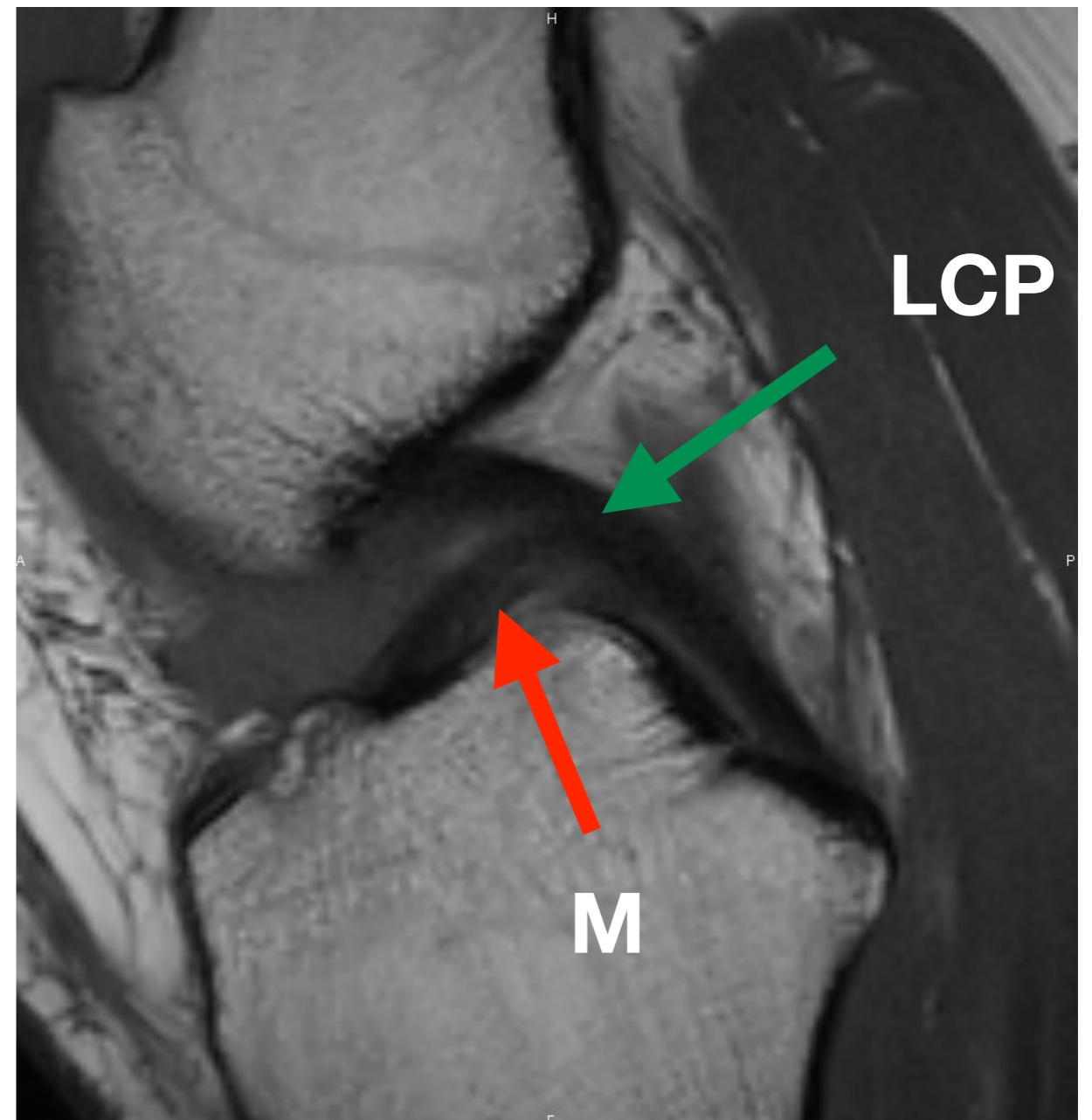


## 4. Ménisque Anse de seau

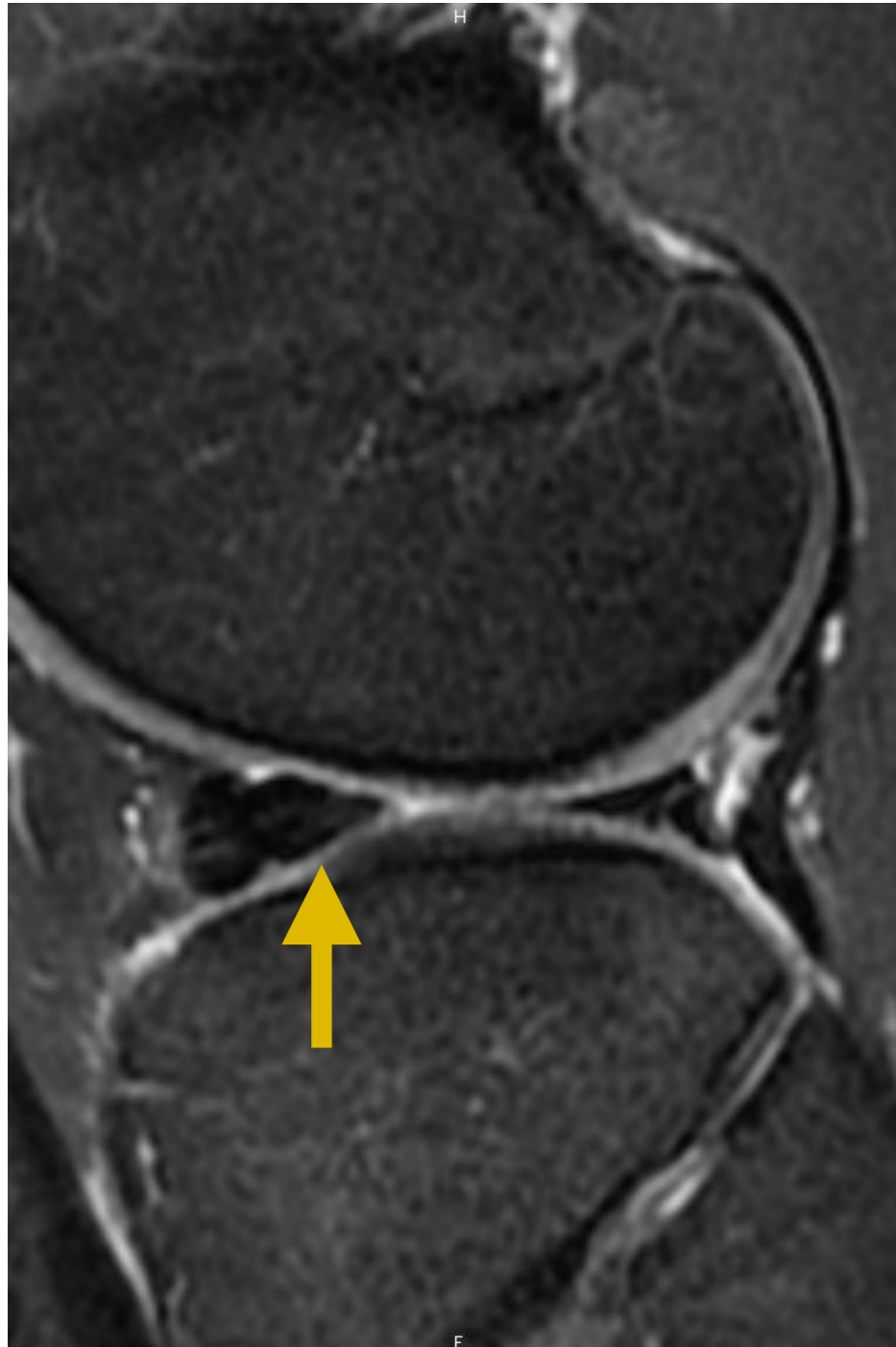
- Trio de l'échancrure



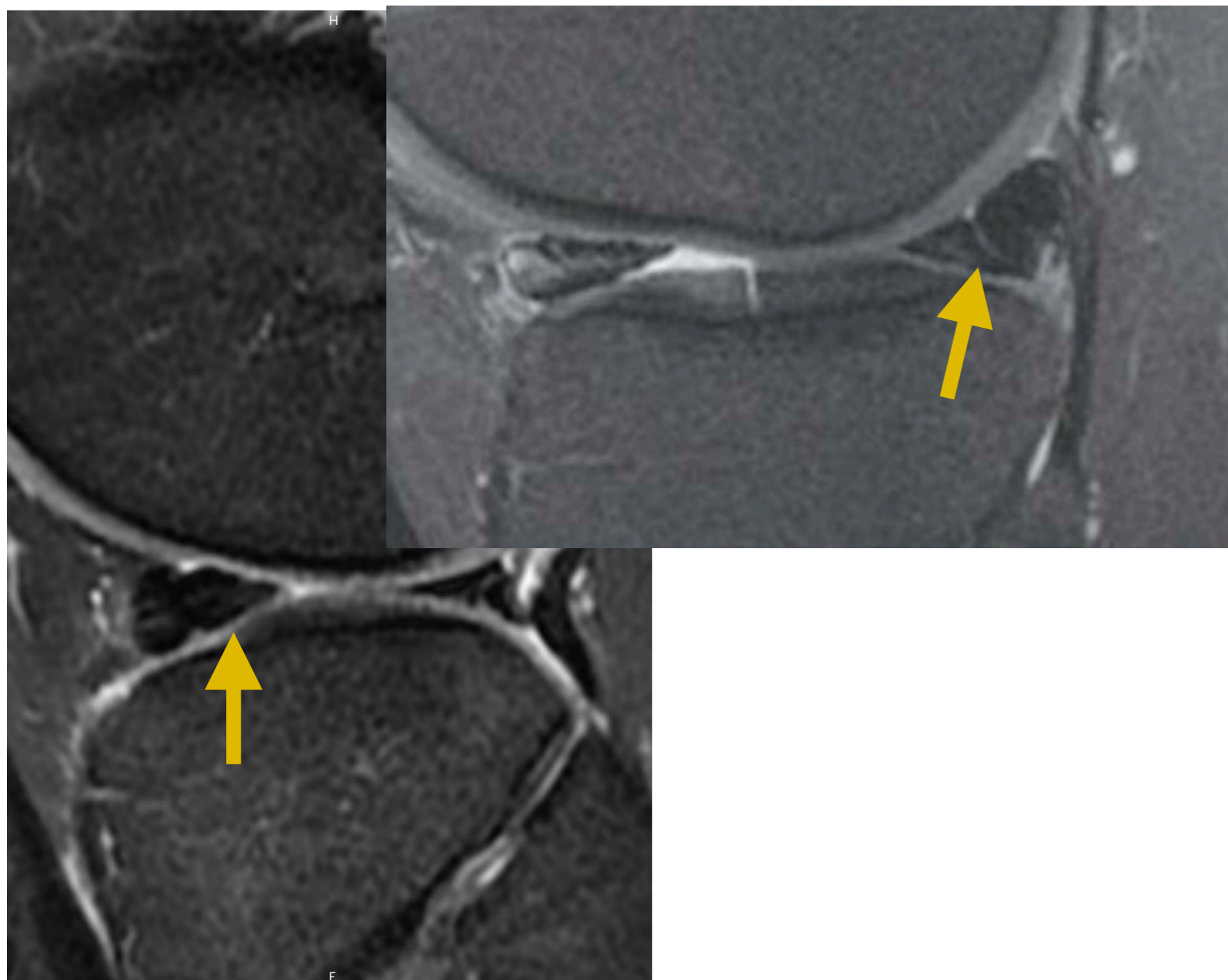
- Double LCP



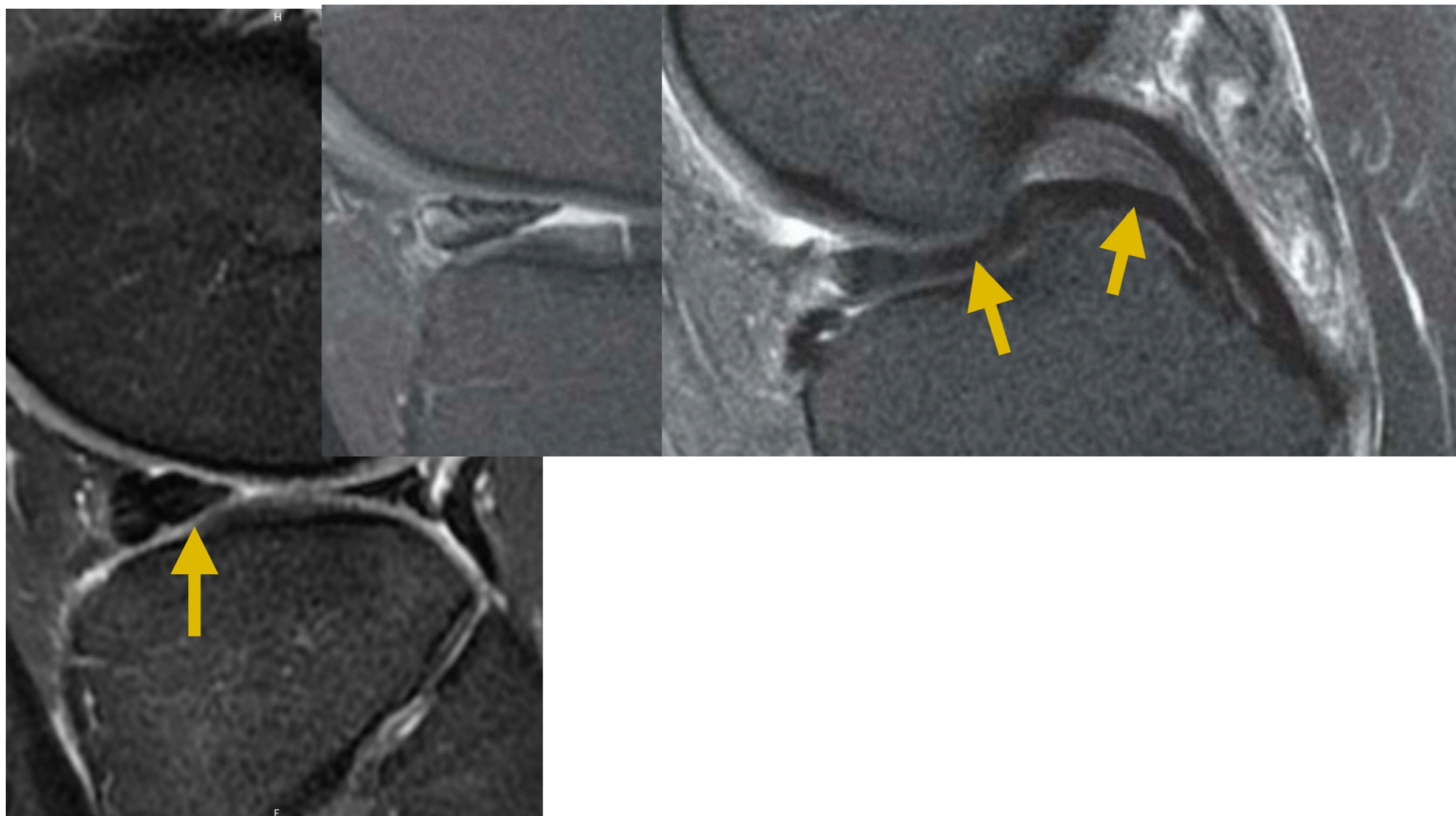
## 4. Ménisque Anse de seau



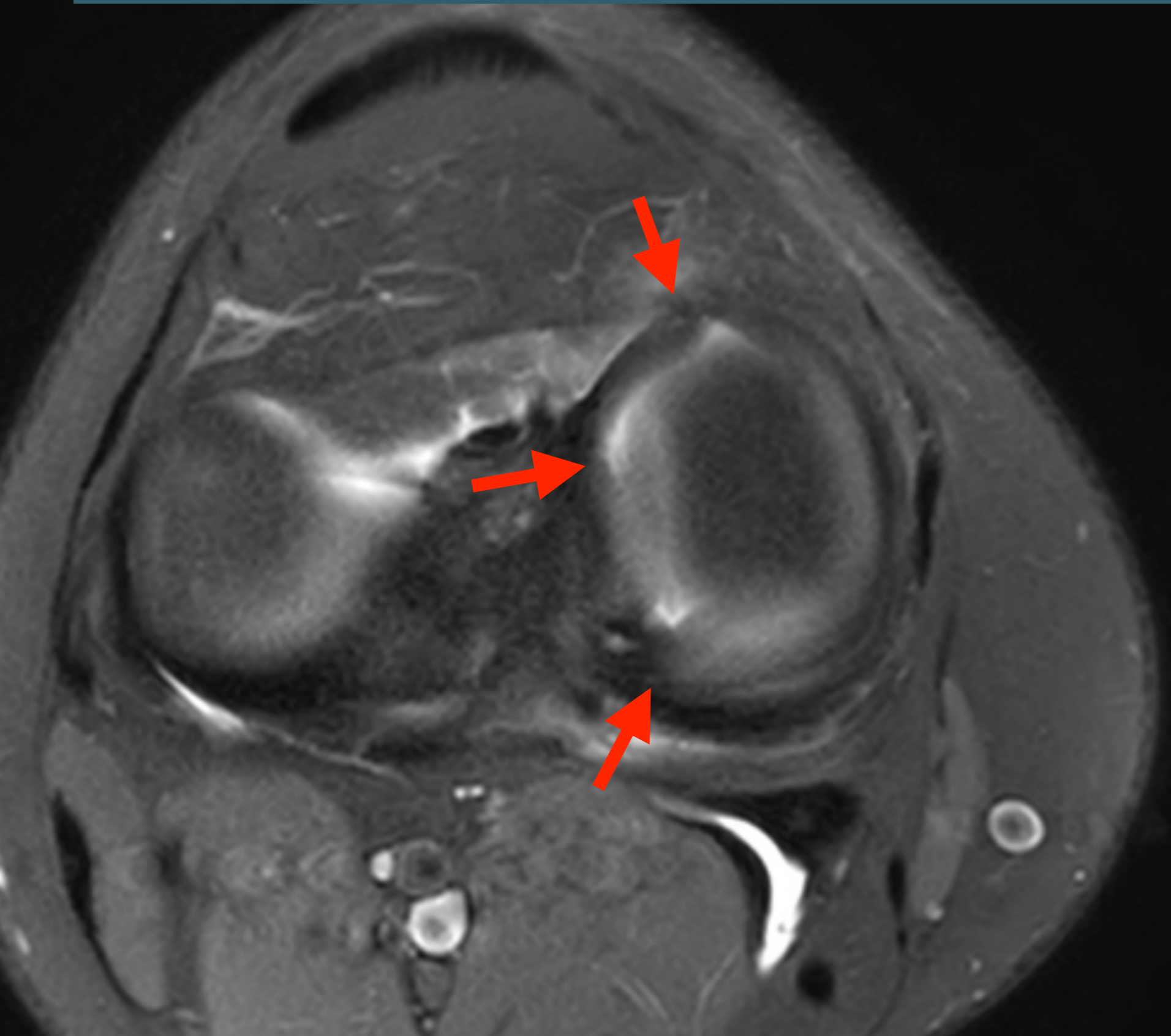
## 4. Ménisque Anse de seau



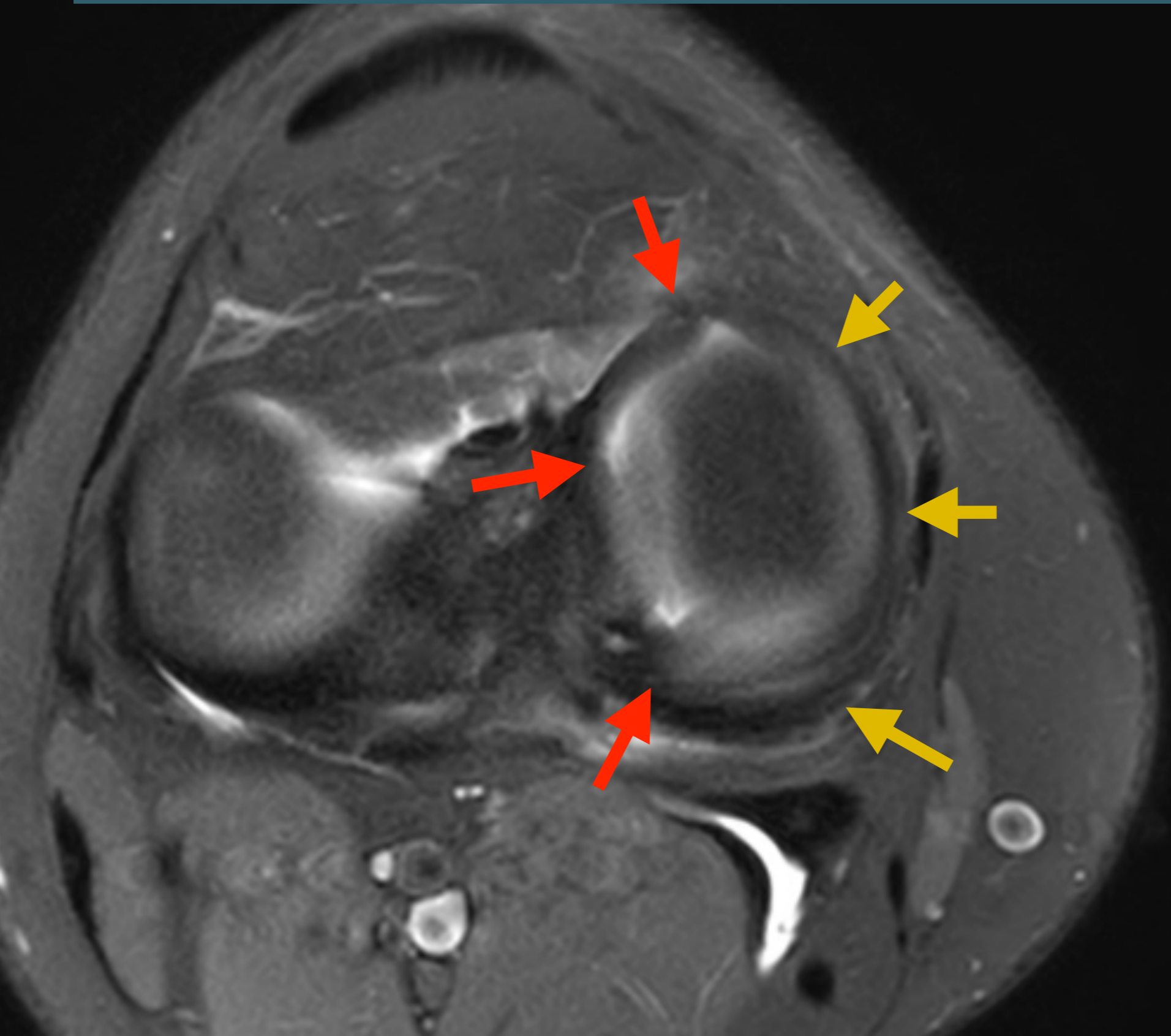
## 4. Ménisque Anse de seau



## 4. Ménisque Anse de seau



## 4. Ménisque Anse de seau



## 4. Languelette méniscale

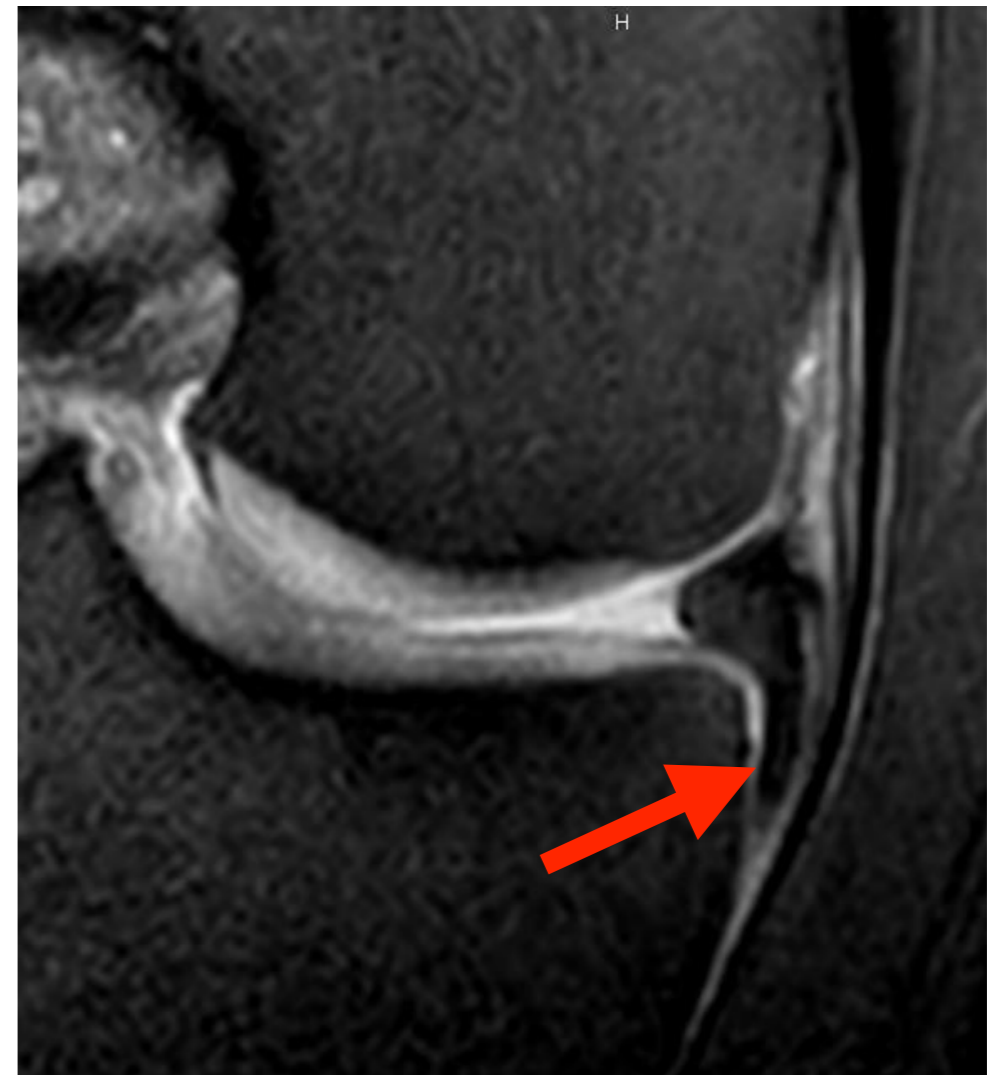- Fragment méniscal
  - Déplacé
  - Mais attaché par une extrémité
  - Base d'implantation large
  - Base fine





# 4. Languelette méniscale

- Fragment méniscal
  - Déplacé
  - Mais attaché par une extrémité
  - Base d'implantation large
  - Base fine



# 4. Languelette méniscale

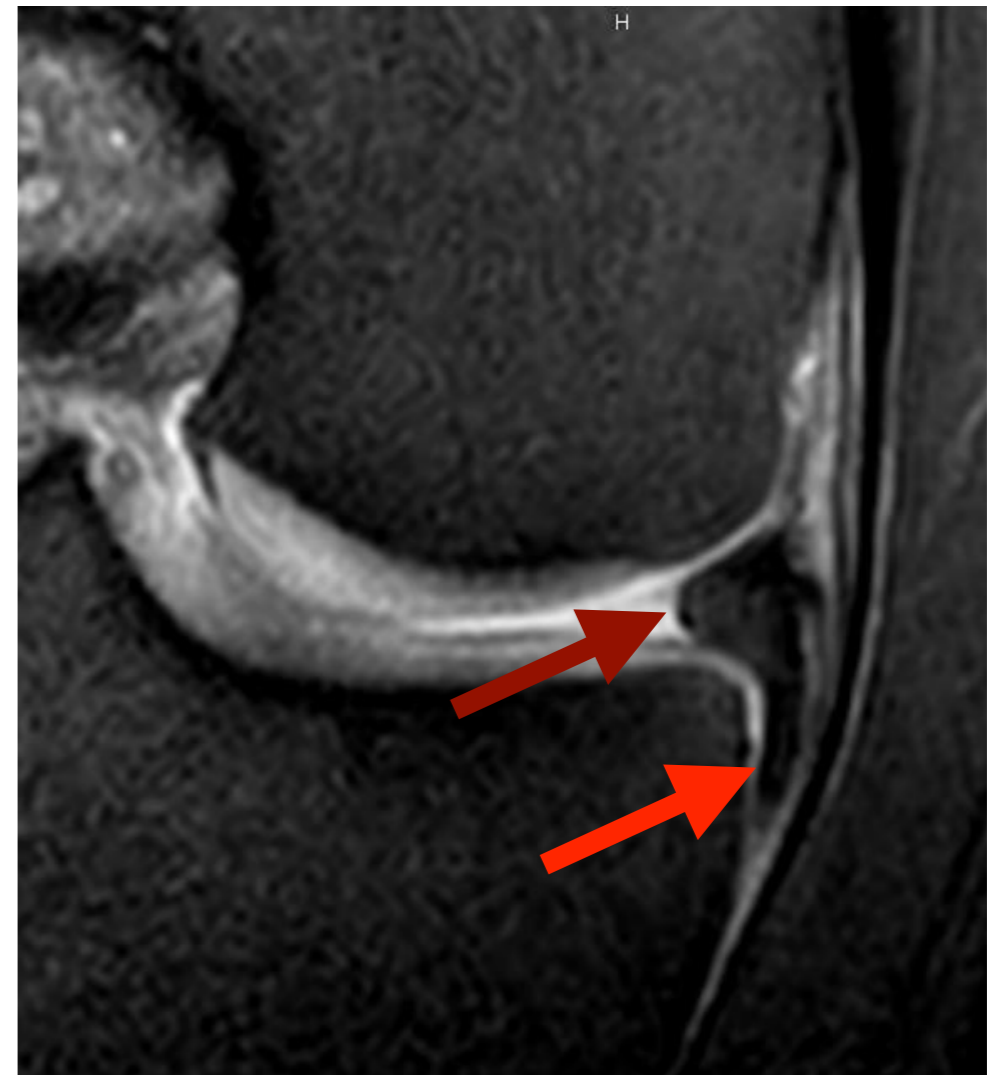
- Fragment méniscal

- Déplacé

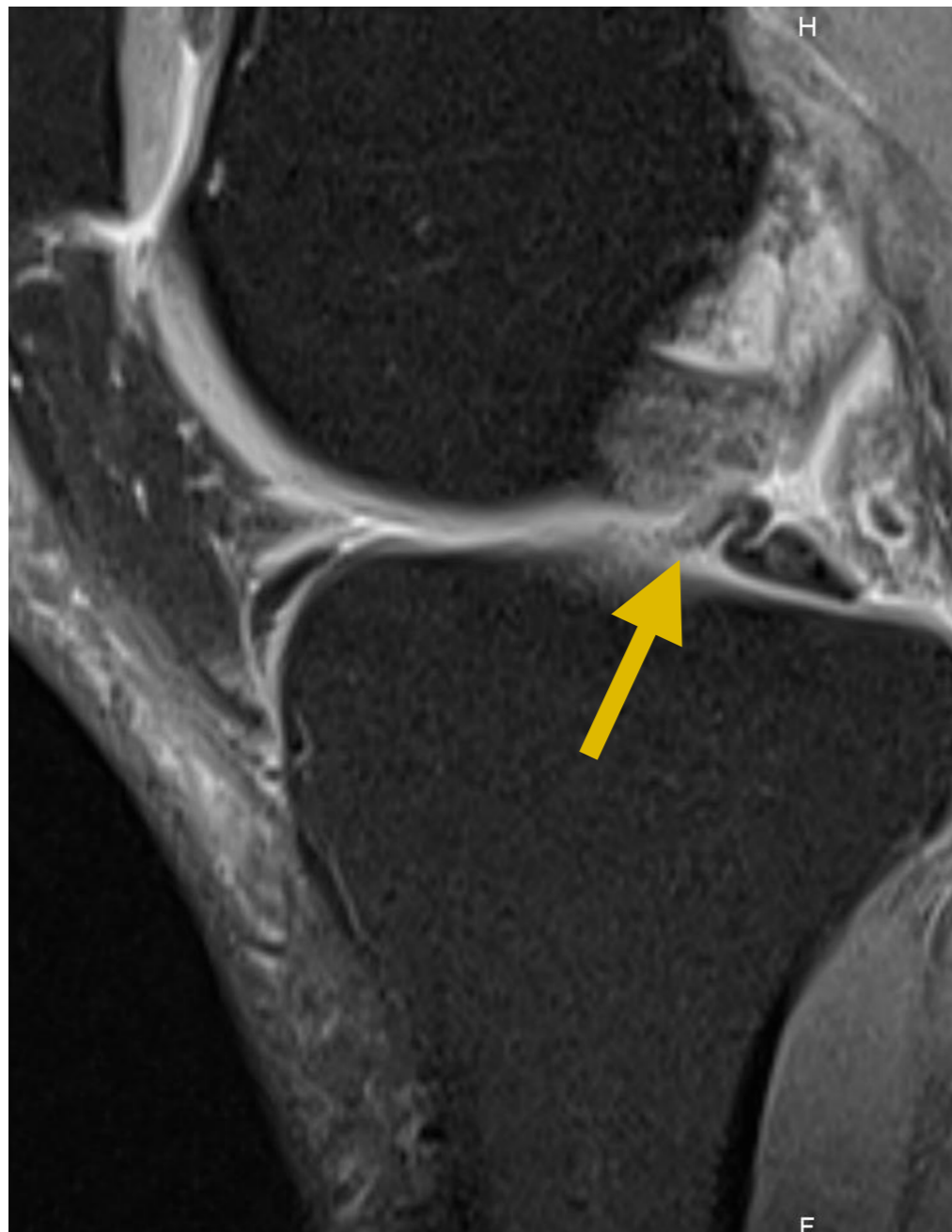
- Mais attaché par une extrémité

- Base d'implantation large

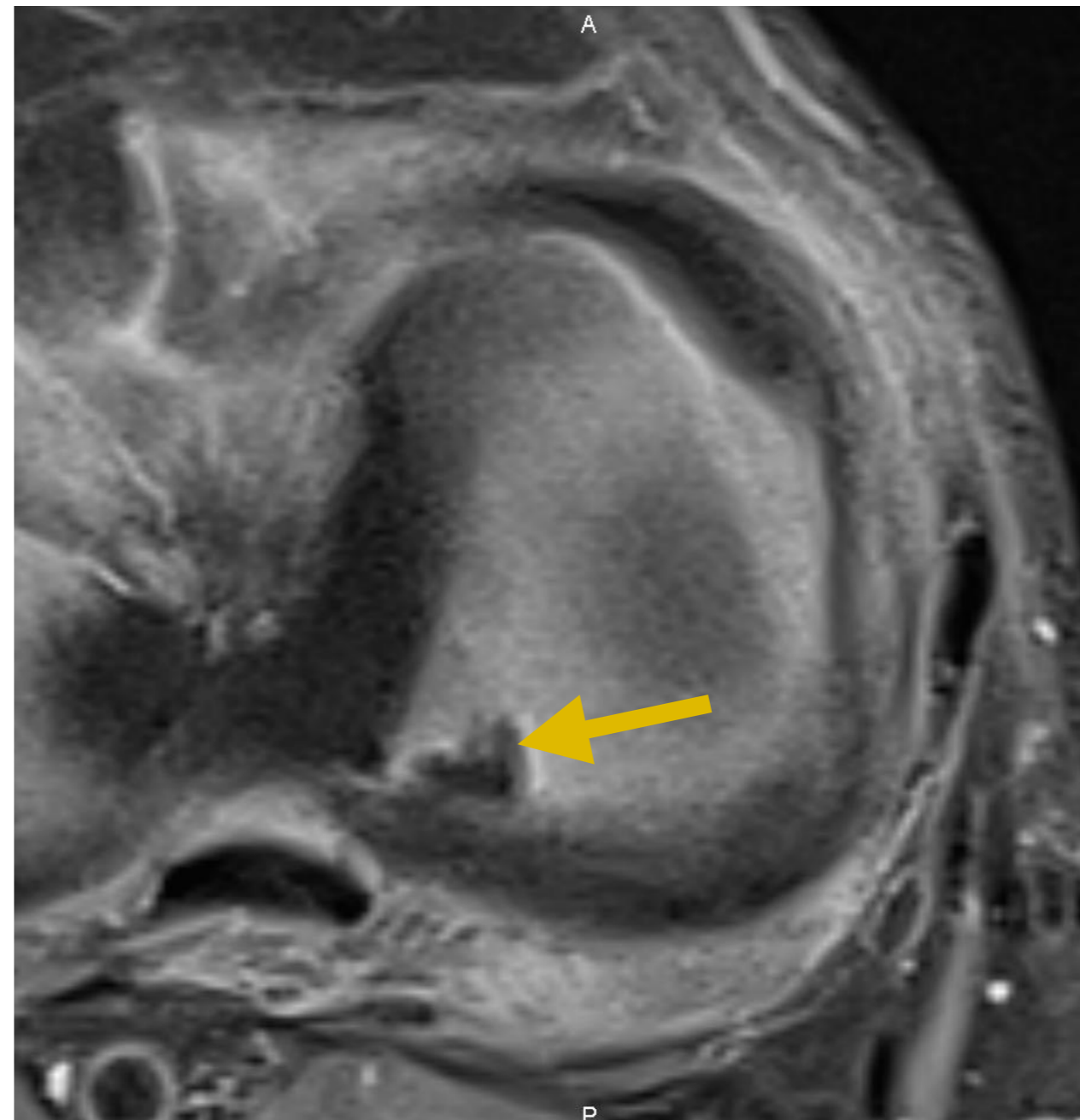
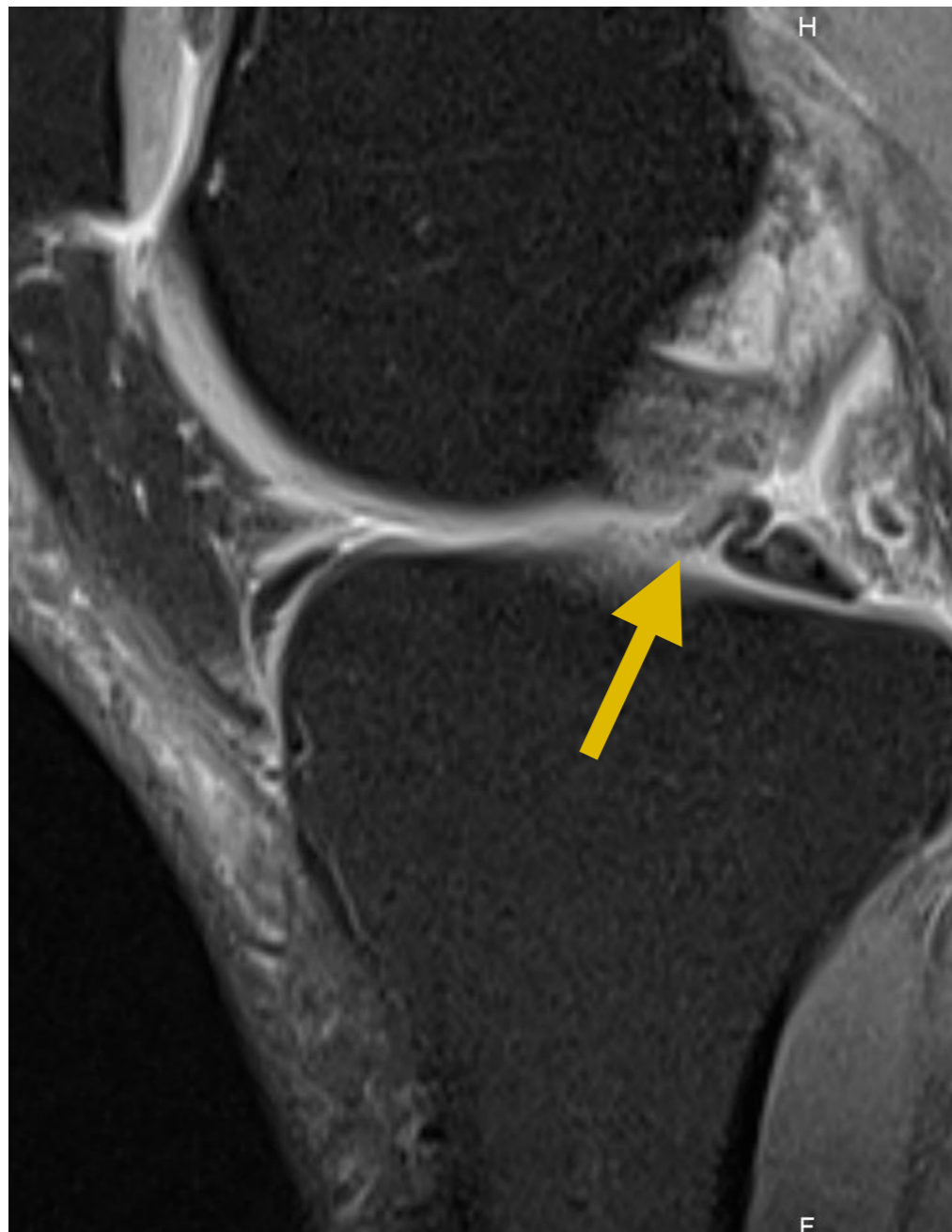
- Base fine



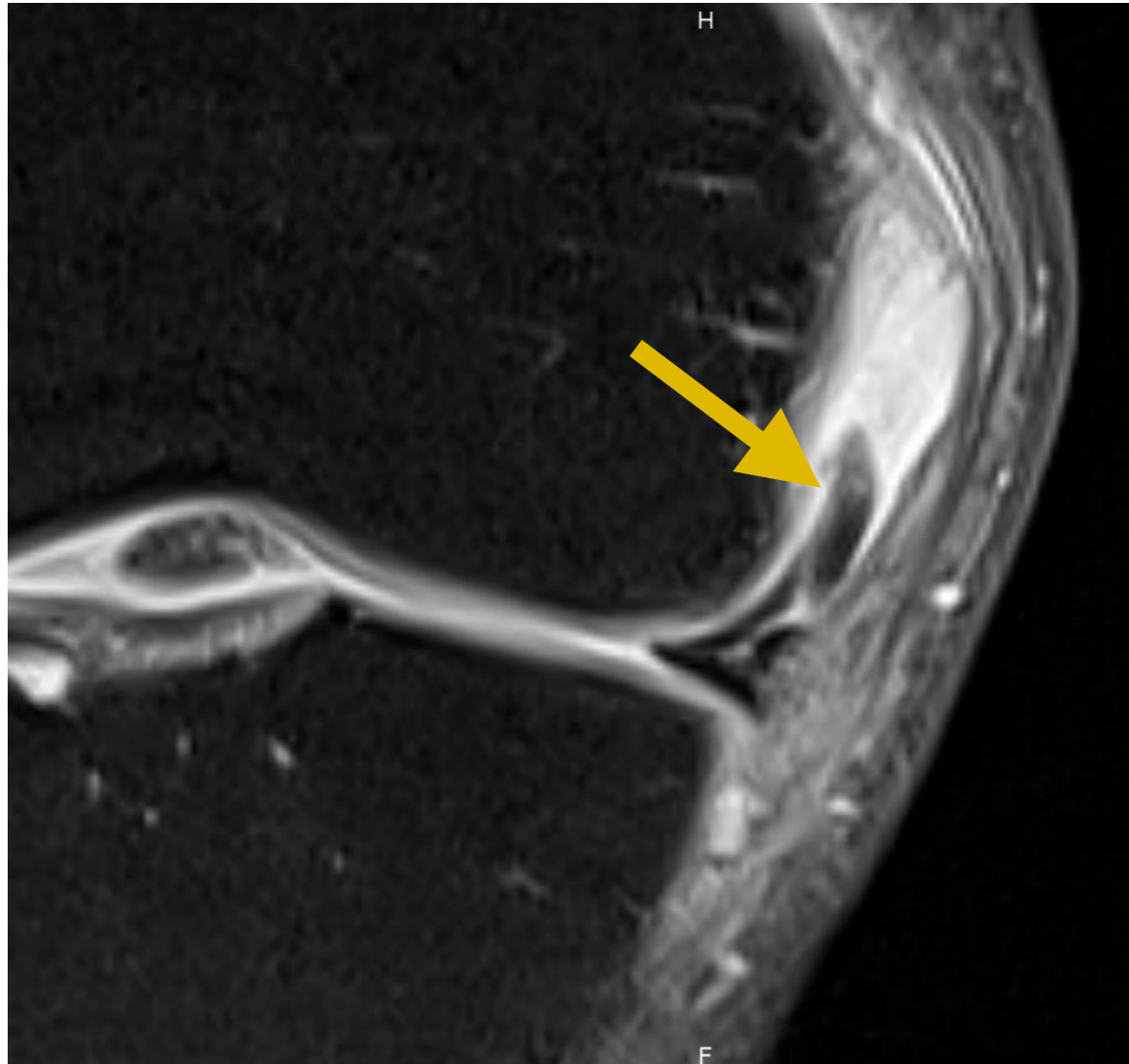
## 4. Langnette méniscale



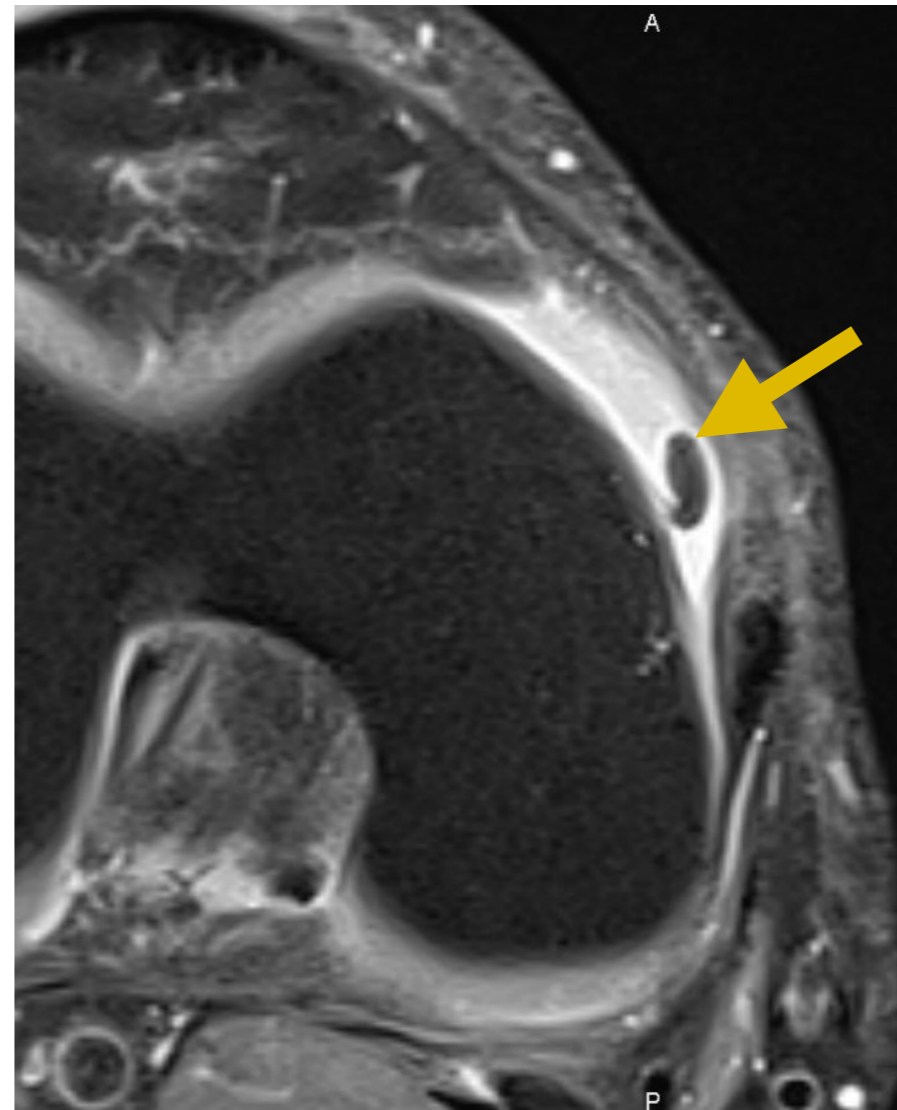
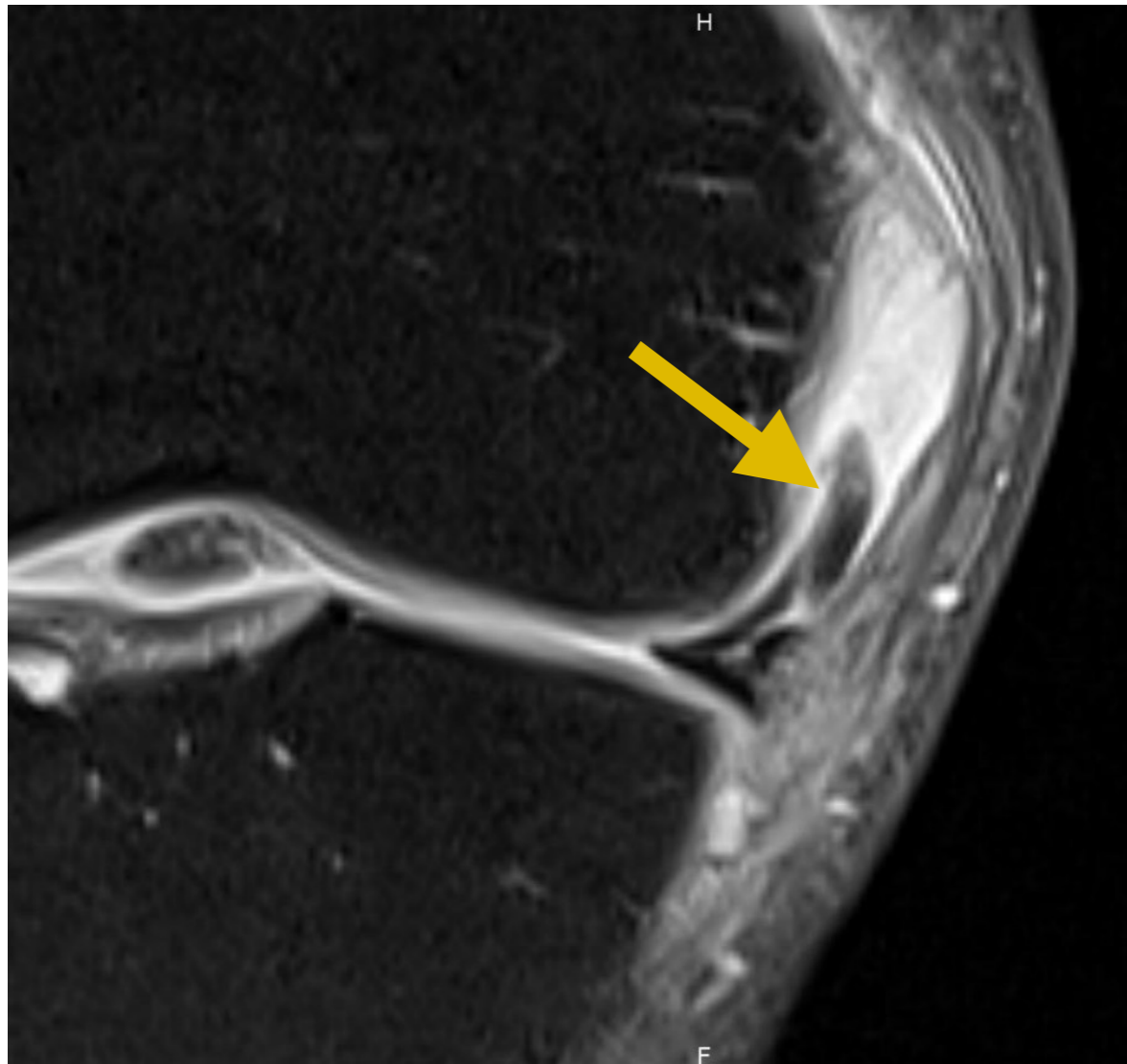
## 4. Languelette méniscale



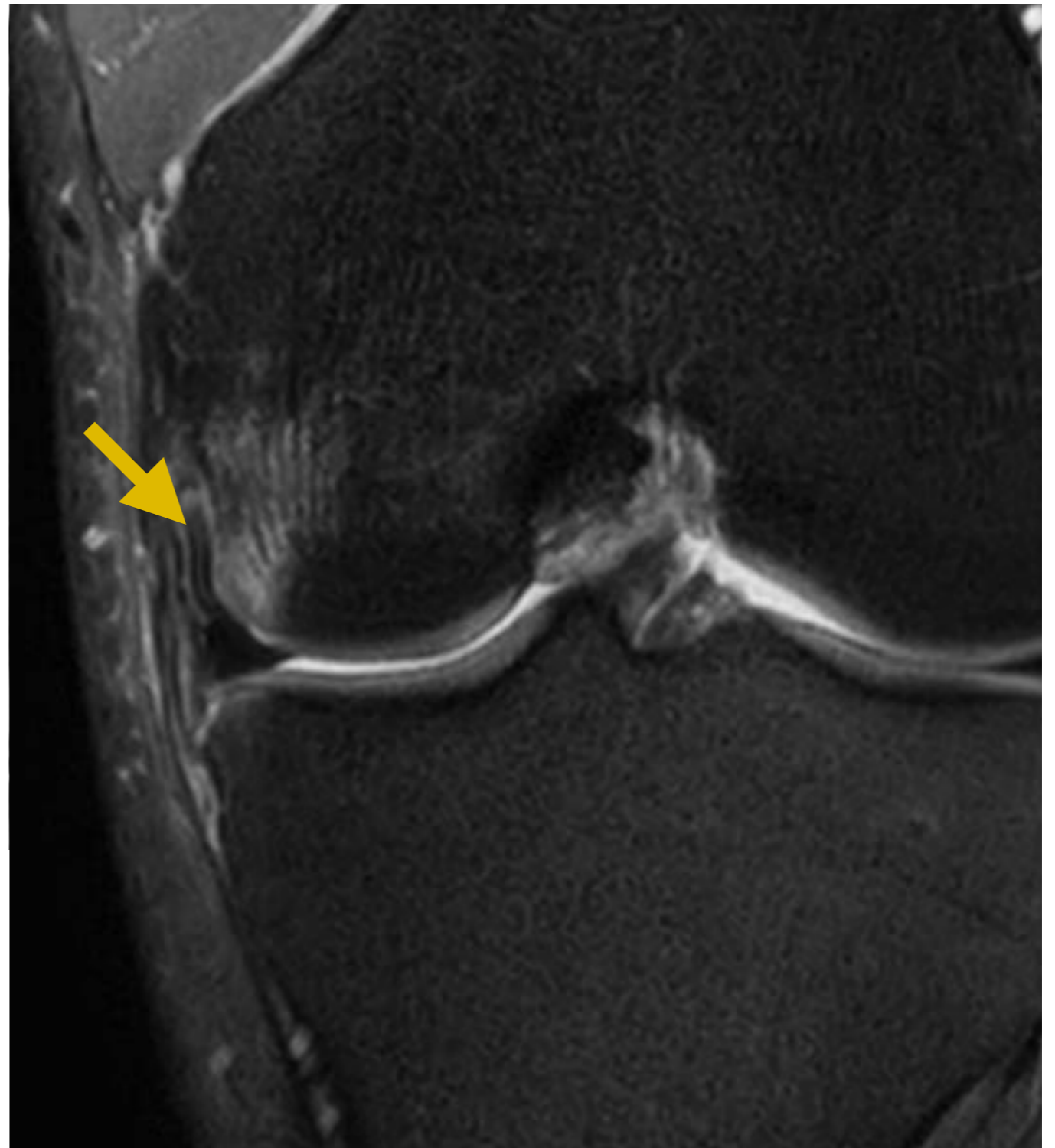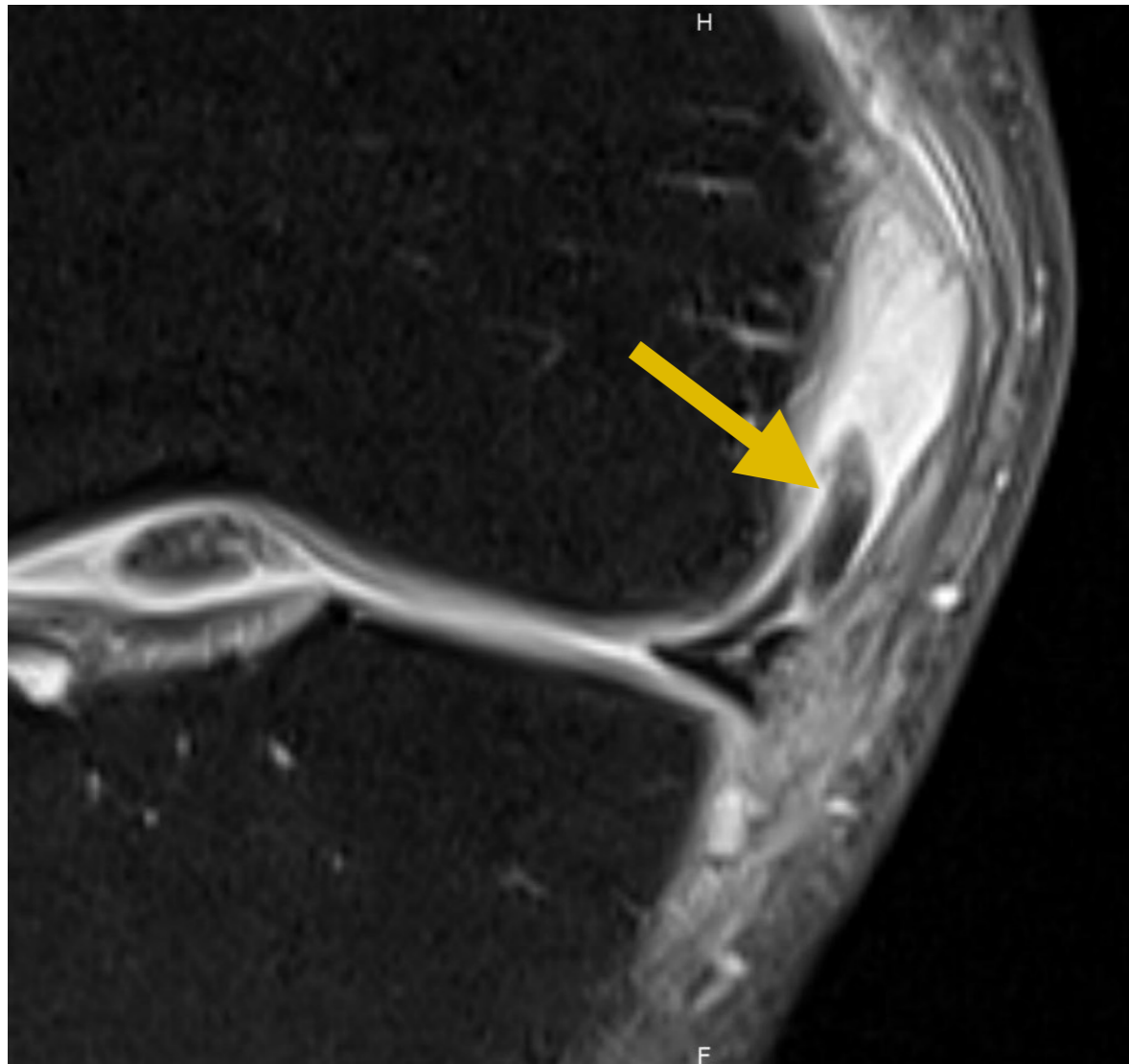
## 4. Langnette méniscale



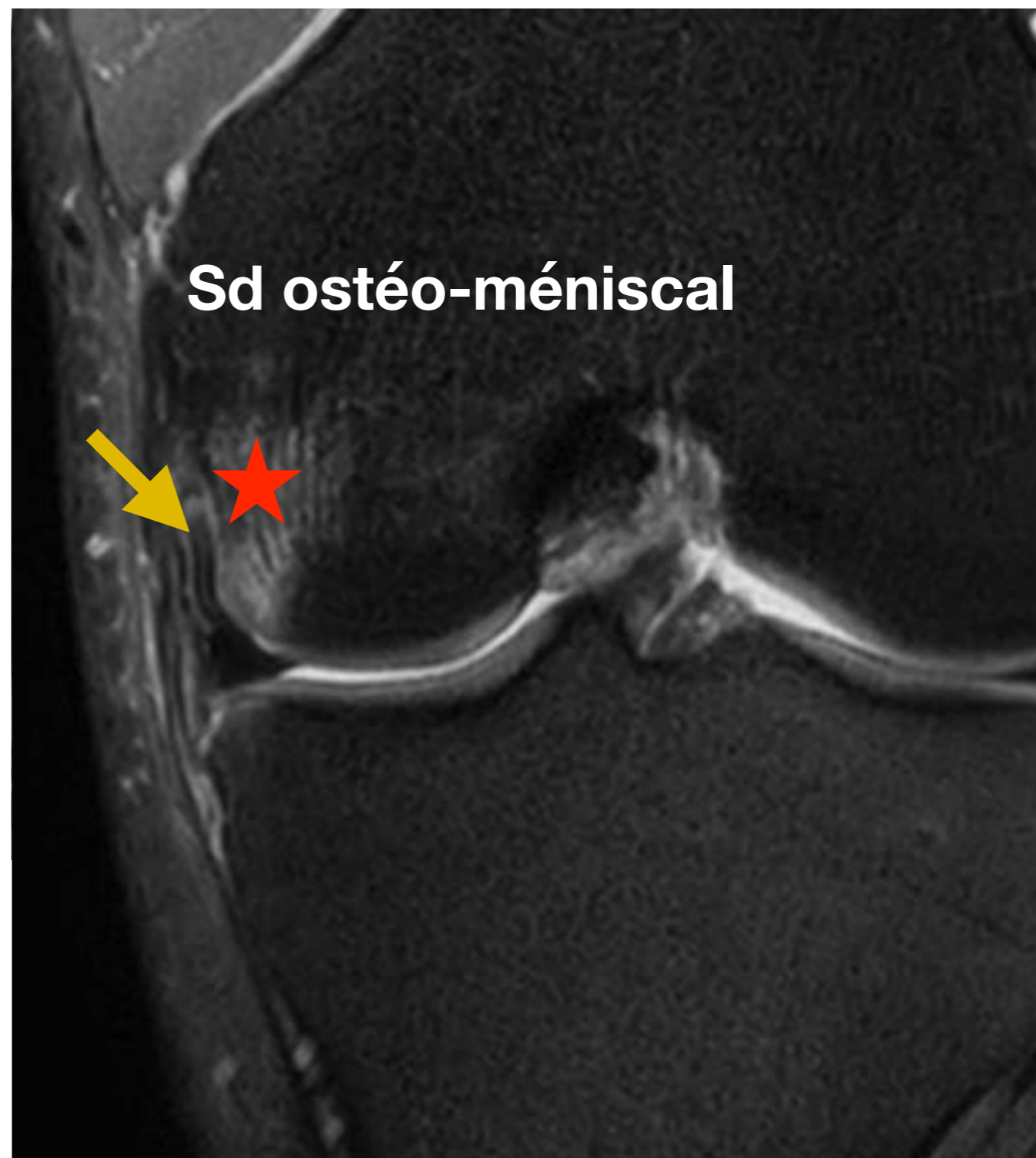
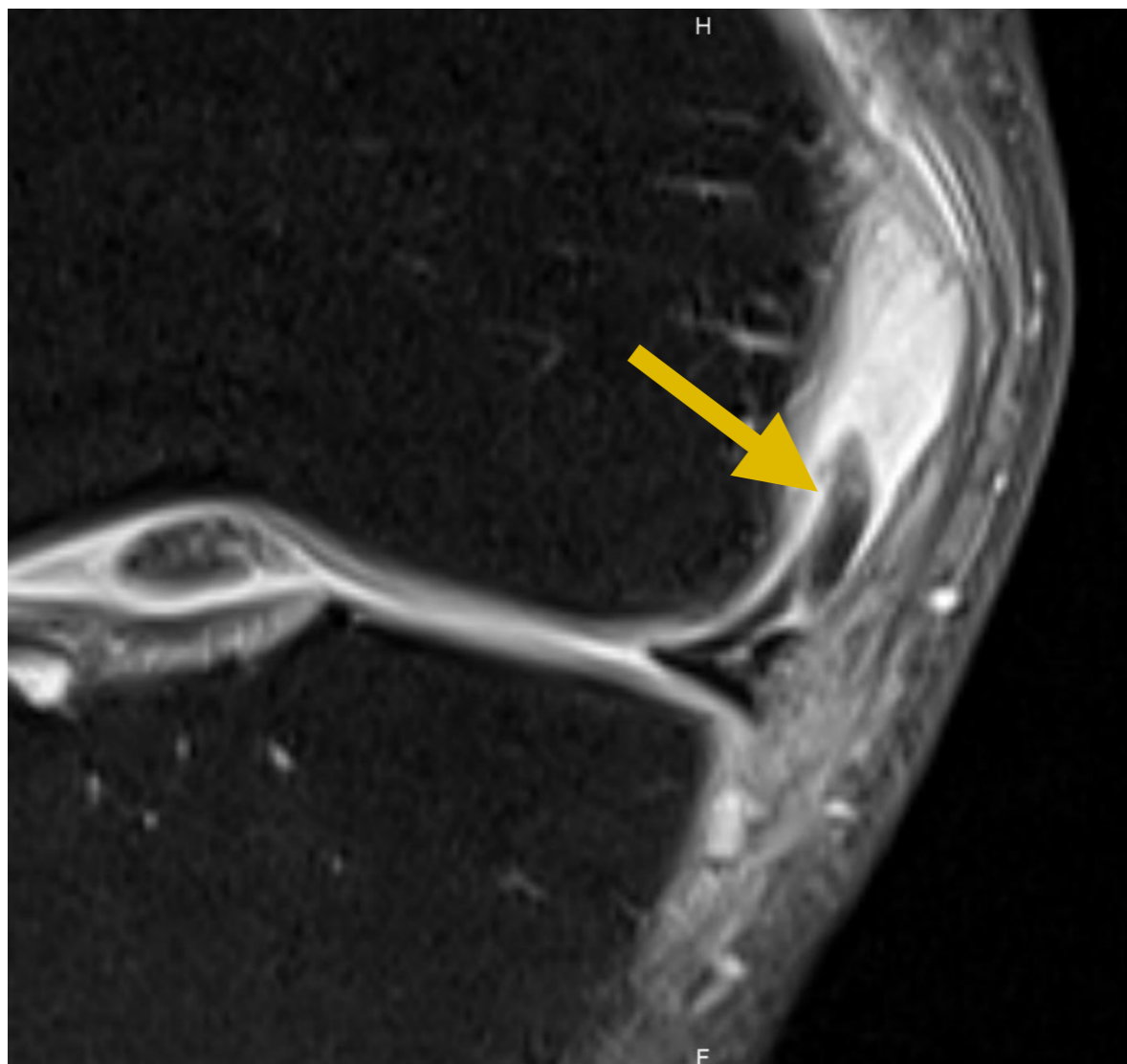
## 4. Languelette méniscale



## 4. Langnette méniscale



## 4. Languelette méniscale



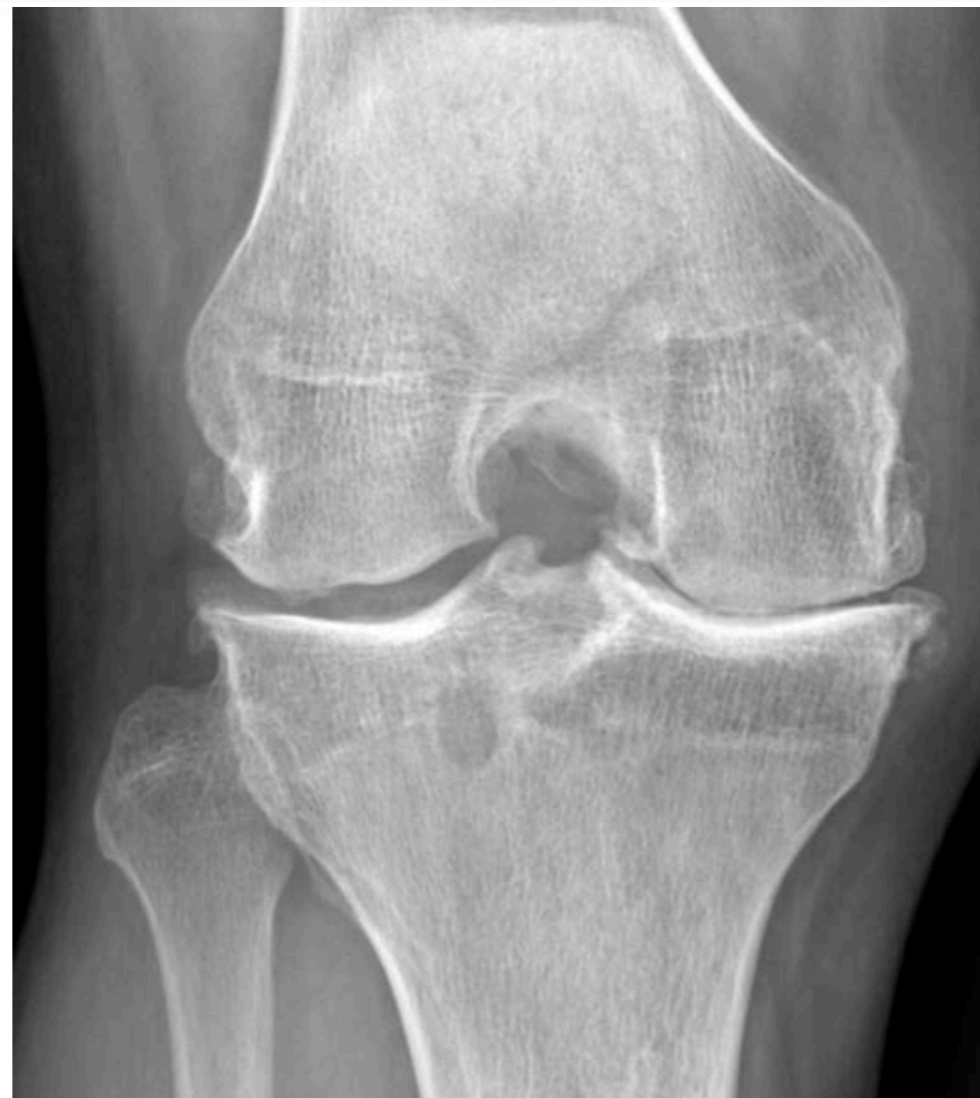

# 5. Lésions ostéochondrales

# 4. Cartilage

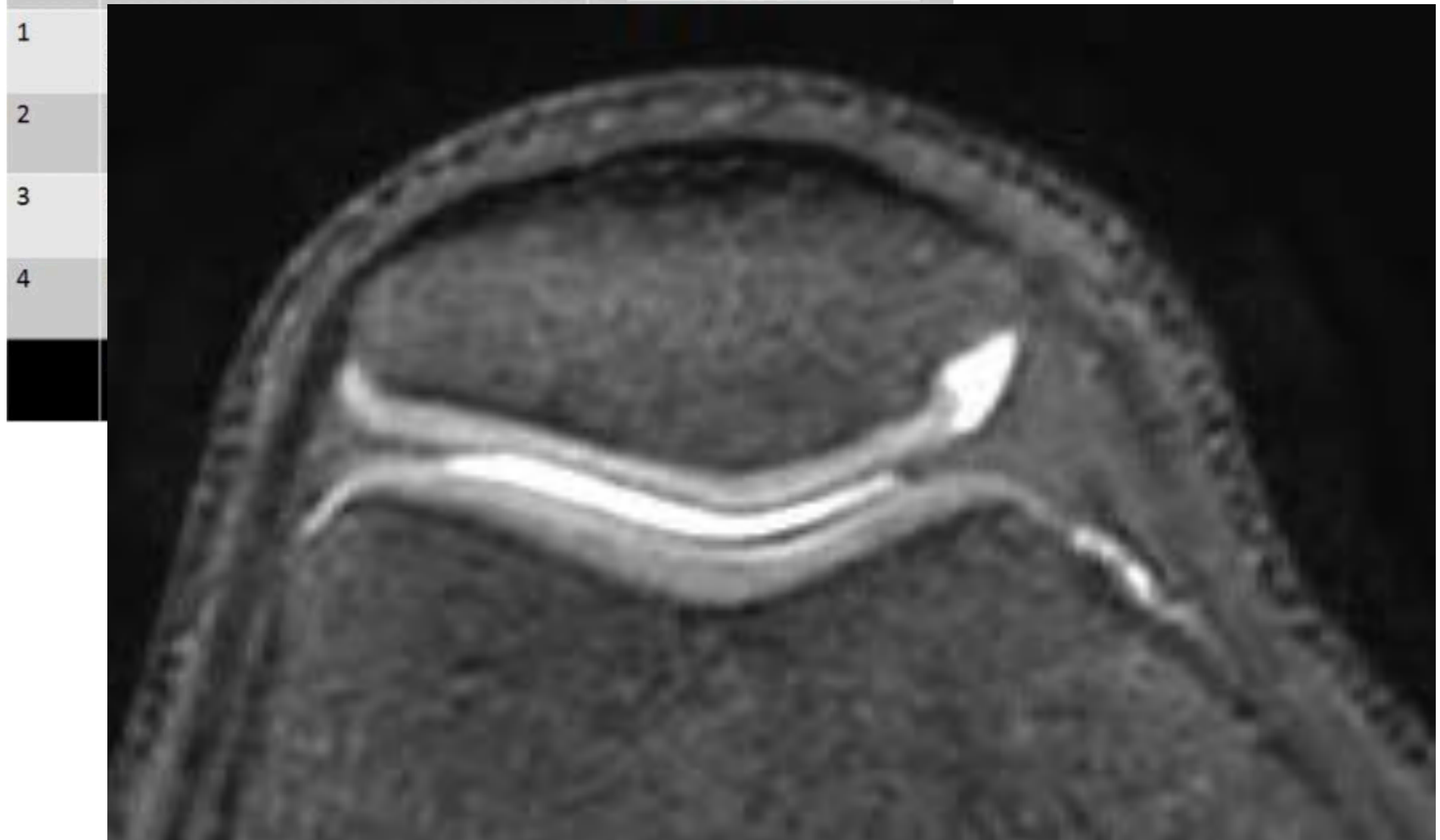
Tableau 1.2 Grades et classification de l'arthrose : modifiée d'après Kellgren et Lawrence.

Grades	Classification	Critères en radiographie
0	<i>Normale</i>	Aucun
I	<i>Douteuse</i>	<ul style="list-style-type: none"><li>– Pincement douteux</li><li>– Possible présence d'une ébauche ostéophytique</li></ul>
II	<i>Minime</i>	Ostéophytose et pincement démontrés de façon formelle
III	<i>Modérée</i>	<ul style="list-style-type: none"><li>– Ostéophytose et pincement démontrés de façon formelle.</li><li>– « Sclérose » débutante de l'os sous-chondral</li></ul>
IV	<i>Sévère</i>	<ul style="list-style-type: none"><li>– Pincement sévère de l'interligne, ostéophytose solide</li><li>– « Sclérose » sévère et géodes de l'os sous-chondral</li></ul>



# 4. Cartilage

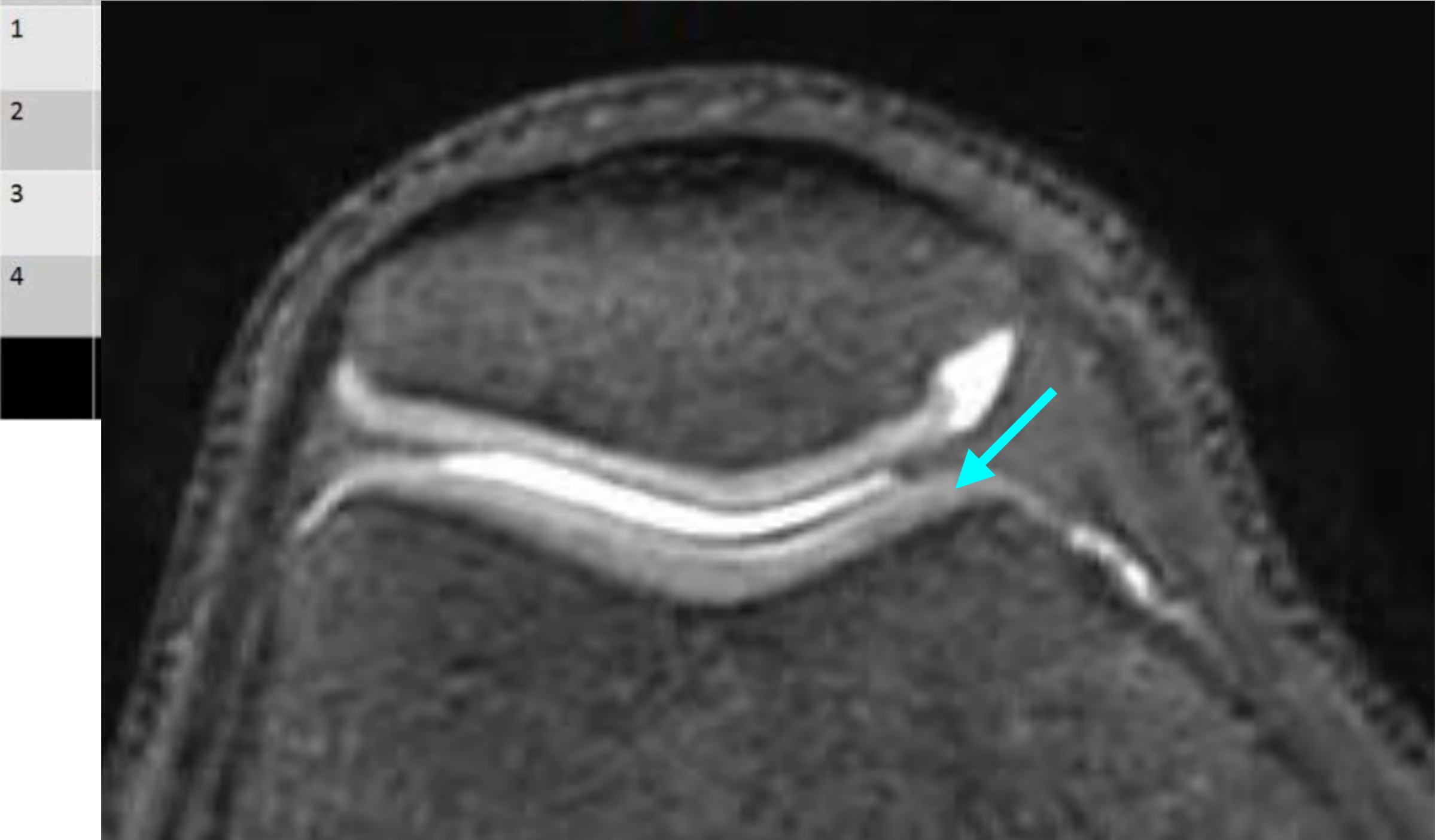
Stade		
0	Cartilage normal	



- 1
- 2
- 3
- 4

# 4. Cartilage

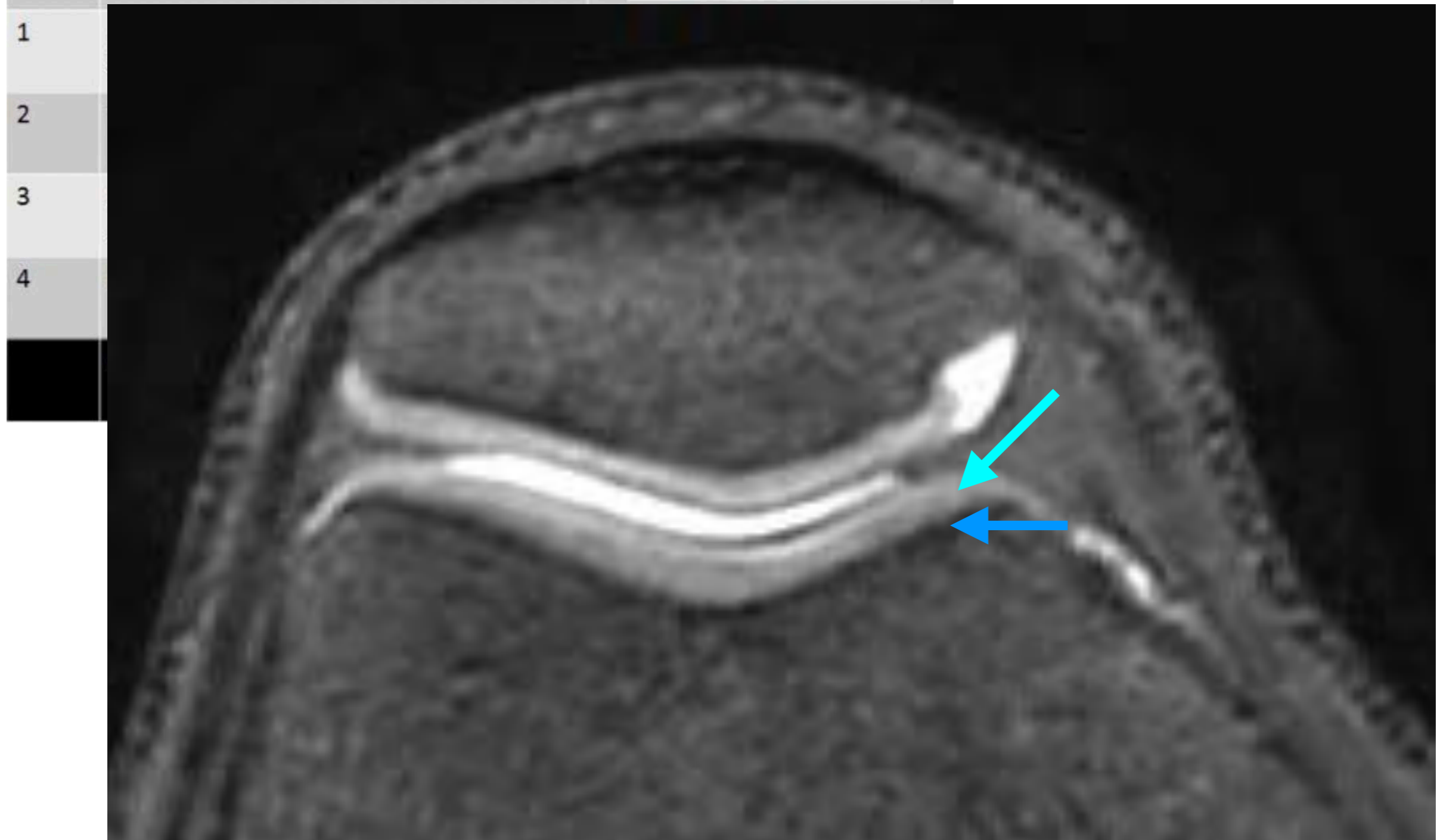
Stade		
0	Cartilage normal	



- 1
- 2
- 3
- 4

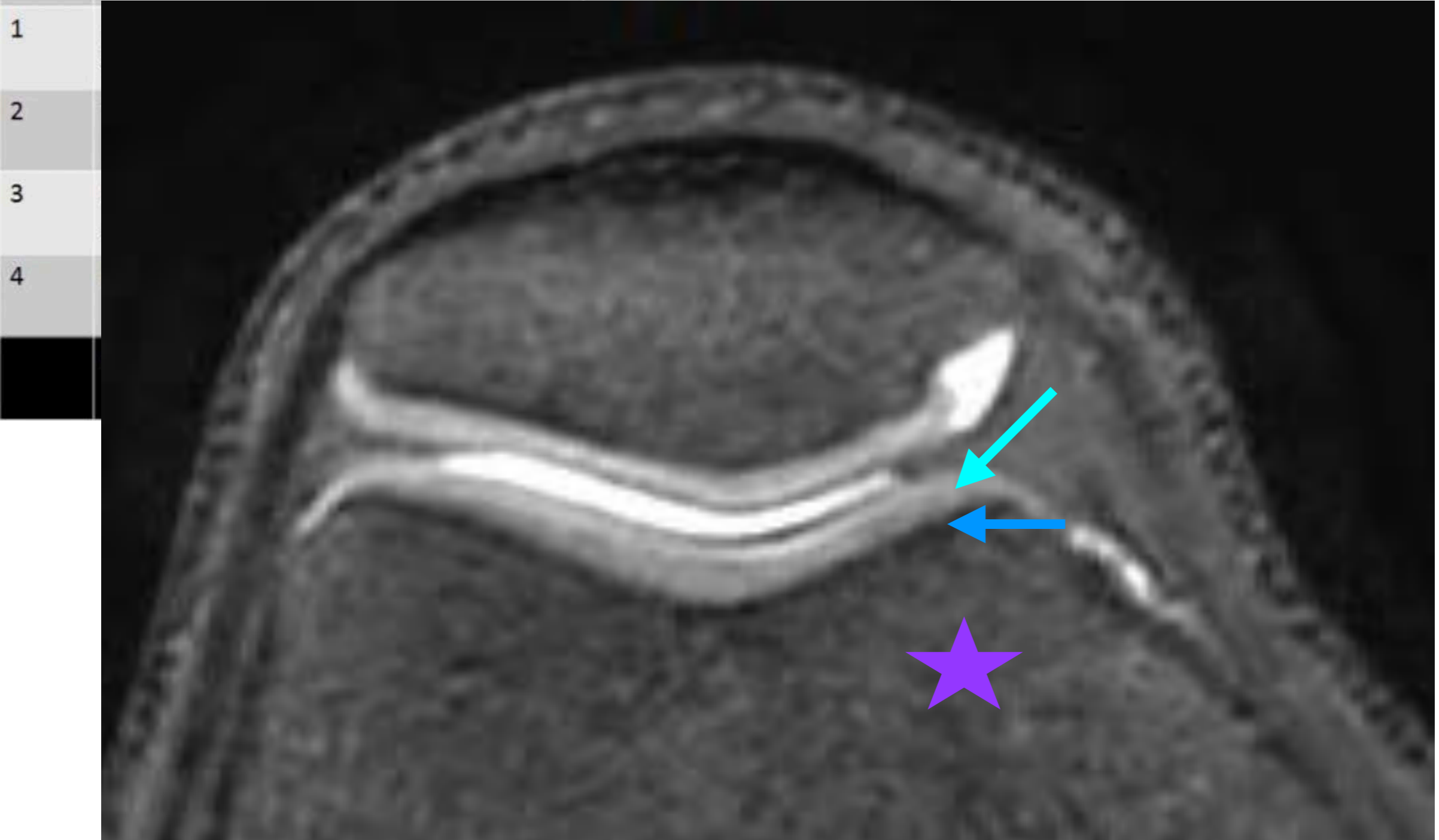
# 4. Cartilage

Stade		
0	Cartilage normal	



# 4. Cartilage

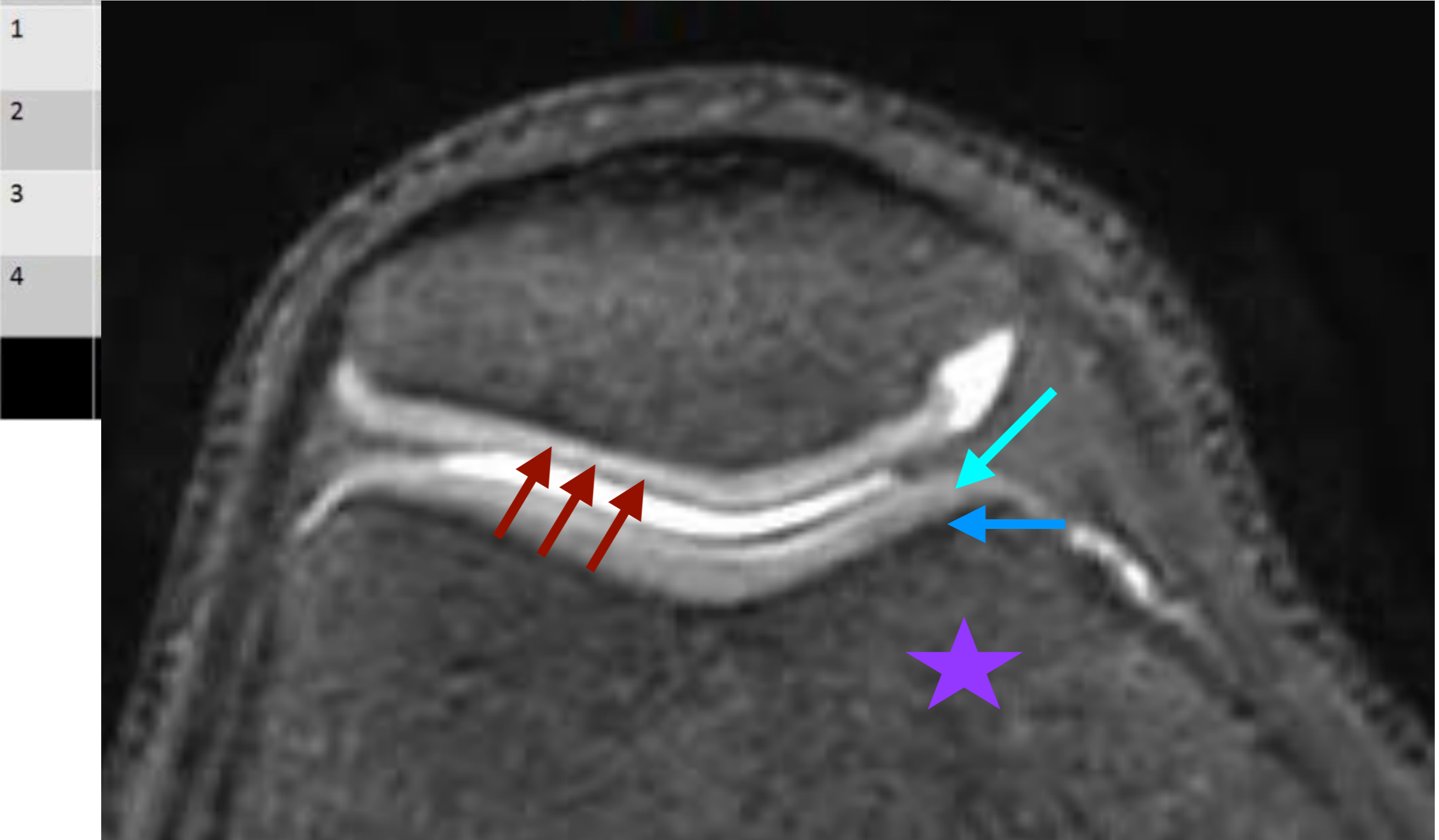
Stade		
0	Cartilage normal	





- 1
- 2
- 3
- 4

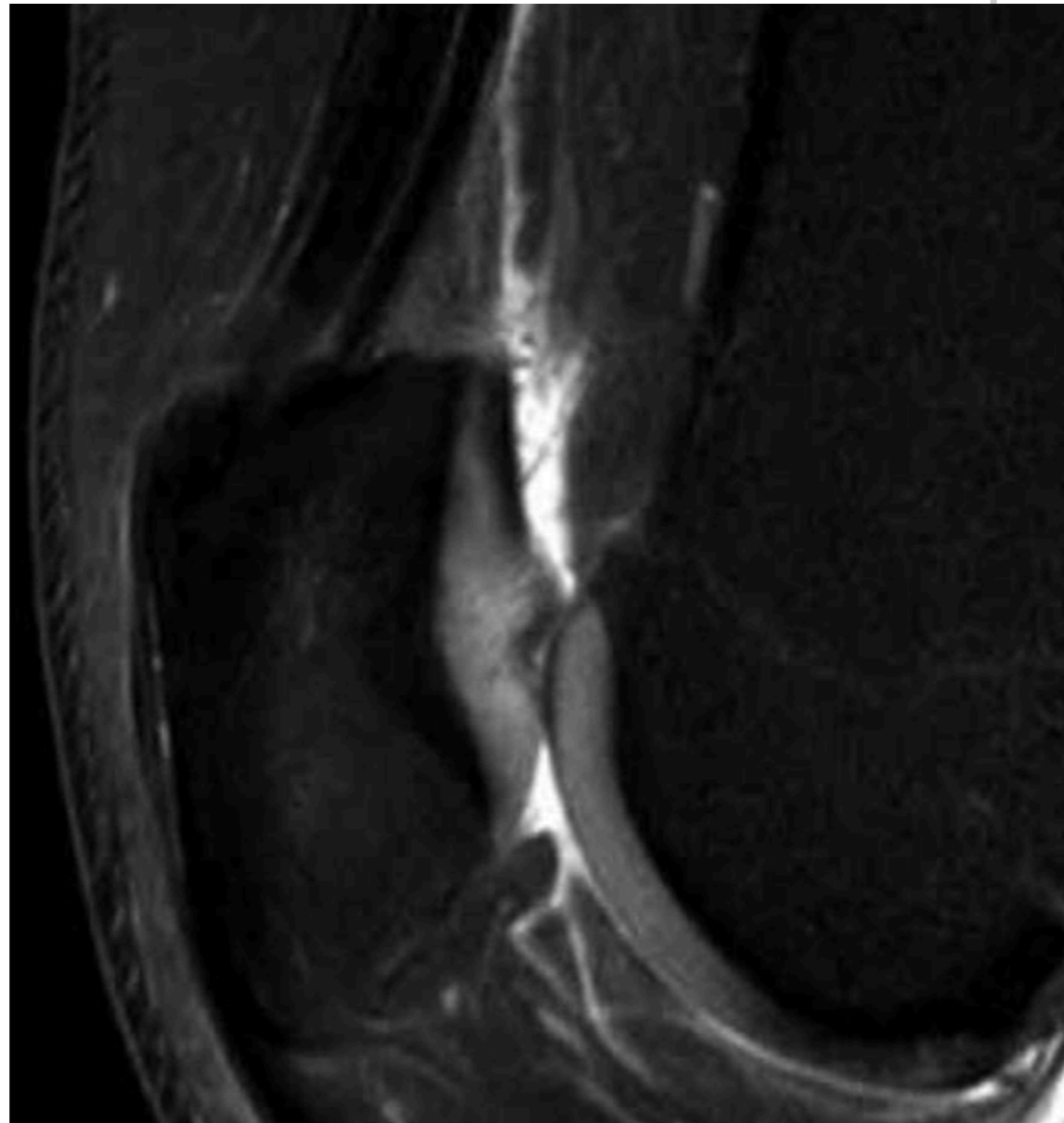
# 4. Cartilage

Stade		
0	Cartilage normal	



# 4. Chondrolyse



Stade		
0	Cartilage normal	
1	Anomalies de signal intrachondrales, surface chondrale normale	
2		
3		
4		

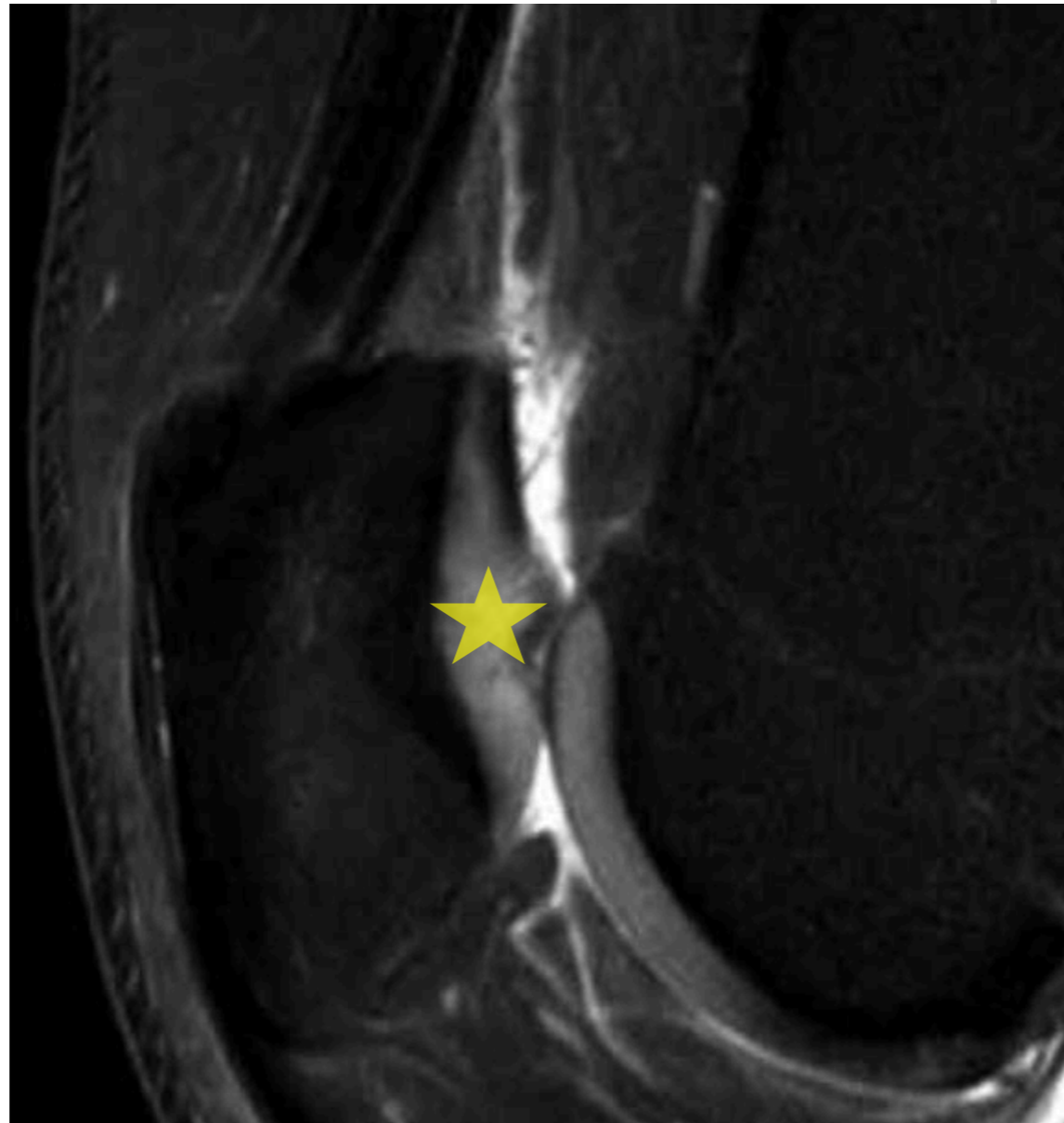


IRM >>>>  
Arthro-TDM



# 4. Chondrolyse




Stade		
0	Cartilage normal	
1	Anomalies de signal intrachondrales, surface chondrale normale	
2		
3		
4		

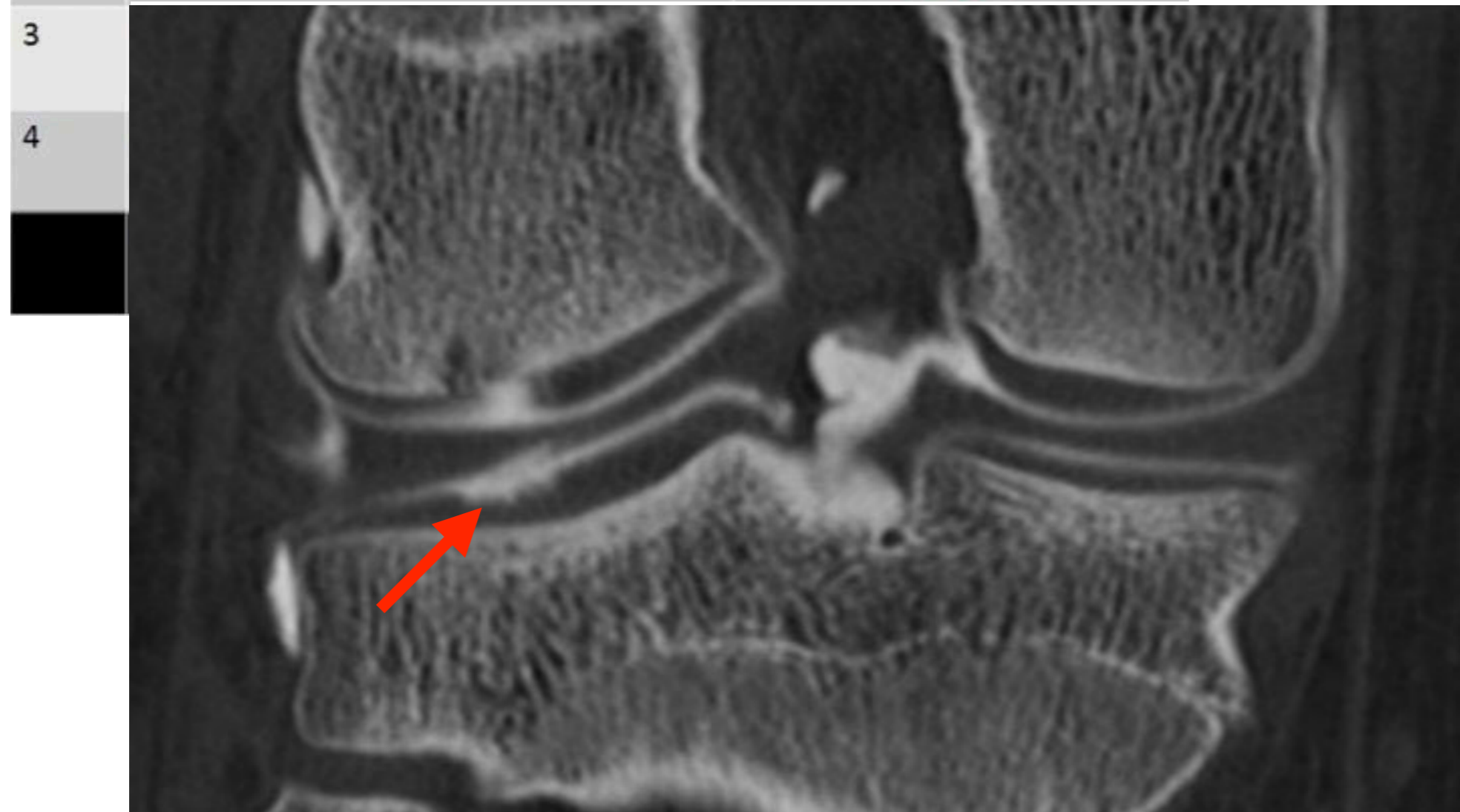


IRM >>>>  
Arthro-TDM

# 4. Chondrolyse




Arthro-TDM >> IRM

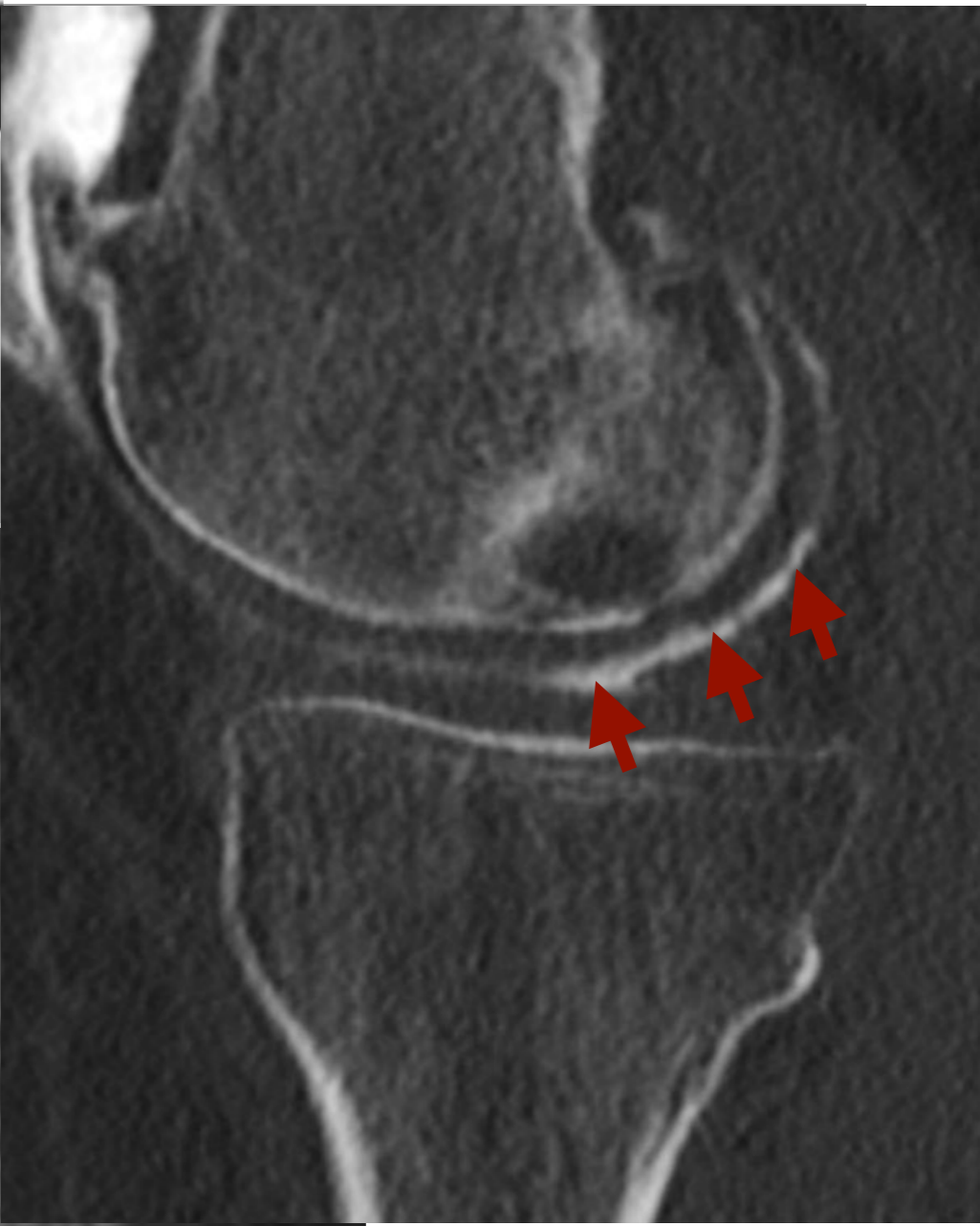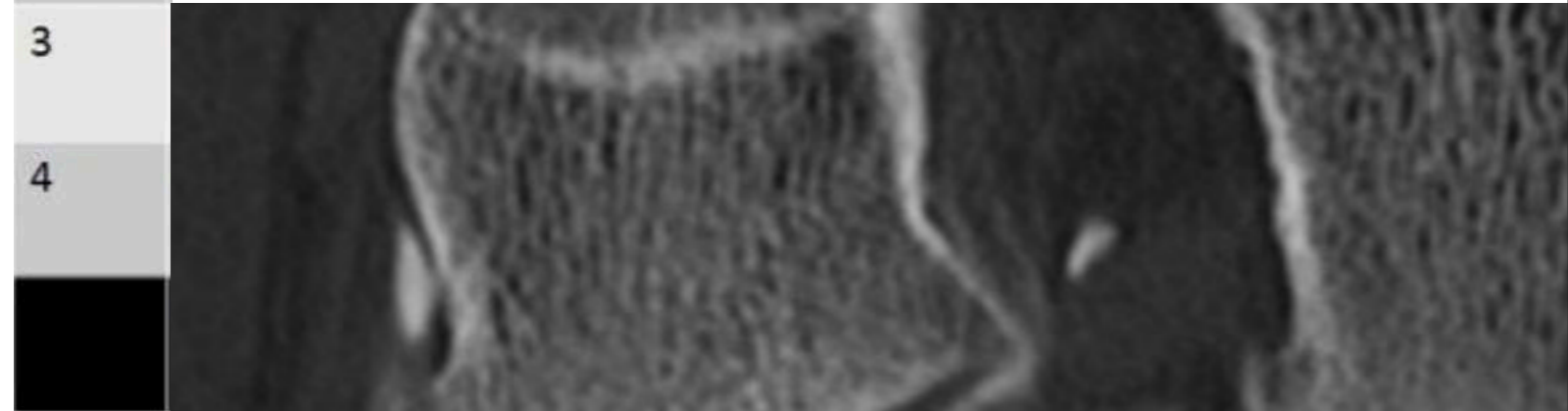
Stade		
0	Cartilage normal	
1	Anomalies de signal intrachondrales, surface chondrale normale	
2	Perte d'épaisseur <50% du cartilage	



# 4. Chondrolyse

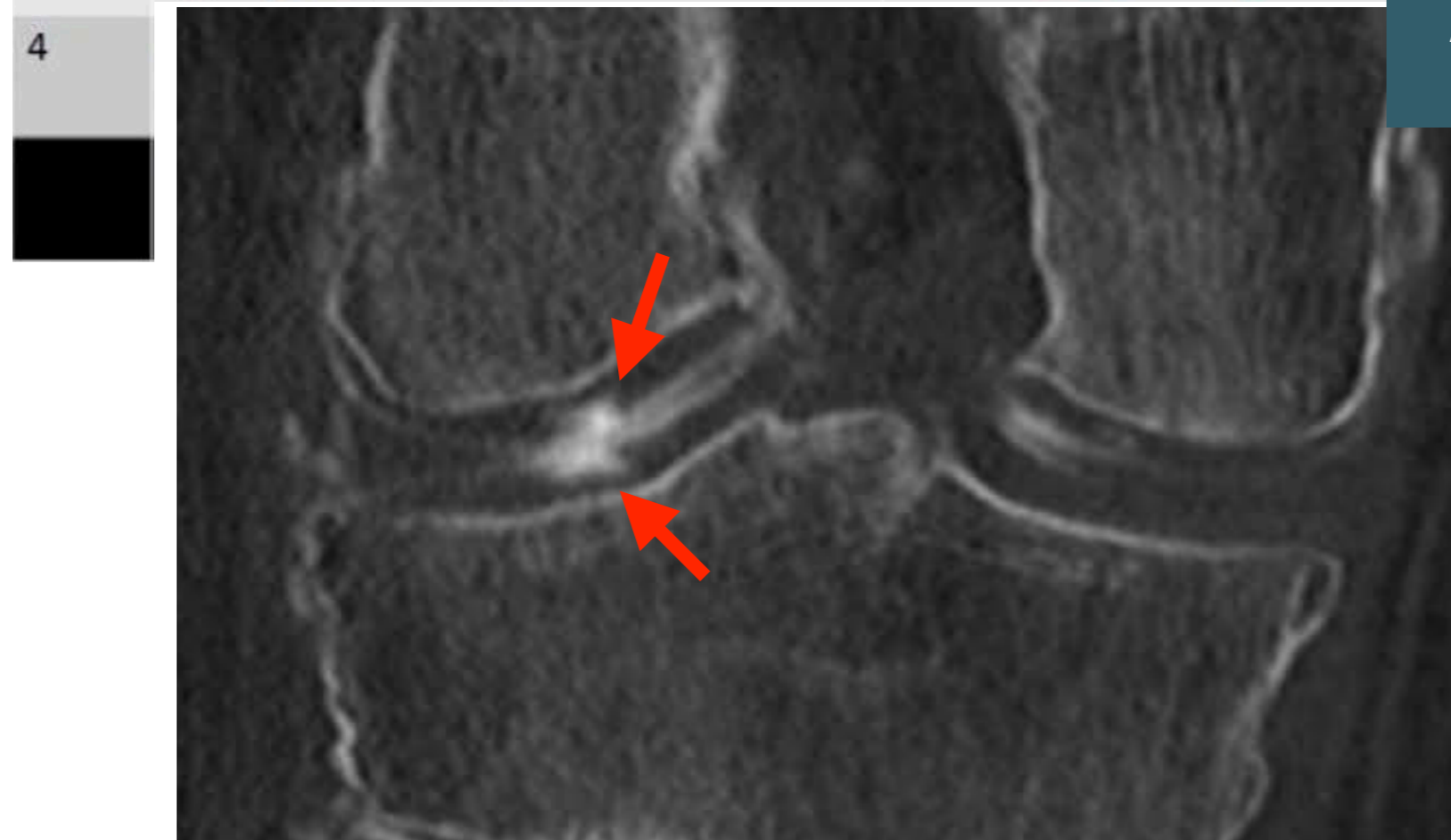
Arthro-TDM >> IRM

Stade		
0	Cartilage normal	
1	Anomalies de signal intrachondrales, surface chondrale normale	
2	Perte d'épaisseur <50% du cartilage	









# 4. Chondrolyse

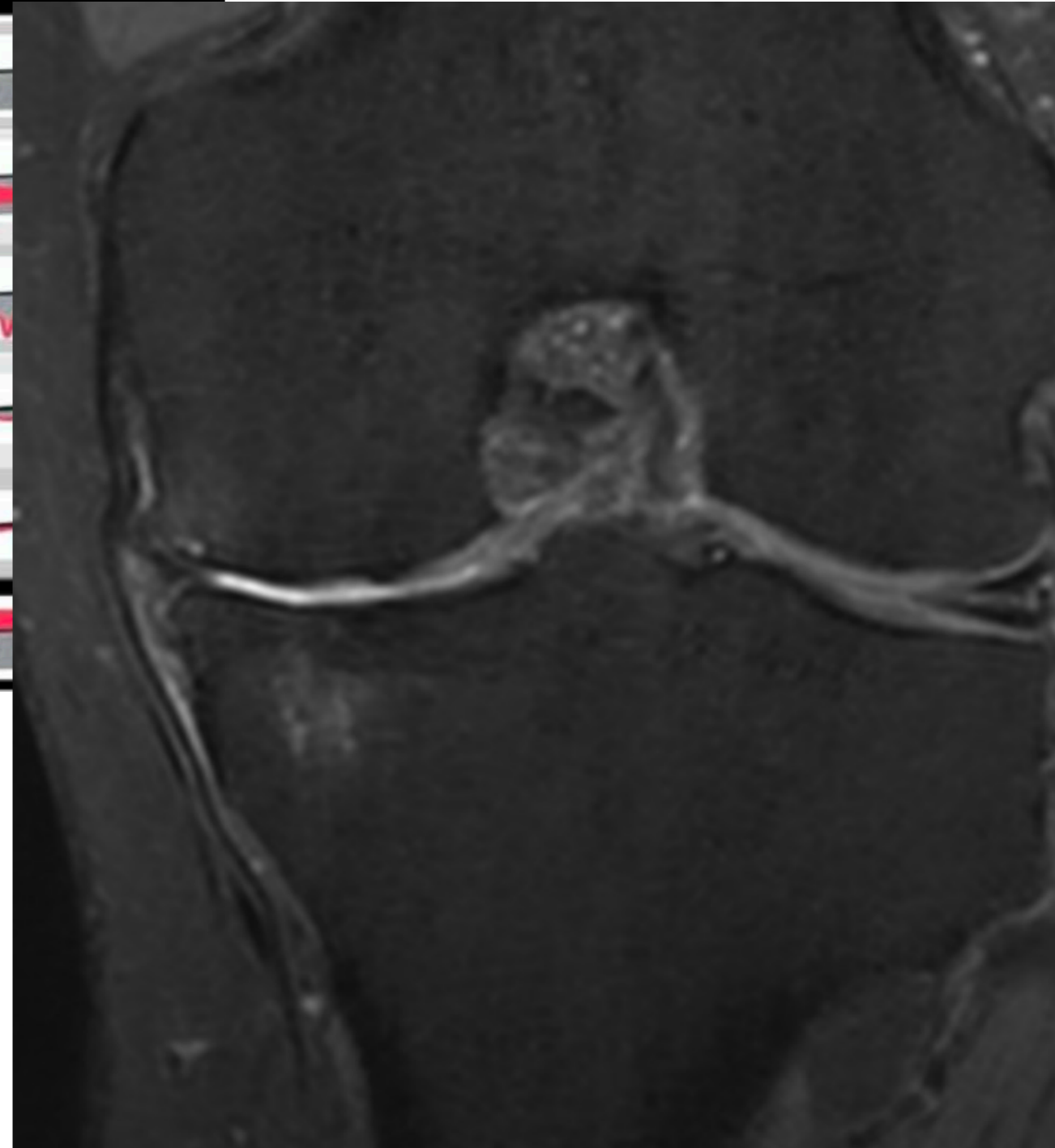
Stade		
0	Cartilage normal	
1	Anomalies de signal intrachondrales, surface chondrale normale	
2	Perte d'épaisseur <50% du cartilage	
3	Perte d'épaisseur >50%, sans exposition de l'os sous-chondral	



Arthro-TDM > IRM

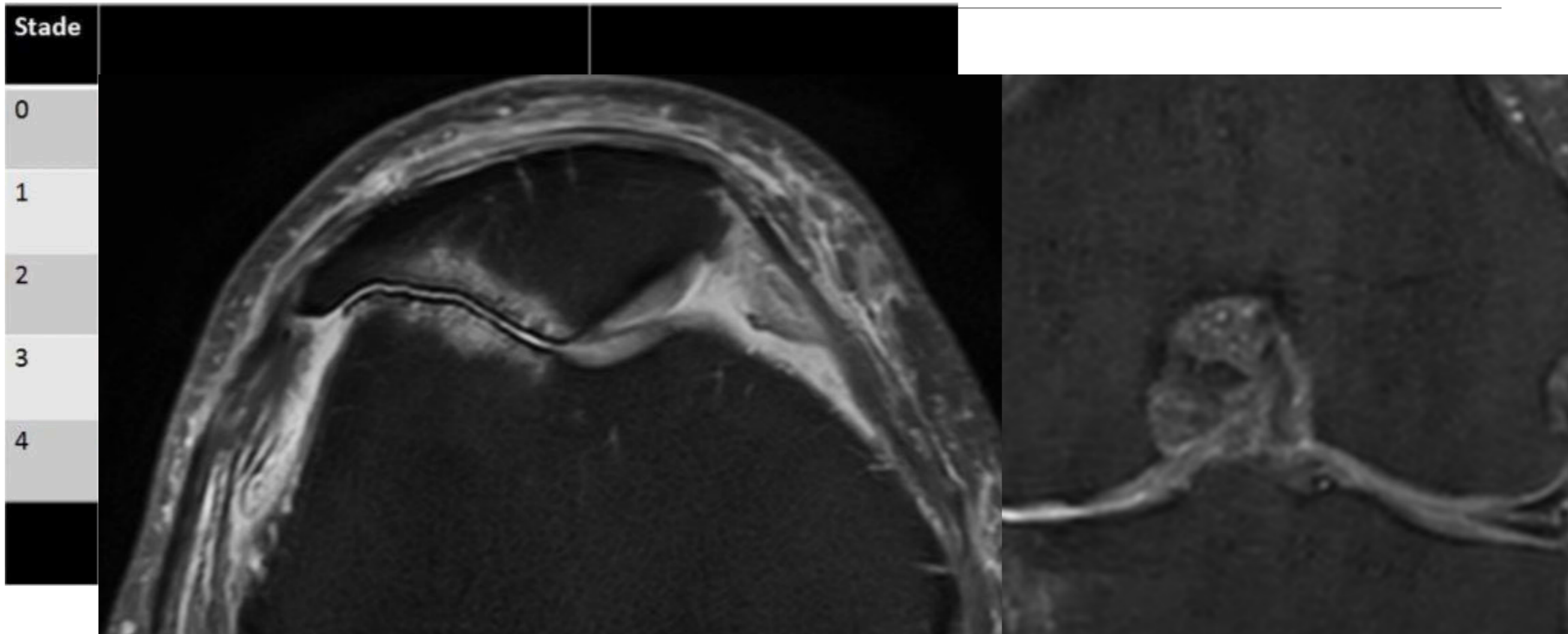
# 4. Chondrolyse

Stade		
0	Cartilage normal	
1	Anomalies de signal intrachondrales, surface chondrale normale	
2	Perte d'épaisseur <50% du cartilage	
3	Perte d'épaisseur >50%, sans exposition de l'os sous-chondral	
4	Os sous-chondral à nu	
	Anomalies de signal de l'os sous-chondral	



**Arthro-TDM > IRM**

# 4. Chondrolyse



**Arthro-TDM > IRM**

# 4. Chondrolyse

Stade

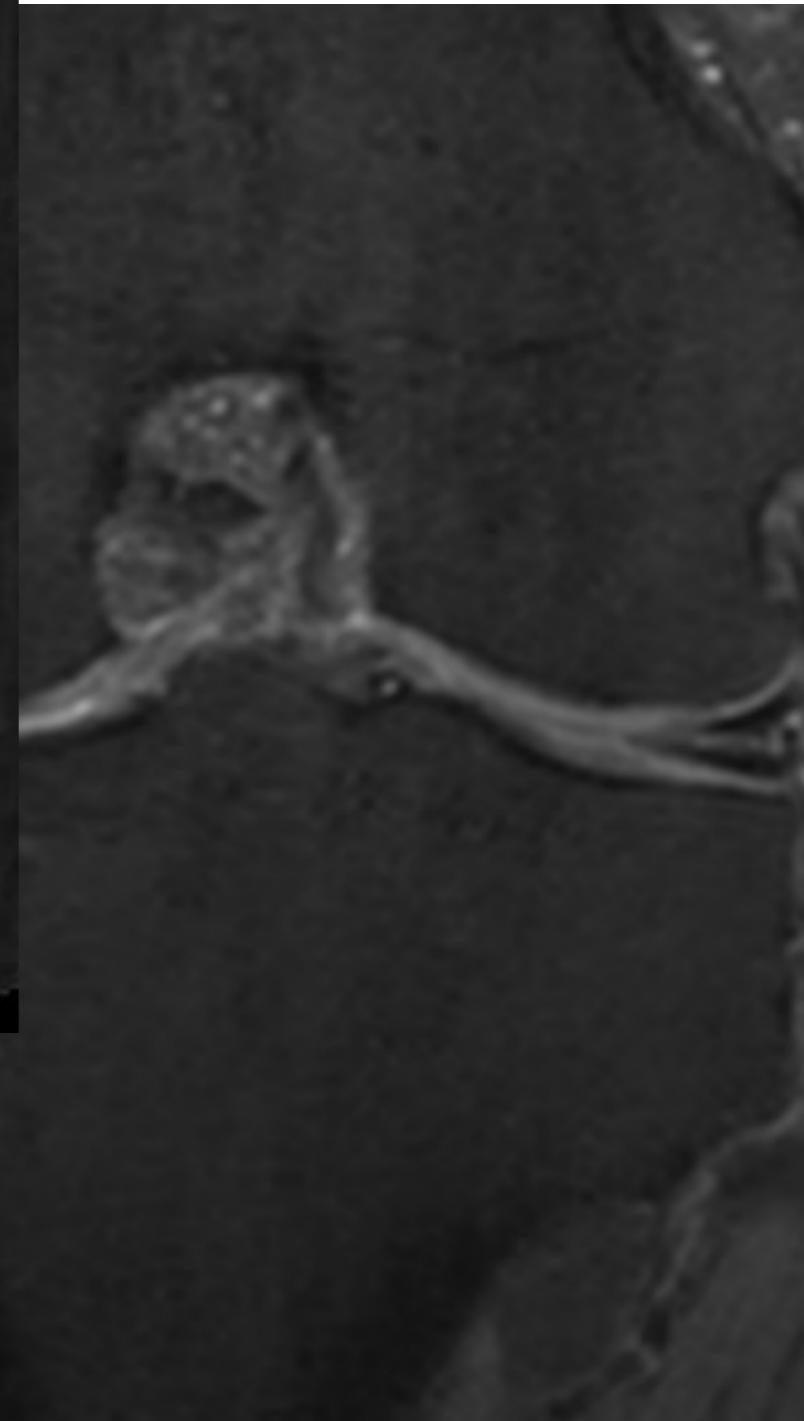
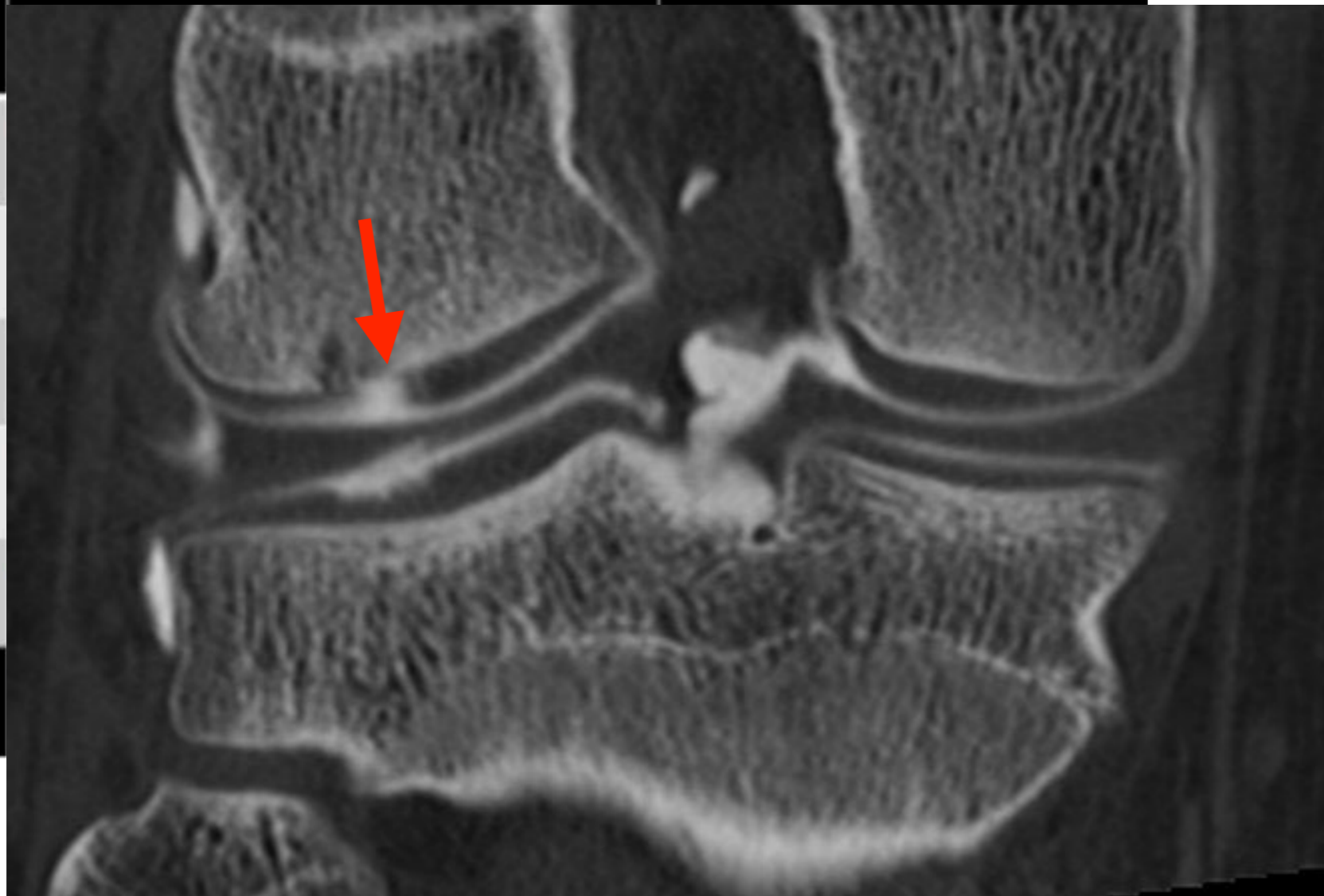
0

1

2

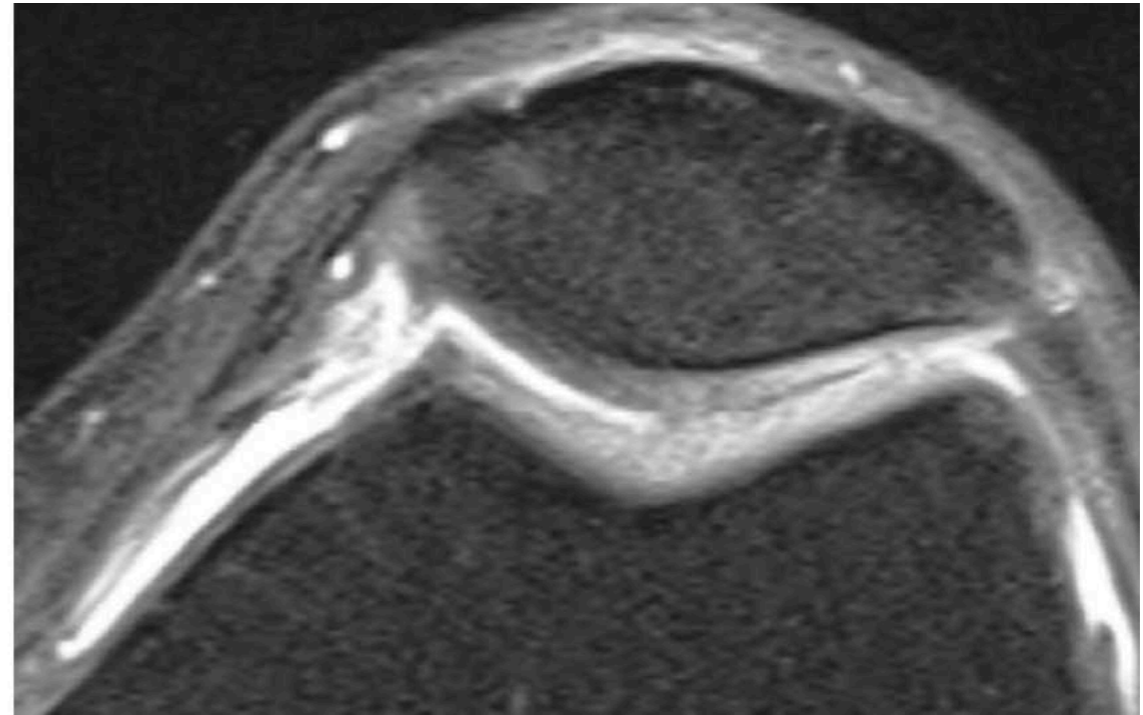
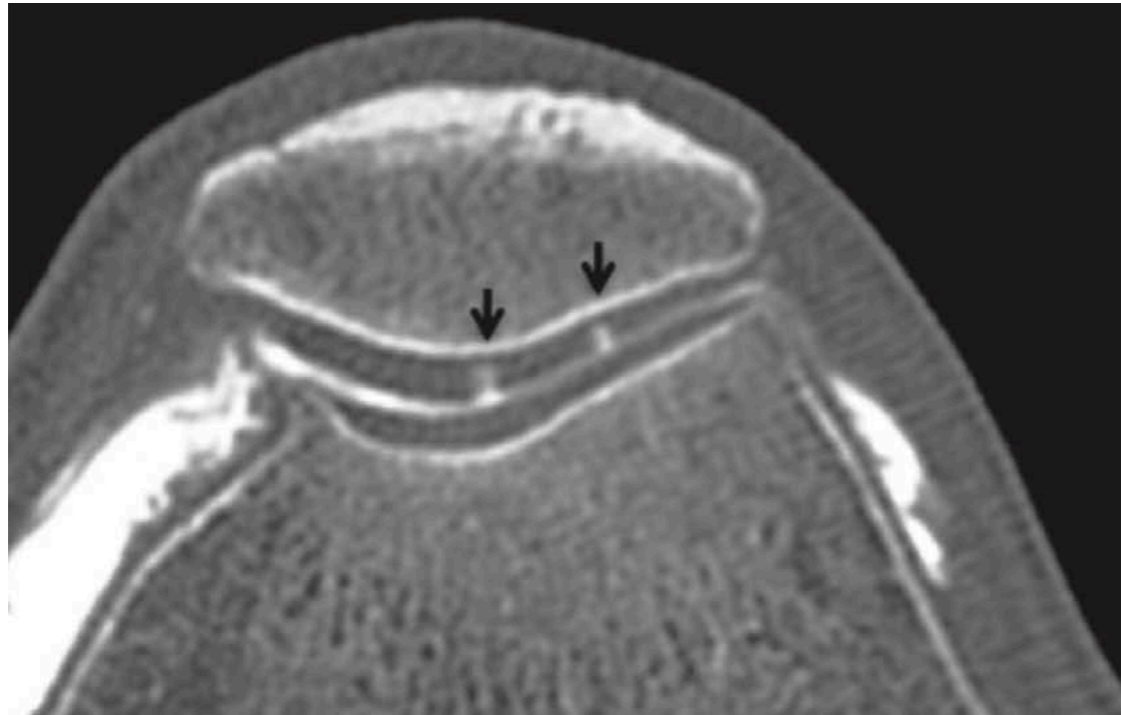
3

4



**Arthro-TDM > IRM**

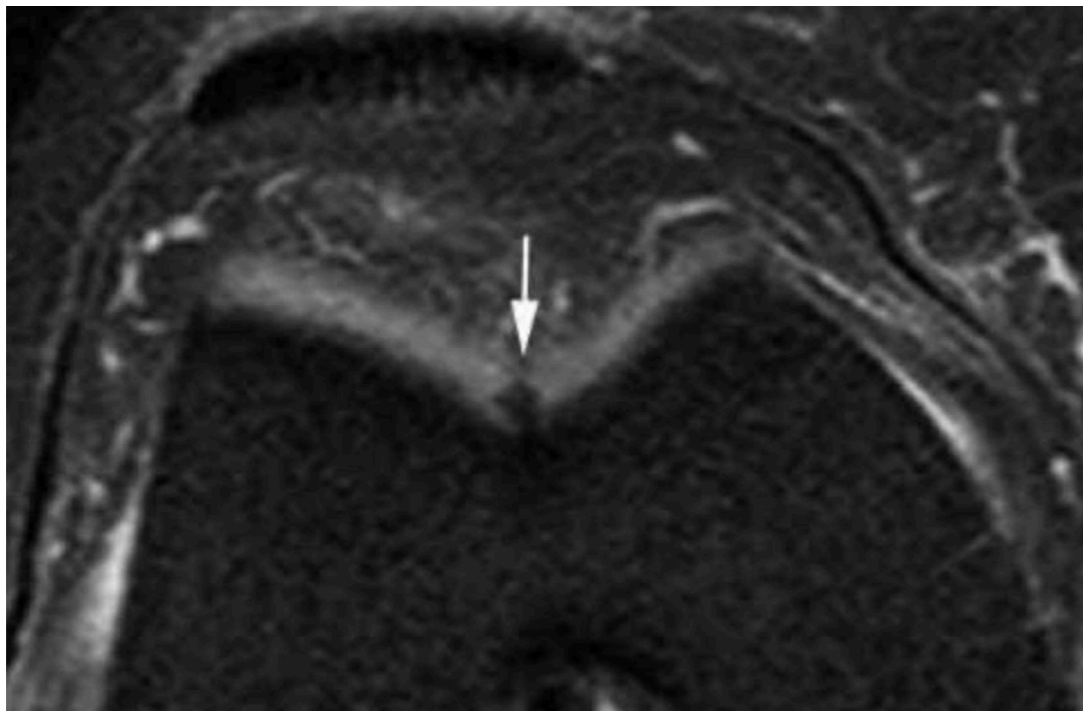
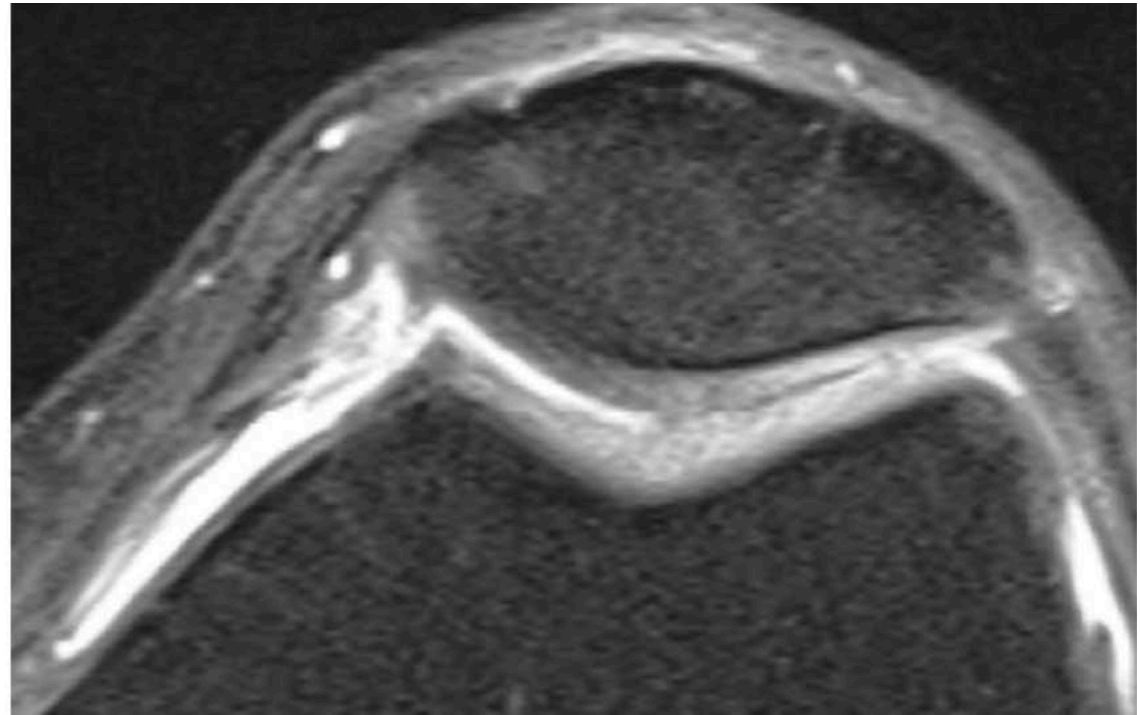
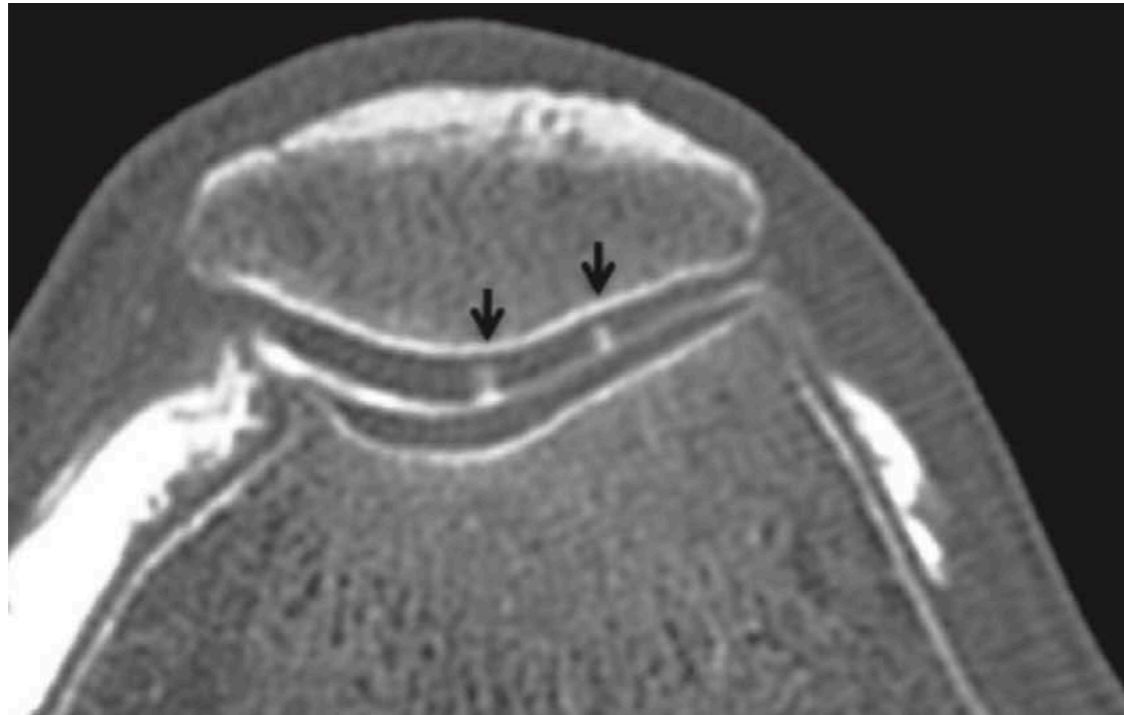
## 4. Cartilage : FISSURES



**Arthro-TDM >> IRM**

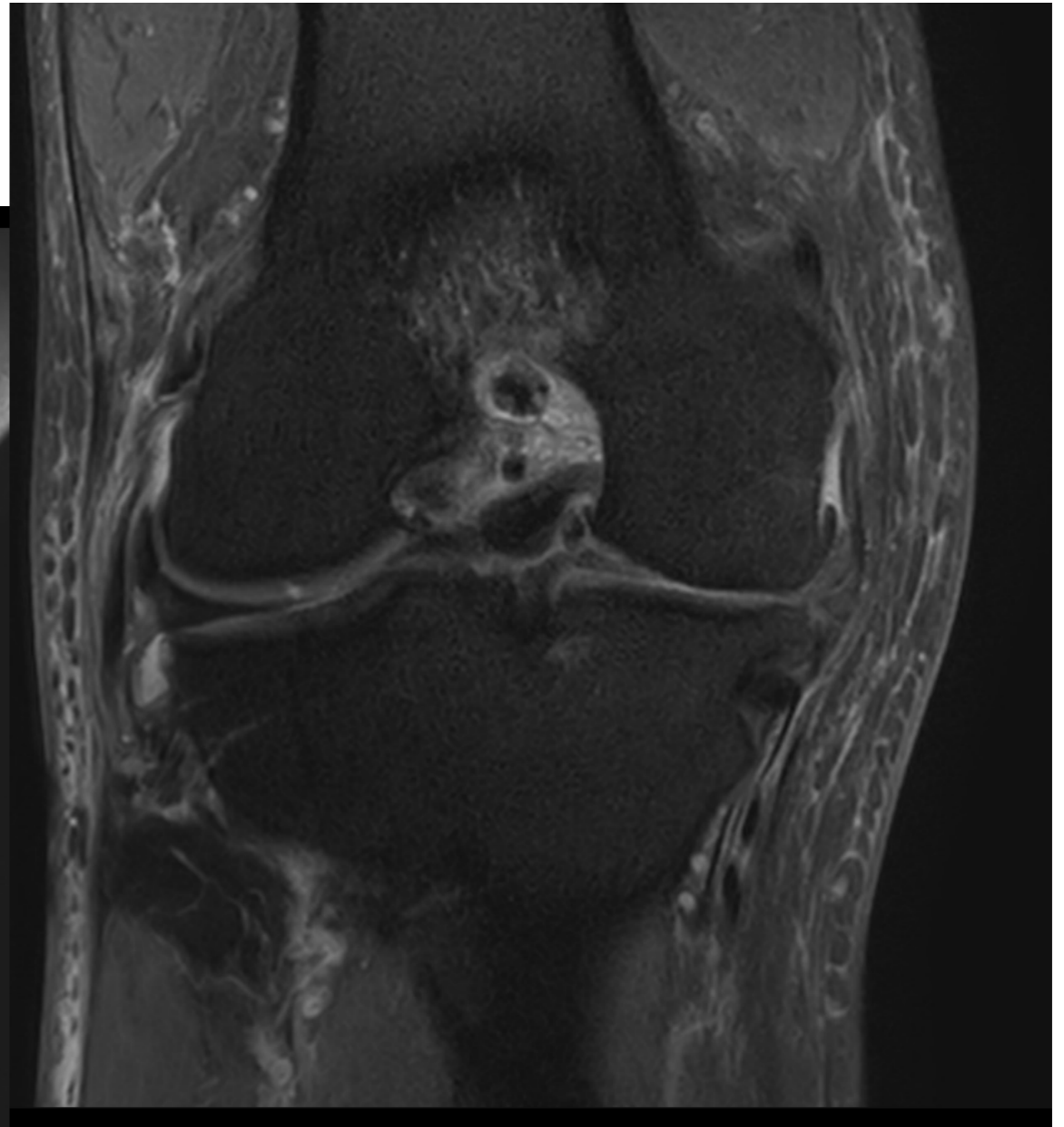
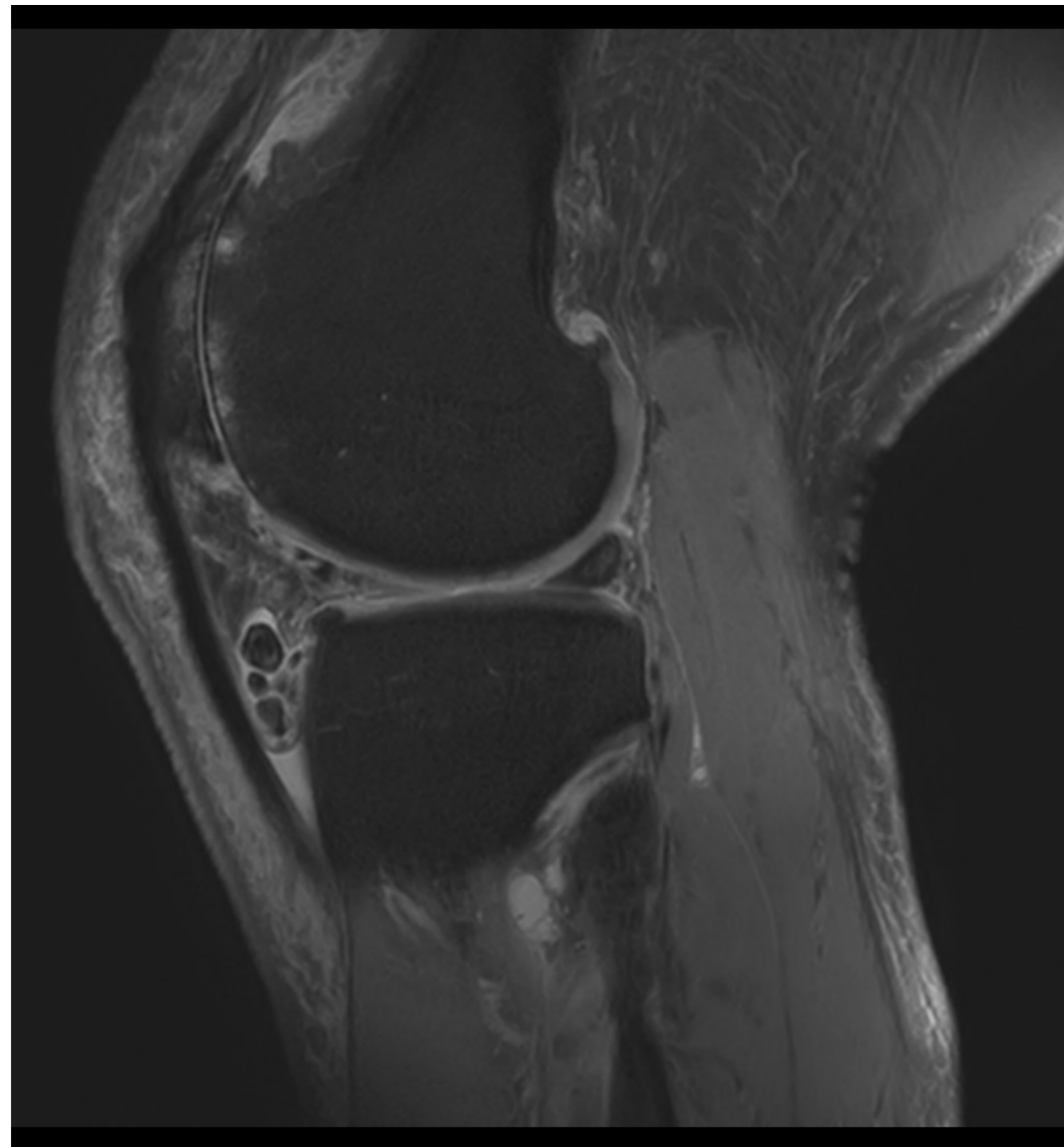


## 4. Cartilage : FISSURES



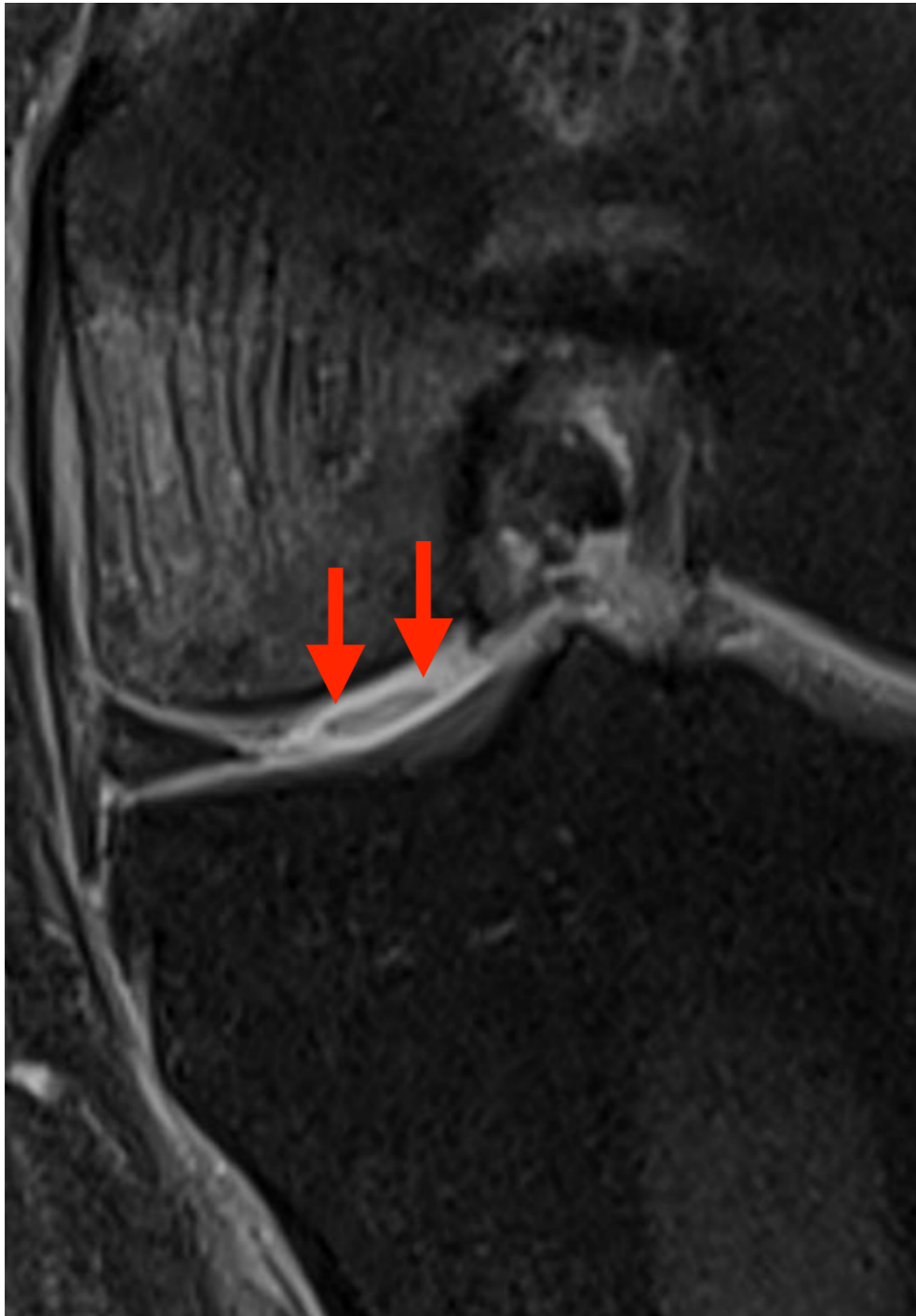
**Arthro-TDM >> IRM**

## 4. Cartilage

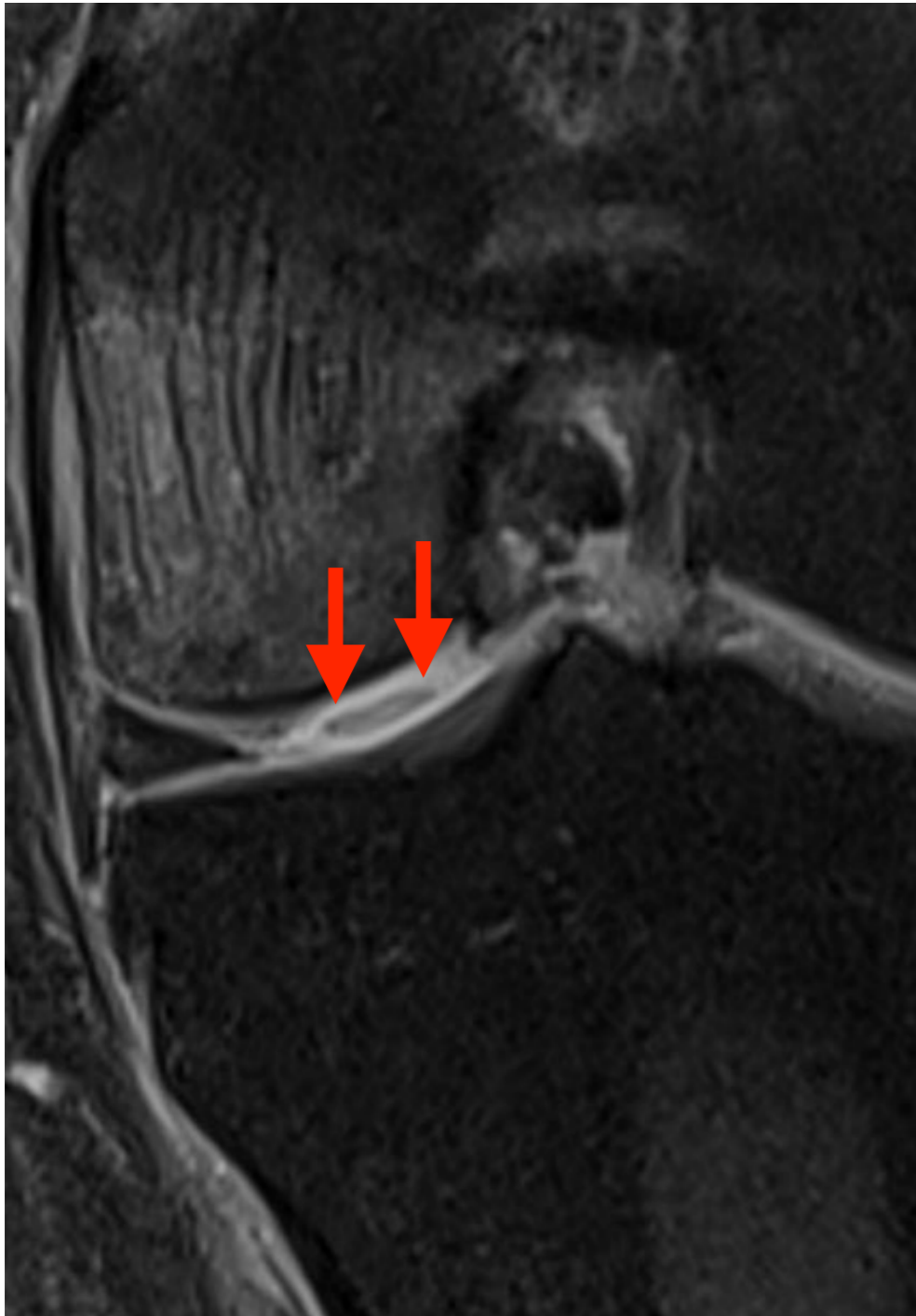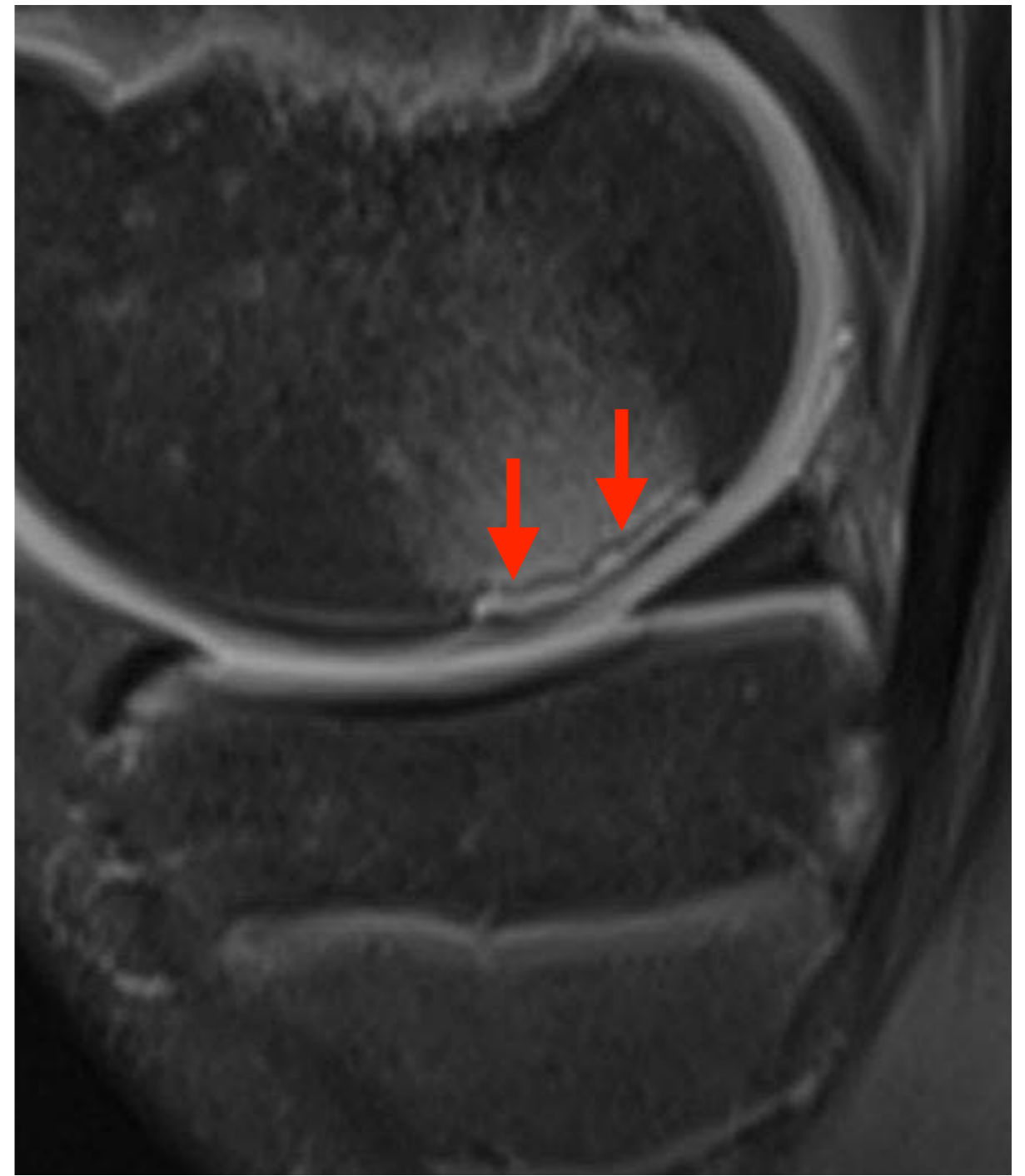


**Arthro-TDM > IRM**

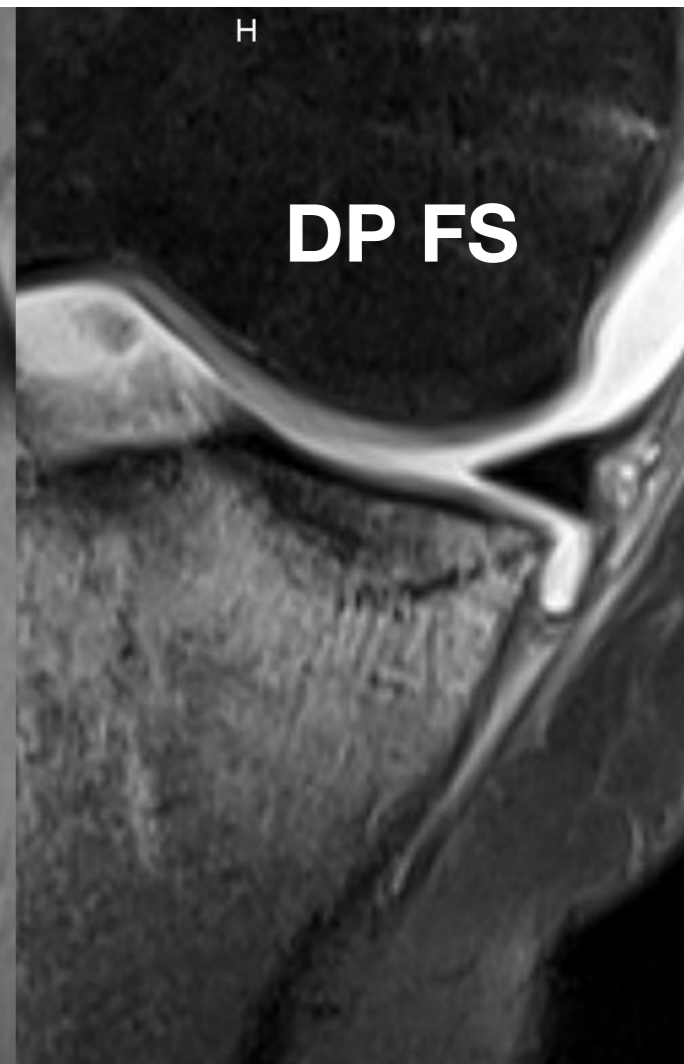
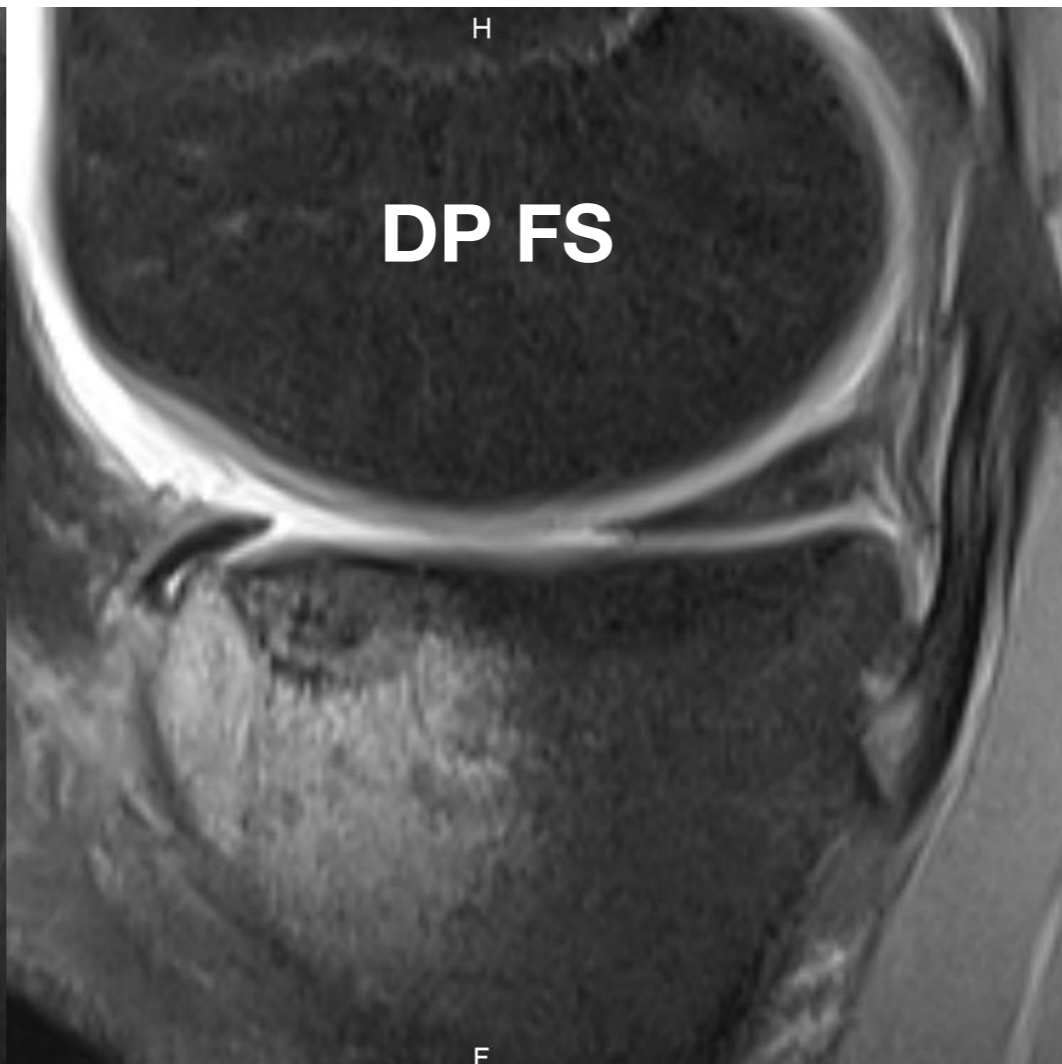
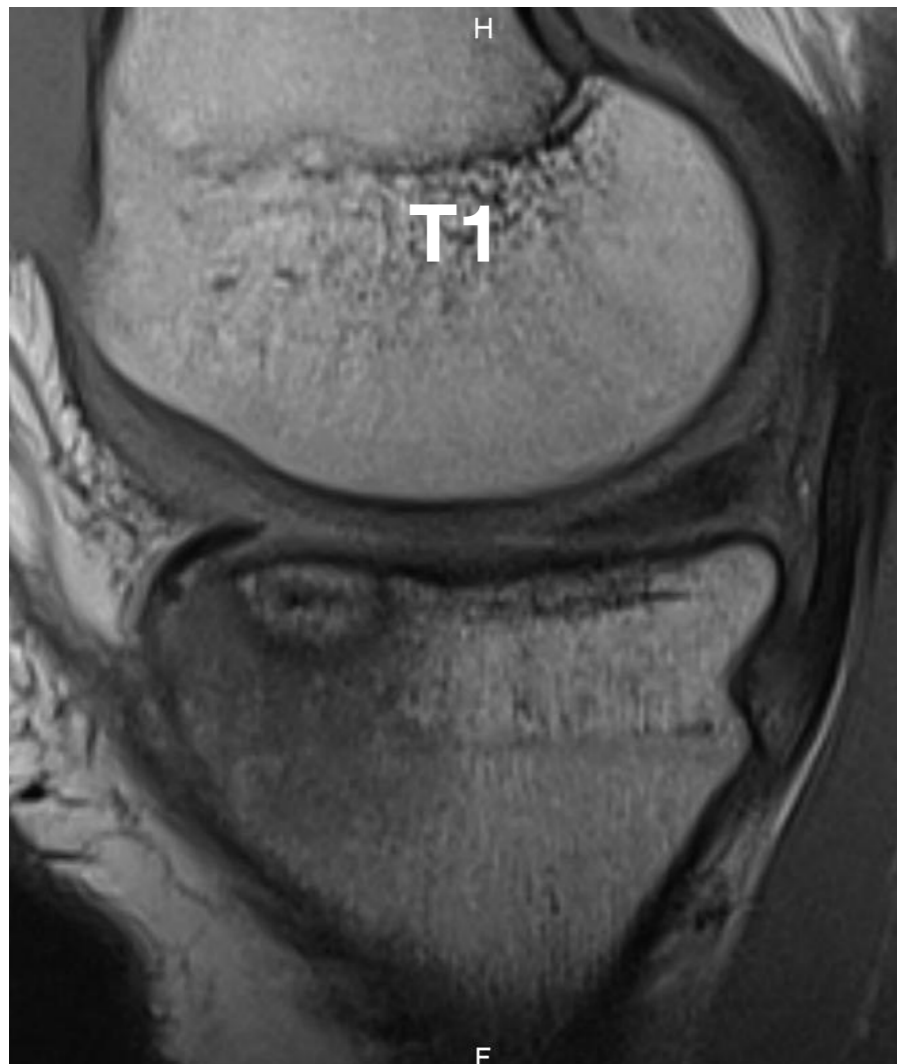## 4. Cartilage : Dissection et ostéochondrose



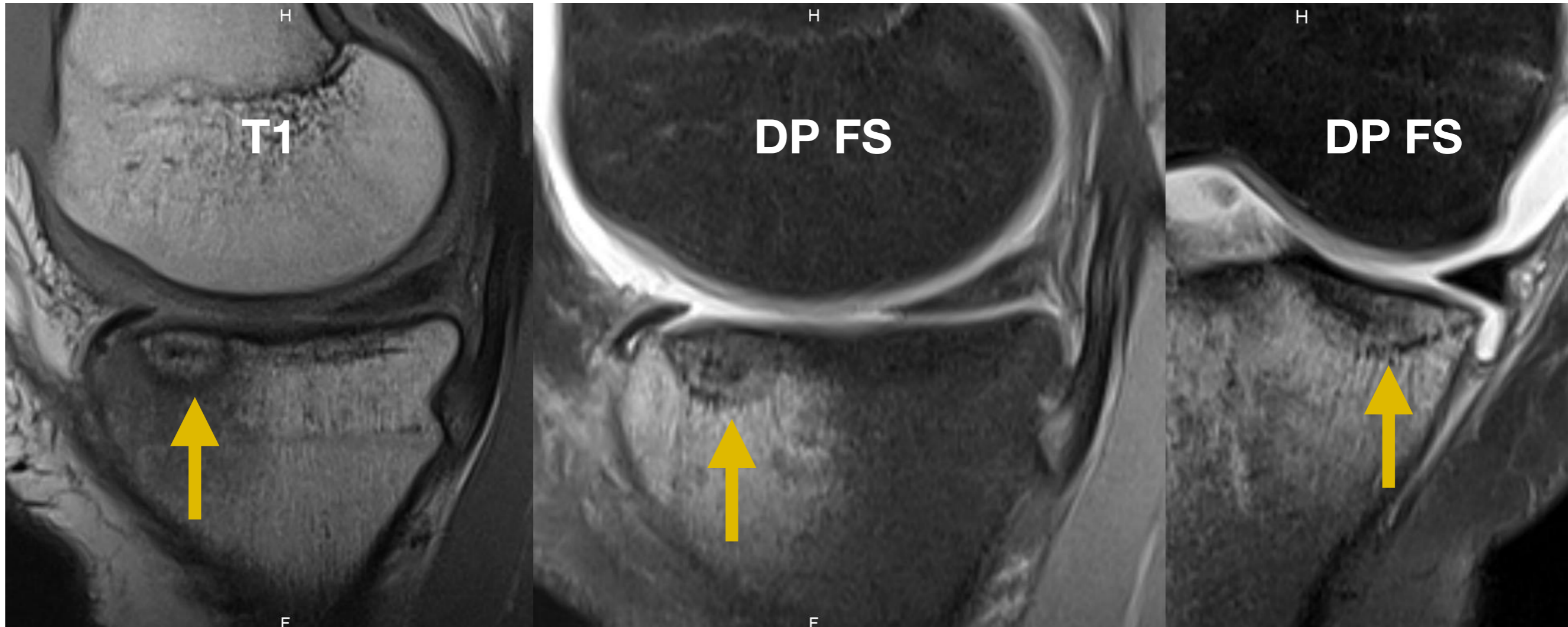
## 4. Cartilage : Dissection et ostéochondrose



# 4. Cartilage



# 4. Cartilage



Fracture sous-chondrale

# ARTHRO-TDM

VS

# ARTHRO-IRM

- **Bilan OS et CARTILAGE +++**

- Opacification des géodes

- **Bilan MENISQUE +++**

- **Bilan ménisque post op +++**

- Recherche de **fissure** sur suture méniscale

- Recherche de **désinsertion capsulo-méniscale** : scanner en extension et flexion

- Bilan OS et CARTILAGE ++

- Bilan MENISQUE ++

- Bilan ménisque post op ++

- Recherche de fissure sur suture méniscale

- Recherche de désinsertion capsulo-méniscale : scanner en extension et flexion

- **Détection OEDEME +++**

- Peut être couplée à l'ARTHRO-TDM grâce à l'opacification articulaire

# ARTHRO-TDM

VS

# ARTHRO-IRM

- **Bilan OS et CARTILAGE +++**

- Bilan OS et CARTILAGE ++

- Opacifica

- **Bilan MENI**

**Arthro-TDM > Arthro-IRM > IRM**

op ++

e sur suture

- **Bilan mé**

- Recherche de **fissure** sur suture méniscale

- Recherche de désinsertion capsulo-méniscale : scanner en extension et flexion

- Recherche de **désinsertion capsulo-méniscale** : scanner en extension et flexion

- **Détection OEDEME +++**

- Peut être couplée à l'ARTHRO-TDM grâce à l'opacification articulaire



# ARTHRO-TDM

VS

# ARTHRO-IRM

- **Bilan OS et CARTILAGE +++**

- Bilan OS et CARTILAGE ++

- Opacifica

- **Bilan MENI**

**Arthro-TDM > Arthro-IRM > IRM**

op ++

e sur suture

- **Bilan mé**

- Recherche  
suture mé

**IRM en 1ère intention**

Recherche de désinsertion  
capsulo-méniscale : scanner en  
extension et flexion

- Recherche de **désinsertion  
capsulo-méniscale** : scanner  
en extension et flexion

- **Détection OEDEME +++**

- Peut être couplée à l'ARTHRO-TDM  
grâce à l'opacification articulaire

# ARTHRO-TDM

VS

# ARTHRO-IRM

- **Bilan OS et CARTILAGE +++**

- Bilan OS et CARTILAGE ++

- Opacifica

- **Bilan MENISQUE**

**Arthro-TDM > Arthro-IRM > IRM**

op ++

e sur suture

- **Bilan mé**

- Recherche de désinsertion capsulo-méniscale : scanner en extension et flexion

**IRM en 1ère intention**

- Recherche de **désinsertion capsulo-méniscale** : scanner en extension et flexion

- **Détection OEDEME +++**

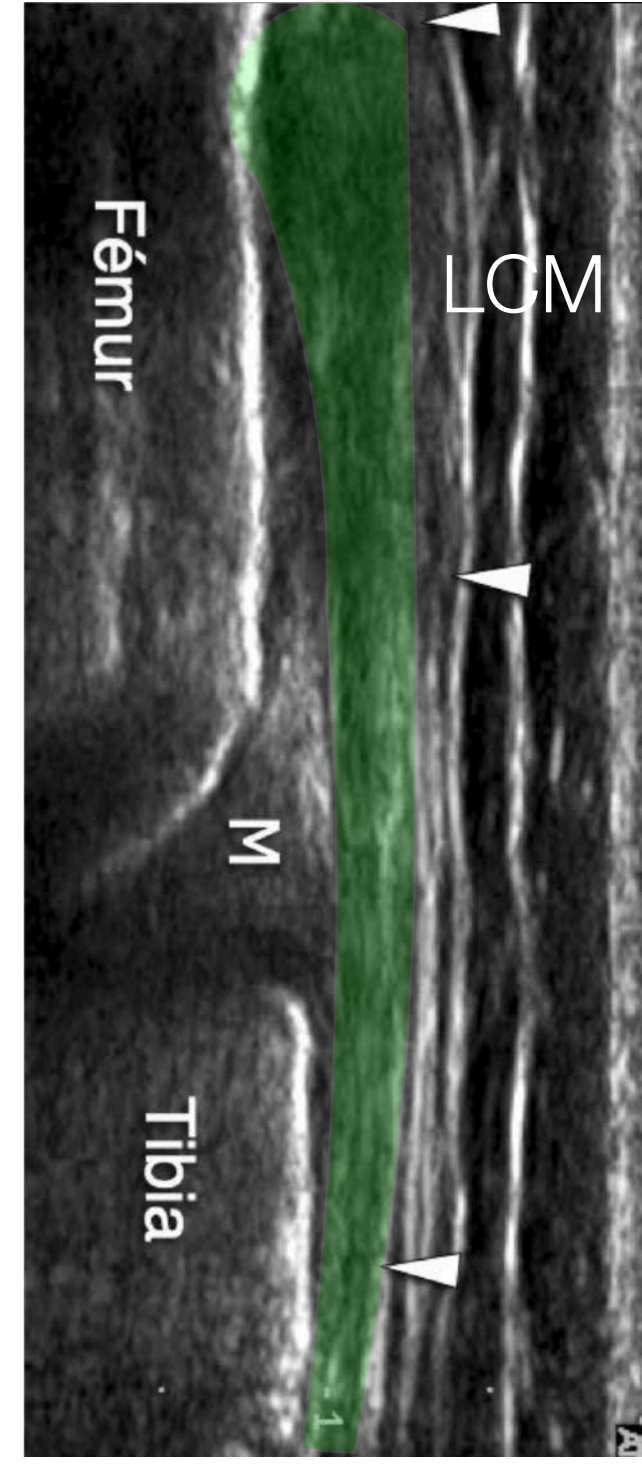
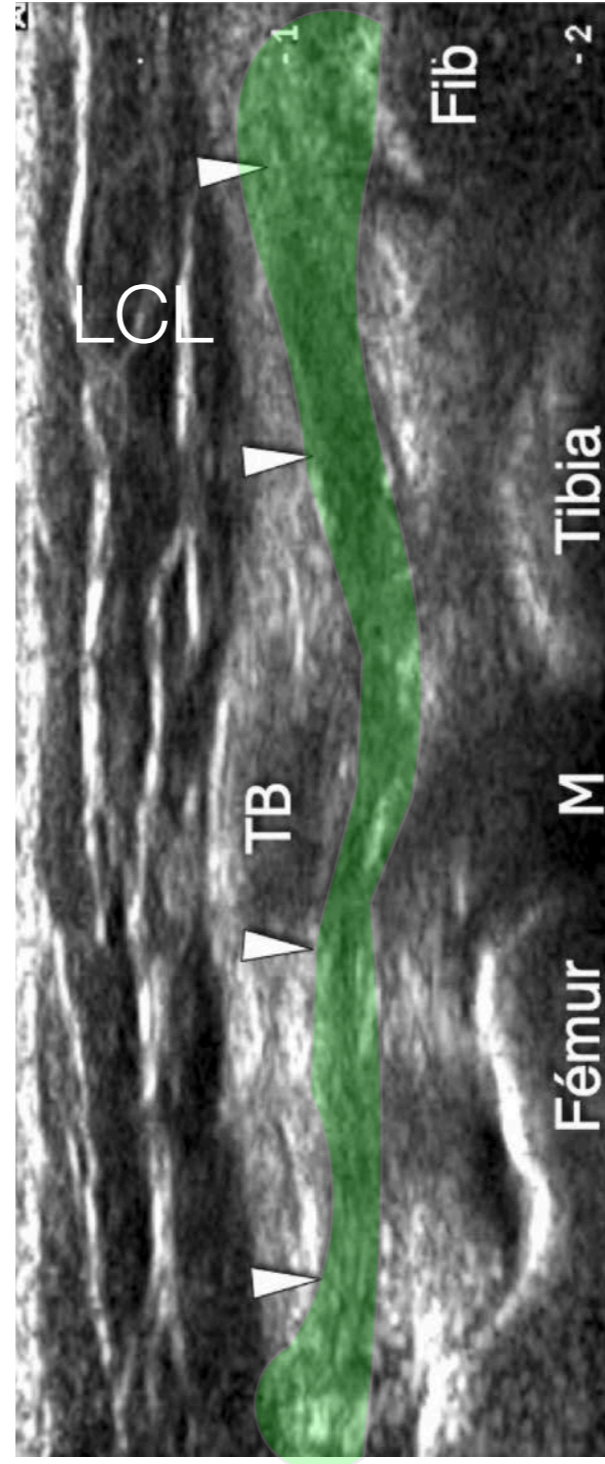
**Arthro-TDM en 2ème intention**

liée à l'ARTHRO-TDM  
opacification articulaire

# 5. Autres Techniques

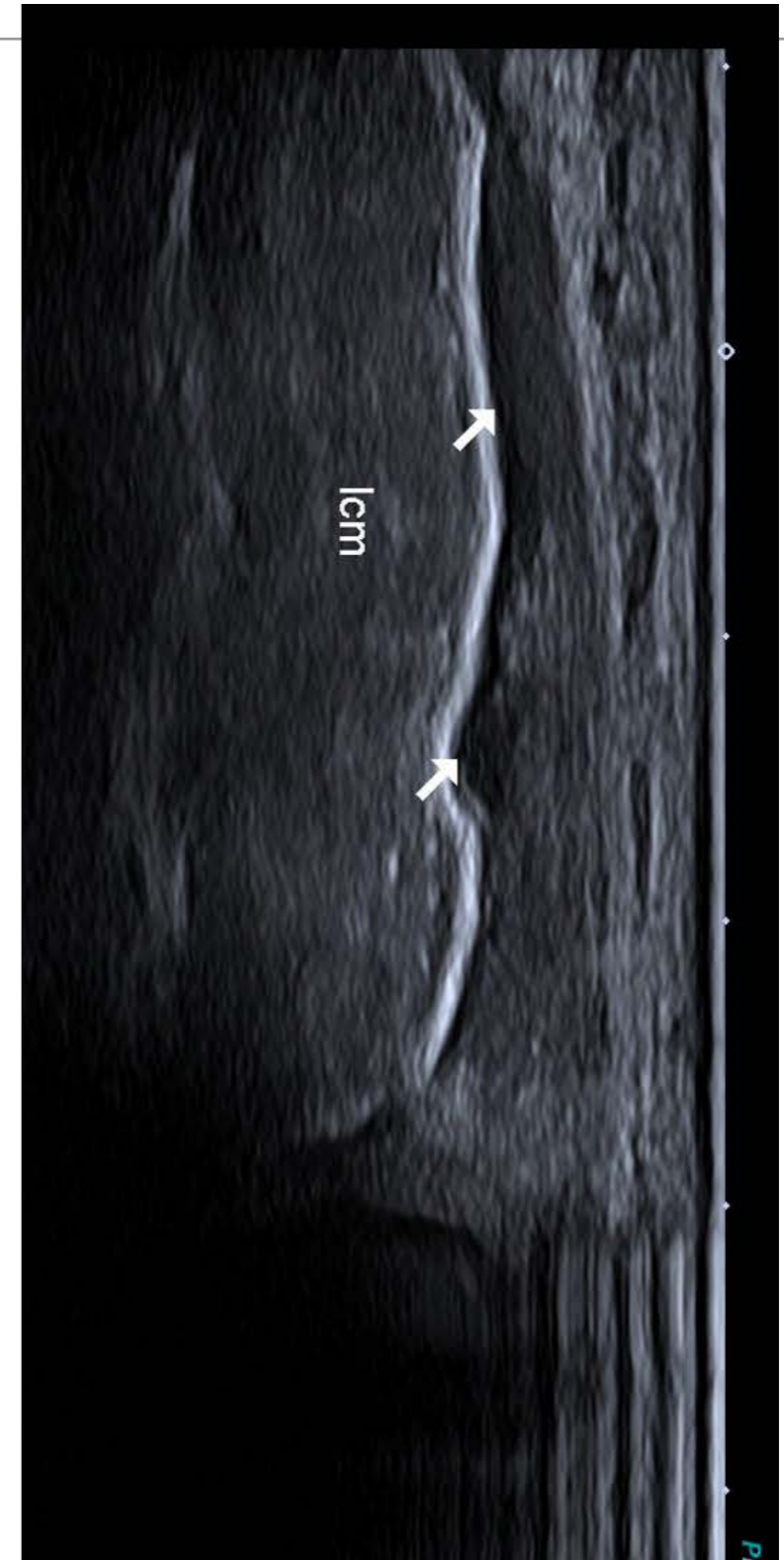
# 5. ECHOGRAPHIE

- Accessible
- Analyse :
  - **Ligaments collatéraux +++** mise en tension des ligaments avec mise en stress



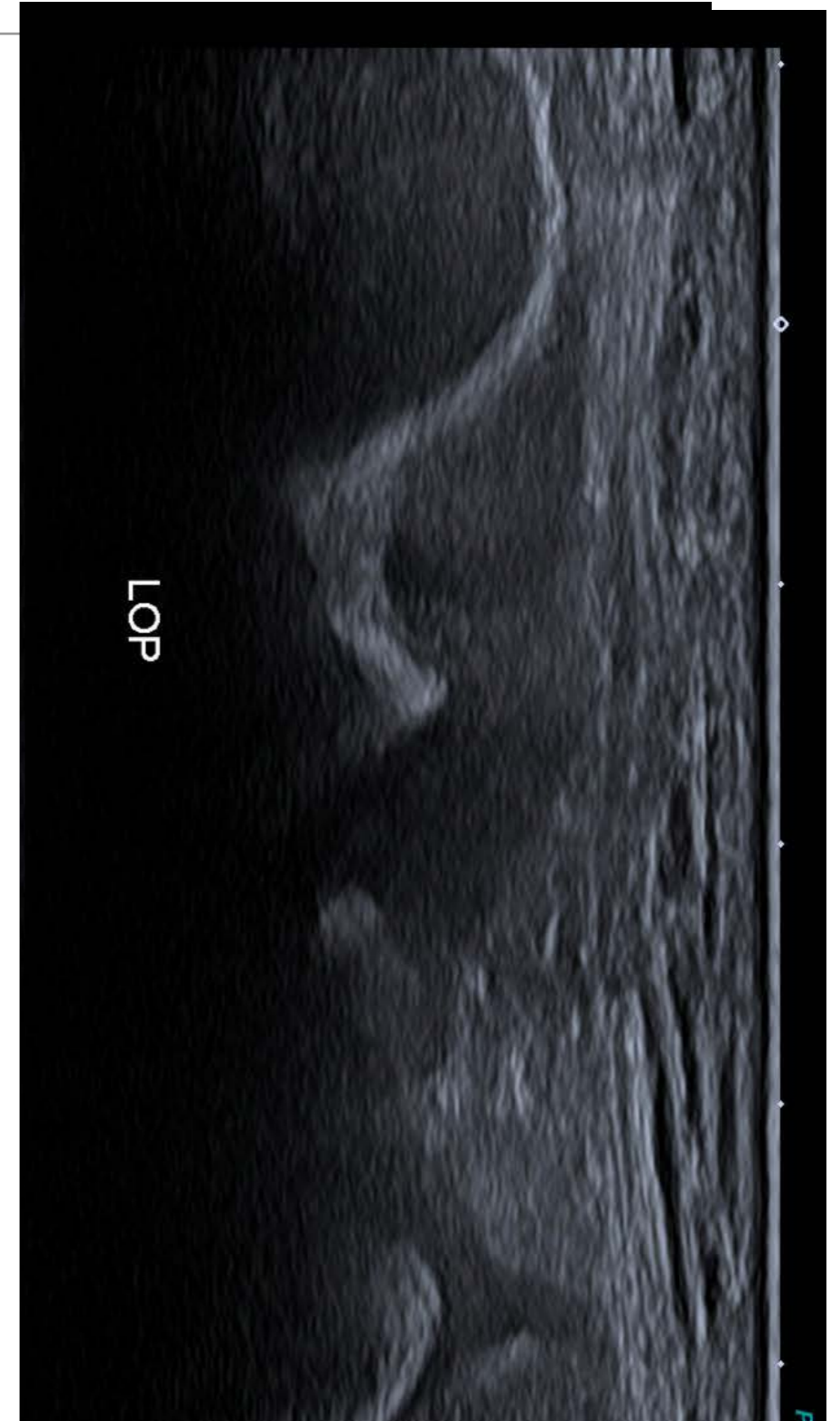
# 5. ECHOGRAPHIE

- Accessible
- Analyse :
  - **Ligaments collatéraux +++** mise en tension des ligaments avec mise en stress



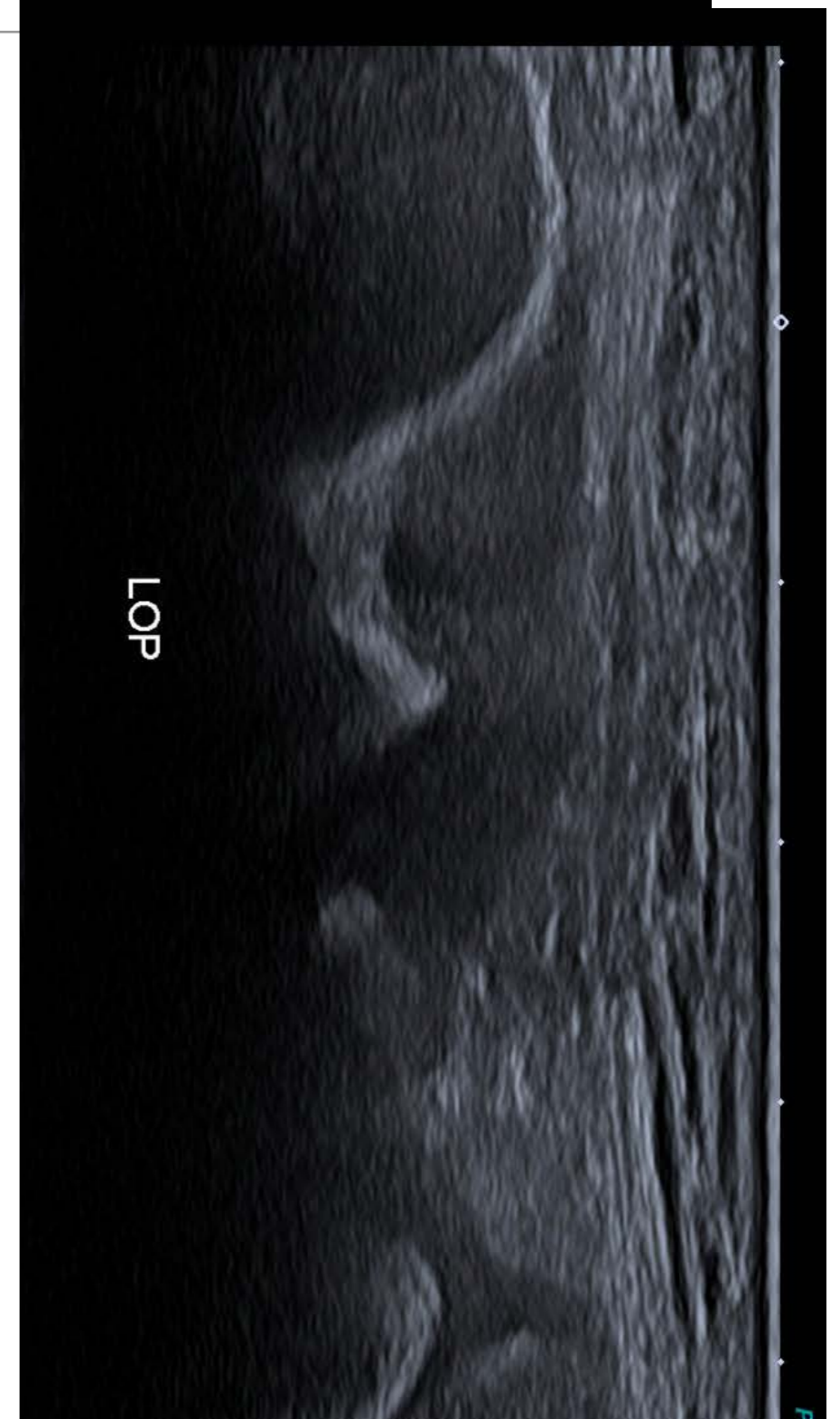
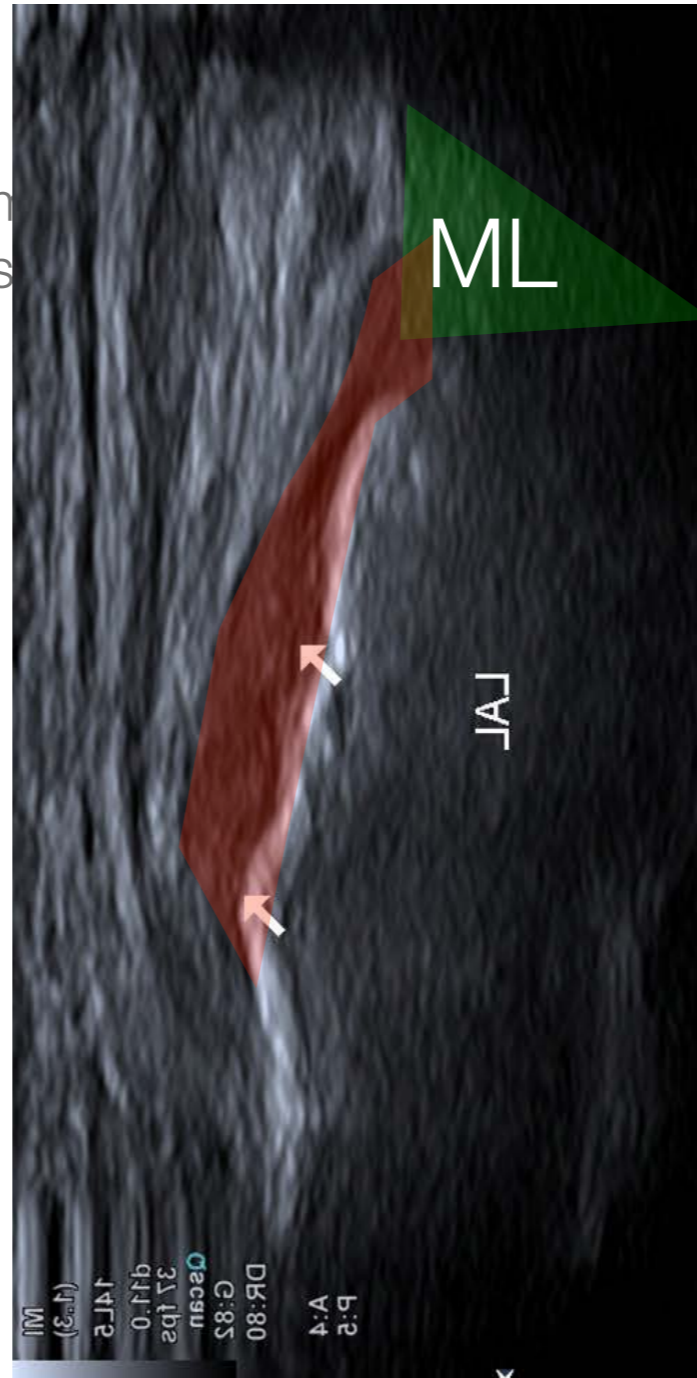
# 5. ECHOGRAPHIE

- Accessible
- Analyse :
  - **Ligaments collatéraux +++** mise en tension des ligaments avec mise en stress



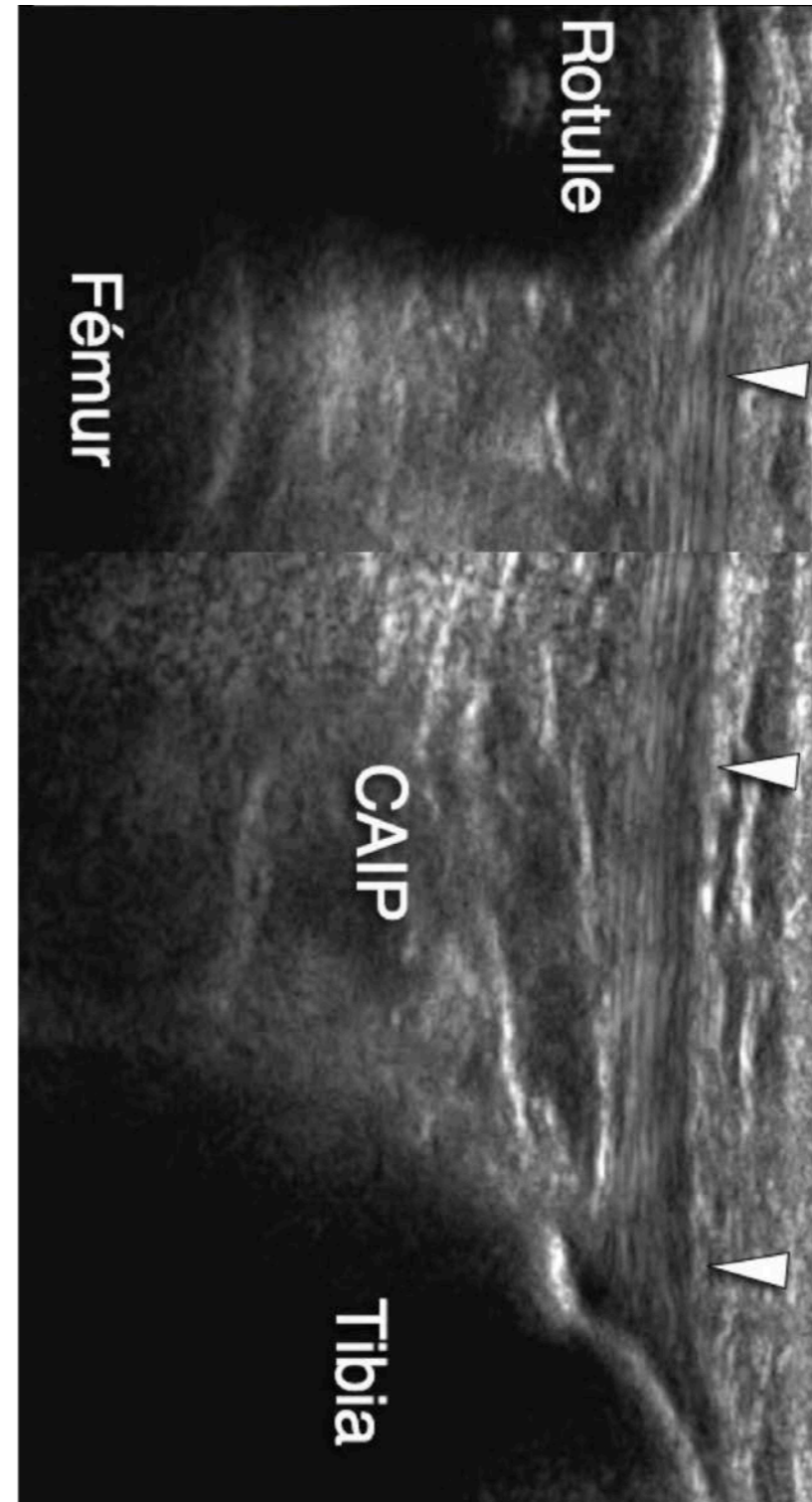
# 5. ECHOGRAPHIE

- Accessible
- Analyse :
  - **Ligaments collatéraux +++** n
  - tension des ligaments avec mis
  - stress



# 5. ECHOGRAPHIE

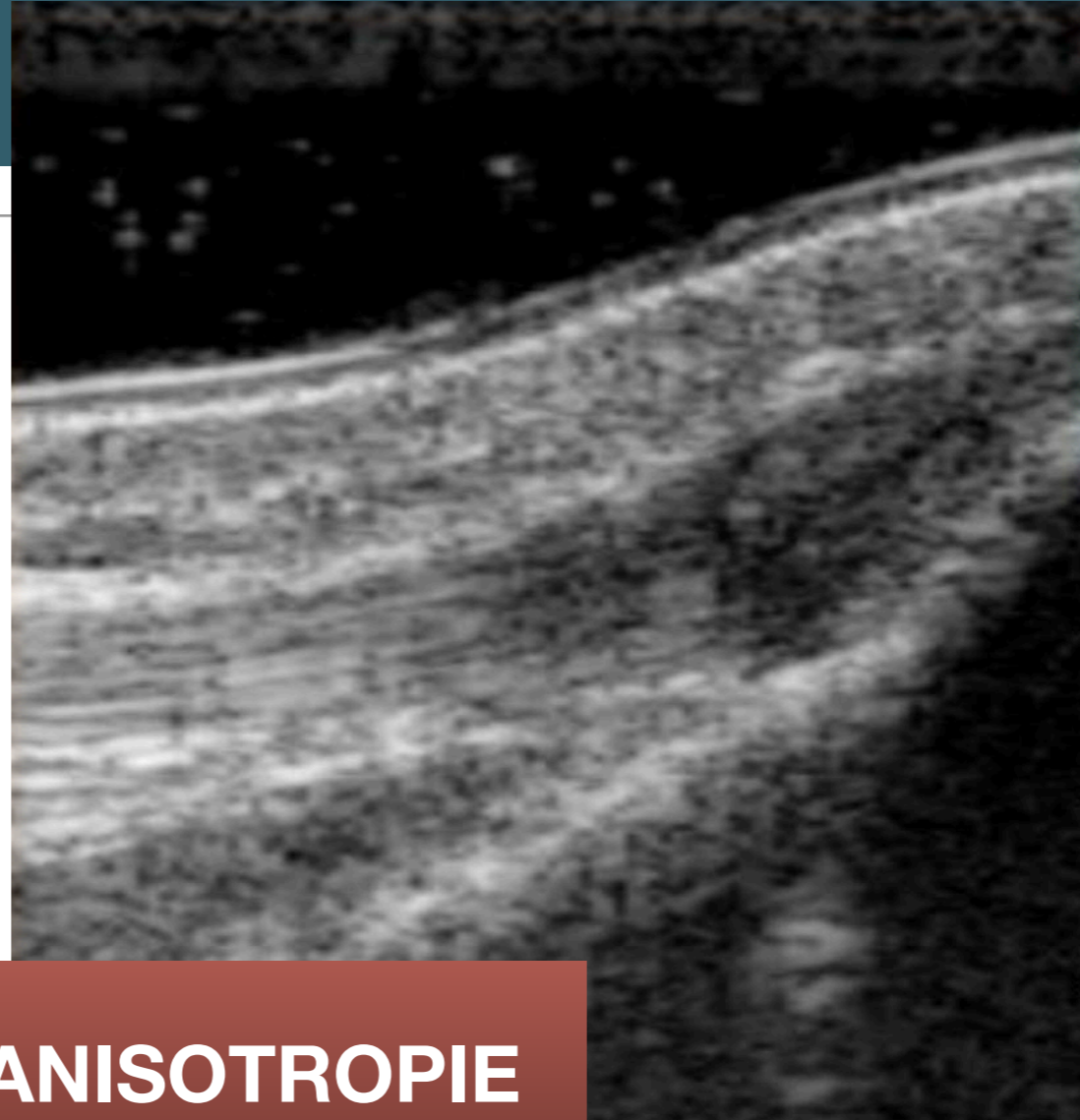
- Accessible
- Analyse :
  - Ligaments collatéraux +++ mise en tension des ligaments avec mise en stress
  - **Tendons +++**





# 5. ECHOGRAPHIE

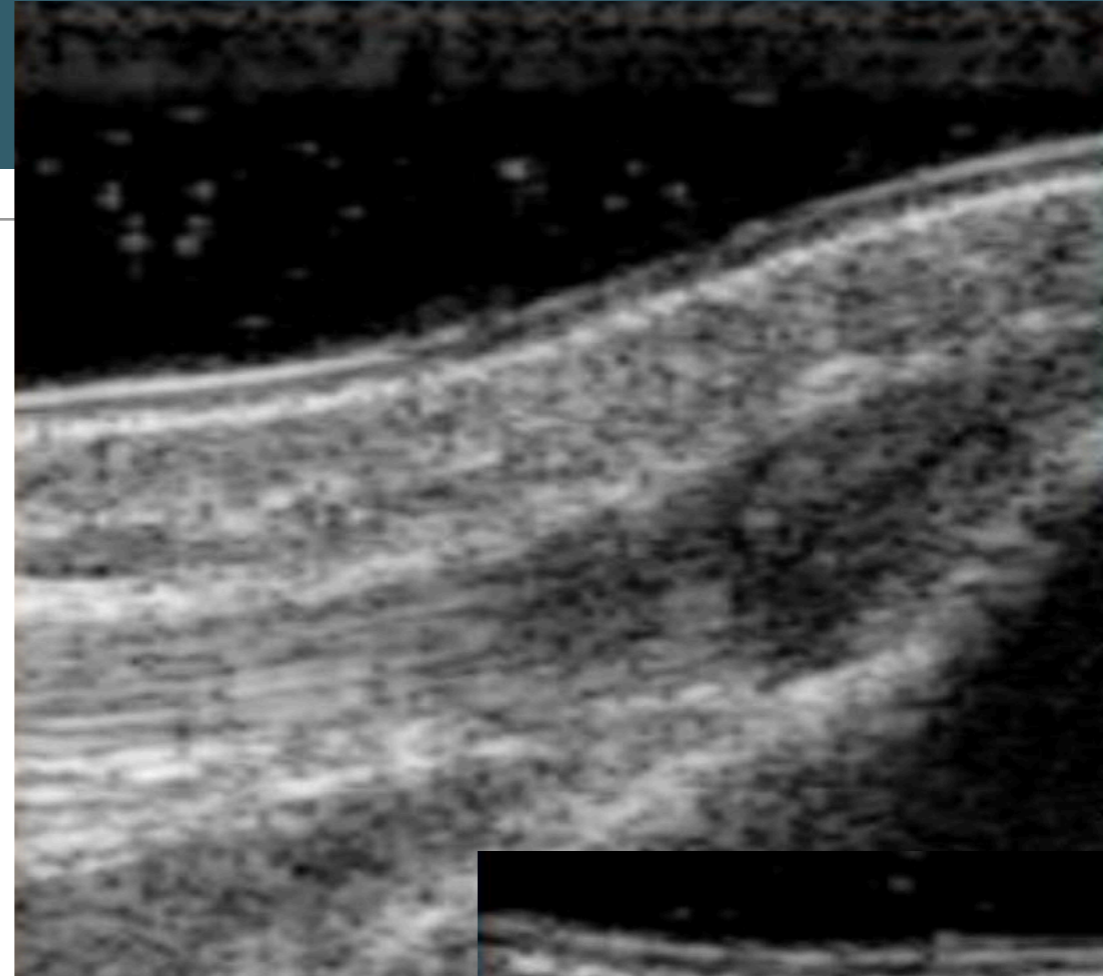
- Accessible
- Analyse :
  - Ligaments collatéraux +++ mise en tension des ligaments avec mise en stress
  - **Tendons +++**



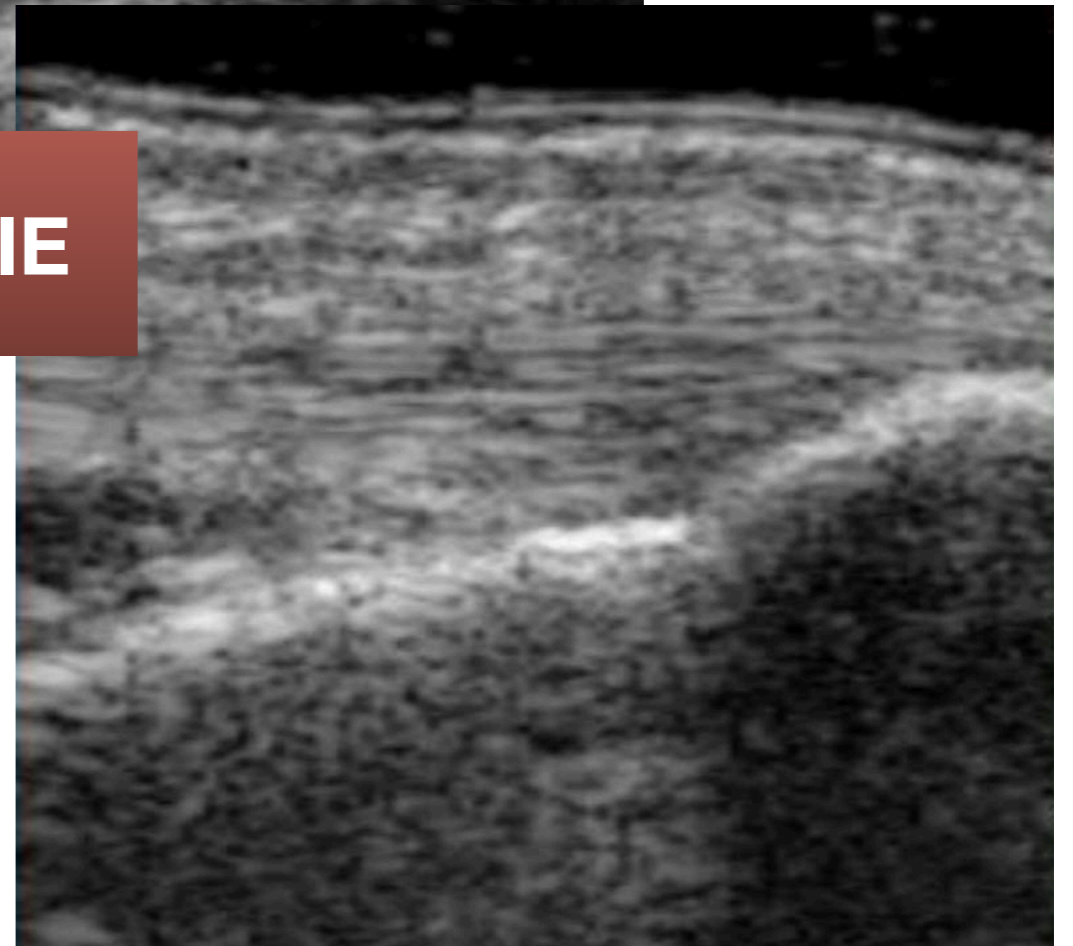
**ANISOTROPIE**

# 5. ECHOGRAPHIE

- Accessible
- Analyse :
  - Ligaments collatéraux +++ mise en tension des ligaments avec mise en stress
  - **Tendons +++**

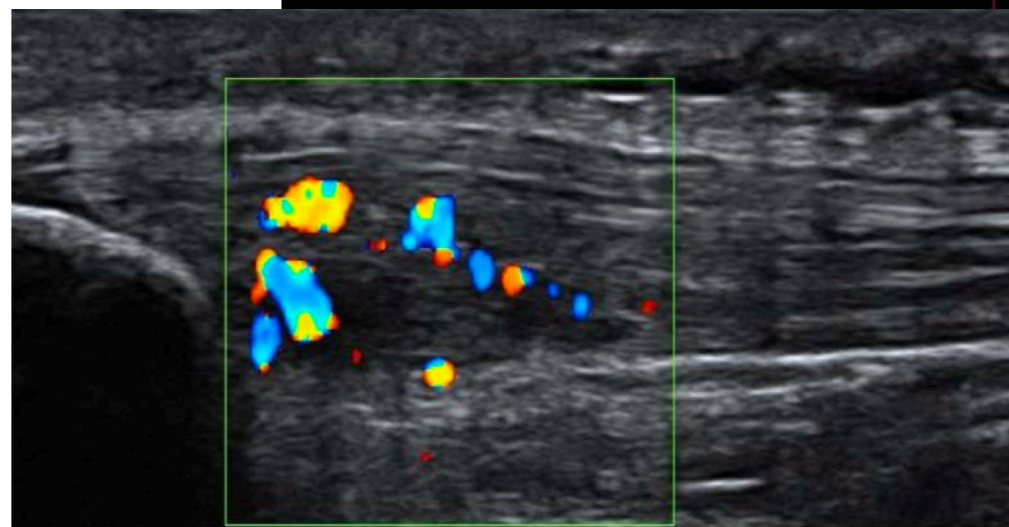
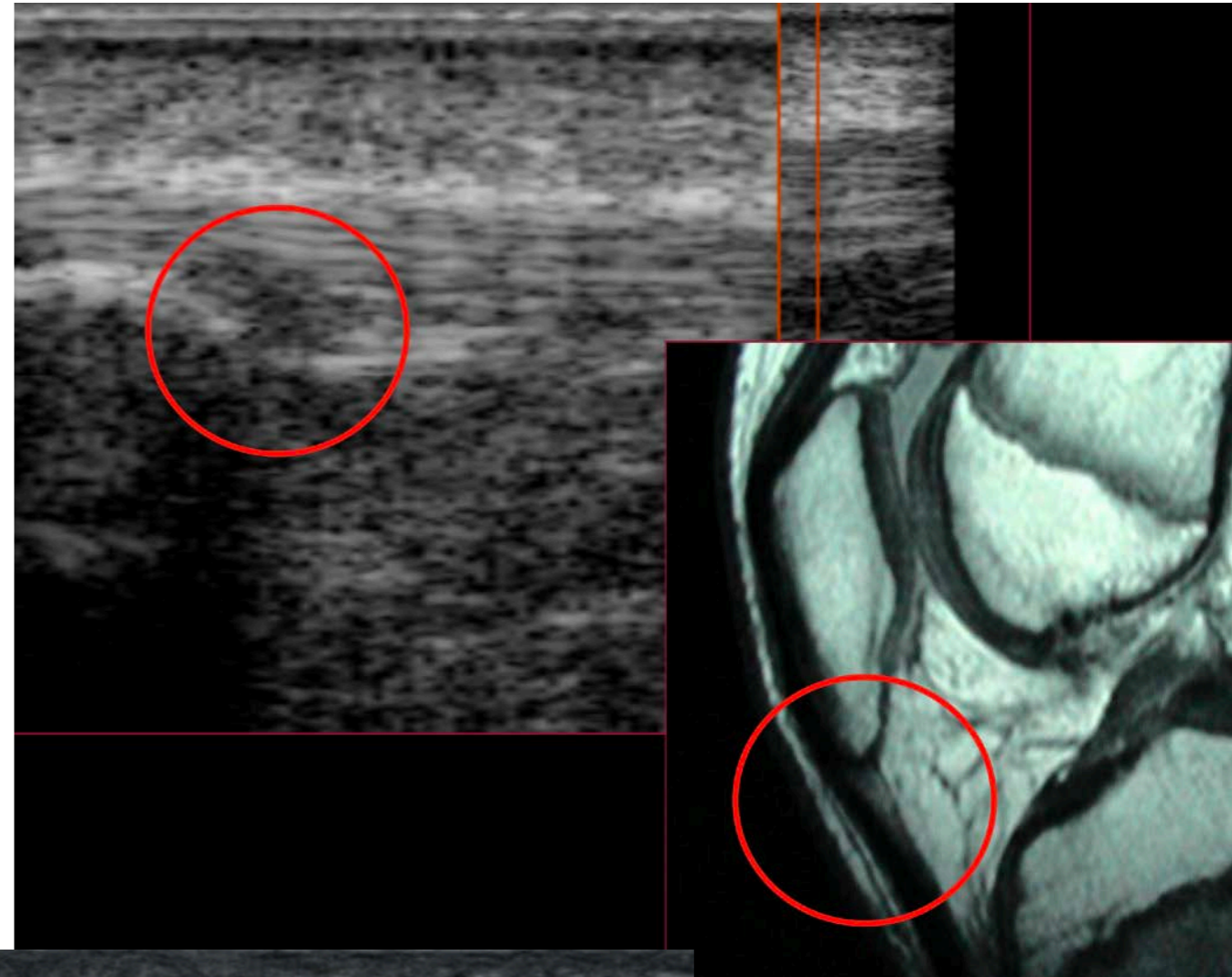


**ANISOTROPIE**



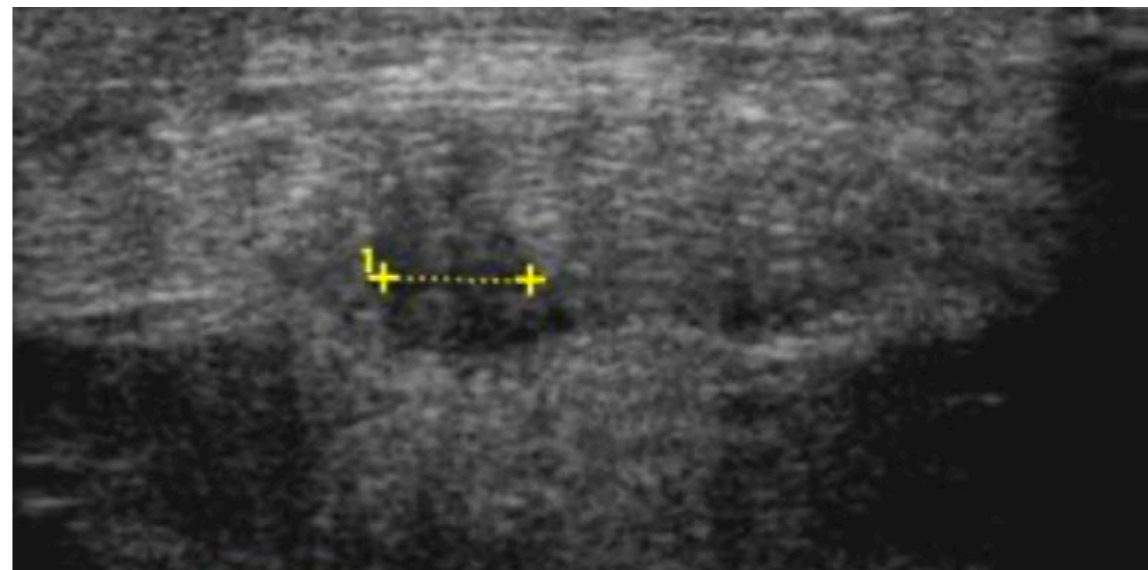
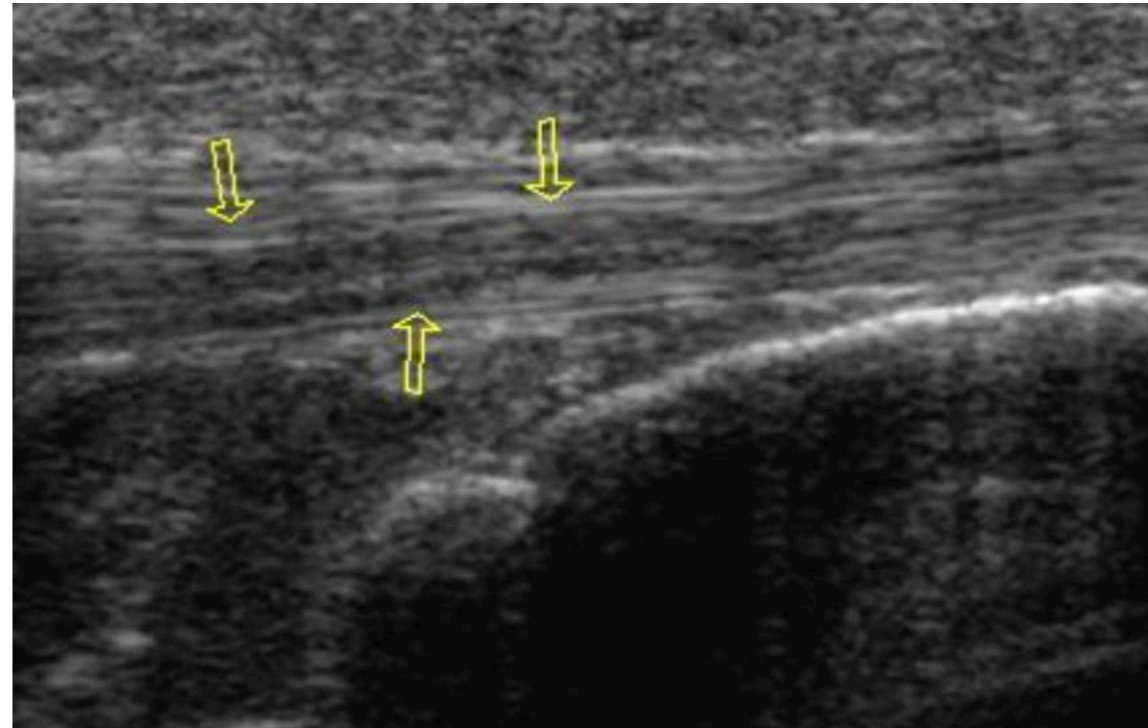
# 5. ECHOGRAPHIE

- Accessible
- Analyse :
  - Ligaments collatéraux +++ mise en tension des ligaments avec mise en stress
  - **Tendons +++**



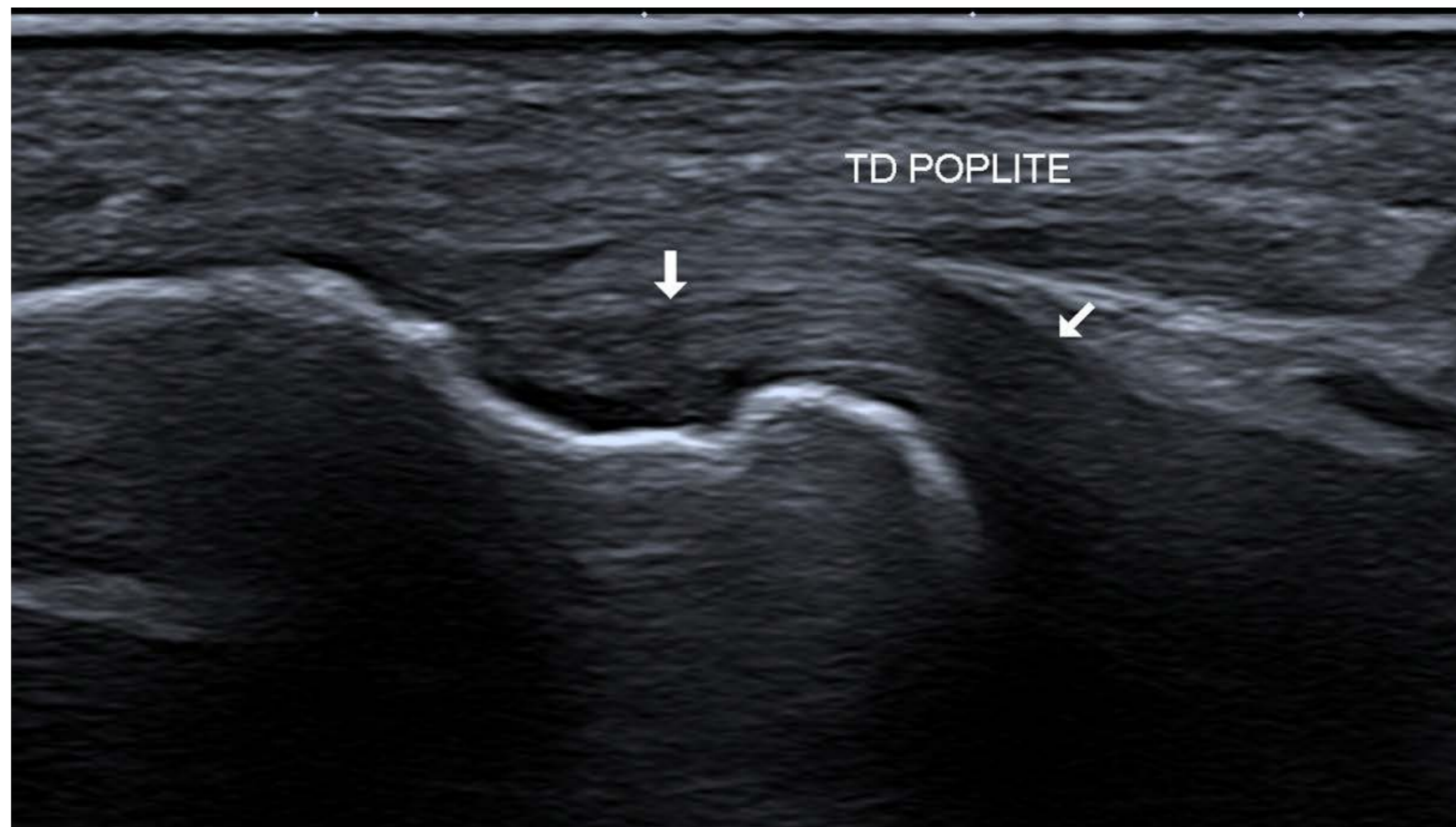
# 5. ECHOGRAPHIE

- Accessible
- Analyse :
  - Ligaments collatéraux +++ mise en tension des ligaments avec mise en stress
  - **Tendons +++**



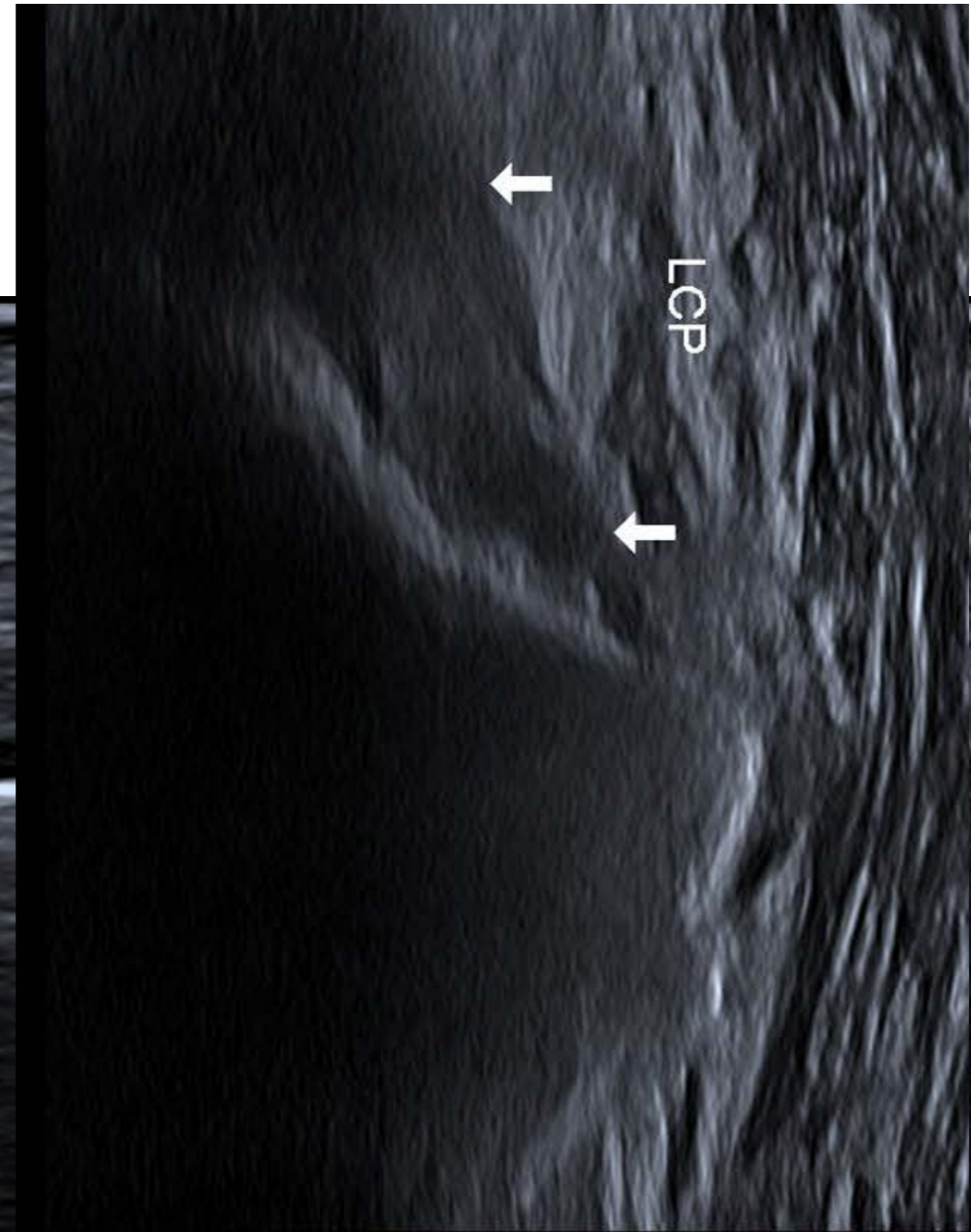
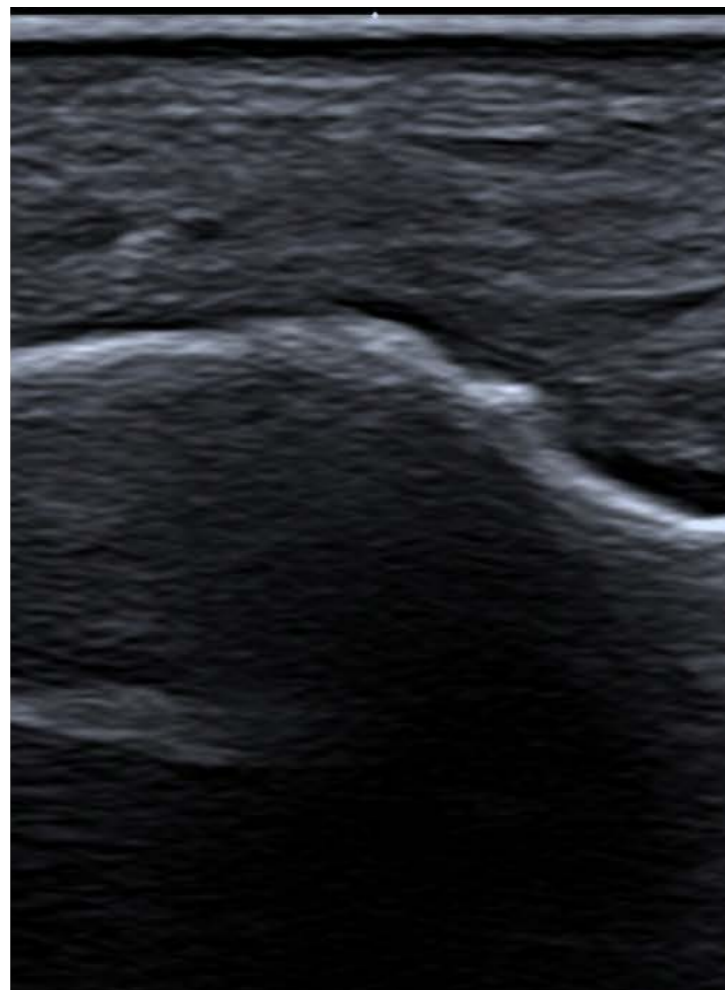# 5. ECHOGRAPHIE

- Accessible
- Analyse :
  - Ligaments collatéraux +++ mise en tension des ligaments avec mise en stress
  - **Tendons +++**



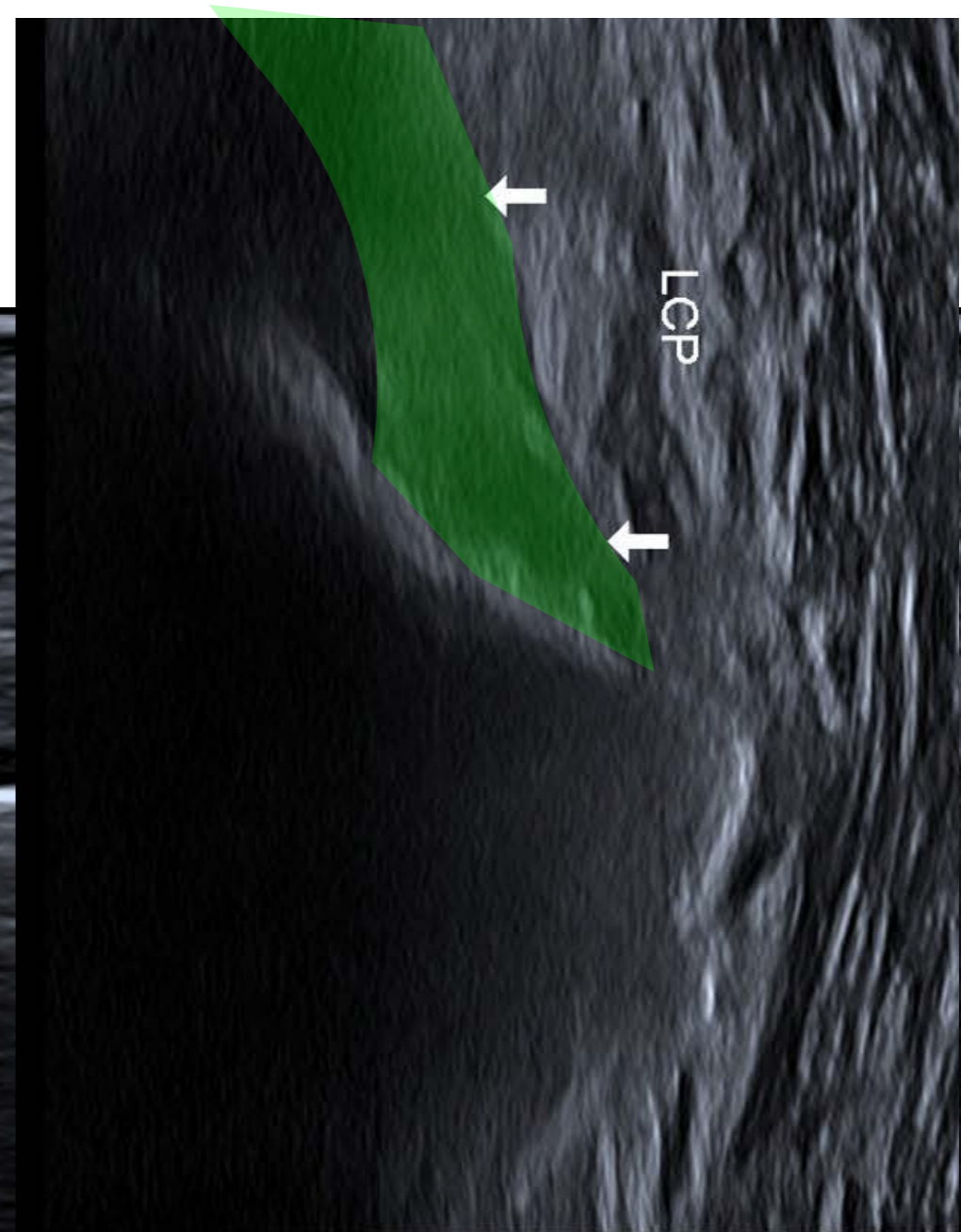
# 5. ECHOGRAPHIE

- Accessible
- Analyse :
  - Ligaments collatéraux +++ mise en tension des ligaments avec mise en stress
  - **Tendons +++**



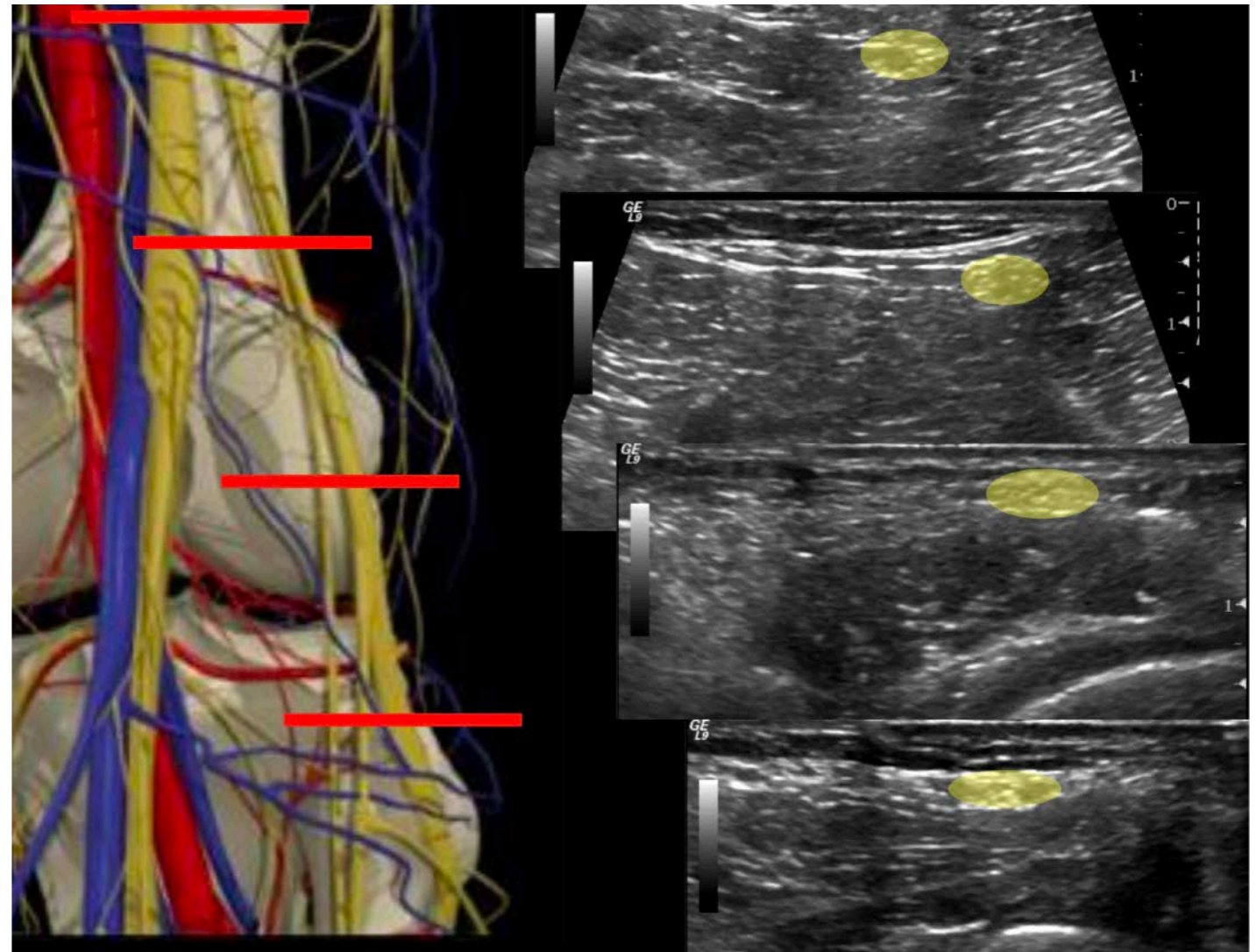
# 5. ECHOGRAPHIE

- Accessible
- Analyse :
  - Ligaments collatéraux +++ mise en tension des ligaments avec mise en stress
  - **Tendons +++**



# 5. ECHOGRAPHIE

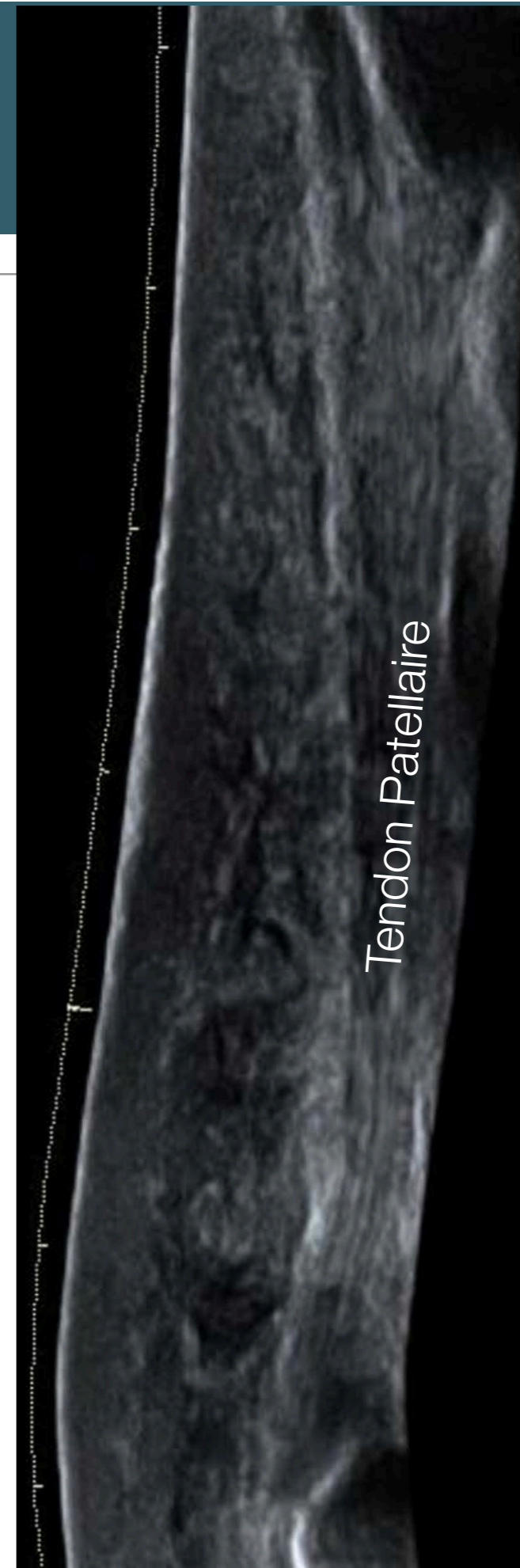- Accessible
- Analyse :
  - Ligaments collatéraux +++ mise en tension des ligaments avec mise en stress
  - Tendons +++
  - **Nerfs +++**





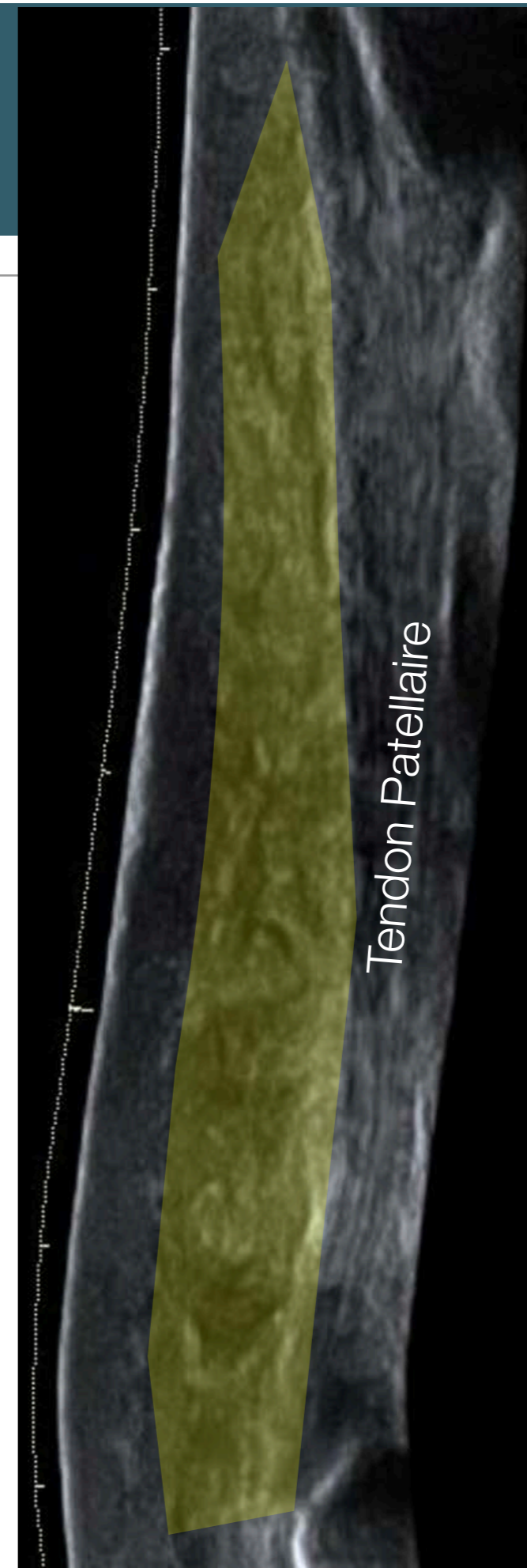
# 5. ECHOGRAPHIE

- Accessible
- Analyse :
  - Ligaments collatéraux +++ mise en tension des ligaments avec mise en stress
  - Tendons +++
  - Nerfs +++
  - **Tissus sous cutanées**



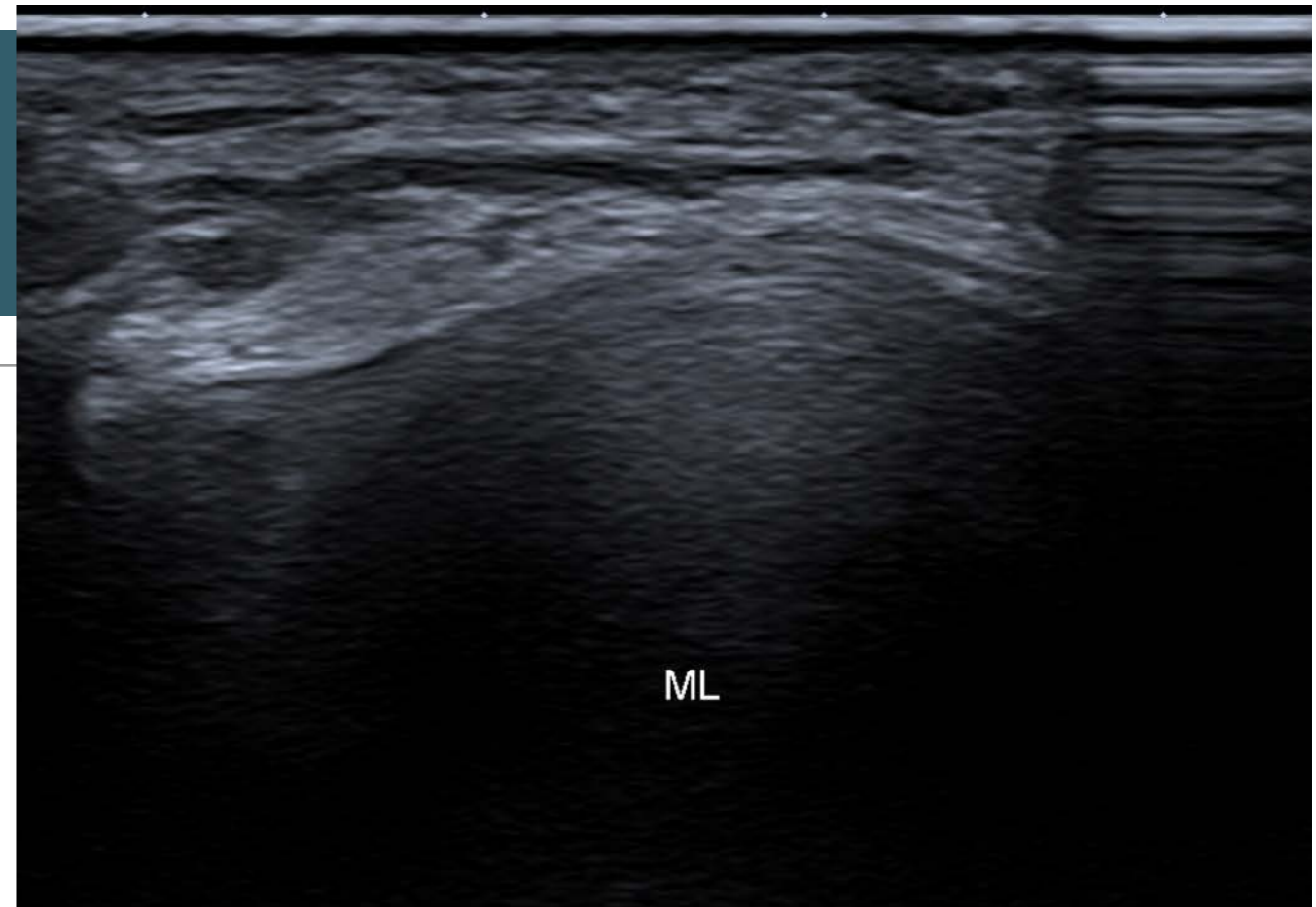
# 5. ECHOGRAPHIE

- Accessible
- Analyse :
  - Ligaments collatéraux +++ mise en tension des ligaments avec mise en stress
  - Tendons +++
  - Nerfs +++
  - **Tissus sous cutanées**



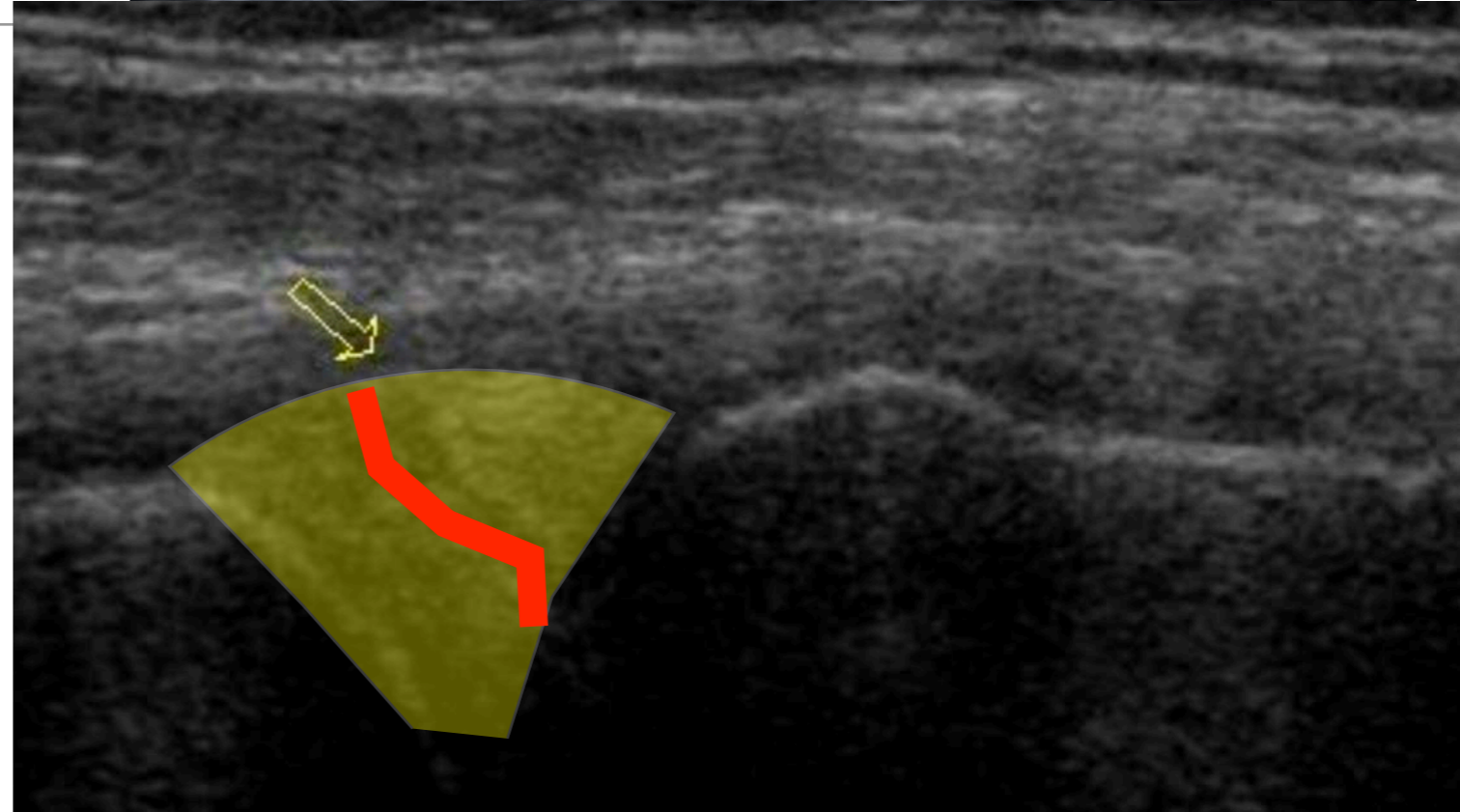
# 5. ECHOGRAPHIE

- Accessible
- Analyse :
  - Ligaments collatéraux +++ mise en tension des ligaments avec mise en stress
  - Tendons +++
  - Nerfs +++
  - Tissus sous cutanées
  - Ménisques -



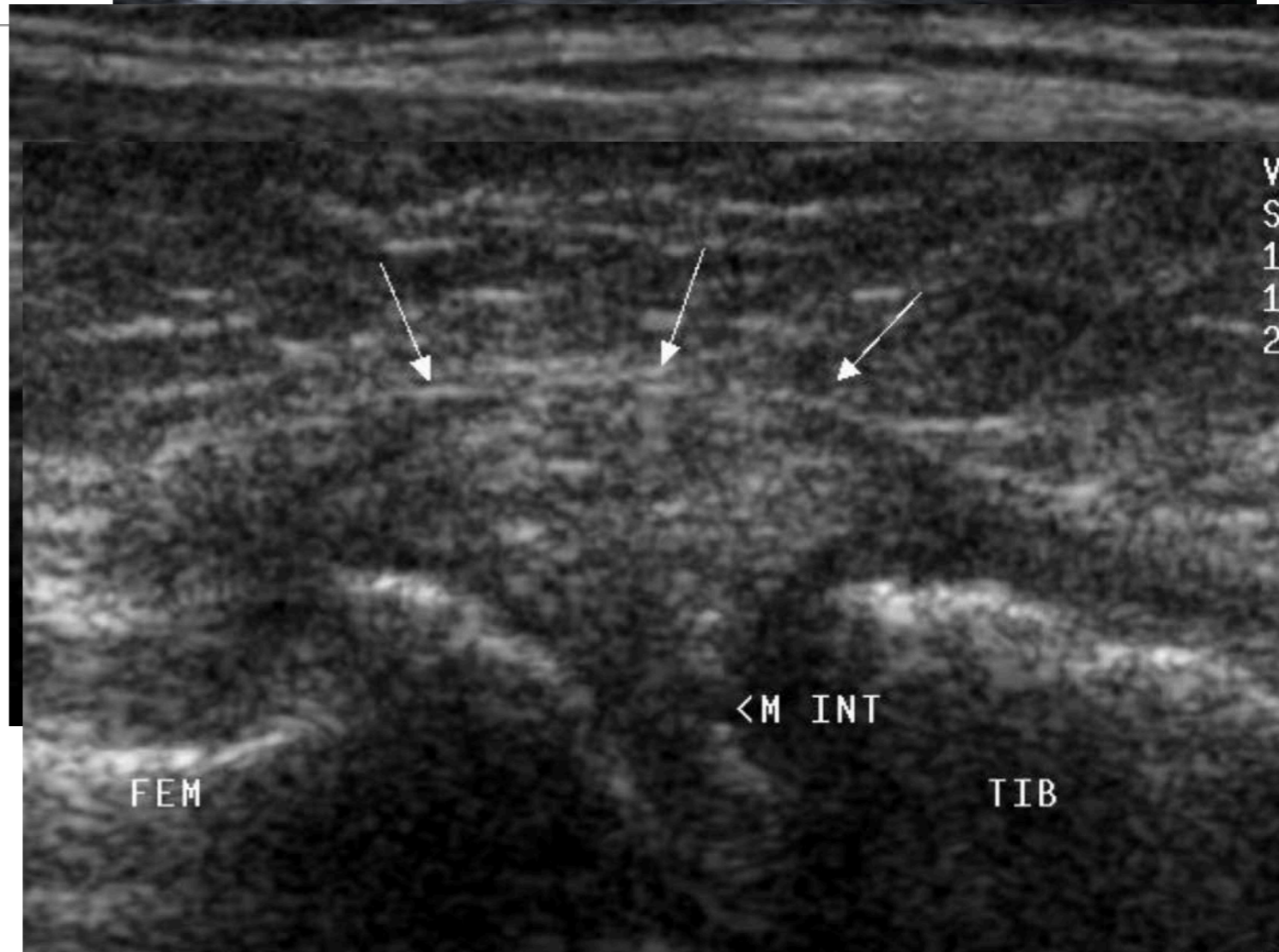
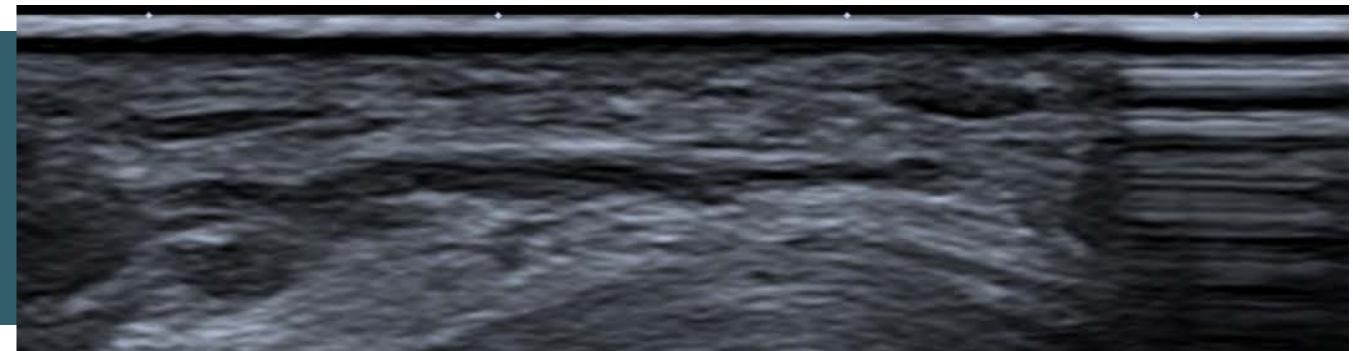
# 5. ECHOGRAPHIE

- Accessible
- Analyse :
  - Ligaments collatéraux +++ mise en tension des ligaments avec mise en stress
  - Tendons +++
  - Nerfs +++
  - Tissus sous cutanées
  - Ménisques -



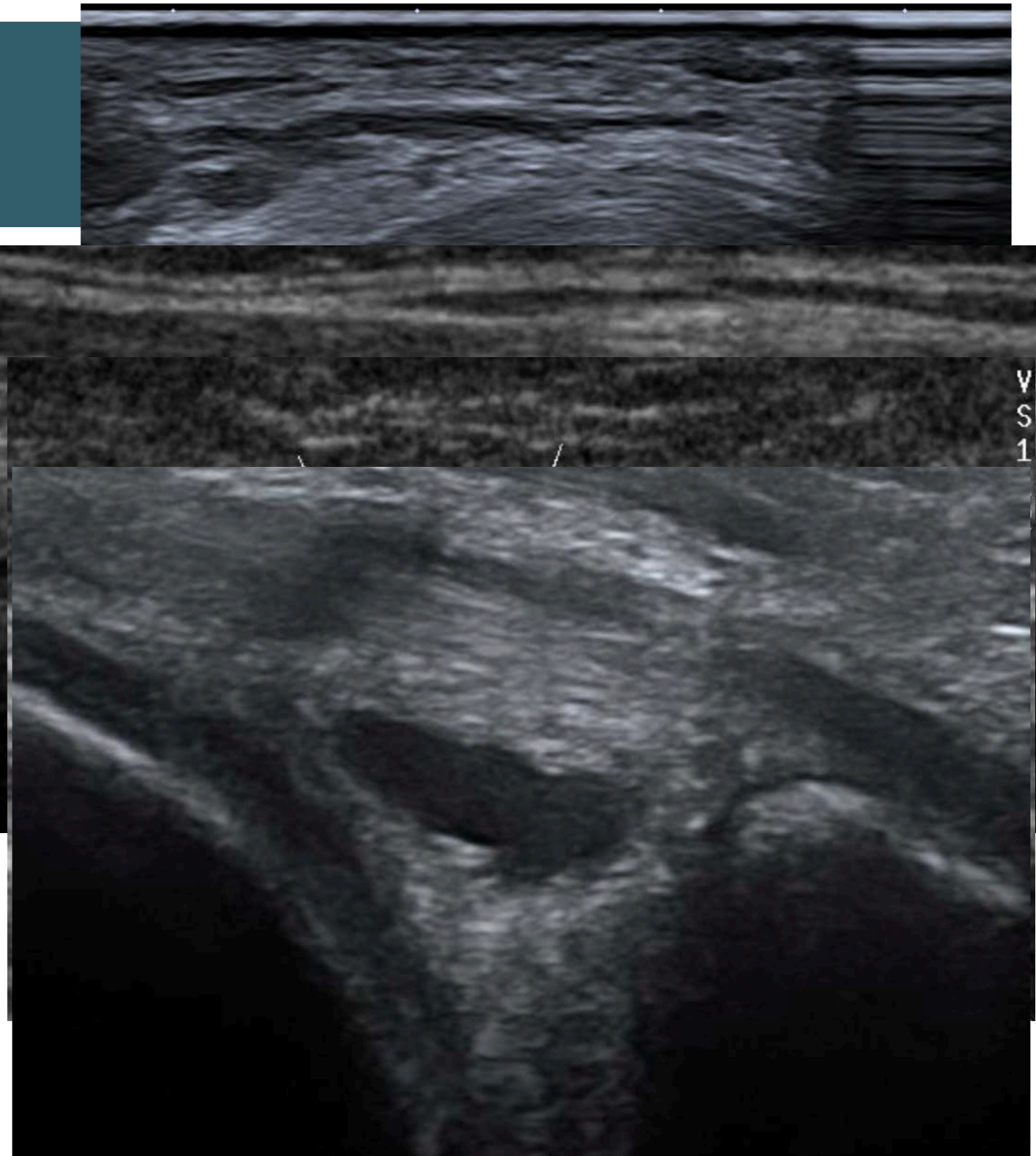
# 5. ECHOGRAPHIE

- Accessible
- Analyse :
  - Ligaments collatéraux +++ mise en tension des ligaments avec mise en stress
  - Tendons +++
  - Nerfs +++
  - Tissus sous cutanées
  - Ménisques -



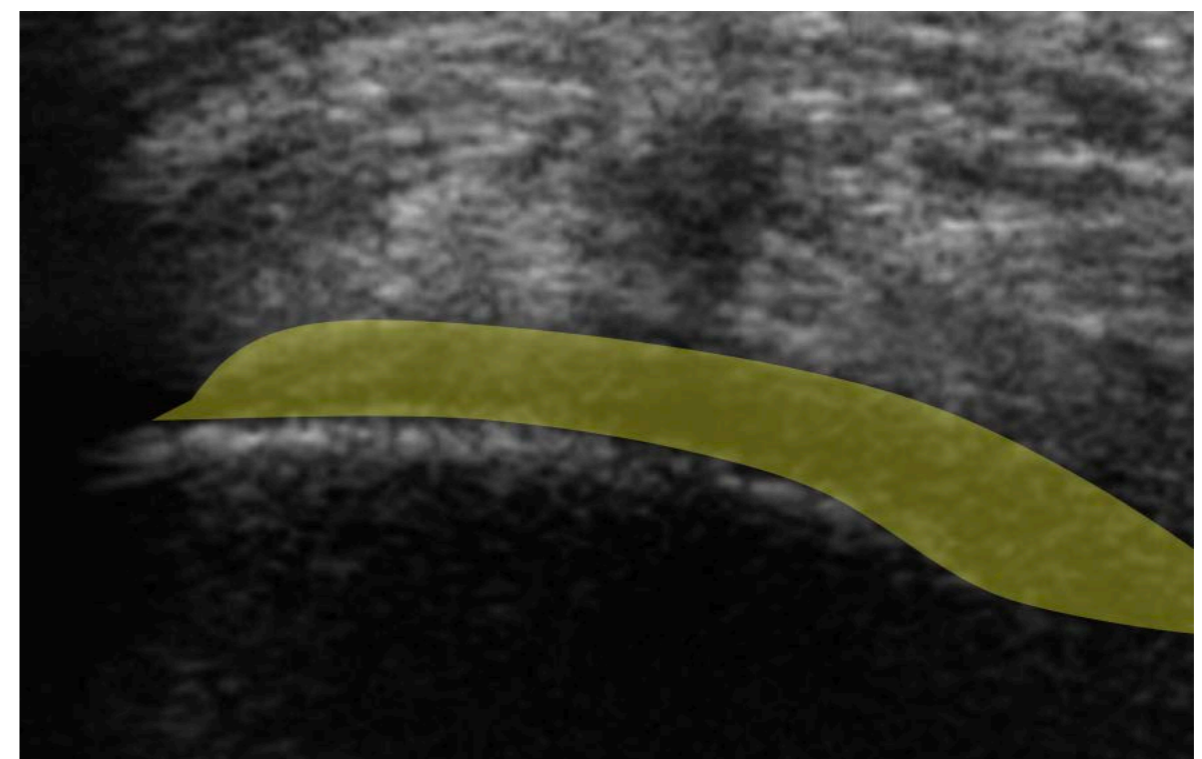
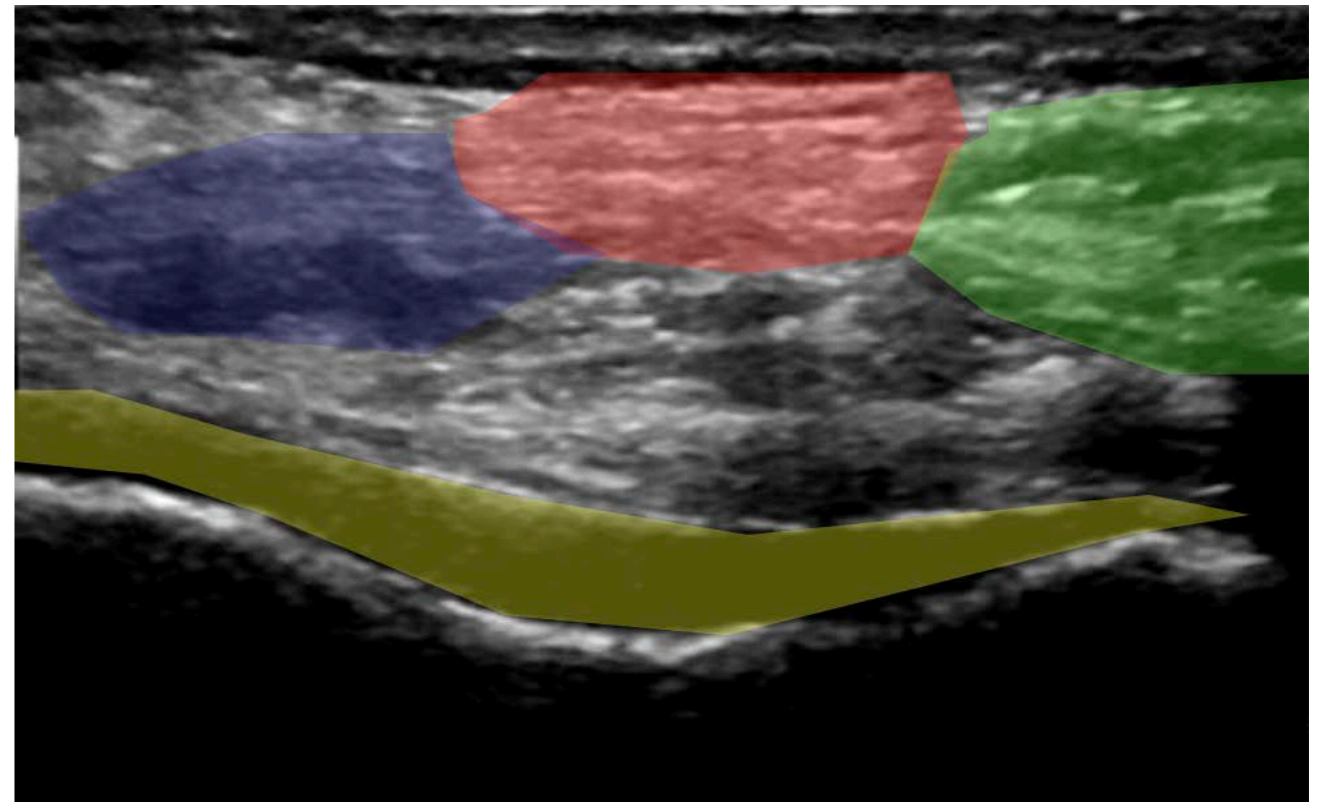
# 5. ECHOGRAPHIE

- Accessible
- Analyse :
  - Ligaments collatéraux +++ mise en tension des ligaments avec mise en stress
  - Tendons +++
  - Nerfs +++
  - Tissus sous cutanées
  - Ménisques -



# 5. ECHOGRAPHIE

- Accessible
- Analyse :
  - Ligaments collatéraux +++ mise en tension des ligaments avec mise en stress
  - Tendons +++
  - Nerfs +++
  - Tissus sous cutanées
  - Ménisques -
  - LCP -
  - Forme Trochlée



- 
- FIN