

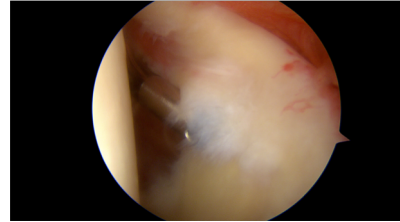
## Technique de Ténotomie / Ténodèse du Long Biceps

Pr Nicolas Bonneville, MD, PhD  
CHU de Toulouse

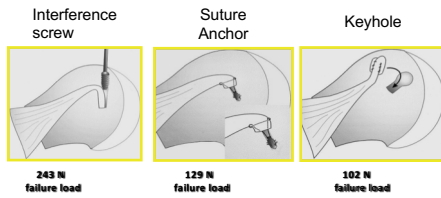


### Ténotomie en Parachute: effet Ténodèse

- Emportant le pied de l'insertion (LB + Labrum)

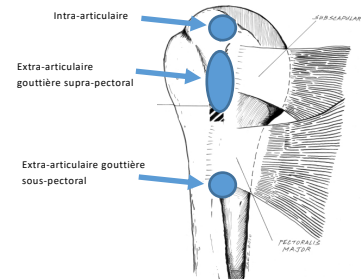


### Biomécanique de l'Ancre



Ozaly Arthroscopy 2005

### Anatomie de l'Ancre

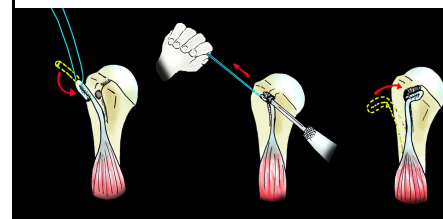


### Ténodèse à l'Ancre

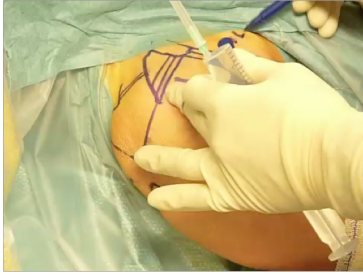

### Original Article With Video Illustration Arthroscopic Biceps Tenodesis: A New Technique Using Bioabsorbable Interference Screw Fixation

Pascal Boileau, M.D., Sumant G. Krishnan, M.D., Jean-Sebastien Coste, M.D.,  
and Gilles Walch, M.D.



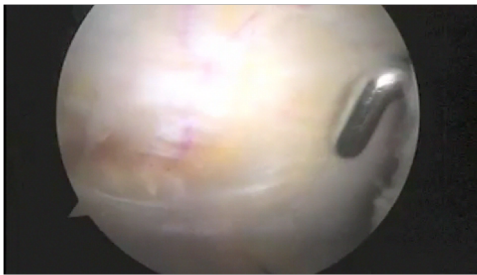
### Ténoùèse avec Vis d'Interférence



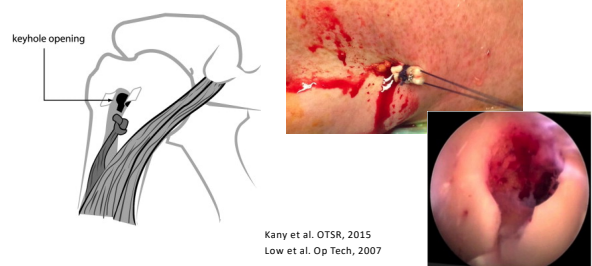### Attention à la SUR-TENSION



### Ténoùèse au Fil

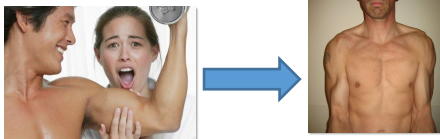


### Ténoùèse Trou de Serrure: « Keyhole »

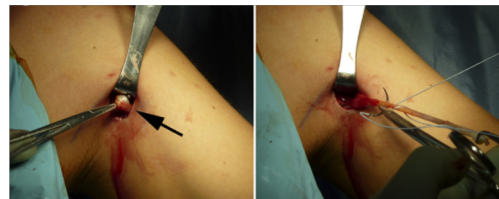

### Comment Traiter un Echec de Ténoùèse ?

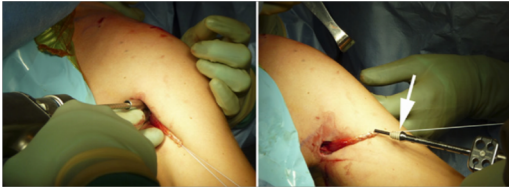
- Douleur: Ténotomie
- Popeye précoce: Ténoùèse sous pectorale



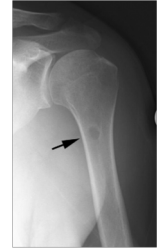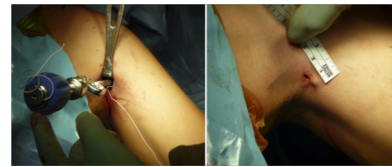
### Ténoùèse Sous-Pectorale



Ténodèse Sous-Pectorale



Ténodèse Sous-Pectorale



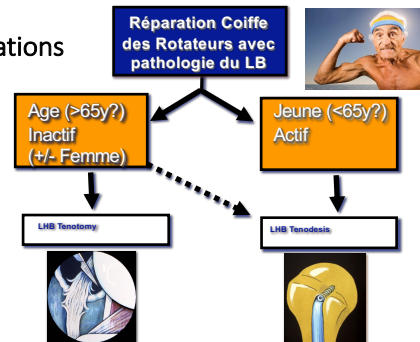
Symposium SFA 2006

	Tenotomy	Tenodesis	p
Cosmesis (Popeye Sign)	31%	10%	0.001
Muscle Cramps	24%	12.5%	ns
Decreased Force in elbow Flexion (contralateral side)	-20%	-9%	0.02
Decreased Force in supination	-12%	-3%	0.005



Boileau et al. RCO 2007

Indications



Merci

